

**RESEARCH ARTICLE****Retained facial foreign body following trauma in a child: a case report****Abhishek Kumar**

Research Scholar, Shri Jagdishprasad Jhabarmal Tibrewala University, Jhunjhunu, Rajasthan

Manuscript Info**Manuscript History:**

Received: 14 November 2015
Final Accepted: 26 December 2015
Published Online: January 2016

Key words:

Paediatric trauma, soft tissue injuries, maxillofacial injuries.

Corresponding Author*Abhishek Kumar.****Abstract**

Traumatic injuries in orofacial region often drive foreign bodies in the soft tissues. They are secondary to penetrating or abrasive trauma resulting in bleeding and deep wound. The foreign body may sometimes remain unnoticed. This case report is of a 32 month old male patient who reported to the Department of Pedodontics and Preventive dentistry with complain of thorn prick injury on right side of the face. On palpation, linear mass on the right cheek region measuring about 3-4 cm in length with small eruption on skin suggestive of healed opening was evaluated. Soft tissue ultrasonography (USG) was advised along with blood investigation. Soft tissue USG did not disclose any foreign body. Blood investigation was normal. Surgical exploration revealed a thorn measuring 17 mm in size. The wound was debrided and sutures placed at the site of incision. The 6-month clinical follow-up revealed uneventful soft issue healing. Early and definite diagnosis correlating clinical and radiologic examination is important for conservative management of such lesion thus eliminating potential risk of developing larger infection.

*Copy Right, IJAR, 2016. All rights reserved.***Introduction:-**

Trauma is the leading cause of morbidity and mortality among children worldwide (Haug and Foss, 2000). Soft tissue injuries are more common than fractures in children who have sustained facial trauma, particularly in younger children whose facial skeletons are resistant to fracture (Gassner et al., 2004). However, in comparison with adults, maxillofacial fractures in children are relatively uncommon due to physiological and environmental factors (Oji, 1998; Ugboke, 1998). According to Nørholt et al. 1993, fractures of the pediatric maxillofacial skeleton are rare due to the resiliency of their bones, the relatively small size of their body in proportion to the head and the comparatively protected lifestyle of children.

During initial assessment of any facial injury, it is important to review the mechanism and time of injury and determine whether it was witnessed. Knowing what caused the injury will be valuable during later exploration and debridement of wounds and the prediction of subsequent wound healing. Every effort should be made to cleanse the wound and remove all foreign material; this may have to be done in the operating room under anesthesia. These retained foreign bodies which are often missed at initial evaluation result in inflammation, pus discharge, and toxicity and delayed healing of wounds.

Case description:-

A 32 months old male patient reported to the Department of Pedodontics and Preventive Dentistry, College of Dental Surgery, B.P Koirala Institute of Health Sciences, Dharan, Nepal with complaint of thorn prick injury on the right side of. (Figure1). The patient had fallen from a tree and was injured two months back. No treatment was sought for the condition at the time of trauma. Medical history was not significant. On examination, a palpable linear mass on the right cheek region measuring about 3-4 cm in length with small eruption on skin suggestive of healed opening was evaluated. The mass was movable upon palpation in all directions. There was no pain or tenderness

upon palpation. There was no history of fever and pus discharge. Soft tissue ultrasonography (USG) was advised along with blood investigation. Soft tissue USG did not disclose any foreign body. Blood investigation was normal.

On the basis of clinical findings, a surgical exploration was planned under local anesthesia to remove the foreign body. Intra-dermal local anesthesia (Lignocaine hydrochloride 2%, adrenaline 1:200000) was administered. A small incision was given at the most fluctuant point of the scar with the help of a B.P blade. The lesion was explored with curved artery forceps and a wooden piece which was curved at one end and pointed at the other end and measuring 17mm was removed. (Figure2). The lesion was cleansed and irrigated with Betadine (Povidone-Iodine) solution and saline. A 3-0 silk suture was placed at the site of incision (Figure 3). The patient was prescribed with antibiotic and analgesic and was recalled after one week for suture removal. The patient was followed up till 6 months and the healing was uneventful (Figure 4)

Discussion:-

Soft tissue injuries, whether isolated or in combination with other injuries, are among the most common traumatic craniofacial injuries encountered by emergency department personnel and plastic surgeons. These injuries account for nearly 10% of all emergency department visits (Hussain, 1994; Mitchener et al., 2010; Ong, 1999).

Unintentional injury, defined as every disability occurring under accidental circumstances, is a significant health problem in children in the general practice, accounting for 9% of all new health problems in children (Hambidge et al., 2002). Divided into three overlapping aesthetic subunits (infraorbital, preauricular, and buccomandibular), the cheeks are by surface area the largest subunit of the face. This size correlates with both a high frequency of injury to the cheek and underlying structures as well as a multitude of approaches that can be used for posttraumatic reconstruction (James, 2010).

Foreign bodies can penetrate soft tissues through open wounds and laceration sustained during trauma or by direct impact against them. Such wounds harboring foreign bodies may appear to be deceptively minor and may not be accompanied by any major symptoms. But if these foreign bodies are left undetected in the tissues they can result in serious consequence days, months or years after initial trauma (Van der Wal, 2000).

Penetrating retained wooden bodies acts as foreign body, usually dirty and carry many microorganisms (Krimmel, 2001). Because of their porous consistency and organic nature, provide a good medium for the growth of the microbial agents. Infection resulting from the retained wooden body may lead to complications such as abscess and fistula formation (Kapila, 1995). The case presented in this report also had a retained wooden foreign body for a period of two months but the patient did not develop any complications as such except presence of a linear scar on the cheek.

The foreign body removal can be delayed in approximately one third of all foreign bodies, because they are initially radiologically missed or misdiagnosed (Robinson et al., 1997). Occasionally, foreign bodies can be retained for some time causing persistent and distressing symptoms (Cameron et al., 2006). It is often difficult to remove foreign bodies in the head and neck because they are usually near vital structures, or the difficult access (Paoli et al., 2001). The careful assessment is required for the identification and location of the retained foreign body, which is essential for the surgical removal (Manekar et al., 2013).

Early diagnosis and definitive treatment as well as good postoperative wound care are important when dealing with soft tissue injuries. Since the initial assessment of these patients may involve a Dentists, a proper knowledge of the diagnosis and management of soft tissue trauma is necessary.

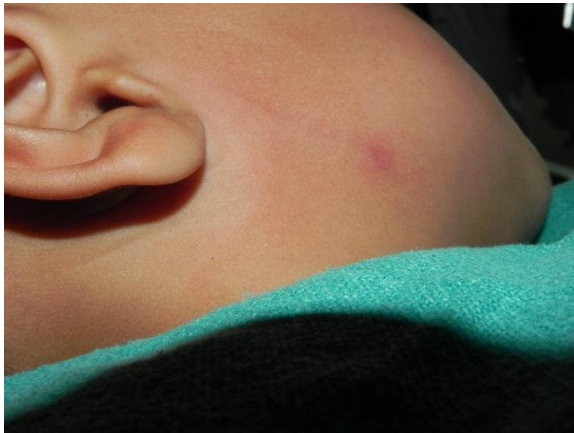

Figure 1 Pre-Operative




Figure 2 Foreign Body

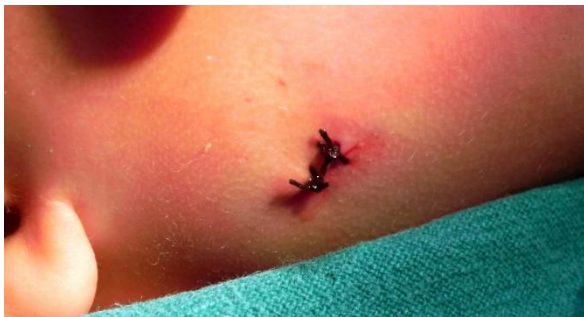

Figure 3 Immediate Post-Operative

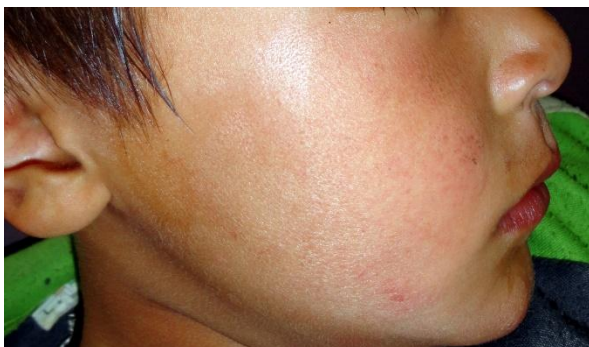

Figure 4. 6 months follow up recall

References:-

1. Cameron M.Philips B. Snookered facial infection secondary to occult foreign body. *Int J Oral MaxillofacSurg* 2006;35:373-75
2. Gassner R, Tuli T, Hachl O, Moreira R, Ulmer H. Cranio maxillofacial trauma in children: a review of 3,385 cases with 6,060 injuries in 10 years. *J Oral MaxillofacSurg* 2004; 62(4):399–407.
3. Hambidge SJ, Davidson AJ, Gonzales R, Steiner JF. **Epidemiology of pediatric injury-related primary care office visits in the United States.** *Pediatrics.* 2002;109:559–565
4. Haug RH, Foss J. Maxillofacial injuries in the paediatric patient. *Oral Surg Oral Med Oral Pathol Oral Radiol Endod.*2000;90:126.
5. Hussain K, Wijetunge D B, Grubnic S, Jackson I T. A comprehensive analysis of craniofacial trauma. *J Trauma.* 1994; 36:34–47.
6. James D. Kretlow, Aisha J. McKnight, Shayan A. Izaddoost. *SeminPlast Surg.* Nov 2010; 24(4): 348–356.
7. Kapila BK,Lata J. Unusual foreign bodies: three case reports.*Int J Oral Maxillofac Surg.*1995;24:208-9
8. Krimmel M, Cornelius CP, Stojadinovic S, Hoffman J, Reinert S, Wooden foreign bodies in facial injury: a radiological pitfall.*Int J Oral and Maxillofac Surg.*2001;30:445-7
9. Manekar VS. Chavan A. Retained Metallic Foreign Body in Cheek: A Diagnostic and Surgical Challenge.*Int J Head Neck Surg* 2013;4(2):107-109
10. Mitchener T A, Canham-Chervak M. Oral-maxillofacial injury surveillance in the Department of Defense, 1996-2005. *Am J Prev Med.* 2010;38(1, Suppl):S86–S93.
11. Norholt SE, Khrishnan V, Sidet-Pedersen S, Jensen IB. Paediatric condylar fractures: a long term follow-up study of 55 patients. *J Oral Maxillofac Surg.* 1993;41:1302-1310.
12. Oji C.Fractures of the facial skeleton in children; a survey of patients under the age of 11 years.*J Cranio-Maxfac Surg.*1998;26:322-325.
13. Ong T K, Dudley M. Craniofacial trauma presenting at an adult accident and emergency department with an emphasis on soft tissue injuries. *Injury.* 1999; 30:357–363.
14. Paoli JR,Dekeister C. A tooth in the orbit. *Br J Oral MaxillofacSurg* 2001;39(4):327
15. Robinson PD, Rajayoeswaran V, Orr R. Unlikely foreign bodies in unusual facial sites.*Br J Oral MaxillofacSurg* 1997;35:36-39
16. Ugboko VI, Odusanya S, Ogunbodede E. Maxillo facial fractures in children. *PaedDentJ.* 1998;8:31-35.
17. Van der Wal KG, Bourkes RJ.Intra-orbital bamboo foreign body in a chronic stage: Case report.*Int J Oral MaxillofacSurg* 2000;29:428-29.