



ISSN NO. 2320-5407

Journal homepage: <http://www.journalijar.com>
Journal DOI: [10.21474/IJAR01](https://doi.org/10.21474/IJAR01)

INTERNATIONAL JOURNAL
OF ADVANCED RESEARCH

RESEARCH ARTICLE**AORTOCAVAL EXTRA ADRENAL PHEOCHROMOCYTOMA.**

Thulasi Kumar, Sritharan Narayanan, Ashhok Kumar and Subrayan Lakshminarayanan.

Manuscript Info**Abstract****Manuscript History:**

Received: 12 May 2016
Final Accepted: 19 June 2016
Published Online: July 2016

We report a case of extra adrenal pheochromocytoma in a young adult male with hypertension having a tumour in inter aorto- caval region which was managed with excision after careful planning with adequate optimization and surgical expertise.

Key words:

Catecholamines.

***Corresponding Author**

Thulasi kumar.

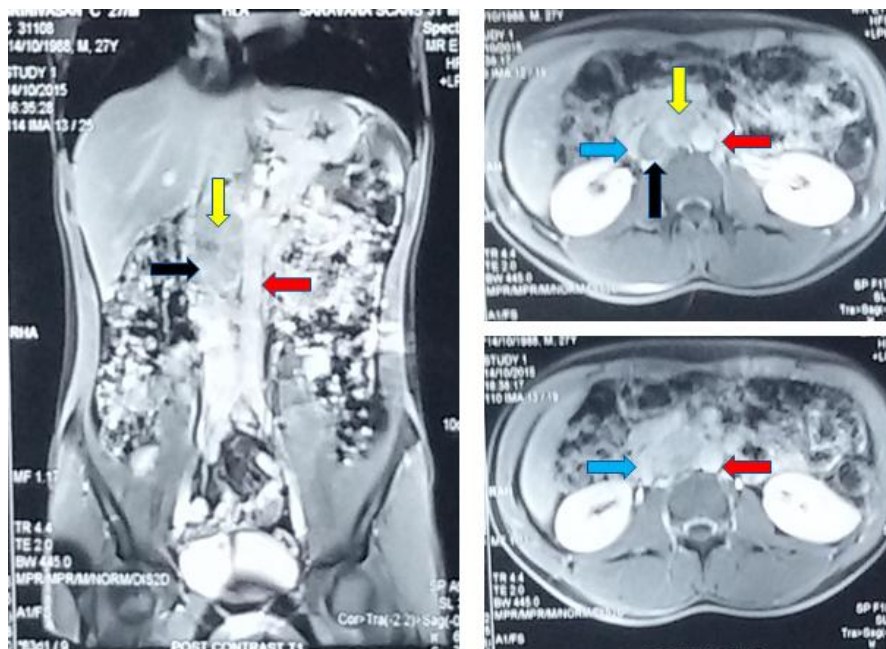
Copy Right, IJAR, 2013,. All rights reserved.

Introduction:-

Pheochromocytomas are catecholamine secreting neuroendocrine tumors that arise from chromaffin cells of sympathoadrenal system. Usually found in the adrenal gland, but also occur in extra adrenal sites. Most of the tumours secrete predominant noradrenaline than adrenaline. Though it's a rare tumour accounting for 0.1% of hypertension it poses a great challenge for the management. Morbidity and mortality is quoted to be 50% in an unexpected emergency situation and less than 2% in a planned surgery. Management of aortocaval extra adrenal pheochromocytoma is highly challenging both in medical and surgical grounds. Medically because of high degree of hemodynamics changes associated during pre, intra and post operative periods. Surgically because of location of tumour near major vessels. Hence careful planning with adequate optimization and preoperative preparation, adequate intraoperative and postoperative management provides best successful result.

Case report:-

25 year male admitted for complaints of pain abdomen and headache for past 1 month. He was diagnosed to have hypertension and was on antihypertensive drugs for past 6 months. No other significant history. General examination findings were normal. His BP- 160/110 mmhg. Abdomen soft, no mass palpable per abdomen. His basic blood investigations were normal. ECG showed features of LVH and Echo - conc. LVH, normal LV systolic function. Urinary VMA (vanillyl mandelic acid) found to be normal. Then plasma metanephrines was done which was elevated 147pg/ml (normal < 90 pg/ml). CECT abdomen showed enhancing retroperitoneal soft tissue lesion to rule out retroperitoneal sarcoma. MRI abdomen revealed 4 x 3 x 6 cm oval lesion noted between IVC and aorta, compressing the IVC and displacing aorta.



With above features patient was diagnosed to have functioning aortocaval paraganglioma (pheochromocytoma) and planned for surgical excision.

Patient was preoperatively optimized by following measures.

he was started on t.prazosin 2mg bd and after 1 week was increased to 5mg bd until α blockade was attained. T. Propranolol 10 mg bd started later, T amlodipine 2.5 mg od was added. Pre op vitals were HR 74/min, BP- 130 / 80 mm hg, Spo2 - 100%, CVS / RS - NAD.

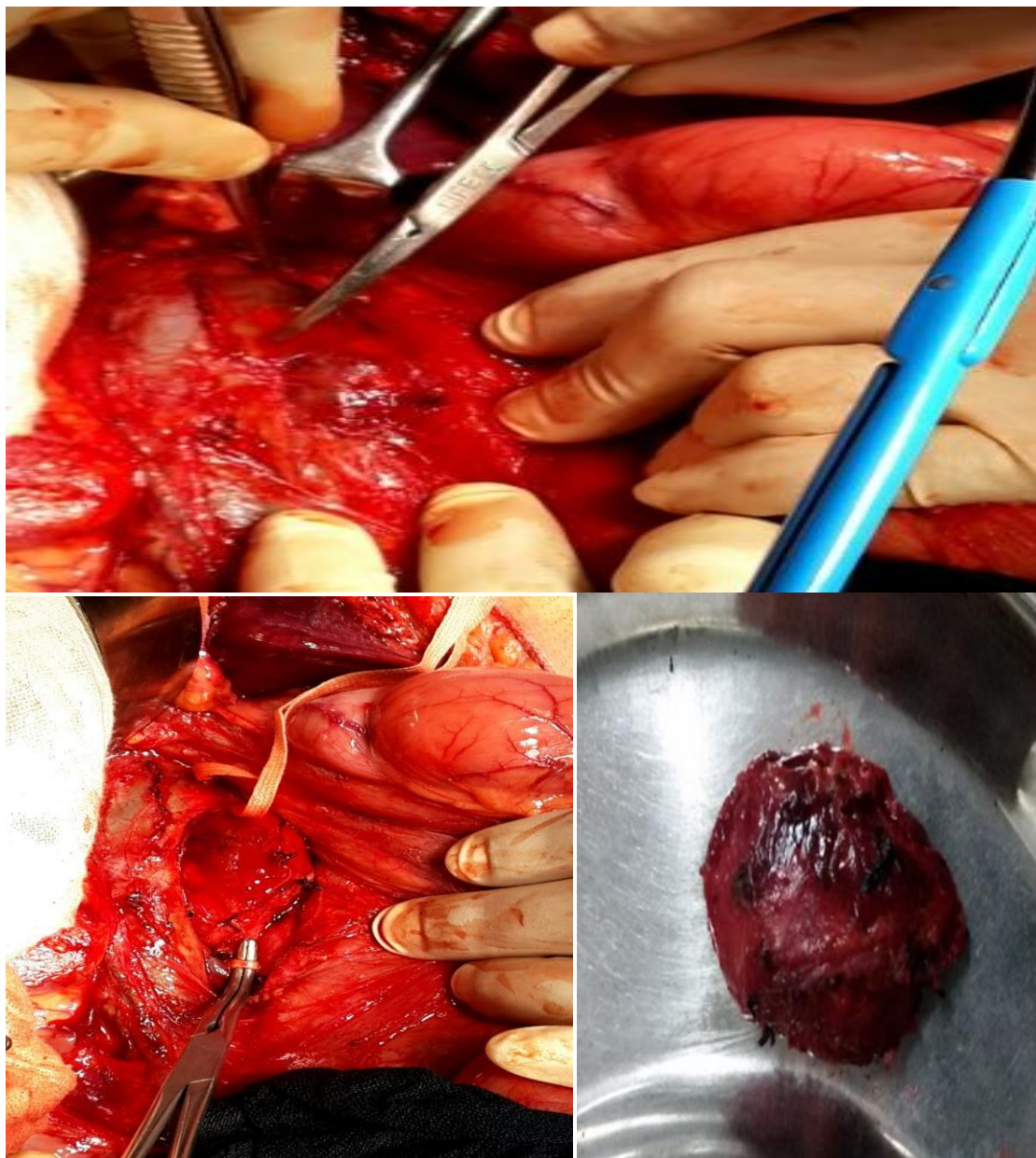
Intraoperatively : epidural with general anaesthesia was given with intraarterial continuous bp monitoring with cvp and peripheral lines. Duration : 4 hours, fluids : 3 litres of crystalloids, vital parameters :Hr : 48 - 110 / min, BP : 70 / 30 mm hg to 308 / 212 mm hg, Spo2 : 99 to 100 % , cvp : 10 to 18 cm h₂o

Drugs used ntraoperatively : Sodium nitro prusside : 1 to 3 μ g / kg / min iv given through aluminium foil covered infusion inorder to avoid light exposure , phenyl ephrine : 1 to 2 μ g / kg / min iv, esmolol : 0.1 to 0.2 mg / kg / min iv, metoprolol : (1+1) mg iv bolus, norepinephrine : 0.1 to 0.2 μ g / kg / min iv.

DAY-TIME	ART
19-11:40	179/137(152)
19-11:41	210/161(186)
19-11:42	285/195(240)
19-11:43	51/50(55)
19-11:44	308/212(245)
19-11:45	282/201(224)
19-11:46	251/185(207)
19-11:47	57/56(58)
19-11:48	196/161(172)

Procedure: midline vertical laparotomy incision made. Peritoneal cavity entered and bowels were pushed away from midline. Retroperitoneal cavity entered. Abdominal aorta, renal vessels and ivc exposed and clearly delineated from tumour mass. Left renal vein was found stretched over the lesion. Tumour of size 6x 4cm found at level of renal artery behind renal vessels between aorta and ivc.

Tumour dissected carefully from surrounding major vessels and structures and excised into without much handling, in order to avoid systemic entry of large amount of catecholamines. Hemostasis secured.



Post operative : after completion of the procedure patient was shifted to icu for elective mechanical ventilation with a supportive dose of phenylephrine infusion at a rate of 2 micro gm/kg/min. Later the dose of phenylephrine was tapered and weaned off. Patient was given epidural bupivacaine + fentanyl at the dose of 5ml / hr for pain relief. Patient was extubated the next day morning with normal vitals. T.prazosin was tapered gradually. Postoperative period was uneventful. His blood pressure normalized. Discharged 10th POD without any antihypertensives. Hpe reported as paraganglionoma – pheochromocytoma. Post operative urinary vma and plasma metanephrines at 3 months were found to be normal. patient on regular follow up without need of any antihypertensive drugs.

Conclusion:-

Management of aortocaval extra adrenal pheochromocytoma is highly challenging but with careful planning and adequate optimization and surgical expertise it can be successfully managed.

References:-

1. Noguchi K, Okada K, Kawamura H, Ishizu H, Honma S. Nonfunctional retroperitoneal paraganglioma simulating pancreatic tumor: report of a case. *Am Surg* 2012; 78: E244-5.
2. Manabe O, Oyama-Manabe N, Alisa K, et al. Multimodality evaluation of cardiac paraganglioma. *Clin Nucl Med* 2012; 37: 599-601.
3. Disick GI, Palese MA. Extra-adrenal pheochromocytoma: diagnosis and management. *Curr Urol Rep* 2007; 8: 83-8.
4. Tischler AS, Kimura N, Mcnicol AM. Pathology of pheochromocytoma and extra-adrenal paraganglioma. *Ann N Y Acad Sci* 2006; 1073: 557-70.
5. Astuti D, Douglas F, Lennard TW, et al. Germline SDHD mutation in familial pheochromocytoma. *Lancet* 2001; 357: 1181-2.
6. Lack EE, Cubilla AL, Woodruff JM. Paragangliomas of the head and neck region. A pathologic study of tumors from 71 patients. *Hum Pathol* 1979; 10: 191-218.
7. Lack EE, Cubilla AL, Woodruff JM, Lieberman PH. Extra-adrenal paragangliomas of the retroperitoneum: a clinicopathologic study of 12 tumors. *Am J Surg Pathol* 1980; 4: 109-20.
8. Davidovic LB, Djukic VB, Vasic DM, Sindjelic RP, Duvnjak SN. Diagnosis and treatment of carotid body paraganglioma: 21 years of experience at a clinical center of Serbia. *World J Surg Oncol* 2005; 3: 10.