



ISSN NO. 2320-5407

Journal Homepage: -[www.journalijar.com](http://www.journalijar.com)

## INTERNATIONAL JOURNAL OF ADVANCED RESEARCH (IJAR)

Article DOI:10.21474/IJAR01/3308  
DOI URL: <http://dx.doi.org/10.21474/IJAR01/3308>



INTERNATIONAL JOURNAL OF  
ADVANCED RESEARCH (IJAR)  
ISSN 2320-5407  
Journal homepage: <http://www.journalijar.com>  
Journal DOI:10.21474/IJAR01

### **RESEARCH ARTICLE**

#### **COMPUTED TOMOGRAPHIC EVALUATION OF ANATOMICAL VARIANTS OF PARANASAL SINUSES IN SINUSITIS.**

**Dr. Amita Kumari<sup>1</sup>, Dr. Manoj Mathur<sup>2</sup>, Dr. Amarjit Kaur<sup>3</sup>, Dr. Navkiran kaur<sup>4</sup>, Dr. Jasvir Singh<sup>5</sup> and Dr. Samrin Haq<sup>6</sup>.**

1. Senior resident radiology GMC Patiala.
2. Associate Professor Radiology GMC Patiala.
3. Professor Radiology GMC Patiala.
4. Professor and Head of Department Radiology GMC Patiala.
5. Junior Resident GMC Patiala.
6. Junior resident GMC Patiala.

#### **Manuscript Info**

##### **Manuscript History**

Received: 22 December 2016  
Final Accepted: 15 January 2017  
Published: February 2017

##### **Key words:-**

Paranasal Sinuses (PNS), Osteomeatal complex (OMC), Deviated Nasal Septum (DNS).

#### **Abstract**

**Background and objectives:** The study was done to evaluate the role of computed tomography (CT) of Paranasal sinuses to determine the background prevalence of bony anatomical variations and mucosal abnormalities of paranasal sinuses in clinically suspected cases of sinusitis. The information provided by the preoperative CT Scan paranasal sinus (PNS) coronal view acts as a road map for the patients undergoing for functional endoscopic sinus surgery (FESS) to reduce the complications during surgeries and thus reducing morbidity and mortality of patients. The study was conducted on 60 cases attending CT section of Radiodiagnosis Department of Rajindra Hospital, Patiala.

**Materials And Methods:** The study was conducted on 60 cases over a period 3 years from 2010 to 2013 irrespective of gender and age group. Selection of patients were based on clinical features like nasal or post nasal discharge, nasal obstruction, headache, anosmia, cough and hoarseness of voice. Relevant history, clinical examination and non-contrast CT Scan of paranasal sinuses (PNS) was performed of every patient in Coronal view complemented by Axial view.

**Results:** It was observed that multi anatomical variations were more as compared to single anatomical variations. In our study deviated nasal septum was the most common finding seen in 46% of cases followed by concha bullosa, uncinata process variations, onodi cells, haller cells and agger nasi cells.

**Conclusion:** Evaluation of CT Scan PNS concluded that deviated nasal septum and anatomical variations at lateral wall of nose causes narrowing of osteomeatal complex area which predisposes to sinusitis in the patients.

*Copy Right, IJAR, 2017,. All rights reserved.*

**Introduction:-**

Acute rhinosinusitis is a clinical condition lasting less than 4 weeks, and subacute rhinosinusitis is present for more than 4 weeks but less than 12 weeks. Chronic sinusitis is a clinical diagnosis and is defined as a rhinosinusitis lasting >12 weeks that includes two or more major sinus symptoms or at least one major and two minor sinus symptoms with or without findings on physical examination[1]. Chronic rhinosinusitis is the most common disease for which ENT consultation is required. The characteristic findings of sinus disease include air-fluid levels, mucosal thickening, and opacification of the normally aerated sinus lumen. The single distinguishing feature of acute sinusitis is the air-fluid level as an isolated finding, whereas the only characteristic finding in chronic sinusitis is sclerotic, thickened bone of the sinus wall[2].

Drainage and ventilation of paranasal sinuses are important for the normal function which in turn depends on effective mucociliary clearance. Drainage of secretions in paranasal sinuses follows definite course. The frontal and maxillary sinuses communicate with middle meatus through prechambers. Mucosa of prechambers are closely opposed and clearance of it is through ciliary action. These narrow prechambers are blocked by mucosal inflammation which affects ciliary clearance. It establishes a vicious cycle of infection and stasis causing chronic sinusitis[1-3]. The key region for these changes is that part of the lateral nasal wall that encloses the sinus ostia and their adjacent mucosa and prechambers. There is considerable anatomical variation in this area that may interfere with normal nasal function and predispose to recurrent or chronic sinusitis[3].

The anatomical variation of osteomeatal complex causes obstruction to OMC Complex and prevent mucous drainage and predispose to chronic sinusitis. Obstruction of the osteomeatal complex causes a vicious cycle of events that leads to sinusitis. Its obstruction leads to mucosal congestion that decreases airflow. These anatomical variations may lead to OMC obstruction.

Surgical clearance of these chronically infected sinuses while maintaining their ventilation and drainage is the treatment of choice.

Imaging of PNS has progressed from the realm of conventional radiograph almost exclusively into realms of computed tomography and magnetic resonance imaging. Both these two technological advances in imaging modalities provide greater detail and about the anatomic extent of disease. Plain radiography has limited value for imaging paranasal sinuses, especially the ethmoid sinuses and the ostiomeatal complex and its use is not indicated [4-5].

CT is the technique of choice in the preoperative evaluation of the nose and paranasal sinuses and is the gold standard for delineation of inflammatory sinus disease resulting from obstruction [6].

The two primary diagnostic imaging techniques for evaluating the paranasal sinuses are CT and MRI. CT PNS plays an important role in the preoperative evaluation of patients considered for FESS called SSCT (Screening Sinus CT). It is now mandatory and medico-legal requirement to evaluate the PNS and nose before FESS. CT is superior to MRI for the delineation of the fine bone structures of the infundibular complex, orbital lamina, orbital floor, and cribriform lamina. Thus, CT is superior to MRI in planning FESS. With MRI, these bone structures have low signal intensity, making them difficult to completely assess [7-8].

**Material and Methods:-**

The present study was a hospital based prospective study conducted in Rajindra Hospital Patiala in patients who presented with clinical symptoms of chronic sinusitis. The study sample was limited to 60 patients and was done over a period of three years from 2010-2013. Institutional review board approval for conducting this study was obtained and informed consent of study patients was taken.

CT scan was performed with Siemens-Somatom Emotion 6 slice third generation spiral CT. Slices of 5 mm were taken in axial and coronal planes. Coronal scan was done with patient lying prone with chin hyperextended and gantry tilted to the approximate plane at right angle to the orbitomeatal line. Scanning was done from anterior wall of frontal sinus to posterior wall of sphenoid sinus. In all the patients FESS was done under local anaesthesia 2% lignocaine with 1:1,00,000 adrenaline was used for mucosal infiltration for anaesthesia and vasoconstriction. Patients were placed in supine position with head turned towards examiner. Endoscope was fixed just above the

nostril with thumb and forefinger of left hand while it was gently introduced with right hand, care was taken not to cause mucosal damage. Endoscope was introduced initially along the floor of nose till nasopharynx was seen and then withdrawn slowly to look for disease pathology. It was then removed and reintroduced below the middle turbinate to examine middle meatus and sphenoidal recess. When endoscope was in middle meatus, the uncinate process, bulla ethmoidalis, hiatus semilunaris, infundibular opening and maxillary sinus opening were inspected. The endoscope was passed posteriorly after viewing the middle meatus area to examine sphenoidal area. Depending upon disease appropriate endoscopic sinus surgery was done which could be uncinectomy, middle meatus antrostomy, anterior ethmoidectomy, posterior ethmoidectomy, sphenotomy, resection of middle turbinate.

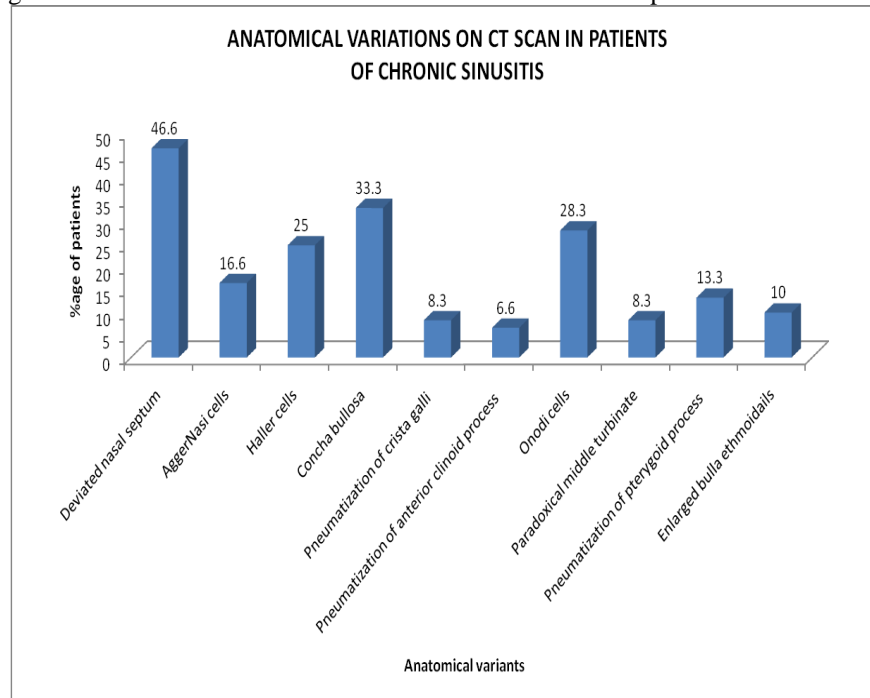
### Results:-

In present study, there were 35 males and 25 females in the study group. The disease frequency was found to be maximum in age group 21-30 years (31.66%). The common presenting symptoms were nasal obstruction in 70% cases and headache in 66.6%. On anterior rhinoscopy examination, deviated nasal septum (46.6%) was the most common sign followed by inferior turbinate hypertrophy (31.6%). Maxillary sinus was most frequently involved (80%).

**Table 1:-**Anatomical variations on CT scan in patients of chronic sinusitis.

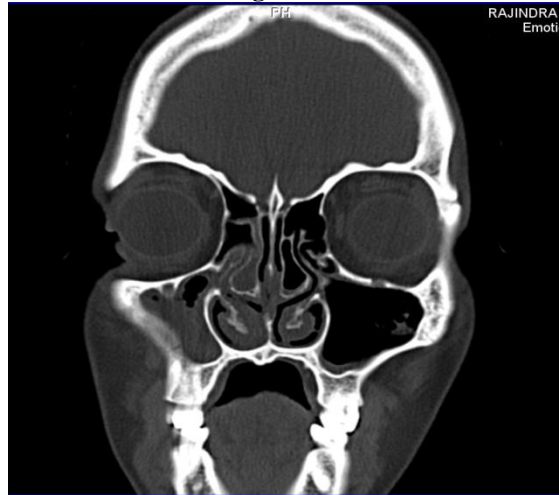
Anatomical Variants	No. of cases	%age
Deviated nasal septum	28	46.6
Concha bullosa	20	33.3
Uncinate process variations	18	30
Agger Nasi cells	10	16.6
Haller cells	15	25
Pneumatization of crista galli (PCG)	5	8.3
Pneumatization of anterior clinoid process (PAC)	4	6.6
Onodi cells	17	28.3
Paradoxical middle turbinate(PMT)	5	8.3
Pneumatization of pterygoid process (PTG)	8	13.3
Enlarged bulla ethmoidalis	6	10

**Table 2:-** Bar diagram shows various anatomical variants in chronic sinusitis patients



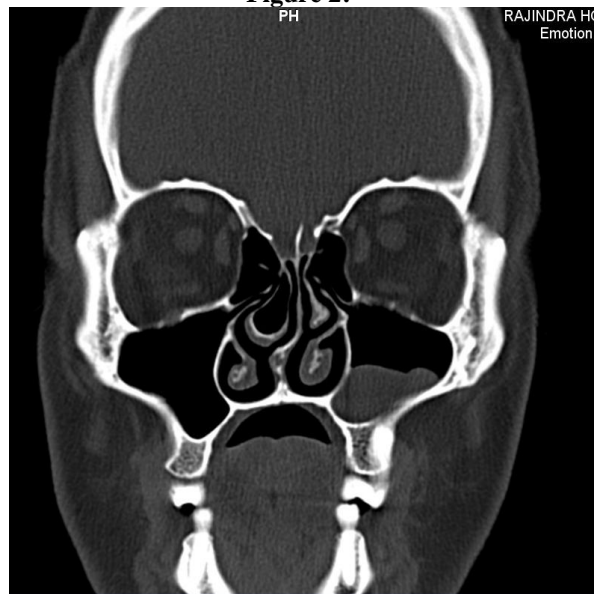
DNS, Concha bullosa, uncinate process variations, Haller cells and onodi cells were the common anatomic variants noted in 46.6%, 33.3%, 30%, 25% and 28.3% cases respectively. The other less common variants noted were Pneumatization of pterygoid process, Agger nasi cells, Pneumatization of anterior clinoid process, enlarged bulla ethmoidalis, Paradoxical middle turbinate and Pneumatization of crista galli.

**Figure 1:-**

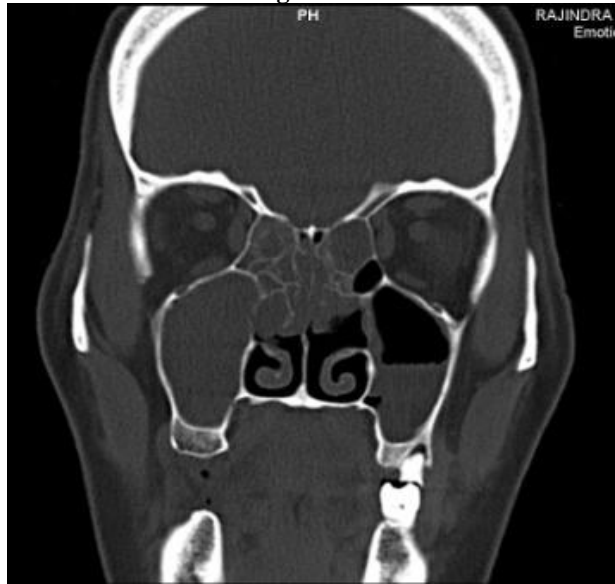


Coronal CT image shows bilateral concha bullosae with maxillary sinusitis

**Figure 2:-**



Coronal CT image shows right concha bullosa with S-shaped DNS and left maxillary sinusitis

**Figure 3:-**

Coronal CT image shows pansinusitis with left Haller cell.

### **Discussion:-**

The complex regional anatomy of the paranasal sinuses has only recently been elucidated through the use of modern imaging techniques. The advent of computerized tomography in the delineation of sinonasal pathology and anatomic variations has proven invaluable to the otolaryngologist in preoperative planning for functional endoscopic sinus surgery. Stammberger et al<sup>[9]</sup> proposed that stenosis of the osteomeatal complex, from either the anatomical configuration or hypertrophied mucosa, can cause obstruction and stagnation of secretions that may become infected or perpetuate infection.

### **Mucosal abnormality of sinuses on CT scan:-**

Mucosal abnormality percentage of various paranasal sinuses noted on CT scan in present study were compared with other studies. In the present study, maxillary sinus was most frequently involved in 80% cases followed by anterior ethmoid, posterior ethmoid, sphenoid & frontal sinuses respectively.

### **Patterns of sinonasal Disease:-**

Five recognisable patterns of inflammatory sinonasal disease were seen on CT in present study. In the present study OMU pattern was the most common pattern observed in 35% cases.

### **Anatomic variations in region to paranasal sinuses noted on CT scan:-**

Anatomic variations are important for that they may narrow normal drainage channels, thereby predispose to chronic recurrent sinusitis. They increase operative risk and surgeon should be forewarned about these. Different investigators report different prevalence rates. Though variations may be encountered in the normal population (without sinusitis) their prevalence rates are significantly higher in patients with chronic sinusitis. In our study we observed that DNS, Concha Bullosa,uncinate process, Haller cells, Onodi cells & Pneumatization of pterygoid process were the common anatomic variants in 46.6%, 33.3%,30%, 25%, 28.3%, 13.3% of patients.

### **Deviated nasal septum:-**

Nasal septum is fundamental in the development of the nose and paranasal sinuses. It is the epiphyseal platform for the development of the facial skeleton. 46.6% of the patients in our study presented with nasal septal deviation. Deviated nasal septum (Figure 2) causes a decrease in the critical area of the osteomeatal unit predisposing to obstruction and related complications. Similar finding were observed by Mamatha et al<sup>[10]</sup> (65%) And Dutra et al<sup>[11]</sup> (14.1%).

**Concha bullosa:-**

Concha bullosa (pneumatized middle turbinate) (Figure 1,2) has been implicated as a possible aetiological factor in the causation of recurrent chronic sinusitis. It is due to its negative influence on paranasal sinus ventilation and mucociliary clearance in the middle meatus region as quoted by Tonai et al<sup>[12]</sup>. The incidence of concha bullosa was 33% which is less as compared to the reported incidence of 53.6% by Bolger et al<sup>[15]</sup>, 42.6% by Maru et al<sup>[14]</sup>, 34.1% by Wanamaker et al<sup>[13]</sup>.

**Uncinate process variation:-**

Uncinate process may be curved or bent. Hypertrophied uncinate process causes narrowing of hiatus semilunaris and the ethmoid infundibulum. It has also been suggested as a predisposing factor for impaired ventilation of the inferior group of sinuses and frontal sinuses. In our study hypertrophy of uncinate process was seen in 30% of cases. Results were compared with study by Bolger et al<sup>[15]</sup> in which reported incidence was 2% and Asruddin et al<sup>[16]</sup> and 9.8% by Maru et al<sup>[14]</sup>.

**Agger nasi cells:-**

Agger nasi cells lie just anterior to the anterosuperior attachment of the middle turbinate and frontal recess. These can invade the lacrimal bone or the ascending process of maxilla. These cells were present in 16.6% of cases. The incidence is less as compared to 98.5% by Bolger et al<sup>[15]</sup>, 88.5% by Maru et al<sup>[14]</sup> and 96% by Wanamaker et al<sup>[13]</sup>. But Asruddin et al<sup>[16]</sup> reported an almost similar incidence of 48%.

**Haller cells:-**

Haller's cells (Figure 3) are ethmoid air cells that project beyond the limits of the ethmoid labyrinth into the maxillary sinus. They are considered as ethmoid cells that grow into the floor of orbit and may narrow the adjacent ostium of the maxillary sinus especially if they become infected. The incidence of Haller's cells in our study was 25%. Llyod et al<sup>[17]</sup> reported 15%, Tonai et al<sup>[12]</sup> reported 20%.

**Onodi cell:-**

Onodi cells are posterior ethmoid cells that extend posteriorly, laterally and sometimes superior to sphenoid sinus, lying medial to the optic nerve. The chances of injury of optic nerve are increased when the bony canal of the nerve is lying dehiscient. The surgeon must pay close attention to the occasional onodi cell in the preoperative evaluation to avoid potential complication of FESS. It was found in 3.5% of cases in our study. A similar incidence was found by Jones et al<sup>[18]</sup> in 8/200 patients.

**Paradoxical middle turbinate:-**

Stammberger et al<sup>[9]</sup> accepted paradoxical curvature of middle turbinate as an etiological factor for chronic rhinosinusitis because it may cause obliteration or alteration in nasal airflow dynamic. Incidence of paradoxical middle turbinate in our study was observed to be 8.3%. Incidence of paradoxical middle turbinate was <10% according to Yousem et al<sup>[19]</sup>, 27% by Bolger et al<sup>[15]</sup>, 15% according to Zinreich et al<sup>[20]</sup>, 12% according to Asruddin et al<sup>[16]</sup>.

**Pneumatization of crista galli, anterior clinoid process & pneumatization of pterygoid process:-**

In present study pneumatization of crista galli was seen in 8.3% cases and anterior clinoid process in 6.6% cases, pterygoid process pneumatization was seen in 13.3%. According to Bolger et al<sup>[15]</sup> any degree of pneumatization of the anterior clinoid process was considered significant and noted incidence of crista galli pneumatization in 83.7% cases of anterior clinoid process pneumatization in 13.3% and of pterygoid process in 43.6% of cases.

**Infundibular opacification and ipsilateral maxillary sinus disease:-**

In present study when infundibulum was opacified 94.4% of ipsilateral maxillary sinuses showed mucosal abnormality on CT scan, when infundibulum was normal, only 4.1% of the ipsilateral maxillary sinuses were abnormal. So, there was significant association between infundibular opacification and ipsilateral maxillary sinus disease. Our results are comparable to Bolger et al<sup>[15]</sup>, who found that when disease was present in infundibulum, 98% of cases had mucosal thickening of ipsilateral maxillary sinuses. When infundibulum was normal, ipsilateral maxillary sinuses were normal in 95.8% of cases.

**Conclusion:-**

CT may reveal an anatomic abnormality that predisposes to sinusitis, however, the treatment (medical or surgical) should be based on combined information extracted from clinical evaluation, CT and endoscopy findings. In present study, maxillary sinus was most commonly involved. DNS and Concha bullosa were the most common anatomic variants that lead to chronic sinusitis. CT is the imaging modality of choice to reveal mucosal changes deeper in osteomeatal complex which are not visible endoscopically and to identify extent of paranasal sinus disease.

**References:-**

1. Lanza DC, Kennedy DW. Adult rhinitis defined. *Otolaryngol Head Neck Surg* 1997;117 (3 Pt2):S1-7.
2. Lund VJ, Kennedy DW, and the Staging and Therapy Group. Quantification for staging sinusitis. *Ann Otol Rhinol Laryngol* 1995;167(Suppl):17-21.
3. Shapiro ED, Milmoie GJ, Wald ER, Rodnan JB, Bowen AD. Bacteriology of the maxillary sinuses in patients with cystic fibrosis. *J Infect Dis* 1982; 146:589-93.
4. Smith LF, Brindley PC, Galveston H. Indications, evaluation, complications and results of functional endoscopic sinus surgery in 200 patients. *Otolaryngol Head Neck Surg*.1993; 108: 688-696.
5. Davidson TM, Brahme FJ, Gallagher ME. Radiographic evaluation of nasal dysfunction: computed tomography versus plain films. *Head Neck* 1989;11:405-9.
6. Kronemer KA, McAlister WH. Sinusitis and its imaging in the pediatric population. *Pediatr Radiol*1997 ; 27:837-46.
7. Duvoisin B, Landry M, Chapuis L, Krayenbuhl M, Schnyder P. Low-dose CT and inflammatory disease of the paranasal sinuses. *Neuroradiology* 1991;33: 403-06.
8. Rao VM, Noueam KI. Sinonasal imaging: anatomy and pathology. *Radiol Clin North Am* 1998;36 : 921-39.
9. Stammberger H. Endoscopic endonasal surgery- concepts in treatment of recurring rhinosinusitis. Part 1. Anatomic and pathophysiologic considerations. *Otolaryngol Head Neck Surg* 1986;94:143.
10. Mamatha H, Shamasundar NM, Bharathi M, Prasanna L. Variations of ostiomeatal complex and its applied anatomy: a CT scan study. *Indian J Sci Technol* 2010; 3: 904-7.
11. Dutra LD, Marchiori E. Helical computed tomography of the paranasal sinuses in children: evaluation of sinus inflammatory diseases. *Radiologia Brasileira* 2002; 35: 161-9.
12. Tonai A, Baba S. Anatomic variations of the bone in sinonasal CT. *Acta Otolaryngol Suppl*(1996) 525:9-13.
13. Wanamaker HH. Role of Haller's cell in headache and sinus disease: a case report. *Otolaryngol Head Neck Surg* (1996) 114(2):324-27.
14. Maru YK, Gupta V. Anatomic variations of the bone in sinonasal CT. *Indian Journal of Otolaryngol and Head Neck Surgery* 2001; 53:123-28.
15. Bolger WE, Butzin CA, Parsons DS. Paranasal sinus bony anatomic variations and mucosal abnormalities: CT analysis for endoscopic sinus surgery. *Laryngoscope* 1991;56-64.
16. Asruddin, Yadav SPS, Yadav RK et al. Low dose CT in chronic sinusitis. *Ind Journal Otolaryngol and Head and Neck Surg* 1999-2000;52(1):17-22.
17. Lloyd GA. CT of the paranasal sinuses: study of a control series in relation to endoscopic sinus surgery. *J Laryngol Otol* (1990) 104(6):477-81.
18. Jones NS, Strobl A, Holland I. A study of the CT findings in 100 patients with rhinosinusitis and 100 controls. *Clin Otolaryngol Allied Sci.* 1997; 22: 47-51.
19. Yousem DM. Imaging of sinonasal inflammatory disease. *Radiology* 1993;188:303-14.
20. Zinreich J. Imaging of inflammatory sinus disease. *Otolaryngologic Clinics of North America* 1993;26(4):535-47.