



Journal Homepage: -[www.journalijar.com](http://www.journalijar.com)  
**INTERNATIONAL JOURNAL OF  
 ADVANCED RESEARCH (IJAR)**

Article DOI:10.21474/IJAR01/6952  
 DOI URL: <http://dx.doi.org/10.21474/IJAR01/6952>



### RESEARCH ARTICLE

#### OUTCOME ANALYSIS OF UPPER LIMB VASCULAR TRAUMA – OUR INSTITUTIONAL EXPERIENCE.

**Dr. Shanmugavelayutham Chitravelu, Prof. Elancheralathan Kalyanaraman, Prof. G. Thulasikumar, Dr. B. Deepan kumar and Dr. S. Saravanan.**

Department of Vascular Surgery, Govt. Stanley Medical College, Chennai.

#### Manuscript Info

##### Manuscript History

Received: 15 February 2018  
 Final Accepted: 17 March 2018  
 Published: April 2018

##### Keywords:-

Pseudoaneurysm  
 Ligation  
 Graft thrombosis  
 Limb salvage.

#### Abstract

**Introduction:** Vascular injuries involving major vessels can be limb threatening and at times life threatening. Ours being a tertiary care center, we encounter lot of vascular injuries due to industrial accidents and road traffic accidents. Loss of upper limb means loss of job. This study is to analyze the outcomes of upper limb vascular injuries.

**Methods:** This is a prospective study from August 2015 and is an ongoing study. We are submitting the interim report of the study till March 2018. All patients admitted with upper limb vascular trauma proximal to wrist irrespective of age and mode of injury were included in our study.

**Results:** Blunt injury was seen in 22 cases (68.75%). Most common complication was wound infection 6/32 (18.75%). Graft thrombosis seen in two patients (6.25%). Pseudoaneurysm with blow out occurred in 1 patient (3.125%) in spite of delayed presentation (>6 hours) and wound infections and ligation of artery due to pseudoaneurysm, all the limbs were saved (limb salvage rate is 100%).

**Conclusion:** Timely intervention in upper limb vascular injuries can save the limb and at times the life. This means they can be economically productive and lead an independent life.

*Copy Right, IJAR, 2018.. All rights reserved.*

#### Introduction:-

In the era of urbanization and industrialisation Road Traffic Accidents and industrial accidents have become more common. Ours being a tertiary care center we receive lot of patients with Polytrauma. Vascular injury is commonly seen in high velocity injuries. This study is to analyze the outcomes of upper limb vascular injuries. Stanley medical college has dedicated vascular surgery department catering industrial worker from north Chennai

#### Materials & Methods:-

This is a prospective study from August 2015, and it is an ongoing study. We are submitting the interim report of the study till March 2018. All patients admitted with upper limb vascular trauma proximal to wrist were included in our study.

**Corresponding Author:-Dr. Shanmugavelayutham Chitravelu,**

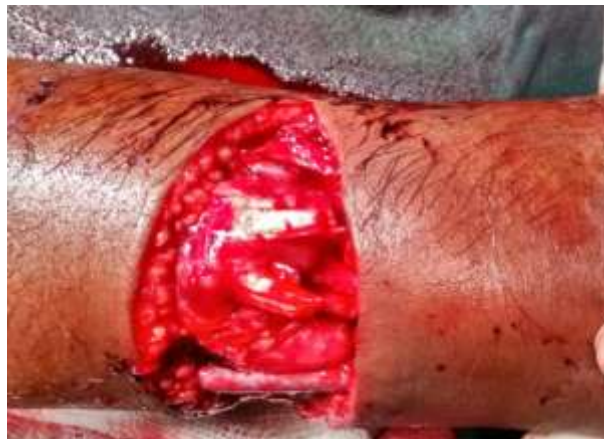Address: - Department of Vascular Surgery, Govt. Stanley Medical College, Chennai.

**Results:-**

Most of our patients were in the age group of 15 to 45 years (23 patients), 4 patients were more than 45 years and 5 patients were less than 14 years of age. There were 26 male patients (26/32=81%) and 6 female patients (6/32=19%). Road Traffic Accidents is the main mode of the injury in 21 patients (21/32=66%) followed by machinery injury in 5 patients (5/32=16%) and accidental fall (3/32=9%) and self inflicted injury (3/32=9%). The type of injury was blunt in 22 patients (22/32=69%) and penetrating in 10 patients (10/32=31%). 26 patients presented after 6 hours, (26/32=81%) and 6 patients presented within 6 hours (6/32=19%). Associated bony injuries were seen in 16 patients (16/32=50%), muscles and venous injuries were seen in all patients (100%), nerve injuries seen in 10 patients (10/32=31%) and skin loss in 7 patients (7/32=22%). Isolated brachial artery injury was seen in 22 patients (22/32=70%), combined brachial and radial artery injury was seen in 3 patients (3/32=10%), brachial and ulnar artery injury in 2 patients (2/32=7%) and radial and ulnar artery injury in 4 patients (4/32=13%).

Most of the patients were in younger age group with no comorbid diseases, only two patients whose age was 47 and 51 had Diabetes Mellitus. Our patients were evaluated by clinical examination (Hard and Soft signs)<sup>1</sup> and using Hand Held Doppler. Hand held Doppler was our main tool. We did CT angiogram in the patients with suspected multilevel injuries to the vessels. Using Hand held Doppler, no flow was seen in 5 patients (5/32=15%), wrist pressure less than 50 mmHg seen in 20 patients (20/32=63%) and wrist pressure more than 50 mmHg in 7 patients (7/32=22%).

Primary end to end anastomosis done in 4 patients when the defect was less than 2 centimeters (4/32=13%) In injuries with defect more than 2 cm defect Reversed Saphenous Vein was used as conduit. Synthetic grafts were not used to prevent infection<sup>2</sup>. Anatomical bypass was done in 25 patients (25/32=78%), and extra anatomical bypass in 3 patients in severely crushed limbs with contamination (3/32=9%)<sup>3</sup>.



**Fig. 1:-** Radial and Ulnar artery repair interposition reversed saphenous vein graft.

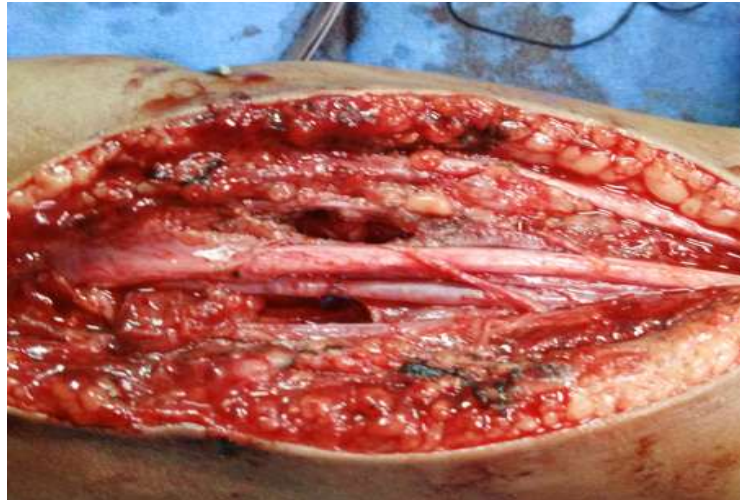


Fig.2

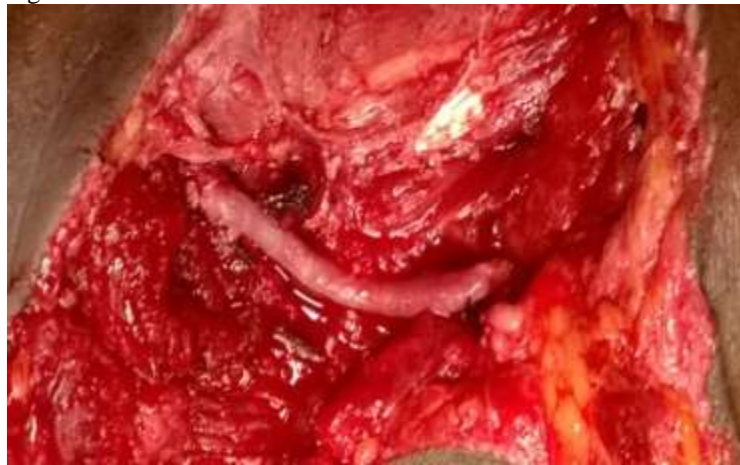

Fig. 3

Brachial artery repair figure 2 – end to end anastomosis, figure 3 interposition reversed saphenous vein graft

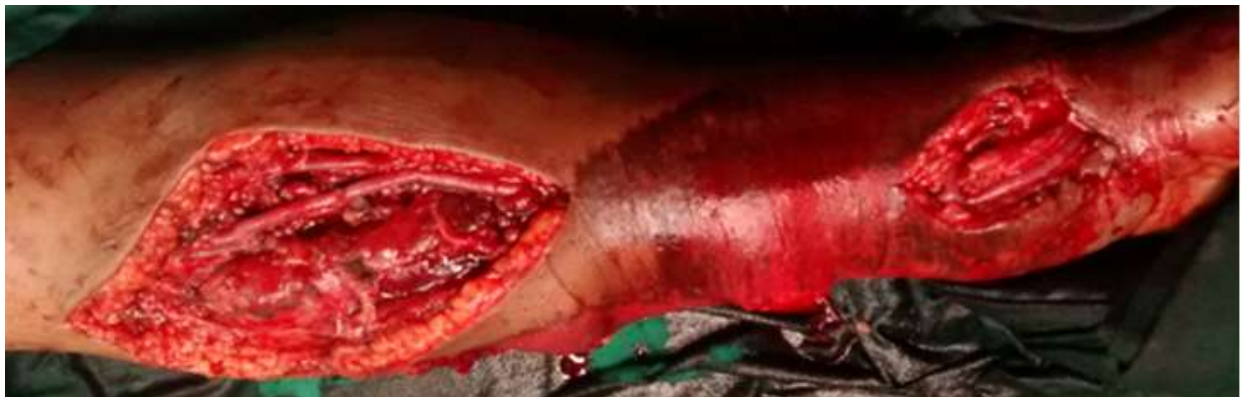

Fig. 4

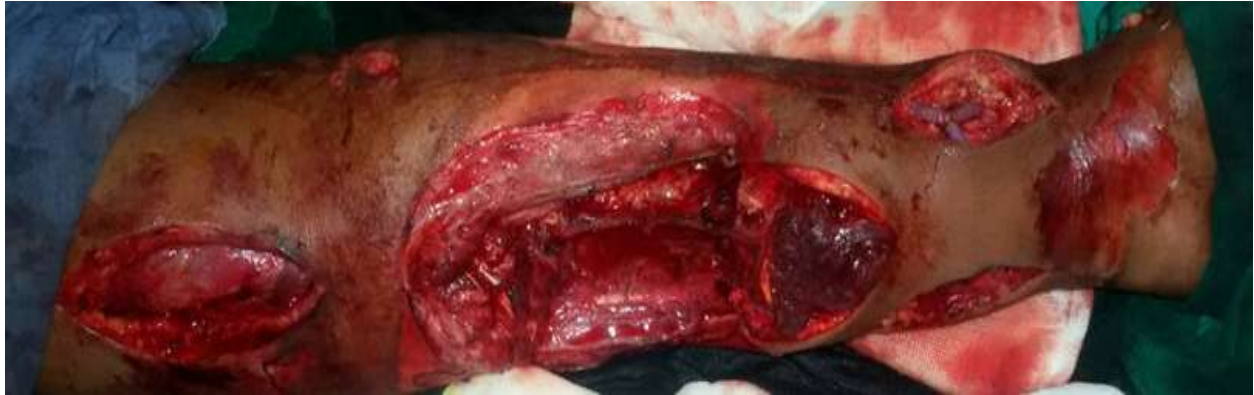

Fig.5  
Extra anatomical bypass figure 4 and figure 5.

We did fasciotomies in most of patients, for those who had no flow status and those who presented after 6 hours. We did skin cover by relaxing incisions and Split Skin Graft primarily or secondarily in 8 patients (8/32=25%).

Since the possibility of vascular injury could be missed in blunt injury, it may be the one of the reasons that most patients presented 6 hours after the injury.

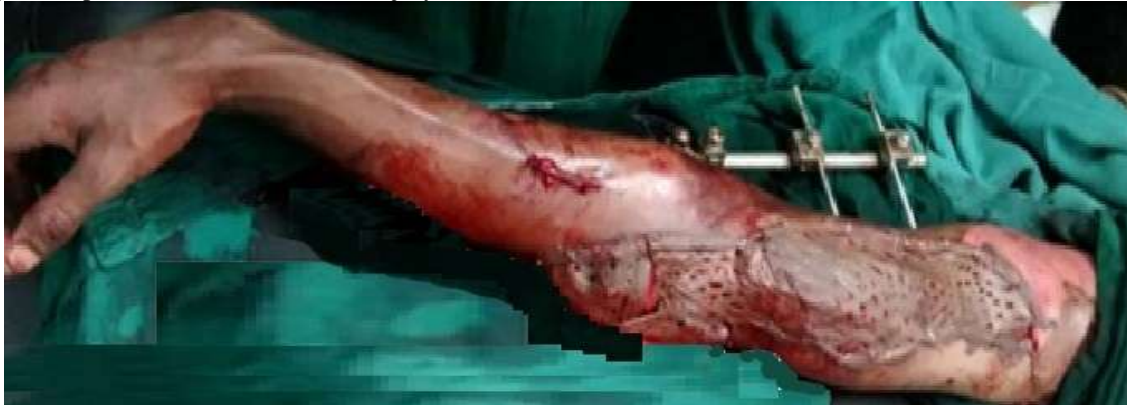

Fig.6

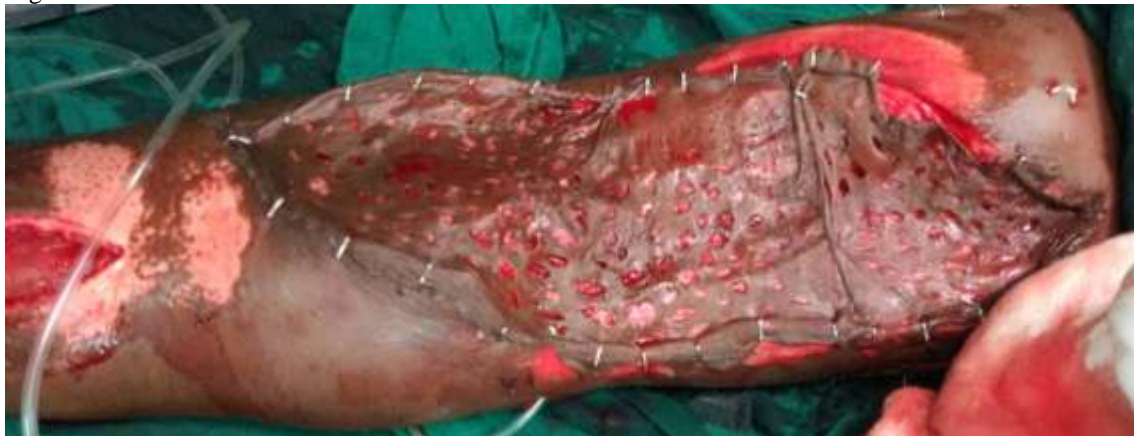

Fig. 7  
Skin cover figure 6 and figure 7.

**Discussion:-****Mode of injury:-**

Blunt injury occurred in (22/32) patients and penetrating injury in 10 patients. Road traffic Accident Occurred (21/32) patients it was the main mode of injury (table1), Followed by Machinery injures (5/32).

**Management:-**

All the patients were heparinised (80IU/kg – bolus followed by 18 IU/kg /hr).Broad spectrum antibiotics were given. We used Reversed Saphenous Vein Graft in 28 patients (figure2&3). All the Machinery injury occurred in male patients (100%).

Penetrating injury was associated with wound infection more commonly (5/6 cases). Blunt injury caused mainly contusion thrombosis. In penetrating injury irregular tears and transactions were common.

**Complication:-**

Complication occurred in (9/32) 28%. Wound infection is the most common incopcation (6/9). Penetrating injury was associated with wound infection due to contamination (5/18). 1 case of wound infection occurred in blunt injury (1/6). Graft thrombosis occurred in 2 patients (table3).

**Table 1:-Mode of injury**

Mode of injury	Male	Female	Total
RTA	18	3	21
Machinery injury	5	0	5
Fall	2	1	3
Self inflicted	1	2	3
<b>Total</b>	<b>26</b>	<b>6</b>	<b>32</b>

**Table 2:-Nature of Injury**

Nature of Injury	RTA	Machinery injury	Fall	Self inflicted	Total
Blunt injury	19	-	3	-	22
Penetrating injury	2	5	-	3	10
<b>Total</b>	<b>21</b>	<b>5</b>	<b>3</b>	<b>3</b>	<b>32</b>

**Table 3:-Complication N =32**

Graft thrombosis	2	6.25%
Wound infection	6	18.75%
Pseudoaneurysm	1	3.125%
<b>Total</b>	<b>9</b>	<b>28.12%</b>

Graft thrombosis occurred on (3rd & 4<sup>th</sup> day) in 2 patients (6.25%). Both the patients presented with severe crush injury. Of the 2 patients one was a chronic smoker and the other had Diabetic Mellitus).

Pseudoaneurysm and Blow out happened in one patient, brachial artery ligated on 5<sup>th</sup> post operative day, but the limb was salvaged.

There was (100%) limb salvage with no mortality.

**Table 4:-Study Comparison**

Author	Period	Centre	No. of patient	Blunt	Penetrating	Follow up	Limb salvage
Fitridge <sup>1</sup>	1994	Adelaide	114	46%	54%	14 months	86%
Wali <sup>2</sup>	1996-2001	Saudi arabia	27	-	-	-	96%
Van dersluis <sup>3</sup>	1997	Toronto	25	76%	24%	24 months	100%
Manor D <sup>4</sup>	1998	New orleans	46	39%	61%	43 months	98%

Brown <sup>5</sup>	2001	Milwaukee	71	30%	70%	6 months	94%
Toepel <sup>6</sup>	2009	Regensburg	33	30%	70%	42 months	98%
Klocker <sup>7</sup>	2010	Innsbruck	89	80%	20%	63 months	98%
Ours	2017	Chennai	32	69%	31%	10 months	100%

Most of our patients presented more than 6 hrs after the injury. Arterial repair done first, followed by fracture stabilisation and nerve repair

Our patients were evaluated by clinical examination (Hard and Soft signs) and Hand Held Doppler. Hand held Doppler was our main tool. We did CT angiogram in patients with suspected multilevel injuries. We have ligated the veins in cases with venous injury<sup>4</sup>, we didn't affect limb salvage. We did faciotomy – in majority of cases (> 6 hr, associated venous injury). If both radial and ulnar arteries were injured we repaired both, because palmar arch integrity couldn't be assessed pre operatively. If one artery (either radial or ulnar) is injured and palmar arch is intact, we ligated the injured vessel, and if palmar arch is incomplete we repaired the injured artery<sup>5</sup>. Though graft thrombosis was seen in 2 patients, limbs were salvaged – (younger age, > 3-5 days, injury beyond profunda brachii) Since most of the injuries occurred were distal to profunda brachii, lean muscle mass of upper limb compared to lower limb,(decreased oxygen demand ) and very good collaterals around elbow joint, the limb salvage rates were high in upper limb vascular trauma.

Our limb salvage rate is comparable or even better than other studies.

### Conclusion:-

Since upper limb vascular trauma commonly occurs in young individuals timely intervention in upper limb vascular injuries can save the limb and the life. This means they can be economically productive and lead an independent quality life.

### References:-

1. Rich's Vascular Trauma 3<sup>rd</sup> edition.
2. Haimovici's Vascular Surgery, 6<sup>th</sup> edition
3. Hallet's Comprehensive Vascular And Endovascular Surgery, 2<sup>nd</sup> Edition.
4. Rutherford's Vascular Surgery, Volume-2, 8<sup>th</sup> Edition.
5. Wesley S.Moore's Vascular And Endovascular Surgery, 8<sup>th</sup> Edition
6. Journal References:
7. Upper Limb Arterial Injuries – Experience At Royal Adelaide Hospital,Robert A.Fitridge Et Al,J.Of Vascular Surgery 1994;20;941-46
8. Upper Limb Vascular Trauma In The Asir Region Of Saudi Arabia,Wali Ma,Annals Of Thoracic Cardiovascular Surgery(2008 Oct 8(5) 298-301
9. Long-Term Outcomes After Upper Limb Arterial Injuries,Wander Sluis Ck,Et Al Canadian Journal Of Surgery 1997 August; 40(4) 265-70
10. Management Of Severe Proximal Vascular And Neural Injury Of The Upper Extremity, Jeffery D.Manord Md, Et Al Journal Of Vascular Surgery, Volume 27 Issue 1,January 1998 Pages 43-49
11. Determinates Of Functional Disability After Complex Upper Extremity Trauma,Brown Kr Et Al,Annals Of Vascular Surgery,2001 January ;15(1) 43-48
12. Clinical Outcome And Quality Of Life After Upper Extremity Arterial Trauma,Topel L Et Al,Annals Of Vascular Surgery,May-June;23(3)317-23
13. Repair of Arterial Injury After Blunt Trauma In The Upper Extremity - Immediate And Long-Term Outcome. Klocker J, Et Al. Eur J Vasc Endovasc Surg. 2010.