



RESEARCH ARTICLE

INCISIONS AND TISSUE MANAGEMENT IN PERIODONTAL SURGERY: A REVALUATION.

Dr. Aamir Shamas Malik, Dr. Syeda Tawkhira Tabasum, Dr. Gaurav Kumar Mittal and Dr. Sorav Gupta.

Manuscript Info

Manuscript History

Received: 10 August 2018

Final Accepted: 12 September 2018

Published: October 2018

Abstract

Periodontal surgery is an essential part of modern periodontal therapy. Selection of the appropriate incision technique is one of the main preconditions for a complication-free healing process involving minimum esthetic impairment. This applies not only to periodontal surgery but also to oral surgery and implant surgery. The different surgical incision techniques are described in detail from this aspect. Instructions on tissue management aimed at minimum traumatization are discussed from macrosurgical and microsurgical points of view. The crucial factors here include inflammation-free tissue, maximum exsanguination, sharp surgical instruments, atraumatic, non-contaminable suture material, and the shortest possible duration of surgery.

Copy Right, IJAR, 2018,. All rights reserved.

Introduction:-

Any surgical intervention starts with the incision, which, once performed, can be altered only partially, if at all. The following points must therefore be observed as essential preconditions for selection of the appropriate incision technique:

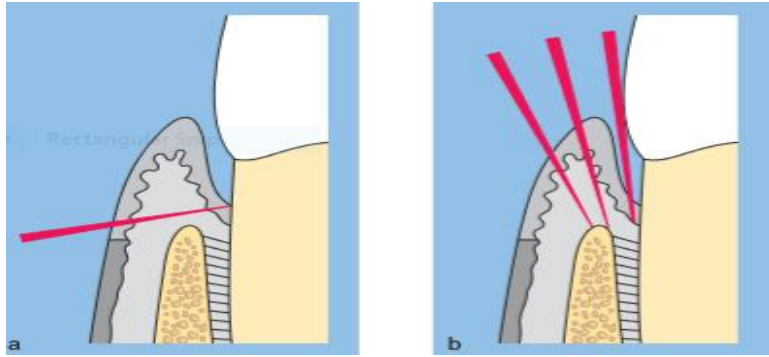
1. precise knowledge of the osseous topography
2. securing an adequate blood supply to the flap
3. adequate overview of the surgical site
4. maximum protection of adjacent anatomic structures
5. possibility of adapting the incision in the event of unforeseen findings
6. wound closure on underlying bone.

Non-fulfillment or only partial fulfillment of these preconditions may result in impaired wound healing, jeopardizing the surgical objective. In the worst-case scenario, the outcome may be legal disputes, e.g., in the event of injured nerves or substantial esthetic impairment (Erpenstein 2004, 1995). A focal distinction can be made between interventions in the fields of periodontal surgery, oral surgery, and implant surgery. The numerous special incisions developed for these specializations must always also take the periodontal structures into account.³

Incisions for periodontal surgery

Horizontal incisions

Horizontal incisions serve to detach the soft tissue from the root surface, with a distinction being made between an external (coronally directed) and an internal (apically directed) incision. In the external version, an obtuse angle is formed between the tooth crown and the scalpel. This is the typical type of incision for a gingivectomy.

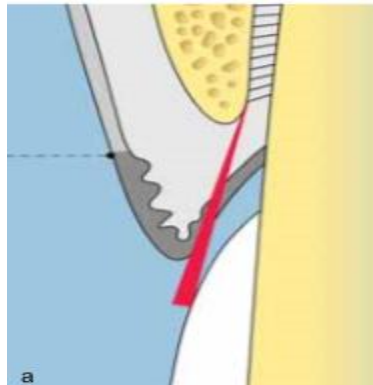


(Figure 1 and 2)

It invariably entails a very great loss of tissue and has therefore been almost completely abandoned, except in cases of gingival hyperplasia. In the internal version, the typical incision for flap surgery, an acute angle is formed between the tooth crown and the scalpel. The location of the horizontal incision, i.e., the distance from the gingival margin, depends on the pocket depth, the width of the keratinized gingiva, and the desired postoperative position of the flap margin. It can accordingly be executed as a sulcular, marginal, or paramarginal incision.¹

Sulcular incision

This is the simplest type of incision. The scalpel is introduced into the sulcus or the pocket and inserted as far as possible into the interdental space around the tooth, keeping close to the crown. The deepest point of the incision is on the alveolar crest. This incision incurs the least loss of soft tissue. Pocket epithelium and granulation tissue are partially retained but may undergo controlled removal with surgical scissors and scalpel from the inner surface of the flap after flap mobilization.²



(Figure 3)

The indications are as follows:

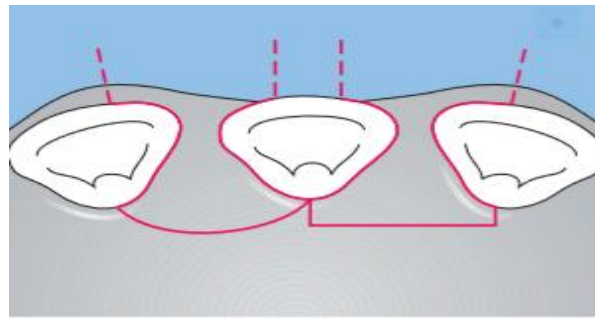
1. access flap
2. access surgery for GTR
3. narrow keratinized gingiva ≤ 3 mm
4. esthetically relevant areas.

With this incision, the flap is generally repositioned to its presurgical level and fixed with interrupted interdental sutures or vertical mattress sutures.

Parapapillary incision (line angle to line angle)

The aim of the parapapillary incision and its variants is to retain the interdental gingiva. Unlike the sulcular incision, where the interdental gingiva is severed, the parapapillary version takes the incision not into the interdental space but past it to the next tooth (line angle to line angle).^{4,5,7}

The interdental gingiva is thus completely retained. This incision is indicated if treatment can be confined to the oral or to the buccal surfaces (e.g., to cover a recession), or if the interdental gingiva has to be retained, for example, to cover a membrane, as is the case with the modified papilla preservation flap (Cortellini 1995, 1998).



(Figure 4)

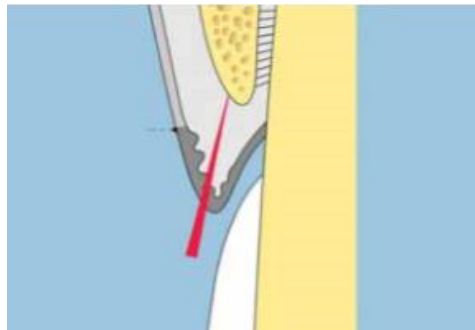
The earliest form of incision preserving the interdental gingiva is the papilla preservation flap, introduced in 1985 by Takei et al.

This involves a flap that is formed between two teeth, with the interdental gingiva being retained by moving the incision to the oral aspect rather than severing the interdental gingival.

An adequately wide interdental space of at least 3 mm at bone level and an inflammation-free interdental gingiva are indispensable if the narrow interdental gingiva is not to be damaged during preparation.

Marginal incision

This incision is made on the top of the gingival margin. The scalpel is guided at an acute angle to the tooth crown, though without following it. The deepest point of the incision should be on the alveolar crest.



(Figure 5)

The marginal incision is extremely difficult to perform, firstly because the scalpel has no guidance at the tooth surface and secondly because it repeatedly slips down into the pocket because of the close proximity to the tooth. This incision will not be successful unless the gingival margin is very thick. Although it can be used to remove pocket epithelium and granulation tissue, it is very rarely indicated.

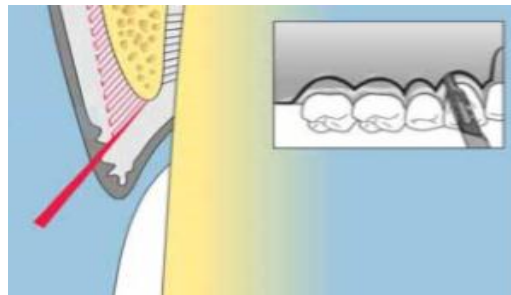
Paramarginal incision

For this incision, the scalpel is moved at an acute angle to the surface of the crown without touching it.

The distance from the gingival margin is approximately half the pocket depth measured there. If this incision is used on the palatal side, the shape of the palate also plays a role, in that the distance from the gingival margin may increase to as much as two thirds of the pocket depth with increasing steepness.

In all events, an adequately wide band of gingiva (≥ 3 mm) must remain on the buccal side.

The incision should be more scalloped than the gingival margin itself. Interdentally, the incision ends at the entrance to the interproximal space in a point that must, after suturing, be located exactly in the interproximal space as a new “interdental papilla”.



(Figure 6)

The paramarginal incision is always supplemented by a sulcular incision that permits largely atraumatic removal of the “gingival collar”. If the paramarginal incision is intended to lengthen the crown rather than eliminate or reduce the pocket, the distance between the incision and the gingival margin is based either on the crown length required for retention or on esthetic aspects, such as the course of the gingiva on the adjacent teeth or the highest point of the gingival margin on the maxillary canines.^{9,10}

One special form of paramarginal incision is the so-called crescent incision.

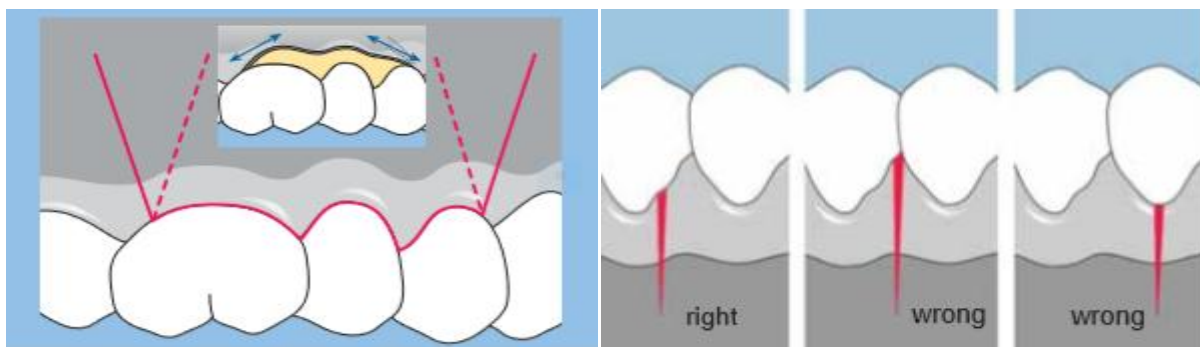
This is used when crown lengthening is confined to the buccal crown surface and the interdental gingiva is to be spared.

A paramarginal incision is indicated for pockets ≥ 5 mm in esthetically irrelevant areas and for crown lengthening. It is contraindicated in cases where the width of the gingiva would be reduced to less than 3 mm.

Vertical incisions

Vertical incisions are also referred to as releasing incisions. They offer increased flap mobility and thus a better overview of the surgically involved area. They are absolutely essential if the flap must be moved into another than the presurgical position, e.g., in a coronal, apical, or lateral direction^{5,6}

They unilaterally or bilaterally outline the area to be operated upon and run at right angles or at an obtuse angle to the horizontal incision. In ideal cases, the flap base is slightly wider than the flap margin to ensure that the blood supply to the flap is maintained, in spite of the supply through the lateral vessels being interrupted.



(Figure 7 and 8)

However, as this relationship cannot be fully observed in lateral displacements which are used, for example, for covering recessions - the blood supply to the flap is at some risk. If vertical incisions are not performed, tension and even tearing may occur upon mobilization of the flap at the end of horizontal incisions.

If it is necessary to forego vertical incisions for anatomic reasons (e.g., to prevent traumatization of the mental nerve), the horizontal incision must be extended far beyond the actual surgical site.

A further contraindication is found in the palatal region of the maxillary second molars due to the presence of the branches of the palatine artery and palatine vein.^{4,1}

Vertical incisions should be made at the angles of the teeth. Experience shows that dehiscences of the suture are more likely when vertical incisions are made in the middle of the papilla or on the facial surface of the root.

Incisions for oral surgery

Among the many incisions indicated in oral surgery, sulcular incisions in esthetically relevant regions are of special periodontal significance, as they often entail a partial loss of the interdental gingiva. Even today, however, sulcular incisions including the interdental gingiva are still recommended, for example, for apicectomies or for surgical tooth extraction in the incisor region (Nentwig 2003; Sailer 1996; Ziegler 2002).

Conventional marginal gingival incisions can be replaced by a papilla-preserving incision without any loss of overview, e.g., for an apicectomy (Erpenstein 2002, 2004).^{7,8,9}

In this case, the horizontal sulcular incision is confined to the buccal surface of the affected tooth with maximum conservation of interproximal tissue. The bilateral vertical incisions are made on the line angles of the teeth, so that the apical process can be shown clearly and suturing can be performed on underlying bone.

If treatment is required on a number of adjacent teeth, the horizontal incision is made as a parapapillary incision (line angle to line angle) to preserve the interdental gingiva. The bilateral vertical incisions are located on the line angle of the affected teeth.

Incisions for implant surgery

From a periodontal viewpoint, the protection of the approximal gingiva of the teeth adjacent to the space and the retention of the gingiva are of significance in implant surgery. The protection of the approximal gingiva is desirable especially in single tooth implants in esthetically relevant regions.

In addition to this consideration, it is the available space that determines the type of incision. In the case of a single tooth implant, the horizontal incision is made from palatal-paracrestally, subject to sufficient space being available. From there the incision runs bilaterally to the buccal, preventing the approximal gingiva of the adjacent teeth.

The vertical incisions run on divergent arcs in the vestibulum. If the space is too narrow, a sulcular incision is made at the approximal surfaces of the adjacent teeth on either side of the paracrestal horizontal incision. This procedure offers maximum protection to the mucosa on the alveolar process, ensuring complete, tension-free coverage of the implant undergoing submucosal osseointegration.^{2,3,4}

A lack of keratinized gingiva is most frequently observed in the buccal region of the mandible. For this reason, the paracrestal lingual incision lends itself to surgery in this region as well; it is extended into the vestibulum, preserving the approximal gingiva of the teeth on either side of the space. For implant coverage – where applicable using a membrane and autogenous bone for augmentation – the mucoperiosteal flap is repositioned to its presurgical position and sutured there.

The same incision is selected for second-stage surgery. However, the flap is not repositioned in this case, but is moved to the buccal side in front of the implants with the aim of augmenting the buccal gingiva in width and thickness.

Tissue management

Fulfillment of the objective of undisturbed wound healing depends on factors from different areas, which together constitute what is known as tissue management. The most important precondition is that the surgical intervention is performed in clinically noninflamed tissue. In periodontal surgery in particular, this can be achieved only through a consistently executed hygiene phase requiring an appropriate infrastructure in terms of personnel and instrumentarium.

During surgery, sufficiently deep anesthesia and maximum exsanguination (where applicable, with an epinephrine additive (vasoconstrictor) 1:50,000, e.g., Xylonor 2% Special) are important for reasons of transparency and precision.

The use of magnifying eyeglasses with four- to sixfold magnification and centered cold lighting is mandatory as an aid to identifying very fine structures. One practical option is the use of a surgical microscope. Only sharp instruments should be used, i.e., scalpels should be replaced after bone contact and burs possibly sterilized twice. Using retraction sutures instead of surgical hooks at the contralateral cheek or teeth for reflection of the flap margins is recommended, especially during more extensive surgical interventions. Osteoplasty and ostectomy are performed with burs, with minimum pressure being applied and adequate cooling provided.^{10,11}

In regions close to roots, hand instruments (e.g., Ochsenbein file, Schluger file) should be used to protect the root surface. The objective of wound closure is tension-free suturing on underlying bone, using atraumatic and minimally contaminable monofil material (De Nardo 1996; Karutz 2001; Katz 1981; Selvig 1998, Shuhaiber 1989). The thickness of the suture and needle must be adapted to the tissue structure (e.g., palatal mucosa 4-0/5-0, transplants and interdental gingiva 6-0/7-0).^{5,6}

Surgery should be performed in the shortest possible time; this essentially depends on the operator's skills, the support of trained assistants, and the preparation of the patient (inflammation-free tissue). Postoperatively, a periodontal dressing (e.g., Coe Pak, Barricaid) securely anchored in the interdental spaces may help to stabilize the wound region, i.e., the blood and fibrin clot.

If the surgical team follows these guide lines, wound healing in the oral cavity can normally be expected to be complication-free. In addition, postoperative symptoms such as swelling and pain can be reduced. The term "microsurgery" was originally associated with the use of a surgical microscope (Shanelec, 2000).

Today, it is also applied with reference to the use of strongly magnifying eyeglasses; however, no generally binding definition of the term "microsurgery" has been formulated to date. Fundamentally, microsurgery is macrosurgery in smaller dimensions. Suturing techniques as well as suture materials are the same as in macrosurgery. The difference is in the thickness of the suture materials (8-0 to 10-0) and the smaller instruments. Potential advantages of microsurgery are:

1. more efficient scaling
2. more exact positioning of the wound margins
3. greater suturing precision
4. less severe postoperative symptoms (swelling, pain)
5. more relaxed posture of the surgeon.

However, as no controlled studies of microsurgical vs. macrosurgical procedures have been published to date, the microsurgical procedure can currently be evaluated only by comparing reports in the literature.^{2,3}

In a study on the effect of enamel matrix derivative in the treatment of intrabony defects through flap surgery, a clinical attachment gain of 1.7 ± 1.4 mm was achieved with 5.2 times magnification in the control group without enamel matrix derivative (Wachtel, 2003). However, such an attachment gain is also generally achieved through flap surgery with macrosurgical procedures (Cortellini 1998; Stavropoulos 2003).

At least with respect to this criterion, no advantage of the microsurgical over the macrosurgical procedure is to be seen at the present time. Controlled studies with the purpose of investigating and verifying the empirically proven, obvious advantage of microsurgery (also with respect to other criteria and other surgical techniques) are warranted.

References:-

1. Cortellini P, Carnevale G, Sanz M, Tonetti MS: Treatment of deep and shallow intrabony defects. A multicenter randomized controlled clinical trial. *J Clin Periodontol* 1998; 25: 981.
2. DeNardo GA, Brown NO, Trenka-Benthin S, Mareta SM: Comparison of seven different suture materials in the feline oral cavity. *J Am Anim Hosp Assoc* 1996; 32: 164.
3. Erpenstein H: Ästhetik in der Parodontologie. *Dtsch Zahnärztl Z* 1995; 50: 181.
4. Erpenstein H: Diskussionsbemerkung zur Arbeit Ziegler et al.: Untersuchung der marginalen Schnittführung bei Wurzelspitzenresektionen. *Dtsch Zahnärztl Z* 2002; 57: 373.
5. Erpenstein H, Borchard R, Diedrich P: Chirurgische Grundlagen. In: Erpenstein H, Diedrich P (Hrsg.): *Atlas der Parodontalchirurgie*. Elsevier Urban and Fischer 2004.
6. Karutz J, Briedigkeit H, Gobel UB, Radlanski RJ, Kleber BM: Klinische und mikrobiologische Untersuchung zur Eignung verschiedener Nahtmaterialien in der Parodontalchirurgie. *Dtsch Zahnärztl Z* 2001; 56: 653.
7. Katz S, Izhar M, Mirelman D: Bacterial adherence to surgical sutures. A possible factor in suture induced infection. *Ann Surg* 1981; 194: 35.
8. Nentwig GH: Wurzelspitzenresektion. In: Horch HH (Hrsg.): *Zahnärztliche Chirurgie*. Urban & Fischer 2003.
9. Sailer F, Pajarola GF: *Farbatlanten der Zahnmedizin*. 11. Orale Chirurgie. Thieme, Stuttgart – New York 1996.
10. Selvig KA, Biagiotti GR, Leknes KN, Wikesjö UME: Oral tissue reactions to suture materials. *Int J Periodontics Restorative Dent* 1998; 18: 475.
11. Shuhaiber H, Chugh T, Burns G: In vitro adherence of bacteria to sutures in cardiac surgery. *J Cardiovasc Surg* 1989; 30: 749.