



ISSN NO. 2320-5407

Journal Homepage: -[www.journalijar.com](http://www.journalijar.com)

## INTERNATIONAL JOURNAL OF ADVANCED RESEARCH (IJAR)

Article DOI:10.21474/IJAR01/ 9233  
DOI URL: <http://dx.doi.org/10.21474/IJAR01/9233>



INTERNATIONAL JOURNAL OF  
ADVANCED RESEARCH (IJAR)  
ISSN 2320-5407  
Journal Homepage: <http://www.journalijar.com>  
Journal DOI:10.21474/IJAR01

### RESEARCH ARTICLE

#### MAJOR PREDICTORS OF LATE MANDIBULAR FRACTURE IN THIRD MOLAR EXODONTIA: A REVIEW.

**Albuquerque Barros<sup>1,2</sup>, Júlio Leal Villela Garcia<sup>1,2</sup>, Luciana Fortes Tosto Dias<sup>1,2</sup>, Diego César Marques<sup>1,2</sup>, Lucas Antônio de Carvalho e Silva<sup>1,2</sup>, Regis Manzini<sup>2</sup>, Andrés Santiago Quizhpi López<sup>2</sup>, André Gunther Lima<sup>1,2</sup>, Igor Mariotto Beneti<sup>1,2</sup>, Rogério Luiz de Araújo Vian<sup>2,3</sup>, Elias Naim Kassis<sup>1,2</sup>.**

1. Unorp - University Center North Paulista - São José do Rio Preto – SP, Brazil.
2. Unipos - Post graduate and continuing education, Street Ipiranga, 3460, São José do Rio Preto SP, Brazil 15020-040.
3. Santa Casa Hospital-Bucomaxillo Facial Traumatology Center- Ribeirão Preto/SP, Brazil.

#### Manuscript Info

##### Manuscript History

Received: 08 April 2019

Final Accepted: 10 May 2019

Published: June 2019

##### Key words:-

Late mandibular fracture. Exodontia.  
Third molar. Surgery. Conventional treatment.

#### Abstract

**Introduction:** The third molar extraction procedure presents a high surgical incidence by the maxillofacial surgeon. In this context, epidemiological data reveal that the incidence of late fracture can vary from an average of 6.5 cases in 1,000.

**Objective:** To present, through a literary review, the main predictors of late mandibular fracture in third molar extraction, in order to contribute important prophylaxis and treatment information to the dental literature.

**Methods:** A total of 34 articles were found. So, 17 articles were included and discussed in this study. Experimental and clinical studies were included (case reports, retrospective, prospective, randomized trials and systematic review and meta-analysis) with qualitative and/or quantitative analysis.

**Results and conclusion:** Late fracture occurs in the first two weeks of the surgical procedure. Some authors reported occurrence within the first four weeks. However, it is more common that the fractures occur in the fifth postoperative week. Chewing presented the highest incidence and prevalence of mandibular fracture cause after third molar extraction, reported by the authors. The present study showed the importance of identifying the main predictors of late fracture in the pre- and postoperative period, orienting the patient in the postoperative period regarding the diet for a prolonged period as a form of prevention. It has also been demonstrated that the best form of treatment of the late fracture is surgical, but in cases of comorbidity conservative treatment can be performed.

*Copy Right, IJAR, 2019., All rights reserved.*

#### Introduction:-

The procedure for the extraction of third molars presents a high surgical incidence by the buccomaxillofacial surgeon [1]. This procedure can cause complications such as jaw fracture. This is associated with third molar

**Corresponding Author:- Arthur Albuquerque Barros.**

Address:-Unorp - University Center North Paulista - São José do Rio Preto – SP, Brazil.

extraction is a rare complication that may occur in the trans or postoperative period. When it occurs in the postoperative period, it is considered a late fracture [1,2].

In this context, epidemiological data reveal that the incidence of late fracture can vary from an average of 6.5 cases in 1,000 [3]. This problem may occur after two weeks of surgery and during chewing. Thus, the fracture presents a simple trait with a little displacement of the bone segments and is located in the region of the mandibular angle, which is an area of low fracture resistance due to its finer sectional area 4.

In this sense, it is possible to establish the main predictors that provoke or increase the risk of mandible fracture after third molar extraction, highlighting the age, gender, degree of impaction, angulation and volume of the dental element, presence of tumors, cysts or lesions osseous associated with the dental element and systemic diseases [5]. Patients older than 40 years of age have an increased risk of fracture due to decreased bone elasticity and hypercementosis of the impacted tooth, which leads to a greater osteotomy for exodontia [5].

Regarding gender, men tend to have greater strength during chewing in relation to women, presenting a greater risk of mandible fracture. In patients with total dentin, the risk is even higher [6]. The degree of impaction, angulation, and volume of the third molar are also important factors. The greater the impaction and angulation of the dental element, the greater the osteotomy necessary for the exodontia. Position III C teeth, according to the classification of Pell and Gregory, that is, located completely inside the mandibular branch and with occlusal surfaces below the cervical line of the second molar, and distoangulated teeth, according to the classification of Winter, have a higher risk of fracture since both require greater osteotomy [7].

In addition, preexisting bone lesions such as cysts, tumors or recurrent pericoronitis may weaken the mandible and are also important predictors [8]. Systemic diseases such as osteoporosis, significantly decrease bone density, are also another important factor. Fracture diagnosis is performed by means of imaging tests, such as panoramic radiography and presence of signs and symptoms such as pain on movement, bone crepitation, edema and ecchymosis, occlusal alteration, jaw mobility and local bleeding [9]. In some cases, it is difficult to verify the trait of the fracture only by the panoramic radiograph, being used the computed tomography to confirm the diagnosis [9].

Added to this, the report of the popping noise perceived by the patient is often the first sign of mandibular fracture after third molar exodontia, with pain and increased volume [10]. The treatment of mandibular fracture after third molar extraction is the same in cases of mandible fracture due to trauma and follows the basic principle of reduction and fixation, restoring the mandibular contour, dental occlusion and temporomandibular function [10].

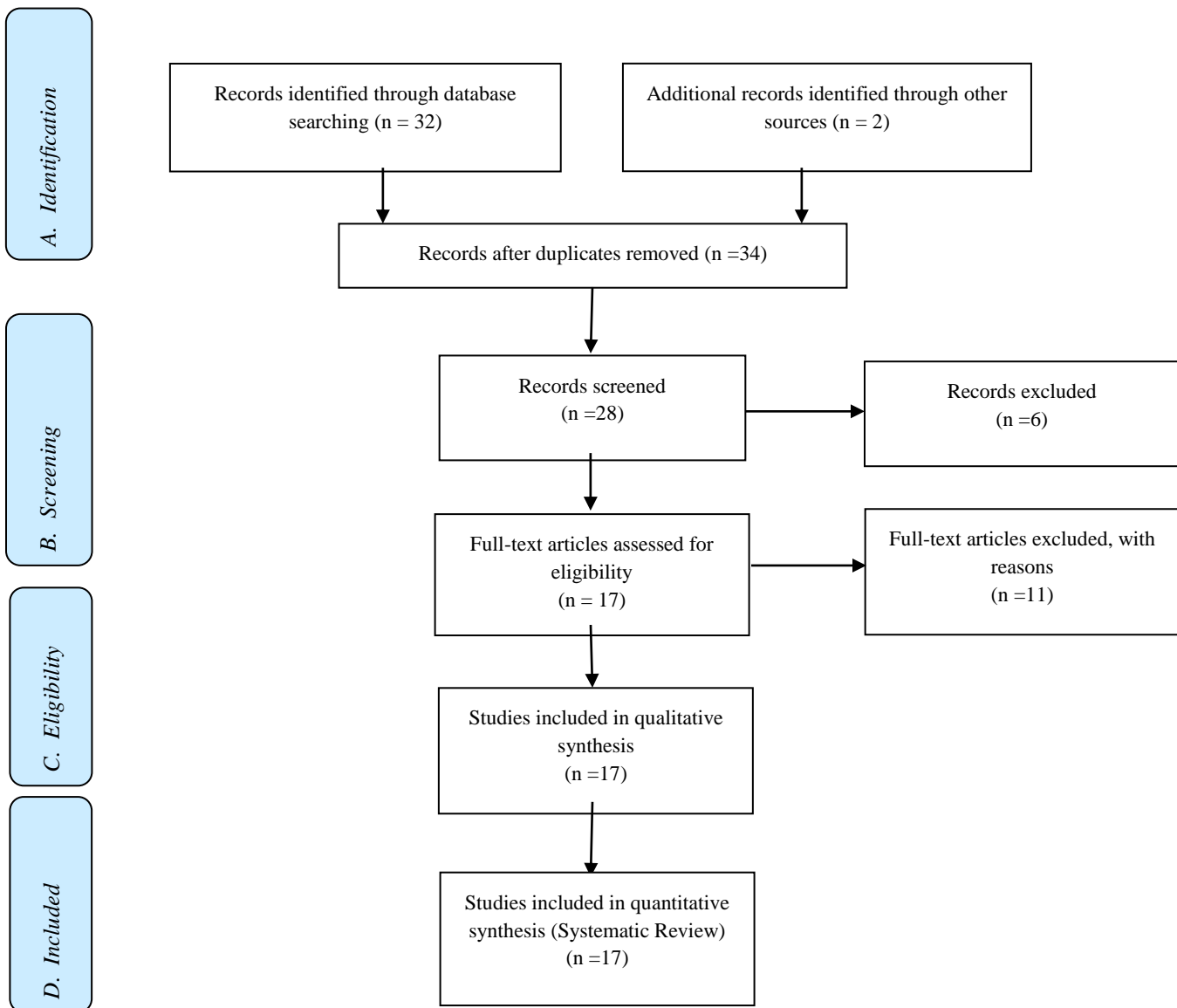
Therefore, the present work aimed to present, through a literary review, the main predictors of late mandibular fracture in third molar extraction, in order to contribute important prophylaxis and treatment information to the dental literature.

## **Methods:-**

### **Eligibility and Study Design**

A total of 34 articles were found involving Late mandibular fracture. Exodontia. Third molar. Surgery. Conventional treatment. Initially, it was held the exclusion existing title and duplications following the interest described this work. After this process, the summaries were evaluated, and a new exclusion was held. So, 17 articles were included and discussed in this study.

Experimental and clinical studies were included (case reports, retrospective, prospective, randomized trials and systematic review and meta-analysis) with qualitative and/or quantitative analysis. Initially, the keywords were determined by searching the DeCS tool (Descriptors in Health Sciences, BIREME base) and later verified and validated by MeSh system (Medical Subject Headings, the US National Library of Medicine) in order to achieve consistent search.

**Flow Chart****Literature Review and Discussion:-**

The late fracture occurs in the first two weeks of the surgical procedure. Some authors have reported an occurrence in the first four weeks [1]. However, fractures are more common in the fifth postoperative week [1]. Chewing presented the highest incidence and prevalence of mandibular fracture cause after third molar extraction, reported by the authors. It is important to guide the patient who presents the risk factors for fracture in relation to diet [1-5].

In addition, in cases requiring extensive vestibular osteotomy, low bone mass in the mandibular basal portion, lingual teeth, and presence of associated osteolytic lesions, it is recommended to maintain a pasty diet for an extended period of time ranging from three to four weeks, according to the literature [ 6-8].

There are still no reports of late mandibular fracture after third molar extraction in the literature with Stafne bone cyst, with the most frequent lesions being dentigerous and radicular cyst 9,10. In other studies, half of the fractures occurred had associated cystic lesions, and most of the cases analyzed by Grau-Manclús (2011) were related to cysts or pericoronal capillary thickening of impacted third molars [11]. However, the longer the time of impacting the tooth, the greater the risk of developing cysts. In addition, over time there is greater retention of the dental element, decrease in bone density, contributing to the increase of the mandibular fragility and the risk of fracture [12-14].

In this context, exodontia is indicated in patients under 25 years of age, since after that age the incidence of complications is higher [15]. Conservative treatment or surgical treatment is indicated for treating mandibular fracture [16]. However, with the advent of rigid internal fixation techniques, the surgical treatment of the fracture through the use of plaques has been the treatment of choice and is superior to the conservative, since it provides a more stable reduction. The conservative treatment consists in the accomplishment of several techniques described by Ivy, Gilmer, and use of Erich bar and is maintained for 45 days. Skeletal blockade can also be performed through the use of screws and is indicated in cases in which the patient presents comorbidity [16].

A recent study reported a case of late mandibular fracture due to the extraction of third molars and highlights the clinical, ethical and legal aspects inherent to this surgical complication. The female patient underwent a surgical procedure to extract the third right lower third molar. Two days after surgery, the patient reported pain and altered the occlusion on the right side of the mandible [1]. After the clinical and radiographic reexamination, the diagnosis of late mandibular fracture was established. A second surgery, under general anesthesia, was performed to fix the mandibular bone. The fractured parts were reduced and secured with locking plate systems and 2mm bolts following the principles of load sharing. The masticatory function presented an optimal performance at 7 and 21 days after surgery. Complete bone healing was observed within 1 year of follow-up. Thus, surgical planning and appropriate techniques should be performed [1].

Still another study presented the predictors associated with the diagnosis, etiology, and treatment of mandibular fractures that occur during the postoperative period, after the removal of a lower third molar. This study evaluated 124 patients, involving the predictors of sex, age, position and dental angulation, bone impaction, relationship between the tooth and inferior alveolar nerve, local pathological conditions, fracture etiology, symptomatology and time between surgery and fracture, as well as any fracture displacement and fracture treatment were evaluated [17]. As a result, male patients aged > 35 years, with teeth in positions II/III and B/C, complete bone impingement and local bone-like alterations, presented a higher frequency of fracture and pericoronaritis ( $p < 0.05$ ). Late fractures usually occurred between the second and fourth postoperative weeks ( $p < 0.05$ ). They were generally not displaced and the typical treatment was the non-surgical approach ( $p < 0.05$ ). Therefore, the risk of mandibular fracture after extraction is associated with excessive osteotomy and/or local changes [17].

### **Conclusion:-**

The present study showed the importance of identifying the main predictors of late fracture in the pre- and postoperative period, orienting the patient in the postoperative period regarding the diet for a prolonged period as a form of prevention. It has also been demonstrated that the best form of treatment of the late fracture is surgical, but in cases of comorbidity conservative treatment can be performed.

### **Conflict of interests**

There is no conflict of interest between authors.

### **References:-**

1. Dos Santos Silva W, Silveira RJ, de Araujo Andrade MGB, Franco A, Silva RF. Is The Late Mandibular Fracture From Third Molar Extraction a Risk Towards Malpractice? Case Report with the Analysis of Ethical and Legal Aspects. J Oral Maxillofac Res. 2017 Jun 30;8(2):e5. doi: 10.5037/jomr.2017.8205. eCollection 2017 Apr-Jun.

2. Fratura tardia de mandíbula decorrente de exodontia de terceiro molar: relato de caso Late mandibular fracture after third molar extraction: case report. *Rev. Assoc. Paul. Cir. Dent.* [periódico na Internet]. 2012 Dez [citado 2019 Abr 30] ; 66( 4 ): 268-271. Disponível em: [http://revodontobvsalud.org/scielo.php?script=sci\\_arttext&pid=S0004-52762012000400004&lng=pt](http://revodontobvsalud.org/scielo.php?script=sci_arttext&pid=S0004-52762012000400004&lng=pt).
3. Lee CT, Zhang S, Leung YY, Li SK, Tsang CC, Chu CH. Patients' satisfaction and prevalence of complications on surgical extraction of third molar. *Patient Prefer Adherence*. 2015 Feb 10;9:257-63.
4. Sigron GR, Pourmand PP, Mache B, Stadlinger B, Locher MC. The most common complications after wisdom-tooth removal: part 1: a retrospective study of 1,199 cases in the mandible. *Swiss Dent J*. 2014;124(10):1042-6, 1052-6. English, German.
5. Bianchi B, Varazzani A, Ferri A, Menozzi R, Sesenna E. Endovascular embolization for the management of inferior alveolar artery bleeding after a third molar extraction: A case report. *Quintessence Int*. 2016 Mar;47(3):227-31.
6. Silveira RJ, Garcia RR, Botelho TL, Franco A, Silva RF. Accidental displacement of third molar into the sublingual space: a case report. *J Oral Maxillofac Res*. 2014 Oct 1;5(3):e5.
7. Bodner L, Brennan PA, McLeod NM. Characteristics of iatrogenic mandibular fractures associated with tooth removal: review and analysis of 189 cases. *Br J Oral Maxillofac Surg*. 2011 Oct;49(7):567-72.
8. Sarikov R, Juodzbals G. Inferior alveolar nerve injury after mandibular third molar extraction: a literature review. *J Oral Maxillofac Res*. 2014 Dec 29;5(4):e1.
9. Özçakir-Tomruk C, Arslan A. Mandibular angle fractures during third molar removal: a report of two cases. *Aust Dent J*. 2012 Jun;57(2):231-5.
10. Gulati A, Herd MK, Nimako M, Anand R, Brennan PA. Litigation in National Health Service oral and maxillofacial surgery: review of the last 15 years. *Br J Oral Maxillofac Surg*. 2012 Jul;50(5):385-8.
11. Zanin AA, Herrera LM, Melani RF. Civil liability: characterization of the demand for lawsuits against dentists. *Braz Oral Res*. 2016 Aug 18;30(1). pii: S1806-83242016000100276.
12. Perea-Pérez B, Labajo-González E, Santiago-Sáez A, Albarrán-Juan E, Villa-Vigil A. Analysis of 415 adverse events in dental practice in Spain from 2000 to 2010. *Med Oral Patol Oral Cir Bucal*. 2014 Sep 1;19(5):e500-5.
13. Koskela S, Suomalainen A, Apajalahti S, Ventä I. Malpractice claims related to tooth extractions. *Clin Oral Invest*. 2017 Mar;21(2):519-22.
14. Marciani RD. Third molar removal: an overview of indications, imaging, evaluation, and assessment of risk. *Oral Maxillofac Surg Clin North Am*. 2007 Feb;19(1):1-13, v.
15. Marei HF. Medical litigation in oral surgery practice: lessons learned from 20 lawsuits. *J Forensic Leg Med*. 2013 May;20(4):223-5.
16. Badenoch-Jones EK, Lynham AJ, Loessner D. Consent for third molar tooth extractions in Australia and New Zealand: a review of current practice. *Aust Dent J*. 2016 Jun;61(2):203-7.
17. Pires WR, Bonardi JP, Faverani LP, Momesso GA, Muñoz XM, Silva AF, Panzarini SR, Bassi AP, Ponzoni D. Late mandibular fracture occurring in the postoperative period after third molar removal: systematic review and analysis of 124 cases. *Int J Oral Maxillofac Surg*. 2017 Jan;46(1):46-53 [doi: 10.1016/j.ijom.2016.09.003. Epub 2016 Sep 28].