



Journal Homepage: -www.journalijar.com
**INTERNATIONAL JOURNAL OF
 ADVANCED RESEARCH (IJAR)**

Article DOI:10.21474/IJAR01/9534
 DOI URL: <http://dx.doi.org/10.21474/IJAR01/9534>



RESEARCH ARTICLE

A RARE CASE OF PRIMARY TUBERCULOUS EPIDIDYMO-ORCHITIS IN A YOUNG PATIENT.

Dr.Diksha Goyal¹ And Dr.Vijaykumar Satishrao Mane².

1. Resident, Department of Radio-diagnosis, Bharati Vidyapeeth (Deemed to be University) Medical College and Hospital, Sangli.
2. Associate Professor, Department of Radio-diagnosis, Bharati Vidyapeeth (Deemed to be University) Medical College and Hospital, Sangli.

Manuscript Info

Manuscript History

Received: 08 June 2019
 Final Accepted: 10 July 2019
 Published: August 2019

Key words:-

tuberculosis, epididymitis, orchitis, testis.

Abstract

Primary tuberculous epididymo-orchitis is a rare form of genito-urinary tuberculosis presenting as a painless or painful testicular swelling. Genito-urinary tuberculosis is an unusual presentation of tuberculosis. Primary genital involvement is seen in very few patients. We report a case of 24 year old male who presented with hard, painless swelling in the left testicular region mimicking as a testicular tumor for which he underwent ultrasonography and MRI followed by a left sided inguinal lymph node biopsy which revealed tuberculosis of tuberculous epididymo-orchitis. Early and accurate diagnosis of genito-urinary tuberculosis is needed to avoid complications. A complete course of anti-tuberculous treatment can cause complete resolution of the lesion.

Copy Right, IJAR, 2019,. All rights reserved.

Introduction:-

History and clinical examination:

A 24 year old male presented with complaints of left sided hard, painless testicular swelling for 2-3 months. The swelling was not associated with any discharging sinus or scrotal ulceration. There was no history of any respiratory symptom, fever, anorexia or significant weight loss.

Laboratory investigations:

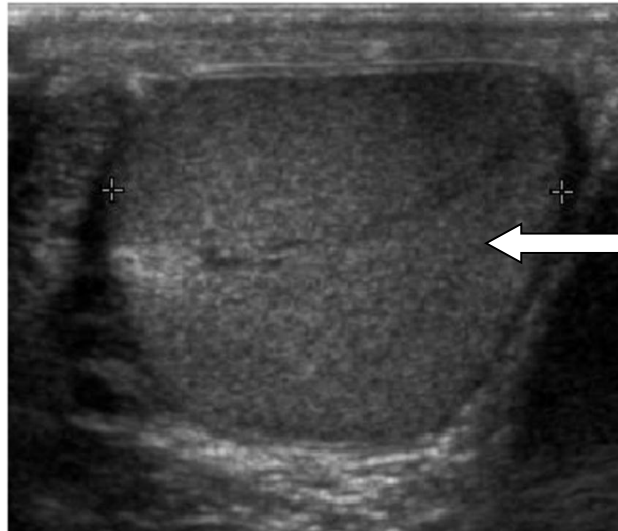
Laboratory investigations were performed which revealed normal hemogram and blood glucose levels. Anti-HIV types 1 and 2 antibodies were done which turned out to be non-reactive. The chest radiograph was normal. All other hematological investigations were normal. After that, a scrotal sonography of the patient was done.

Ultrasonography features:

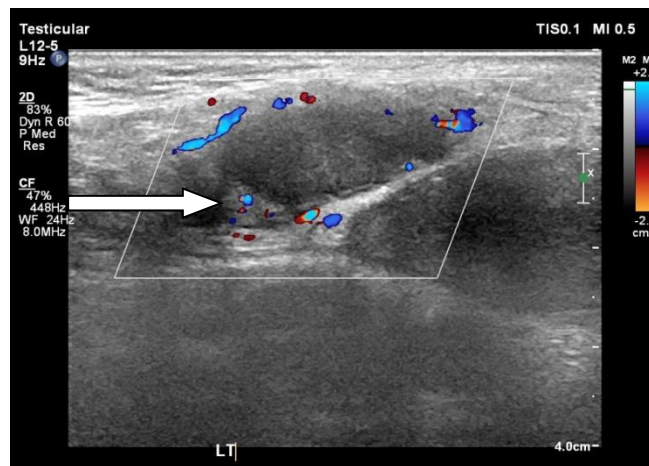
On Ultrasonography, there was normal right testis. The left testis was enlarged in size and shape. It showed ill-defined hypoechoic lesion of size 30x11x12 mm. There was no evidence of hypervascularity or calcification seen within it. Moderate hydrocele was noted on left side. Multiple, well defined, non-compressible, heterogenous, solid hypoechoic lesions were seen in the scrotal wall showing necrotic changes within. Left sided inguinal lymphadenopathy noted.

Corresponding Author:-Dr.Diksha Goyal.

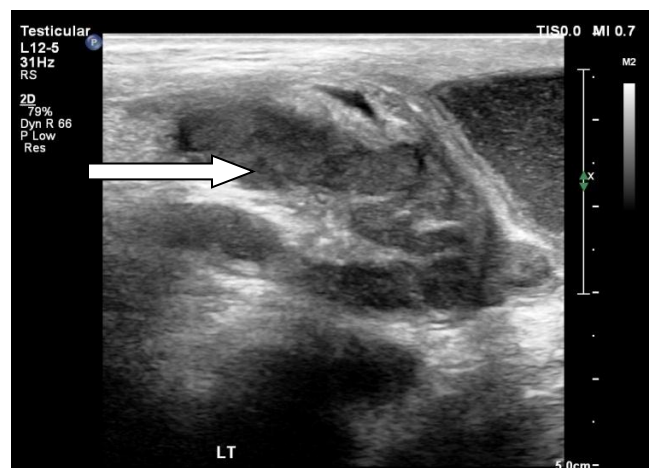
Address:-Resident, Department of Radio-diagnosis, Bharati Vidyapeeth (Deemed to be University) Medical College and Hospital, Sangli.



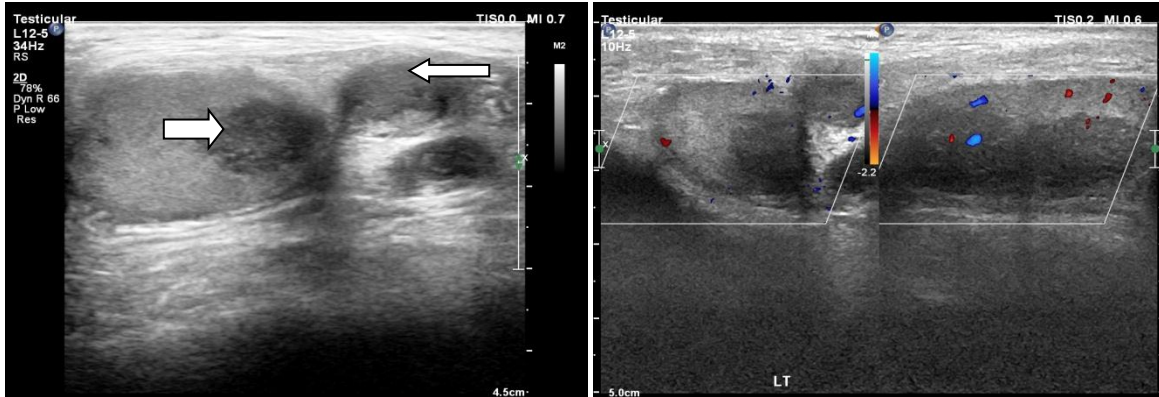
Normal Right testis



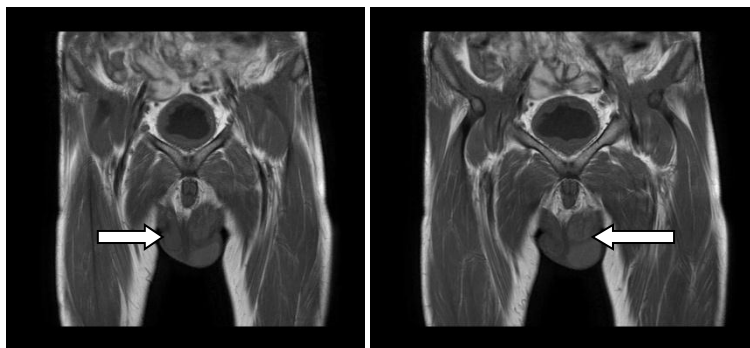
Left testis- showing heterogenous echotexture



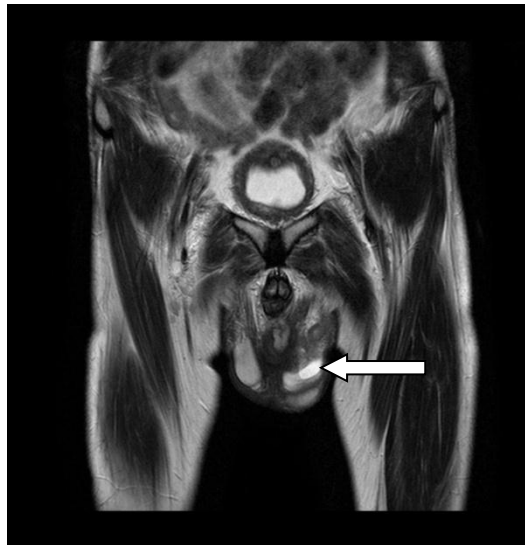Thickened left epididymis on the left thickened left epididymis



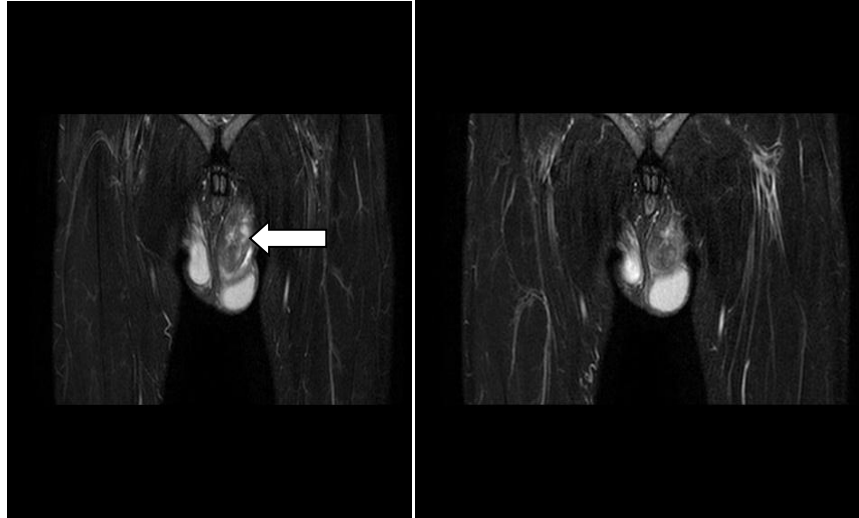
Well defined, hypochoeic lesions seen in the left testis and scrotal wall showing necrotic changes. No evidence of increased vascularity or calcification noted.



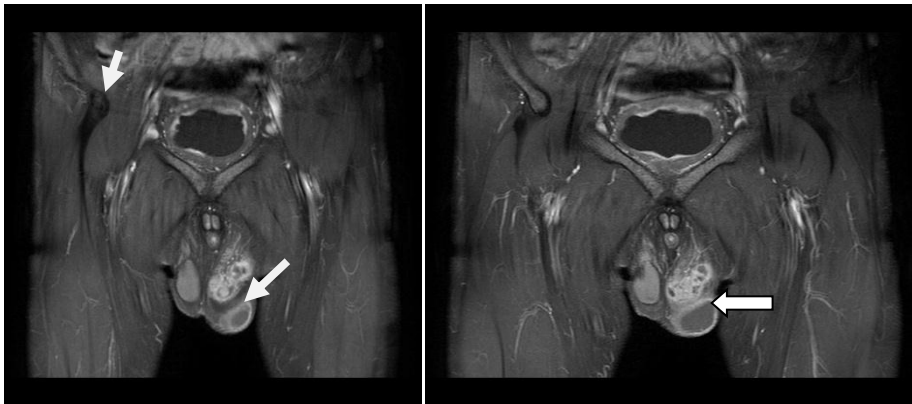
MRI T1W Images Coronal sections showing a normal Right testis and an enlarged Left testis



T2W Image coronal section showing Left sided hydrocele



STIR Coronal MR images showing slightly enlarged left testis. It is also showing hypointense focal lesions. Thickening of cord is also noted on the left side.



CONTRAST STUDY (MRI Coronal section) –Extra- testicular lesion is seen within the scrotal wall towards left.

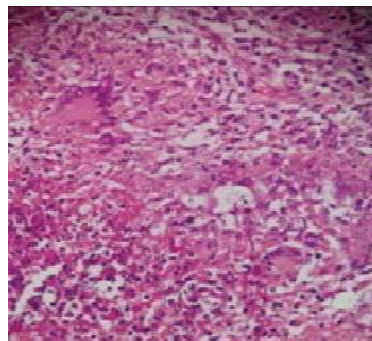
Differential diagnosis:

1. Tuberculous epididymo-orchitis
2. Bacterial epididymo-orchitis
3. Testicular tumour

Final diagnosis :

Tuberculous epididymo-orchitis

Biopsy findings :



The biopsy of inguinal lymph node revealed the presence of caseous necrosis surrounded by granulomas composed of epithelioid cells, Langhans type of giant cells and infiltrated by lymphocytes suggestive of caseating tuberculous inflammation.

Treatment Given –

Patient was then started on anti-tuberculous treatment and followed up.

Follow Of Up up Examination –

The patient was recovering well after the treatment.

Discussion:-

Tuberculosis is a leading cause of death worldwide, especially in the developing countries which are tuberculosis endemic zone, like India. Emergence of drug resistance tuberculosis and rapid increase in incidence of HIV infection makes the world's scenario further critical. Genitourinary tuberculosis is an unusual presentation of tuberculosis and comprises 8–15% of extra-pulmonary tuberculosis. Isolated genital involvement is seen in 28% patients of genitourinary tuberculosis. It is more common in males [5].

Genito-urinary tuberculosis is an unusual presentation of tuberculosis. Primary genital involvement is seen in very few patients. The most common site of genital tuberculosis in males is the epididymis, followed by prostate, seminal vesicles and testis[4]. The mechanism of dissemination is from retrograde spread of tubercle bacilli from the affected urinary tract into the prostate via reflux, followed by canalicular spread to the other parts[1]. It may spread via hematogenous or lymphatic spread.[2]. Tuberculous orchitis commonly occurs with tuberculous involvement of lower urinary tract, even of kidneys. Hence, it may present with lower urinary tract symptoms like irritative voiding symptoms and hematuria. Early and accurate diagnosis of genito-urinary tuberculosis is needed to avoid complications.

A complete course of anti-tuberculous treatment can cause complete resolution of the lesion.

References:-

1. KB Badmos. Tuberculous epididymo-orchitis mimicking a testicular tumour: a case report. Afr Health Sci. 2012 Sep; 12(3): 395–397.
2. Malai Muttarak, Wilfred C.G. Peh, Bannakit Lojanapiwat and Benjaporn Chaiwun. Tuberculous Epididymitis and Epididymo-orchitis Sonographic Appearances. American Journal of Roentgenology. 2001;176: 1459-1466. 10.2214/ajr.176.6.1761459
3. Vishnu Prasad Shenoy, Shashidhar Viswanath, Annet D'Souza, Indira Bairy, Joseph Thomas. Isolated tuberculous epididymo-orchitis: an unusual presentation of tuberculosis. J Infect Dev Ctries 2012; 6(1):92-94.
4. H. Hadiseh, M. Farzaneh. Unilateral tuberculous epididymo-orchitis with scrotal fistula: a case report. Iranian Journal of Pathology (2015) 10 (2): 165 – 168.
5. Das A, Batabyal S, Bhattacharjee S, Sengupta A. A rare case of isolated testicular tuberculosis and review of literature. J Family Med Prim Care 2016; 5: 468-70.