



Journal Homepage: - www.journalijar.com
**INTERNATIONAL JOURNAL OF
 ADVANCED RESEARCH (IJAR)**

Article DOI: 10.21474/IJAR01/9795
 DOI URL: <http://dx.doi.org/10.21474/IJAR01/9795>



RESEARCH ARTICLE

DIFFERENT MODALITIES FOR ACCELERATING ORTHODONTIC TOOTH MOVEMENT: A REVIEW OF STUDIES.

Dr. Mohammed Korayem¹, Dr. Nuha Malibari² and Dr. Waleed Bakhadher³.

1. Assisstant Professor In Orthodontic, College Of Dentistry, Albaha University, Albaha, Saudi Arabia.
2. Specialist In Family Medicine, Ministry Of Health , Saudi Arabia.
3. Associate Consultant In Orthodontic, Dr.Sulaiman Al Habib Private Hospital. Saudi Arabia.

Manuscript Info

Manuscript History

Received: 16 July 2019

Final Accepted: 18 August 2019

Published: September 2019

Key words:-

orthodontics, corticotomy, accelerated tooth movement.

Abstract

Technological advancement and the initiation of modern therapeutic methods are constantly changing contemporary orthodontics. More and more orthodontic patients are working adults, who expect satisfactory therapeutic effects as soon as possible, increasing the importance of methods accelerating tooth movement.

Aim: The aim of this hypothesis was to review the present literature regarding methods of accelerating tooth movement and reducing the duration of the active phase of therapy.

Methods: The methods described were categorized as conservative and surgical. The pharmacological agents used in conservative treatment, such as growth hormone, parathyroid hormone, thyroxine, and vitamin D, are especially worth mentioning. They stimulate osteoclasts to increase resorption through a variety of mechanisms. Effective methods also include physical stimuli, e.g., vibrations or photo bio-modulation. Corticotomy and its modifications based on the regional acceleratory phenomenon (RAP) might prove to be a useful augmentation of orthodontic treatment, especially in adults, including patients with periodontal disease.

Conclusion: Tooth acceleration phenomenon is still a relatively new horizon and researchers have yet to seek a single most ideal and prudent technique for the patient. The surgical techniques have most of the human trials and also show very favorable and long term effects adding to the stability and retention of the orthodontic therapy.

Copy Right, IJAR, 2019,. All rights reserved.

Introduction:-

The ambition of a beautiful smile is presently not hard to fulfill, as interdisciplinary treatment involving prosthetic, surgical, periodontal, and orthodontic procedures makes successful esthetic effects possible in the majority of cases. Among these methods, orthodontics have a fundamental disadvantage: prolonged therapy time. Depending on the kind and severity of the defect, as well as the general condition of the patient, comprehensive treatment lasts on average close to two years.¹⁰

Corresponding Author:-Dr. Mohammed Korayem.

Address:-Assisstant Professor In Orthodontic, College Of Dentistry, Albaha University, Albaha , Saudi Arabia.

This has a veto impact on the patient's compliance with braces requiring strict control of meals consumed, special attention to hygiene, and regular appointments at the orthodontist's office. On the clinical level, long-term therapy may lead to iatrogenic complications, including demineralization of enamel, tooth decay, inflammation and recession of gums, damage to the periodontium, or root resorption. In light of contemporary literature, using increased force to accelerate the movement of teeth is discouraged due to possible hyalinization of the periodontal fibers and undermining resorption, leading to delayed movement.⁶

It is hence necessary to affect the surroundings of the tooth that ensure its stable position in the neutral zone – the alveolar bone. Tooth movement takes place with the simultaneous cooperation of osteoclasts in the pressure zone (which leads to resorption) and osteoblasts in the pulling zone (the apposition process). An imperative role is also played by periodontal ligaments, which, while acting as a force absorber, also play the part of specific receptors associated with the sympathetic system. Methods of accelerating tooth movement are based on stimulating biological tissue response, i.e., enhanced metabolism and accelerated bone remodeling. On the basis of the level of invasiveness, the methods encountered in the scientific literature can be divided into conservative methods and those based on surgical intervention.¹¹

Recently, numerous methods have been proposed to enhance the rate of orthodontic tooth movement so that faster and better treatment options can be provided to the patients. The aim of this article is to enumerate and discuss different methods to accelerate orthodontic tooth movement and also to discuss advantages and shortcomings of each method. Methods to accelerate orthodontic tooth movement can be discussed under the following categories:

Conservative Methods:-

The application of pharmacological agents

At the cellular level, the predominance of osteoclast activity over osteoblasts is responsible for bone resorption. It occurs as a result of the intensification of the inflammatory process in the periodontal and connective tissue of the gum. Mature osteoclasts can be stimulated by pro-inflammatory signals coming from perio-pathogens, fibroblasts, macrophages or Th lymphocytes. Another pathway of bone resorption is based on the mechanism of osteoblast and cell-precursor differentiation towards osteoclasts. This is an effect of the nuclear factor kappa B receptor (RANK) system and the receptor activator of nuclear factor kappa-B ligand (RANKL) competing with osteoprotegerin (OPG).¹

Growth Hormone

Growth hormone (GH), also called somatotropin, is secreted by the anterior lobe of the pituitary gland. It has a stimulating effect on bone growth and remodeling, and a deficiency results in pituitary dwarfism. The action of GH is based directly on increases in the proliferation and differentiation of osteoblasts, as well as on induction of protein synthesis and mineralization. Ribeiro et al. assessed the modifying effect of growth hormone on the pace of tooth movement during experimental orthodontic treatment in rats. In their study, individuals from the experimental group were administered daily subcutaneous doses of growth hormone of ≈ 0.033 mg/kg, analogous to the dose used in humans. A day after the 1st dose was administered, a nickel-titanium spring was fixed between the incisor and the right 1st molar, exerting a force of 30 g. Growth hormone accelerated bone resorption (in the experimental group the highest number of osteoclasts was recorded as early as on the 3rd day, which was twice as high as in the control group on day 7), but it also delayed angiogenesis. This suggested that the activation of a device should be less frequent after GH administration. There are even recommendations to begin orthodontic therapy 12–24 months after GH administration, because only then will somatotropin stimulate the process of bone formation. As GH reduces the synchronization between resorption and bone apposition, this is not a method of high potential clinical relevancy.⁵

Parathormone

Parathormone (PTH) is a compound secreted by the parathyroid gland which binds to receptors on osteoblasts, activating them and leading to the expression of insulin-like growth factor 1 (IGF-1; somatomedin). This results in the proliferation of osteoblasts and, with the participation of the RANK ligand, osteoclast activation. Depending on the frequency of administration, PTH may stimulate bone formation (intermittent therapy) or its resorption (exposure longer than 1–2 years). Two 12-day studies in rats confirmed that intermittent administration of PTH accelerated the mesialization of the 1st molar 1.6 times after administration of a dose of 0.25 MG/100 g b.w. into the subperiosteal area and 1.4 times as a result of subcutaneous administration of 4 μ g/100 g m.c. However, another study by the same authors does not confirm the efficacy of intermittent therapy. Long-term research on the superiority of this method over other protocols is needed, as well as clinical trials. Nevertheless, it is important to consider chronic PTH intake when planning orthodontic treatment, e.g., in cases of severe osteoporosis.^{1,11,18}

Vitamin D

Another agent that may affect tooth movement is vitamin D. 1,25-dihydroxycholecalciferol is the most active metabolite of this vitamin. It mainly has an anabolic effect on the bone tissue (to a small extent also catabolic). Similarly to PTH, subperiosteal administration of vitamin D enhances the activity and proliferation of osteoblasts. These properties prompted researchers to design animal experiments attempting to modify the course of orthodontic treatment. Collins et al. used calcitriol dissolved in DMSO (dimethylsulfoxide) – a compound that readily penetrates cell membranes, as well as has a high solubility coefficient for vitamin D) – administered daily into the periosteum. After 3 weeks, the retraction range of the canines was 60% higher compared to the control group.

7,8

Other researchers came to similar conclusions, this time testing the action of this vitamin on rats. They noticed an increased number of both osteoclasts and osteoblasts. Kawakami and Takano- Yamamoto emphasized the continuation of intensified remodeling during the retention period as well. In turn, Kale et al. observed that distalization of the maxillary incisors increased by 23%. In a few clinical trials, acceleration of orthodontic tooth movement was also demonstrated. After a daily oral dose of 0.25 µg of vitamin D, the mean difference in the retraction movement between the experimental group and the control group (who underwent orthodontic therapy without supplementation) was 1 mm/60 days. However, the use of a very low dose of the supplement in the study appears to be questionable (10 IU vs the daily recommendations of 1000–2000 IU).¹⁹

Thyroxine

Thyroxine administration is a recommended form of hypothyroidism treatment. It increases bone remodeling and stimulates resorption, which contributes to a decrease in bone density. This is probably due to the increased concentration of interleukin 1 (IL-1), which stimulates the formation of osteoclasts and the resorption process. Animal studies confirm accelerated tooth movement after administration of this substance. Seifi et al. observed 0.45 mm of movement after 21 days in their experimental group, compared to 0.23 mm in the control group. Additionally, they detected cumulative effects of concomitant administration of thyroxine and prostaglandine E2 (0.74 mm of movement). However, Shirazi et al. noticed much less root resorption after thyroxine-assisted orthodontic treatment. Despite the lack of clinical trials, the presence of metabolic diseases related to the thyroid gland should be taken into consideration when planning orthodontic treatment. In cases of hypothyroidism it is recommended to activate the device less frequently, Where as for patients with hyperthyroidism, a longer retention period is recommended.³

Beta 2-Adrenergic Agonist

There is a very specific periodontal microenvironment between the tooth and the bone that requires further description. It consists of collagen fibers, cells and tissue fluid acting as a force absorber. The ligaments are strongly innervated: they contribute to the transmission of pain, modification of the immune response and bone remodeling. During orthodontic treatment mechanical force acting on the tooth is transmitted to these ligaments. Periodontal cells stimulate the biological response (e.g., by increasing the amount of Y-neuropeptide-containing fiber, substance P or calcitonin gene-related peptide). This is confirmed by the impossibility of moving ankylosed teeth, which are deprived of periodontal fibers due to direct connection with the bone. Periodontal ligaments are formed from the cranial neural crest differentiating in embryonic stem cells. Due to their origins, they express B2-adrenergic receptors and, through the RANK receptor system, stimulate osteoblasts to undergo osteoclastogenesis. The available studies involving B2- adrenergic agonists are based on direct evidence (stimulation of receptors with agonists, e.g., isoproterenol) or indirect observations (similar inhibition of the sympathetic system after using propranolol). Takeda et al., using isoproterenol, induced an osteoclastogenic response in mice. According to Kondo et al., by inhibiting the sympathetic system with the butaxamine, bone loss was limited and tooth movement slowed down. Kondo et al. also made intraperitoneal injections of propranolol, isoproterenol or (in the control group) saline solution, and blockages or stimulations confirmed their thesis. More invasive tests on rats were performed by Cao et al. After performing ganglionectomies of the upper cervical ganglion, they noted a decrease in osteoclast differentiation and limited tooth movement. Yamashiro et al., in an animal model of experimental tooth movement, noted a lack of significant changes in bone remodeling after transection of the lower alveolar nerve. In conclusion, despite the presence of many experiments related to B2-adrenomimetics, one cannot overlook the fact that there are no clinical trials that provide significant scientific evidence.^{4,6,10}

Physical Stimuli

Studies on the acceleration of teeth movement describing stimuli which increase the metabolism of tissues were investigated. The mechanisms of the most of them are not fully understood, but there is considerable evidence of their beneficial effects.

Electromagnetic Fields

Electromagnetic fields have a proven effect on cell membrane permeability. They can be divided into static magnetic fields (SMF) and pulsed electromagnetic fields (PEMF). Both types have been used in general medicine for many years. A SMF can contribute to the healing process after an osteotomy, can stimulate bone remodeling, or prevent bone volume decrease after surgical intervention or implantation. In the field of orthodontics, it has been used for many years as an element supporting active therapy or even as an independent procedure. It may be of certain clinical benefit during space closure, intrusion, forced extrusion of impacted teeth, and palatal expansion. An analysis of the few available animal studies concludes that in order to accelerate tooth movement, a field with a flux density of 460 mT should be used. Sakata et al. came to this conclusion analyzing the previous experiment of Tengku et al., who, while using the intensity of 10 mT, did not observe clinically satisfactory results.⁹

A PEMF, by stimulating osteoblasts to proliferate and differentiate, as well as increasing the production of alkaline phosphatase and regulating calcium metabolism, can improve the treatment of bone fractures, osteonecrosis and osteoporosis, among other things. According to Bassett's research, therapeutic application of magnetic fields results in the creation of cellular tension similar to that which is induced during mechanical deformation of the bone (e.g., during the movement of the teeth). Studies on a rat model have shown that the support of active orthodontic elements operating with a force of about 20 g, both using a PEMF of 1.8 mT (or 1.5 mT) and a Nd-Fe-B magnet (neodymium), increases the distance a tooth can be moved. Stark and Sinclair and Showkatbakhsh et al. also confirmed the accelerating action of PEMF. In both cases, they observed positive effects. However, the authors pointed out that due to differences in size and physiology, predicted results on the human body should be extrapolated with caution. Information regarding the lag phase in orthodontic tooth movement (the phase of clearing hyalinized fibers from the pressure zone) is also important. It can be hypothesized that electromagnetic field therapy can shorten the lag phase (due, among other things, to earlier formation and removal of hyalinized tissue).^{7,9}

Vibrations

Rubin et al. have proven that vibrations increase the remodeling rate and the overall reconstruction of the long bones - a phenomenon used in the prevention of osteoporosis. In addition, by comparing the effects of cyclic and static forces in experiments on animal models (cranial sutures and the periosteum of the long bones), an improvement in bone formation and an increase in orthodontic tooth movement was observed. Initial clinical trials have shown promising results. Dubravko et al. used the AcceleDent device (Ortho Accel Technologies, Bellaire, USA) to generate a vibration of 0.25 N and a frequency of 30 Hz. It was possible to accelerate the distalization of canines with skeletal anchorage by 48.1% compared to the control group (1.16 mm vs 0.79 mm/month). Other reports have also confirmed the accelerating effect of vibrations. This time, the source of the stimuli was electric toothbrush massage for 15 min a day (a frequency of 125 Hz). Within 3 months, a 2.85 mm distal axial movement of the canines was obtained (37.7% greater than in the control group). Those authors additionally investigated the concentration of IL-1 β in fluid collected from the gingival pocket, which, as a factor stimulating the expression of RANKL, can be a good indicator of the effectiveness of orthodontic movement. On the pressure side, the concentration of the cytokine in the study group was on average more than 6 times higher than in the fluid collected from the control group. Contrary to expectations, acceleration was not confirmed by studies in mice in which orthodontic forces were applied to the 1st molars and low frequency vibrations (5, 10 and 20 Hz) were used. Furthermore, the latest randomized clinical trials call into question the chances of significantly shortening the time of orthodontic treatment by administering vibrations.^{2,7,19}

Photobiomodulation

This technique can be characterized by a very limited invasiveness. It involves the exposure of tissues to the effects of red light of a therapeutic wavelength (600–1200 nm). These wavelengths reduce absorption of the light by hemoglobin and water and allow it to reach the deeper soft tissue and the alveolar bone. The resulting stimulation may have potentially positive effects on the production of adenosine triphosphate (ATP).

]

On the other hand, increasing the activity of cells leads to increased bone metabolism in situ, which creates favorable conditions for the movement of teeth. Therapy with light can be divided into 2 basic types: low-intensity lasers (LIL), producing coherent light, and light-emitting diodes (LED), which are sources of incoherent light. There are no publications regarding the superiority of one above the other. What is more, most authors agree that the cellular response depends primarily on the wavelength and the dose of light, not on its source. Only Fujita et al. noted more favorable results in LIL therapy, and Vinck et al. found that an LED source creates more favorable conditions for cell growth in green light. Numerous studies on this subject can be found in the literature, on both animal and clinical models. Most of them indicate a significant increase in the speed of tooth movement. In these studies gallium-aluminum-arsenide (Ga-Al-As) lasers were used, and the length of light wave was on average 820 nm. The challenge was to determine the optimal

energy dose. Goulart et al. achieved acceleration as a result of a combined dose of 5.25 J/cm², but noted that increasing it to 35 J/cm² could have the opposite effect. This thesis was confirmed by several researchers, including some studies applying irradiations of 100 mW.^{61–70} Animal studies have adopted a methodology focusing on determining remodeling efficiency, the RANK/RANKL system, and the expression of fibronectin and type I collagen.^{6,8}

In addition to standard tooth movements, Saito and Shimizu were able to accelerate bone regeneration after suture opening during expansion of the palate in rats. Youssef et al., after 6 months of research on a group of 15 adults, achieved an almost 2-fold acceleration of canine retraction. Nahas et al. investigated the effects of the Ortho-Pulse device (Biolux Research Ltd., Vancouver, Canada) in patients with Little's irregularity index in the range of 2–10 mm. Satisfactory results were obtained in the research group after an average of 68.3 days (compared with 87.8 days in the control group), which shortened the treatment time by 22%. Acceleration has also been reported in a few randomized clinical trials. Nevertheless, Marquezan et al., during an experiment on an animal model, despite an increased number of osteoclasts on the pressure zone side, did not notice an increased dental shift macroscopically. Chung et al. came to a similar conclusion after observing 11 patients for 3 months. To sum up, due to the differences in the protocols of the experiments conducted, further research is needed, focusing, among other things, on harmonizing the radiation dose.^{9,12}

Clear Aligners and Self-Ligating Brackets

In the literature, only a few studies can be found analyzing the acceleration of the movement of teeth using clear aligners and self-ligating brackets. It should also be noted that research based on histological evidence is lacking. Conclusions can be drawn based only on the differences in therapy duration and cases assessed using various indices, such as the peer assessment rating (PAR) or the objective grading system (OGS). Gu et al. found the Invisalign system (Align Technology Inc., San Jose, USA) to be advantageous in correcting minor orthodontic defects; the duration of treatment with the same effects was 30% (5.7 months) shorter compared to fixed braces. Buschang et al. reached similar conclusions: in a study of 150 patients with incisor crowding under 5 mm (the study group), they noted that the duration of therapy was reduced by 5.5 months.¹⁶

However, despite shorter treatment and less frequent visits, they point out that aligner therapy is much more expensive and requires more experience. On the other hand, Hennessy et al. did not notice a difference between the length of the treatment of mandible incisor crowding with the Invisalign system and with a fixed labial appliance. In summary, the use of clear thermoplastic aligners, despite their presence and growing popularity in orthodontic clinics, requires further research in terms of accelerating the movement of teeth. Self-ligating brackets are also worth mentioning. The 1st brackets of this type were created by Stolzenberg over 70 years ago.

The aim was to reduce the friction between the arch and the bracket, which is increased by ligatures (both elastic and metallic). According to some researchers, reducing it improved the effectiveness of the "sliding mechanism" used during tooth rotation, correction of angulation and closing spaces. It does not affect bone remodeling, but only changes the distribution of forces that the orthodontist uses during treatment. In addition, despite manufacturers' assurances of shorter treatment times, numerous studies have reported the opposite, detecting no significant differences between the duration of active therapy with the use of conventional and self-ligating devices.¹⁷

Surgical Methods

The surgical technique has been documented in many case reports. It is a clinically effective technique used for adult patients, where duration of orthodontic treatment may be critical. Periodontal ligament (PDL) and alveolar bone remodeling are the important parameters in tooth movement and bone turnover is known to increase after bone grafting, fracture, and osteotomy. Several surgical approaches that have been tried in order to accelerate tooth movement are Corticotomy and Piezocision technique. The idea of surgical acceleration came into being after the introduction of Regional Acceleratory Phenomena (RAP) by Frost in 1983. RAP is a local response to noxious stimulus, by which tissue forms faster than the normal regional regeneration process. This phenomenon causes healing to occur 2–10 times faster than normal physiologic healing by enhancing the various healing stages.⁹

Corticotomy

It was first tried in orthodontics by Kole. Conventional corticotomy is one of the surgical procedures that is commonly used, in which only the cortical bone is cut and perforated but not the medullary bone. This will reduce the resistance of the cortical bone and accelerate tooth movement. It was suggested that bony blocks were created as a result of the corticotomy, hence causing faster tooth movement. The conventional corticotomy procedure involves elevation of full

thickness muco periosteal flaps, buccally, followed by placing the corticotomy cuts using either micro motor under irrigation, or piezo surgical instruments. This can be followed by placement of a graft material, wherever required, to augment thickness of bone. ⁴

Until 2001, the “bony block” concept prevailed as a misconception. However, Wilcko et al reported that tooth movement was not the result of bony block, but rather a process of transient remineralization/demineralization which is a concept of reversible osteopenia in the bony alveolar housing consistent with wound healing pattern of RAP. He also introduced the term “bone matrix transportation and developed patent techniques which were called Accelerated Osteogenic Orthodontics (AOO) and Periodontal Accelerated Osteogenic Orthodontics.

Modification of RAP was done by adding bio-absorbable grafting material over the injured bone to enhance healing.

Advantages

1. Corticotomy procedure causes minimal changes in the periodontal attachment apparatus.
2. It has been proven successfully by many authors to accelerate tooth movement.
3. Bone can be augmented; thereby preventing periodontal defects.⁷

Disadvantages

1. Invasive procedure leading to high morbidity.
2. Chances of damage to adjacent vital structures.
3. Postoperative pain and swelling.
4. Chances of infection or avascular necrosis.
5. Low acceptance by the patient.

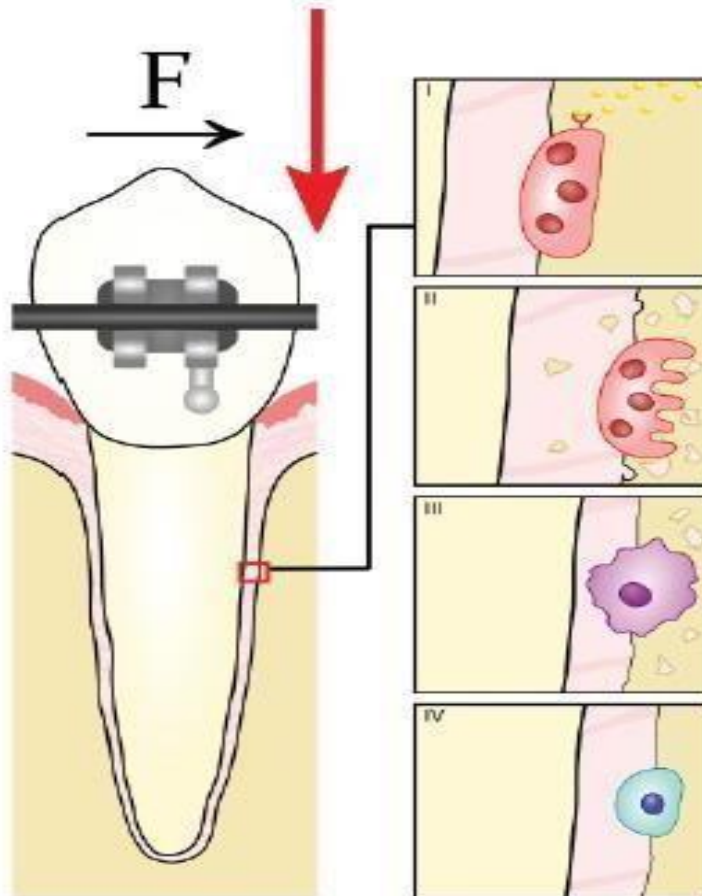


Fig 1:-The regional acceleratory phenomenon (RAP) a phenomenon described by H. Frost in 1983, involving the temporary reduction of bone density as a result of harmful stimulus.

Small harmful stimuli (such as Shallow bone incisions) activate the RANK/RANKL system. In “weakened” bone tissue, 10–50 times faster remodeling is expected. This effect lasts for about 4 months (though it can last up to 6–24 months), with peak efficiency reached 1 or 2 months after surgery. Due to the nature of the surgery, which involves a high risk of infection, antibiotic protection is vital. Only local anesthesia is required. The field of the procedure depends on the

defect:

vertical incisions are made between the roots of the teeth, horizontally, 2–3 mm above the apices, in order not to damage the bundles.

The advantage of the method lies in the creation of a more stable anchorage, not involving teeth/arches in the procedure. The brackets of the fixed appliance are bonded before the surgery. The cuts, after earlier retraction of the muco-periosteal flap, can be made with traditional rotational tools or a piezoelectric knife. Dibart et al. recommend the use of the latter, due to limited traumatization of tissues, greater precision of execution, and more extensive bone demineralization, which induces prolonged RAP. To avoid interfering with the bone remodeling process, non-steroidal anti-inflammatory drugs (NSAIDs) should not be administered. Initially (in the first 3–7 days) the pain can severely affect the patient’s well-being. Tooth brushing should be neglected for a week. An alternative is to rinse the mouth with an antiseptic solution (e.g., chlorhexidine). After this period, the 1st activation of the braces can be performed. It is important that during the demineralization of the bones, the patient appears regularly for frequent visits.^{1,2,12,16}

Periodontally Accelerated Osteogenic Orthodontics

Described by Wilcko et al. in 2001, the technique referred to as periodontally accelerated osteogenic orthodontics (PAOO) or accelerated osteogenic orthodontics (AOO) is a combination of conventional corticotomy with the implantation of bone graft material. After analyzing high-resolution computed tomography (CT) scans, Wilcko et al. observed the process of remodeling remineralization and demineralization of the bone and demonstrated its relationship with the RAP, as described earlier. After retraction of the muco-periosteal flap and incisions in selected areas, allogenic frozen and dried material is placed in the scars. It is very important that it is fully biocompatible. Otherwise, only the extension of the epithelial attachment can be observed, leading to the accumulation of bacteria, which in turn may result in abscess formation and bone loss.⁹⁴ Insertion of the material allows bone density and mass to increase. This is particularly important in adults, who have much lower regenerative bone capacity than children. The main goal is to surround the teeth on each side, while eliminating fenestration and bone dehiscence. This increases the possible range of tooth movement, the apical base and the arch envelope, and minimizes gum recessions, relapses and the need for extraction. One indication is the presence of shortened roots, which could become shorter during traditional treatment. Wilcko et al. presented many cases demonstrating the effectiveness of the method in accelerating the movement of teeth while improving the condition of periodontal tissues.^{6,8,9}

Piezocision

One of the recent techniques in accelerating tooth movement is the Piezocision technique. Dibart was amongst the first to apply the Piezocision technique which starts with primary incision placed on the buccal gingiva, below the interdental papilla, as far as possible, in the attached gingiva using a No.15 scalpel. These incisions need to be deep enough so as to pass through the periosteum and contact the cortical bone. Next, using ultrasonic instrumentation (they used a BS1 insert Piezotome), perform the corticotomy cuts to a depth of 3 mm through the previously made incisions. At the areas requiring bone augmentation, tunneling is performed using an elevator inserted between the incisions, to create sufficient space to accept a graft material. No suturing is required except for the areas where the graft material needs to be stabilized. Piezocision technique does not cause any periodontal damage as reported by Hassan. The study by Keser concluded that this technique can be used with Invisalign which leads to a better aesthetic appearance and also the treatment time is shortened. Piezocision is a promising tooth acceleration technique because of its various advantages on the periodontal, aesthetic, and orthodontic aspects.

Micro-Osteoperforations

This is another treatment modality based on the RAP. The goal is to further minimize soft tissue damage. Perforations are made in the bone through the mucous membrane, with the aim of accelerating orthodontic movement. Micro-osteoperforations can also be combined with standard corticotomy or the PAOO technique. The device used during the treatment was designed by Propel Orthodontics (Ossing, USA). It is intended for single use only. It perforates both the attached gingiva and the mucous membrane. Clinically, the use of micro-osteoperforations significantly increases the expression of cytokines, which leads to a 60% shorter treatment time compared to a control group, and 2.3 times faster

retraction of canines. The procedure itself is described as effective, convenient, and less invasive than standard corticotomy.^{2,5,7}

Corticotomy and other attempts at surgical acceleration of tooth movement are documented in a large number of scientific publications. Despite the different levels of invasiveness, they have similar effectiveness, which was confirmed in a comparative study by Librizzi et al. It can be assumed that this is the effect of the same mechanism of action (inducing the RAP). Experiments conducted on an animal model show both a shorter therapy time and increased remodeling occurring within the cancellous bone. Similar results were obtained during the treatment of mild crowding (a study on 24 patients resulted in a 47% shorter treatment time), orthodontic extrusion of palatally impacted canines (6 patients) and retroinclination of upper incisors with sufficient bone support. Al-Naoum et al., in a group of 30 patients, obtained an average speed of 0.74 mm/week (compared to 0.2 mm/week on the control side) during retraction of canines. The potential usefulness of corticotomy in the treatment of post-traumatic ankylosis is also worth considering. Małyszko et al. published a case of post-traumatic intrusion of tooth complicated with ankylosis and resistant to other methods of traditional orthodontic treatment. The application of bone incisions with the intraocular luxation resulted in a positive effect, i.e., tooth extrusion. The role of corticotomy in clinical orthodontics seems to be constantly growing and is currently one of the most frequently used methods to shorten the time of orthodontic treatment.

Combined Methods

Considering the different mechanisms of action of conservative and surgical methods, the question arises: Would the combination of both prove even more efficient? Referring to this hypothesis, Kim et al. conducted a study combining cortical bone incision (also referred to as corticision) and radiation. The experiment involved 12 dogs divided into 4 groups: a control group (only orthodontic force was used), a group undergoing photobiostimulation, a group undergoing surgical treatment, and a group in which both of these methods were implemented. In the groups involving the surgical procedure, incisions were made near the 2ND maxillary premolars (for the purpose of their mesialization after the extraction of the 1st premolars). A diode laser with a wavelength of 808 nm was used as the source of photobiostimulation.^{7,8,9}

Contrary to expectations, the group covered by both treatment methods showed less acceleration than the groups undergoing each treatment separately. Moreover, within 8 weeks after the procedure, the dental movement in the group exposed to both methods was comparable to the control group (in which only orthodontic forces were used). Considering the regenerative effect of light irradiation, it can be assumed that the laser significantly accelerated bone healing and thus led to the elimination of the RAP. The available literature also describes 2 cases in which corticotomy and Smiletech polyvinyl overlays (Ortodontica Italia, Rome, Italy) were used. Cassetta et al. described the therapy of 2 patients with moderate crowding (the 1st with class I, the 2ND with class II). The treatment was completed with a satisfactory effect after 2 months (in the class I patient) and after 8 months (in the class II patient). However, attention should be paid to the low power of scientific evidence (no control group; only a case report) and the possible bias of the conducted study.^{6,17}

Conclusions:-

The contemporary literature presents various methods of accelerating tooth movement during orthodontic treatment, but a significant number of them, especially those using pharmacological agents, are supported by rather limited scientific evidence due to the fact that randomized clinical trials are rarely encountered. The methods using physical stimuli, in spite of the larger number of published trials, can prove difficult to apply in everyday practice due to the use of expensive and specialized equipment and the need for regular and repeated administration of specific agents. Surgical methods are currently the most soundly evidenced, and could be described as methods of documented efficacy. Unfortunately, they are associated with significant (though constantly diminishing) invasiveness, exposing.

References:-

1. Tsihlaki A, Chin SY, Pandis N, Fleming PS. How long does treatment with fixed orthodontic appliances last? A systematic review. *Am J Orthod Dentofacial Orthop.* 2016;149:308–318.
2. Szymańska-Kubal D. Selected complications of orthodontic treatment with fixed and removable appliances [in Polish]. *Nowa Stomatol.* 1999;4:1–2:31–40.
3. Proffit WR, Fields HW, Sarver DM. The biologic basis of orthodontic therapy. In: Komorowska A, ed. *Contemporary Orthodontics* [in Polish]. Wrocław, Poland: Elsevier Urban&Partner; 2016;2:7–9.

5. Konopka T. Etiopathogenesis of periodontal diseases. In: Górska R, Konopka T, eds. Contemporary Periodontology [in Polish]. Otwock, Poland: Med Tour Press International; 2013:94–95.
6. Marcus R. Skeletal effects of growth hormone and IGF-I in adults. *Horm Res.* 1997;48(Suppl 5):60–64.
7. Ribeiro JS, Maciel JV, Knop LA, Machado MÁ, Grégio AM, Camargo ES. Effect of growth hormone in experimental tooth movement. *Braz Dent J.* 2013;24:503–507.
8. Simpson H, Savine R, Sönksen P, et al.; GRS Council. Growth hormone replacement therapy for adults: Into the new millennium. *Growth Horm IGF Res.* 2002;12:1–33.
9. Dobnig H, Turner RT. Evidence that intermittent treatment with parathyroid hormone increases bone formation in adult rats by activation of bone lining cells. *Endocrinol.* 1995;136:3632–3638.
10. Esbrit P, Alcaraz MJ. Current perspectives on parathyroid hormone (PTH) and PTH-related protein (PTHrP) as bone anabolic therapies. *Biochem Pharmacol.* 2013;85:1417–1423.
11. Soma S, Matsumoto S, Higuchi Y, et al. Local and chronic application of PTH accelerates tooth movement in rats. *J Dent Res.* 2000;79:1717–1724.
12. Li F, Li G, Hu H, Liu R, Chen J, Zou S. Effect of parathyroid hormone on experimental tooth movement in rats. *Am J Orthod Dentofacial Orthop.* 2013;144:523–532.
13. Soma S, Iwamoto M, Higuchi Y, Kurisu K. Effects of continuous infusion of PTH on experimental tooth movement in rats. *J Bone Miner Res.* 1999;14:546–554.
14. Diravidamani K, Sivalingam SK, Agarwal V. Drugs influencing orthodontic tooth movement: An overall review. *J Pharm Bioallied Sci.* 2012;4(Suppl 2):299–303.
15. Kouskoura T, Katsaros C, von Gunten S. The potential use of pharmacological agents to modulate orthodontic tooth movement (OTM). *Front Physiol.* 2017;8:67.
16. Reichel H, Koeffler HP, Norman AW. The role of the vitamin D endocrine system in health and disease. *N Engl J Med.* 1989;320:980–991.
17. Collins MK, Sinclair PM. The local use of vitamin D to increase the rate of orthodontic tooth movement. *Am J Orthod Dentofacial Orthop.* 1988;94:278–284.
18. Wood DC, Wood J. Pharmacologic and biochemical considerations of dimethyl sulfoxide. *Ann NY Acad Sci.* 1975;243:7–19.
19. Takano-Yamamoto T, Kawakami M, Kobayashi Y, Yamashiro T, Sakuda M. The effect of local application of 1,25-dihydroxycholecalciferol on osteoclast numbers in orthodontically treated rats. *J Dent Res.* 1992;71:53–59.
20. Kawakami M, Takano-Yamamoto T. Local injection of 1,25-dihydroxyvitamin D₃ enhanced bone formation for tooth stabilization after experimental tooth movement in rats. *J Bone Miner Metab.* 2004;22:541–546.