



Journal Homepage: - [www.journalijar.com](http://www.journalijar.com)  
**INTERNATIONAL JOURNAL OF  
 ADVANCED RESEARCH (IJAR)**

Article DOI: 10.21474/IJAR01/9796  
 DOI URL: <http://dx.doi.org/10.21474/IJAR01/9796>



### RESEARCH ARTICLE

#### PROSTHETIC REHABILITATION OF UNILATERAL CONGENITALLY MISSING EAR- A CASE REPORT.

Nimmi Gupta,<sup>1</sup> Vandita Srivastava<sup>2</sup> and Neteesh K Shukla<sup>3</sup>.

1. MDS, Prosthodontics faculty of dental sciences, IMS BHU.
2. Professor, Prosthodontics faculty of dental sciences, IMS BHU.
3. MDS., Orthodontics faculty of dental sciences, IMS BHU.

#### Manuscript Info

##### Manuscript History

Received: 16 July 2019

Final Accepted: 18 August 2019

Published: September 2019

##### Key words:-

Auricular prosthesis, silicone material, spectacle retention.

#### Abstract

Loss of facial structures may be congenital or acquired. These maxillofacial defects can be rehabilitated by the prosthesis and/or cosmetic surgeries. Success of the prosthesis depends upon its retention. With the advancements, implants have served better option in terms of retention. Silicone are widely used material as compared to acrylic. This article describes a simple process to rehabilitate auricular defects with silicone prosthesis of simple retention mechanism with the help of spectacle and earring which is aesthetically and economically helpful for the patient. This method avoids cumbersome procedures used by other means.

Copy Right, IJAR, 2019,. All rights reserved.

#### Introduction:-

Auricular defects are mainly due to congenital causes or acquired due to surgical resection of tumour, burn, and trauma. Auricular defects stands most common after cleft defects. Auricular defects those are presented with younger age group brings more of functional, emotional, and aesthetic concerns. Prosthetic replacement of the missing ear provides the patients self-esteem, confidence, and improves their quality of life.<sup>[1]</sup> Attainment of higher rate of success in terms of retention of these auricular prosthesis is most challenging for a prosthodontist. Retention can be obtained by mechanical (implants, spectacles, hair bands, modified earrings) means or chemical like silicon adhesive.<sup>[2-5]</sup> Apart from various treatment options like mechanically and chemically retained prosthesis, the recently developed technique is rapid prototyping, and Computer Aided Designing – Computer Aided Machining (CAD-CAM) developed prosthesis.<sup>[6-7]</sup> This article describes the clinical and laboratory procedures for fabricating mechanically retained auricular prosthesis using spectacle and piercing silver pin for a male patient who have congenital unilateral ear defect.

#### A case report

A 54 year old male patient came to our prosthodontics unit with the chief complaint of dust entrapment in the congenitally malformed left ear, patient was not much concerned for aesthetics and wanted just to cover the defect site with the prosthesis. On taking case history and examination only lobule and tragus was found in left side with closed external auditory meatus due to which patient had hearing problem in left ear [figure 1]. Patient had recurrent infection in the deformed ear for which he underwent surgery and hearing aid was placed internally. Implant retained prosthesis as a treatment option was offered to the patient but patient was not ready. As patient was spectacle wearer, so it was comfortable and easier to proceed. Before proceeding a signed consent form was taken. Patient wanted surgical excision of hanging ear lobule, and simple surgical removal was done successfully.

**Corresponding Author:-Nimmi Gupta.**

Address:-MDS, Prosthodontics faculty of dental sciences, IMS BHU.

Figure 1- Pretreatment photograph; 1a- right normal ear, 1b- frontal facial photograph, 1c-left defective ear.

### Steps in fabrication of prosthetic ear

Combination of donor method and sculpting method was used to fabricate the prosthesis. Tissue undercut was used to aid in retention.

### Impression procedure

First we made impression of normal ear by irreversible hydrocolloid by blocking the meatus with gauge and after applying petroleum gel around hairs. Wax pattern was made to see anatomy of ear to be replaced even in the absence of the patient [figure 2a]. Then similarly we made impression of donor ear from one of our student that simulated the patient's ear to a greater extent [figure 2b]. Wax pattern thus obtained was sculpted and carved to match the patient's normal ear [figure 2c]. Impression of the defect is obtained from irreversible hydrocolloid (alginate) after applying petroleum jelly and patient was asked to wear spectacle to get it into impression [figure 2d]. Cast is poured with die stone where indentation have been recorded [figure 2e]. Later we place the orientation lines on face [figure 3a]. This was done for final positioning of wax trial. After that wax try-in is done for the left auricular defect for its proper positioning, and its position is matched with opposing ear for symmetry [figure 3b]. Also groove was made in the wax up for spectacle attachment.

Figure 2- Impression procedure; 2a- wax pattern of the normal right ear, 2b- impression of donor ear, 2c- wax pattern of the donor ear after sculpting, 2d- impression of the defect site, 2e- cast of the defect site.

### Mold Making

A three piece mold is required for auricular prosthesis [Figure 3c]. Type 3 gypsum product (dental stone) and type 2 gypsum product (plaster of paris) was used. Keyways are made in the master cast around wax pattern in different location. Separating media is applied over it. Dental stone is poured in posterior part of wax pattern, extending to the helix. Again keyways are prepared in different location of the second piece mold. Every effort is made to prevent undercut. Coat with separating media over posterior mold and remaining portion of cast. Place the middle portion of flask and pour the third mix over it with plaster of paris. Close the flask also place it under clamp to remove excess gypsum product. After it has set, dewaxing is carried out by soaking flask in boiling water for five minutes. On opening the flask it is washed with hot water to remove any wax left behind.

Figure 3- wax pattern trial and mold making; 3a- orientation lines, 3b- wax pattern final trial, 3c- three piece mold.

### Silicone Mixing

In the presence of patient we mix RTV (room temperature vulcanising) silicone (MP Sai, Enterprise) with the intrinsic stains (MP Sai, Enterprise) to match shade. Opacity is achieved by mixing white silicone paste. After this packing of mold is done and flask is closed and placed under clamp to remove excess material. Mold is kept for minimum of 24 to 48 hours at room temperature for curing.

### Extrinsic colouring and mechanical retention of prosthesis

Prosthesis was tried in for proper positioning and final adjustments were made for colour as well. Pigments are applied with help of brush to obtain desired shade of skin. Finally spectacle was attached in groove with cyanoacrylate glue [figure 4a, 4b]. A prosthesis did not retain well due to bony overgrowth [figure 4c]. Finally decision was made to get retention from tragus by piercing through prosthetic ear and placing silver simple earring pin [figure 4d].

Figure 4- final prosthesis retention and delivery; 4a and 4b – spectacle attachment to the auricular prosthesis, 4c and 4d- earring retention provided to prosthesis.

### Prosthesis delivery and Instructions to the patient

Finally prosthesis was delivered with proper retention and patient was very happy with it. Patient could very easily wear and remove prosthesis. Patient was advised to clean prosthesis with soft brush and mild warm water. Remove it while sleeping and participating in sports. Also sun exposure and water contact is avoided. Prosthesis is to be kept in dry and safe place, patient is advised to come for follow up and repair of prosthesis when required.

**Discussion:-**

Maxillofacial defects brings emotional, social, functional and aesthetics trauma to the patients. Prosthetic rehabilitation of maxillofacial defects are most challenging. Position, shape and amount of defect plays important role. We achieve good aesthetics with silicone material as compared to acrylic although being costlier than acrylic. [8] Various retention mechanism are available in which implants hold high success rate but due to surgical intervention procedure and high cost it was relatively less acceptable to the patient. [2] Bio-adhesives are used as a retention material because it is easy to use but being unable to provide longevity and its cumbersome maintenance it is not generally not chosen as a treatment option. [5] Compared to above stated retention mechanism, Spectacle retention was chosen for retention because patient was spectacle wearer and was economical to the patient. In terms of comfort to patient it is relatively better as patient can easily remove the prosthesis and maintain cleanliness. Additional earring was used to achieve greater retention in simple manner. [3]

**Conclusion:-**

Spectacle retained silicone ear prosthesis with additional earring retention is economical for patient. It provides good aesthetics and retention of prosthesis. It brings satisfactory results to both patient and prosthodontist.

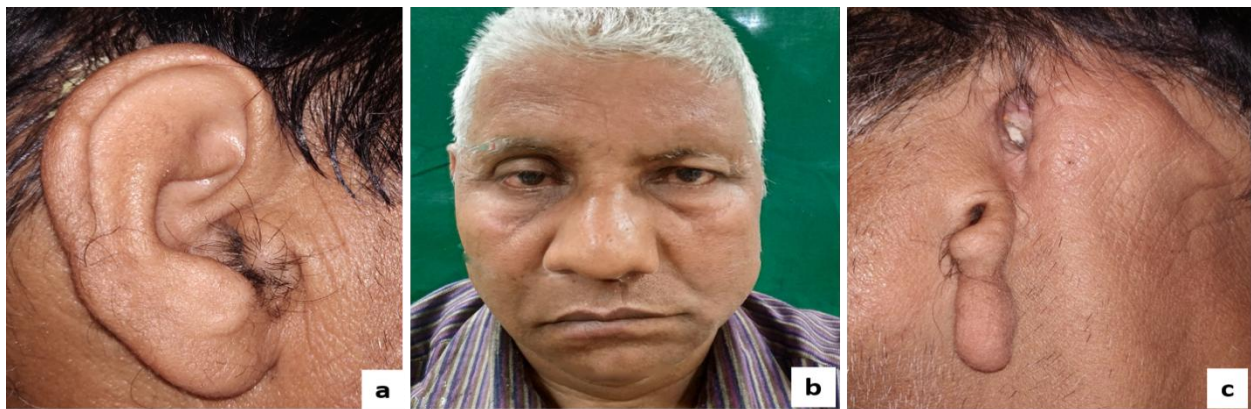

Figure 1(a,b,c):-

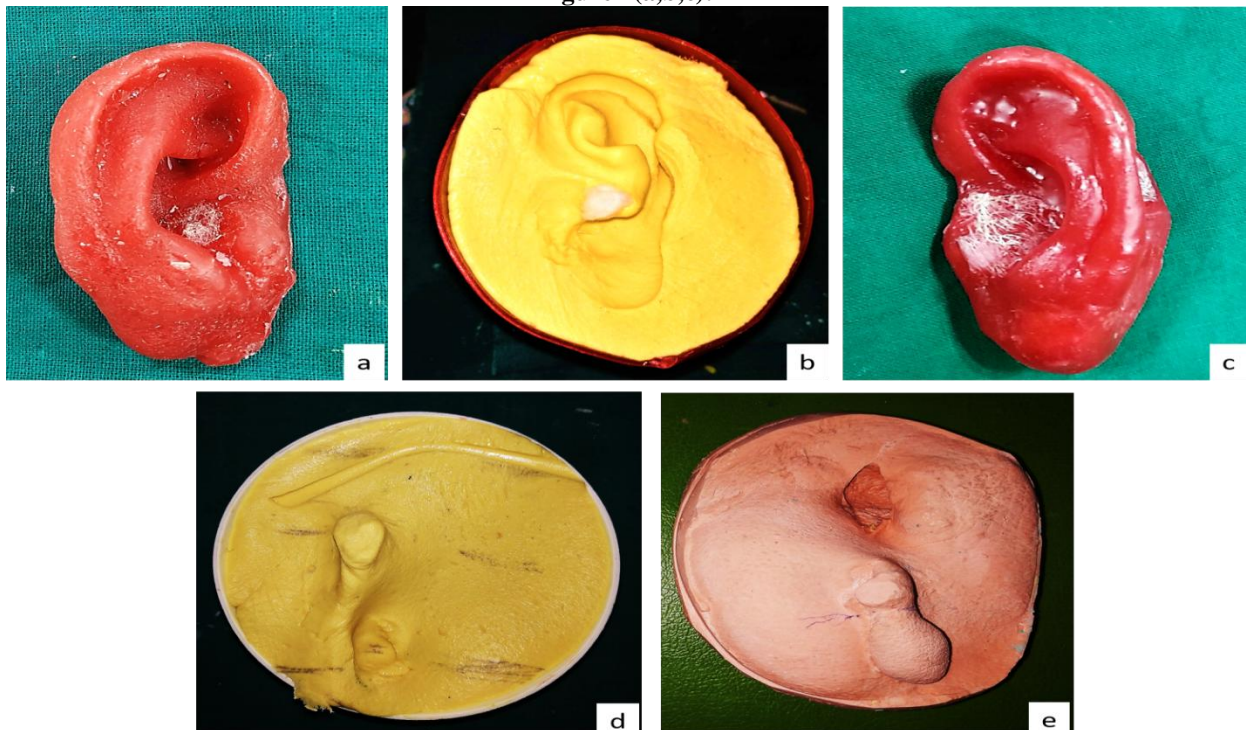


Figure 2(a,b,c,d,e):-

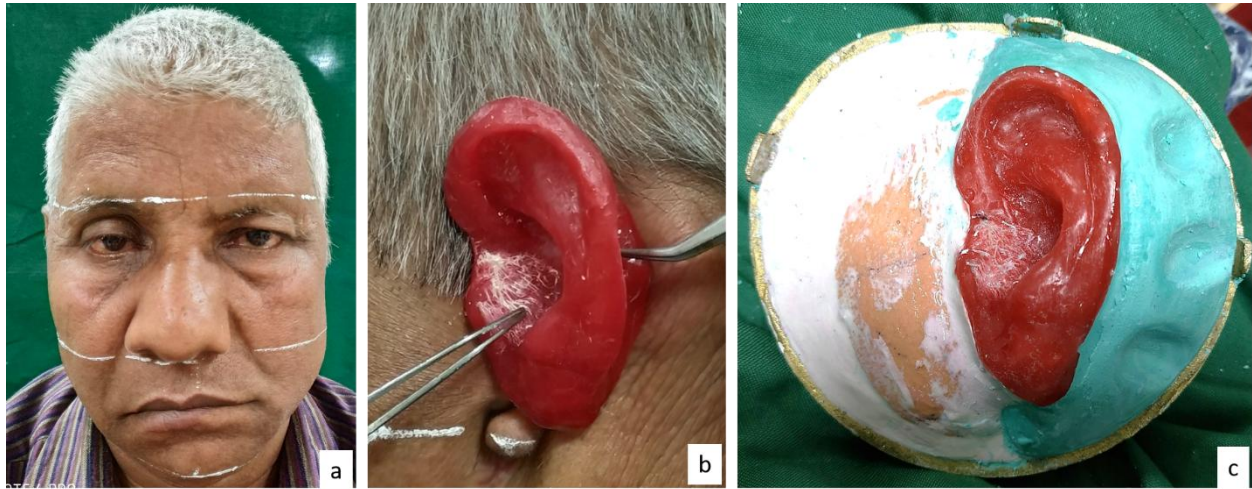


Figure 3(a,b,c):-

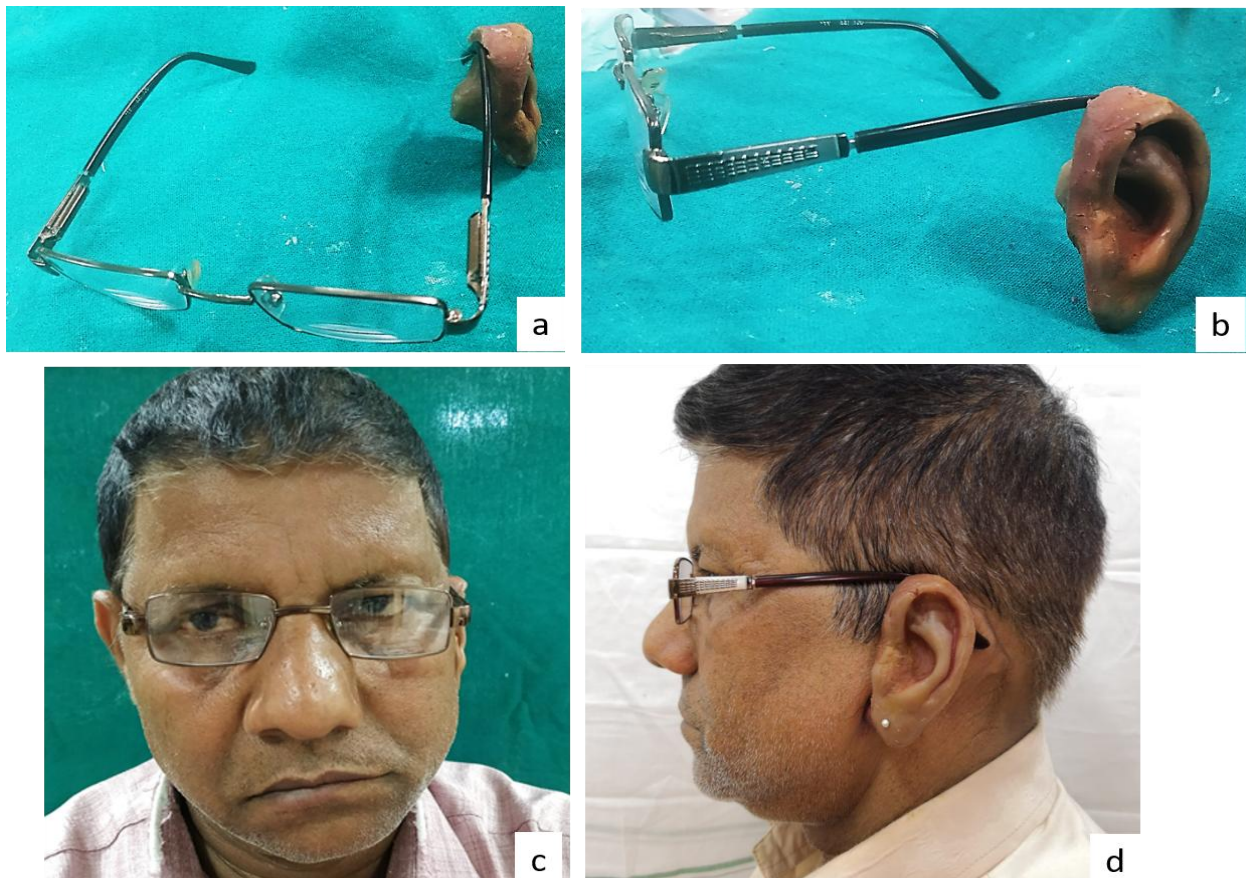

Figure 4(a,b,c,d):-

**References:-**

1. Helen Collyer. Facial Disfigurement - Successful Rehabilitation. Macmillan International Higher Education, London, 06-Dec-1984.
2. A. Nilgun Ozturk, Aslihan Usumez, Zekeriya Tosun. Implant-Retained Auricular Prosthesis: A Case Report. Eur J Dent 2010;4:71-74.

3. Rajyalakshmi Ravuri, Bheemalingeshwarrao, Suchita Tella, Kiran Thota. Auricular Prosthesis-A Case Report. *J of Clin and Diagno Research* 2014;8(1):294-296.
4. C. Minati, N. Shanmuganathan, Bhakti S. Jain, T. V. Padmanabhan. Hair band retained prosthetic reconstruction of bilaterally missing ears: A case of congenital atresia of external auditory canals and pinna. *J of Prostho Research* 2014;58(1):62-67.
5. Tazeen Raees, Usha Radke, Nupur Shrirao, Runali Chavan . “Auricular Prosthesis Retained with Hair Clip and Earring: A Case Report”. *Acta Scientific Dental Sciences* 2.7 (2018): 110- 113.
6. Al Mardini M, Ercoli C, Graser GN. A technique to produce a mirror-image wax pattern of an ear using rapid prototyping technology. *J Prosthet Dent* 2005;94:195-8.
7. Sanghavi RV, Shingote SD, Abhang TN, Thorat PR, Vathare AS. An innovative technique for fabricating a mirror image wax pattern using three-dimensional printing technology for an auricular prosthesis. *SRM J Res Dent Sci* 2018;9:91-5.
8. Khindria SK, Bansal S, Kansal M. Maxillofacial prosthetic materials. *J Indian Prosthodont Soc* 2009;9:2-5.