



Journal Homepage: -www.journalijar.com

INTERNATIONAL JOURNAL OF ADVANCED RESEARCH (IJAR)

Article DOI:10.21474/IJAR01/10194

DOI URL: <http://dx.doi.org/10.21474/IJAR01/10194>



RESEARCH ARTICLE

A POSSIBLE GASTROPROTECTIVE AND IN VITRO ANTI-OXIDANT EFFECT OF HIBISCUS AGAINST EXPERIMENTALLY INDUCED ULCER IN RATS

P.Sailaja Rao¹ and V. Ravi Kumar²

1. Associate Professor, Department of Pharmacology, S V College of Pharmacy, Hyderabad, Telangana State, India.
2. Associate Professor, Department of Pharmacology, M.N.R. College of Pharmacy, Sangareddy, Telangana State, India.

Manuscript Info

Manuscript History

Received: 08 October 2019

Final Accepted: 10 November 2019

Published: December 2019

Key words:-

Anti-ulcer, Hibiscus Tiliaceus, Anti-Oxidant, Ethanol, Phytochemical Constituents

Abstract

The anti-ulcer activity of methanolic extract of whole plant *Hibiscus tiliaceus* (Malvaceae) was investigated in ethanol induced ulcer model in wistar rats. Ulcer index was used as the common parameter to determine the activity. Maceration was the extraction procedure used. Then, the extract was screened for the presence of phytochemical constituents. In-vitro anti-oxidant studies were performed using H₂O₂ radical scavenging and reducing power assay. Albino rats of either sex weighing between 160-250 gms were divided into five groups of six animals each (n=6). The in-vitro anti-oxidant studies revealed that the inhibitions were statistically significant (p < 0.05). The methanolic extract at doses 200 mg/kg and 400 mg/kg p.o produced significant inhibition of the gastric lesions produced by ethanol. It also significantly (P<0.05) reduced gastric volume, free acidity and ulcer index as compared to positive control and standard drug treated animals. The obtained data suggested that methanolic extract possess potent anti-ulcer activity, which might be due to its anti-secretory activity. The presence of flavanoids in the extract supports its activity. Thus, the present investigation concluded that the methanolic extract of *Hibiscus tiliaceus* is possessed anti-oxidant and anti-ulcer property.

Copy Right, IJAR, 2019.. All rights reserved.

Introduction:-

Globally, peptic ulcer is serious public health problem that affects about 5-10% of population, with high rate of morbidity and mortality; need to be focused on experimental and clinical investigations (Alkofahi A and Atta, 1999). Usually, peptic ulcers are aggravated by an imbalance between destructive and defensive factors in the stomach (Peskar B M and Maricic, 1998). In the treatment of peptic ulcers, control over the acidic hypersecretion is critical, and the conventional drugs chosen have direct effects on the gastric mucosa (Toma W et al., 2005).. The two main classes of drugs used to treat acid-related disorders include proton pump inhibitors (PPI) that inhibit the hydrogen pump in the parietal cell directly, independently of any membrane receptor stimulation, and histamine type 2 receptor antagonists (H2RAs), which block the histamine receptor on parietal cells thereby reducing hydrogen ion release. Long-term use of H2RAs is associated with the development of undesirable effects such as gynecomastia and galactorrhoea as well as alteration of the bacterial flora of the gastrointestinal tract (Borelli F and Izzo A A, 2000).

Corresponding Author: -V. Ravi Kumar

Address:-Associate Professor, Department of Pharmacology, M.N.R College of Pharmacy, Sangareddy, Telangana State, India

There are two types of factors which are responsible for the ulcers. The endogenous destructive factors in the stomach are HCl, pepsin, biliary reflux, lipid peroxidation, and the formation of reactive oxygen species (ROS). The exogenous factors are excessive use of ethanol, indiscriminate use of non steroidal anti-inflammatory drugs (NSAID), stress, smoking, and infection by *Helicobacter pylori* bacteria. The defensive factors are mucus-bicarbonate barrier, mucin secretion, surface phospholipids, prostaglandins (PGs), nitric oxide (NO), mucosal blood flow, cell renewal, growth factors, and antioxidant enzymes (Zhongzhi W et al., 2011). Oxidative stress, present in the process of gastric ulceration, increases the formation of ROS that can disrupt epithelial cell integrity. In addition, ROS accumulates neutrophils in the tissues of the mucosa during gastric ulceration. Studies have shown that pro-inflammatory cytokines induce the activation of neutrophils and are strong contributors to the of ulcer damage (Melese E, 2011).

Hibiscus tiliaceus Linn is a plant which belongs to the family Malvaceae, commonly known as “bola” exists as herb, shrub and around 250 species of same genus were found in tropical and subtropical regions of the world, out of which out 40 species occur in India. Since ancient times *Hibiscus* spp were used as folk remedies for various disorders (Borhede P S et al., 2011). In folk medicine, the leaves of this plant used to treat fevers, soothe coughs, ulcer, wounds and various skin diseases. The various phytochemicals isolated from plant are hibiscusin, hibiscus amide, vanillic acid, Phydroxybenzoic acid, syringic acid, P-hydroxybenzaldehyde, scopoletin, N-trasferuloyltyramine, N-cis-feruloyltyramine, β -sitosterol, stigmasterol, β -stigmasterone, hibiscolactone, hibiscones, hibiscoquinones, lapachol, gossypol, gossypetin, manosonones, hyperoside, kaempferol, quercetin, gossypitin, gossytrine, para-coumaric and fumaric acid Sharma M C et al., 2010).

The presence of these phytochemical constituents in plants, exert a beneficial effect on health by different actions such as antioxidant, anti-inflammatory, and modulating gene expression. In fact, the intake of antioxidants from the natural source such as fruits and vegetables can provide protection against oxidative stress. Keeping in view of the use of this in ethnomedicine, the present study was taken up to investigate the effect of methanolic extract of whole plant *Hibiscus tiliaceus* on ethanol induced gastric ulcers in rats to determine its effect on gastric secretion, development of gastric ulcers in rats and also involves in-vitro antioxidant activity.

Materials and Methods:-

Collection of plant material:-

The whole plant of *Hibiscus tiliaceus* was collected from the local market in kukatpally, telangana, India which was identified and authenticated by Prof. Suresh babu, Dept. of botany, Govt. Degree College, Kukatpally.

Preparation of extract: (Dhandapani R and Sabna B, 2008):

The whole plant species were collected and then dried under shade for a period of three weeks. The dried plant material was milled to a fine powder using commercial laboratory blender and were stored in air tight containers until extraction.

Maceration was a simple widely used procedure involves leaving the pulverized plant to soak in a suitable solvent in a closed container. Simple maceration was performed at room temperature by mixing the ground drug with the solvent (drug solvent ratio 1:5 or 1:10), methanol was used as a solvent.

Preliminary Phytochemical Screening (Kokate, 2001):

Methanolic extract of *Hibiscus tiliaceus* (MEHT) was screened for the presence of various phytoconstituents like alkaloids, flavanoids, steroids, tannins, glycosides, triterpenoids and saponins.

Tests carried out for different phytochemical constituents:

Methanolic extract of *Hibiscus tiliaceus* (MEHT) was subjected to preliminary phytochemical investigations to identify various phytoconstituents present in whole plant according to the method.

Test for alkaloids:

A small portion of crude extract was dissolved in 5 ml of 1% hydrochloric acid, filtered and tested with Dragendorff's reagent and Mayer's reagent separately. Any precipitate or turbidity with the reagents suggested the presence of alkaloids.

Test for flavonoids:

A few drops of conc. hydrochloric acid and 1-2 magnesium turnings were added to 1 ml of methanolic extract. The presence of flavonoids was indicated by the development of pink or magenta-red colour.

Test for phenols (Ferric chloride test):

A fraction of the extracts was treated with aqueous 5% ferric chloride and observed for formation of deep blue or black color.

Test for amino acids and proteins (1 % ninhydrin solution in acetone):

2 ml of filtrate was treated with 2-5 drops of ninhydrin solution placed in a boiling water bath for 1-2 minutes and observed for the formation of purple color.

Test for carbohydrates (Molisch test):

To a fraction of extract α -naphthol and alcohol was added. It was mixed well and conc. sulphuric acid was added drop by drop by keeping the test tube in inclined position. Violet ring is formed at the junction of two layers which shows the presence of carbohydrates.

Test for saponins (Foam test):

To 2 ml of extract was added 6 ml of water in a test tube. The mixture was shaken vigorously and observed for the formation of persistent foam that confirmed the presence of saponins.

Test for sterols (Liebermann-Burchard test):

2 ml of extract was treated with drops of chloroform, acetic anhydride and conc. H_2SO_4 and observed for the formation of dark pink or red colour.

Test for tannins (Braymer's test):

2 ml of extract was treated with 10% alcoholic ferric chloride solution and observed for formation of blue or greenish colour solution.

In vitro anti oxidant assay:

Methanolic extract of *Hibiscus tiliaceus* (MEHT) was tested for in-vitro antioxidant activity using standard methods. Amongst them, two methods were chosen for the present study. The absorbance was measured spectrophotometrically against corresponding blank solution. The percentage inhibition was calculated by the following formula.

$$\text{Radical scavenging activity (\%)} = \frac{OD \text{ Control} - OD \text{ Sample}}{OD \text{ Control}} \times 100$$

IC_{50} which is the concentration of sample required to scavenge 50% of the free radicals was calculated. IC_{50} was calculated from equation of line obtained by plotting a graph of concentration versus % inhibition. H_2O_2 radical scavenging assay (Zamora Z B, 2007)

Hydrogen peroxide is a weak oxidizing agent and can inactivate a few enzymes directly, usually by oxidation of essential thiol (-SH) groups. Hydrogen peroxide can cross cell membranes rapidly, once inside the cell, H_2O_2 can probably react with Fe^{2+} , and possibly Cu^{2+} ions to form hydroxyl radical and this may be the origin of many of its toxic effects. It is therefore biologically advantageous for cells to control the amount of hydrogen peroxide that is allowed to accumulate.

Preparation of reagents:

1. Phosphate buffer solution pH 7.4: Add 250.0 ml of 0.2 M potassium dihydrogen phosphate to 393.4 ml of 0.1 M sodium hydroxide and make up the volume to 1000 ml with the distilled water.
2. Potassium dihydrogen phosphate (0.2M) solution: Potassium dihydrogen phosphate (2.72 g) was dissolved in distilled water and volume made upto 100 ml.
3. Sodium hydroxide solution (0.1M) solution: 0.4 g of sodium hydroxide was dissolved in distilled water and volume made upto 100 ml.

Method:-

A solution of hydrogen peroxide (2 mmol/l) was prepared in phosphate buffer (P^H 7.4) Test compounds (10–50 µg/mL) were added to hydrogen peroxide solution (0.6 ml). Absorbance of hydrogen peroxide at 230 nm was determined after 10 min against a blank solution containing phosphate buffer without hydrogen peroxide and compared with ascorbic acid, the reference compound.

Reducing Power Assay (Cabral B, 2016):

This method was based on the principle of increase in the absorbance of the reaction mixtures. Increase in the absorbance indicates an increase in the antioxidant activity. In this method, substances, which have reduction potential, react with potassium ferricyanide (Fe³⁺) to form potassium ferrocyanide (Fe²⁺), which then reacts with ferric chloride to form ferric ferrous complex that has an absorption maximum at 700 nm.

Potassium ferricyanide + Ferric Chloride → Potassium ferrocyanide + Ferrous Chloride

Preparation of reagents:

1. Phosphate buffer pH 6.6: Potassium dihydrogen phosphate (62.5 ml 0.2 M) was added to 250 ml volumetric flask and also 20.5 ml of 0.2 M NaOH and made upto volume 250 ml with distilled water.
2. Phosphate (0.2 M) solution: Potassium dihydrogen phosphate (2.72 g) was dissolved in distilled water and volume made upto 100 ml.
3. Sodium hydroxide solution (0.2 M) solution: 0.8 g of sodium hydroxide was dissolved in distilled water and volume made upto 100 ml (Saumya SM et al., 2011).
4. Potassium ferricyanide (1% w/v) solution: Potassium ferricyanide (1g) was dissolved in water and volume made upto 100 ml in volumetric flask.
5. Ferric chloride solution (0.1% w/v): Ferric chloride (25 mg) was dissolved in distilled water and volume made up to 25 ml in volumetric flask.

Method:-

To 1 ml of test and standard compounds added 2.5 ml of potassium ferricyanide (1 % w/v), 2.5 ml of phosphate buffer (pH 6.6) and incubated at 50^o C for 30 min. To 2.5 ml of above supernatant liquid, added 2.5 ml of distilled water and 0.5 ml of FeCl₃ solution (0.1% w/v). The absorbance of ferric ferrous complex was measured using phosphate buffer pH 6.6 as control at 700 nm using UV-Visible spectrophotometer and estimated the increase in absorbance.

Acute Toxicity Studies of METS (OECD):

Acute toxicity studies were performed according to the OECD 425 guidelines.

Female Wister rats weighing 100-150g were selected and divided into four groups containing three animals in a group. Depending on the mortality or morbidity of animals a few steps may be necessary to judge the toxicity of the test substance. Minimal usage of animals while it allows for acceptable data is the main advantage of this method. The single dose of the ethanolic extract starting from 5 mg/kg up to 2000 mg/kg (5, 50, 300, 2000mg/kg) was administered orally. The starting dose of the ethanolic extract of *Hibiscus tiliaceus* L was 2000 mg/kg (p.o). The drug treated animals were carefully observed individually for the toxicity signs and mortality upto 14 days.

Animals:

Animal Protocol was approved by IAEC (Institutional Animal Ethical Committee) of CPCSEA (Committee for Purpose of Control and Supervision of Experimentation on Animals) through its reference no: IAEC/MNRCP/2018/002, Dated: 27/2/18. Male Wistar rats, weighing (180-250 gms) were obtained from NIN (National Institute of Nutrition, Hyderabad). The animals were acclimatized to the experimental room at a temperature of 23±2^o C, controlled humidity conditions (50-55%) and 12 hr light and 12 hr dark cycles. They were fed with standard food pellets (Hindustan Lever, Hyderabad) and water ad libitum.

Experimental protocol:

Albino rats of either sex weighing between 160-250 gms were divided into five groups of six animals each (n=6).

Group I Control (Saline)

Group II Ethanol (1 ml/200g)

Group III Standard (Ranitidine 150 mg/kg)

Group IV Methanolic extract of *Hibiscus tiliaceus* (200 mg/kg)

Group V Methanolic extract *Hibiscus tiliaceus* (400 mg/kg)

Ethanol induced ulcer model (Raju D, 2009):

Albino Wistar rats were divided into five groups of 6 animals each. All animals received treatment for 5 days. Group-I served as normal control, received 0.9% normal saline solution (1ml/kg b. wt), Group II: disease control received ethanol (90% v/v, 1 ml/200g), Group III: received with MECM of 200 mg/kg body weight, p.o., Group IV: received MECM of 400 mg/kg body weight, p.o., and Group V served as a standard group which received Ranitidine 150 mg/kg p.o. Gastric ulcers were induced in rats by administration of 1ml 90% v/v ethanol p.o. Animals were fasted for 24 h with free access to water prior to the test. MECM and the standard drug (Ranitidine) were given orally 30 minutes before administration of ethanol (90% v/v, 1 ml/200g) and were sacrificed after 15 minutes. The stomach was dissected out, gastric juice was collected, and its volume was measured. The free and total acidity was also determined. The stomach was opened along the greater curvature, rinsed under a stream of water and pinned flat on a corkboard. Erosions formed on the glandular portion of stomach were counted and each was given a severity rating on 1-3 scale, based on diameter of the ulcer. The overall total diameter of ulcers in one stomach divided by factor 10 was designated as ulcer index (UI).

Evaluation of parameters:

Collection of gastric juice:

The stomach was excised carefully opened along the greater curvature and the gastric contents were removed. The gastric contents were collected in plain tubes and centrifuged at 3000 rpm for 5mins; the volume of the supernatant was expressed as ml/100 gm body weight. The mucosa was flushed with the saline and observed for gastric lesions using a dissecting microscope, ulcer score was determined.

Ulcer scoring:

After sacrificing the rat, stomach was removed and opened along the greater curvature, and washed slowly under running tap water. Then keep it on the glass slide and observed under 10X magnification for ulcer. Score the ulcer as below.

1. 0 - Normal stomach
2. 0.5 - Red coloration
3. 1 - Spot ulcers
4. 1.5 - Hemorrhagic streaks
5. 2 - Ulcer >3mm but <5mm
6. 3 - Ulcers >5mm

Mean ulcer score for each animal was expressed as ulcer Index.

Free acidity and Total acidity:

One ml of gastric juice was pipette in to a 100 ml conical flask and titrated with 0.01N NaOH using topfers reagent as an indicator. It is Dimethyl-amino-azo-benzene with phenolphthalein, used for the detection and estimation of hydrochloric acid and total acidity in gastric fluids. The end point was to orange color. Noted the volume of NaOH which responded, and continued with titration further till the solution regained its pink colour. Noted the volume of NaOH which corresponded to the free acidity. Acidity (mEq/L/100g) was expressed as $\text{Acidity} = \frac{\text{Volume of NaOH} \times \text{Normality of NaOH}}{0.1 \times 100}$

Statistical Analysis:

The statistical analysis is carried out using analysis of variance (ANOVA), followed by Dunnett's test. P values < 0.05 considered as significant.

Histopathological Studies:

One animal of each group was euthanized at the end of experiment. Gastric tissue samples from each group were fixed in 10% formalin for 24 h. The specimens were then embedded in paraffin, sectioned and stained with hematoxylin and eosin, before being evaluated by light microscopy. Open excised stomach was also observed for histopathological study.

Results and Discussion:-

Percentage yield of plant extract:

The yield obtained from the methanolic extract of *Hibiscus tiliaceus* L. was about 50 g which was obtained from 1000 g. % Yield = Actual yield/Theoretical yield X 100% Yield = 50/1000 X 100 The percentage yield of extract = 5%

Preliminary Phytochemical screening:

The results of preliminary phytochemical screening of the methanolic extract of *Hibiscus Tiliaceus* L. were given in table 1. It showed the presence of

1. Flavonoids
2. Glycosides
3. Tannins
4. Saponins
5. Triterpenoids

Table 1:- Preliminary screening for phytochemical constituents in methanolic extract of *Hibiscus tiliaceus* L.

S.No	Tests for different chemical constituents	Absent/Present
1.	Test for carbohydrate	Absent
2.	Test for Alkaloids	Absent
3.	Test for Flavanoids	Present
4.	Test for Glycosides	Present
5.	Test for triterpenes	Present
6.	Test for Tannins	Present
7.	Test for Saponins	Present
8.	Test for Proteins	Absent

Table 2:- % inhibition of methanolic extract of *Hibiscus tiliaceus* in Hydrogen peroxide (H₂O₂) scavenging assay.

S. No	Group	Dose (µg/ml)	% inhibition	IC50 value (µg/ml)
I	Ascorbic acid	50	11.20 ± 0.58	
		100	17.2 ± 0.06	
		200	38.0 ± 1.17	
		300	54.01 ± 0.16	42 ± 0.18
		400	72.01 ± 0.18	
		500	95.60 ± 0.37	
II	Methanolic extract of <i>Hibiscus tiliaceus</i> L.	50	8.08 ± 2.4	
		100	20.07 ± 1.18	
		200	38.89 ± 1.72	45 ± 0.16
		300	50.59 ± 2.40	
		400	76.24 ± 1.82	
		500	78.61 ± 1.63	

^ap < 0.0001 considered as significant; compared with corresponding standard

Table 2:- Absorbance of for methanolic extract of *Hibiscus tiliaceus* and standard Ascorbic acid at various concentrations in Reducing Power Assay.

Concentration (µg/ml)	MEHL	Ascorbic acid
50	0.20 ± 0.004*	0.45 ± 0.003
100	0.24 ± 0.003*	0.40 ± 0.005

200	0.76±0.006*	1.06±0.005
300	1.02±0.004*	1.79±0.003
400	1.40±0.005*	1.89±0.004
500	1.88±0.005*	2.52±0.002

^ap<0.0001 considered as significant; compared with corresponding Standard

In the determination of anti-oxidant property of the methanolic extract of *Hibiscus tiliaceus* using H₂O₂ assay, the IC₅₀ value of the test extract showed 45±0.16 µg/ml, where as the standard Ascorbic acid (positive control) was found to be 42±0.18 µg/ml, which was commonly used as a standard for anti-oxidant activity. Similarly, in the reducing power assay method, the reducing power of extract was determined and compared to standard used; absorbance with increased concentration significantly increased the reducing power. The test extract exhibited significant (p<0.0001) reducing ability. MEHT reduced the generation of free radicals, showed the absorbance of 1.88 indicated good (p<0.0001) reducing ability power which was comparable to Ascorbic acid.

Biologically active antioxidants may help protect the gastric mucosa against cell damage caused by oxidative stress, as well as enhance the defense systems against degenerative diseases. Studies have associated the administration of antioxidants (synthetic or natural) with protection of the gastric mucosa against necrotic agents, including ethanol and non steroidal anti-inflammatory drugs. The in vitro antioxidant study showed that the methanolic extract of *Hibiscus tiliaceus* contains classes of bioactive compounds involved in antiulcer processes, and this observation may contribute to the justification of its use in traditional medicine.

Table 3:- Effect of test extracts on gastric mucosal factors in experimentally induced gastric ulcer in rats.

Groups	Treatment	Vol of gastric juice	pH	Free acidity	Total acidity
I	Control	1.69±0.09	5.50±0.09	14.33±2.57	27.38±0.25
II	Control (Ethanol ml/200g)	4.22±0.32*	2.3±0.47*	19.8±1.5*	39.8±2.5*
III	Ethanol+ Ranitidine	2.20±0.22*	6.33±1.01*	8.4±1.7*	16.46±2.8*
IV	Ethanol+Methanolic extract of <i>Hibiscus tiliaceus</i> (200 mg/kg)	3.12±0.15*	4.83±0.9*	12.7±2.1*	24.7±3.1*
V	Ethanol+Methanolic extract of <i>Hibiscus tiliaceus</i> (400 mg/kg)	2.50±0.26*	5.7±0.75*	10.5±1.5*	19.5±1.5*

Values were showed as the mean ± SEM. *p < 0.05 compared with the control, ethanol and ethanol+standard group.

Table 4:- Effect of test extracts on ulcer index in experimentally induced gastric ulcer in rats.

Grps	Treatment	Ulcer Index	% protection
I	Control	-----	-----
II	Control (Ethanol 1 ml/200g)	7.33± 0.33	-----
III	Ethanol+ Ranitidine	1.84±0.15*	74.89
IV	Ethanol+Methanolic extract of <i>Hibiscus tiliaceus</i> (200 mg/kg)	2.78±0.29*	62.12
V	Ethanol+Methanolic extract of <i>Hibiscus tiliaceus</i> (400 mg/kg)	2.10±0.19*	71.23

Values were showed as the mean ± SEM. *p < 0.05 compared with the control, ethanol and ethanol + standard rats

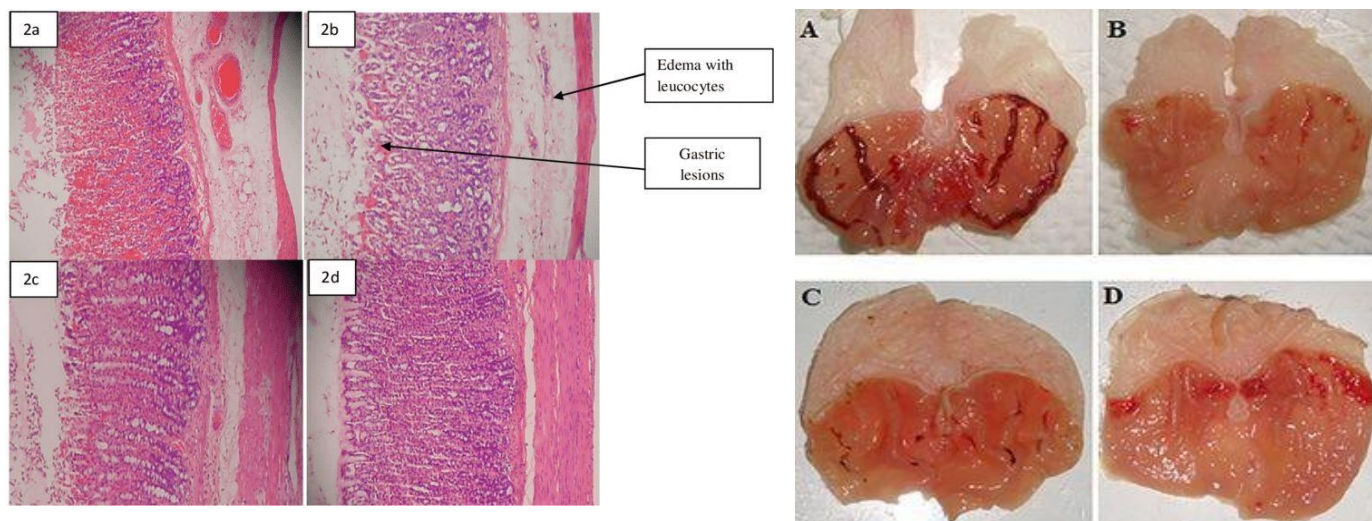


Fig 1:-Explains - I) Open excised stomach in ethanol induced gastric lesions model.

1. Ethanol (1 ml/200 g) damaged mucosal epithelium was observed
2. In Ranitidine (150 mg/kg) treated, no damaged to epithelium was observed
3. In MEHT (200mg/kg) treated, apparent epithelisation was observed
4. In MEHT (400mg/kg) treated, apparent epithelisation was observed
5. Gastric lesions induced by Ethanol(1ml/ 200 g)
6. Absence of gastric lesions in Ranitidine (150 mg/kg)
7. Fraction inhibition in gastric lesions at 200mg/kg of MEHT
8. Inhibition in gastric lesions at 400mg/kg of MEHT

Histopathological examination of open excised stomach in ethanol induced ulcer model:

In the present study, the anti-ulcerative effects of methanolic extract of *Hibiscus tiliaceus* was investigated in ethanol-induced gastric ulcer rat model.

Effect on gastric volume:

Administration of the test extract at both the doses (200 and 400 mg/kg) significantly decreased ($*p < 0.05$) the gastric volume in comparison with control ethanol rats and rats treated with ranitidine. Also there was a significant increase in pH in both the extract treated animals (200 and 400 mg/kg), and it was more prominent with the higher dose.

Effect of Free acidity and Total acidity:

The free acidity and total acidity was determined based on the titer values. The free acidity and total acidity in extract treated rats was ($*p < 0.05$) decreased significantly in comparison with the standard group treated with ranitidine.

Ulcer index:

The ulcer index was calculated by taking the mean ulcer score for each group. It was noticed that the ulcer index of dose groups treated with extract (200 and 400 mg/kg) was significantly less ($*p < 0.05$) when compared to the standard group treated with Ranitidine. *H.tiliaceus* in two doses caused a significant reduction in the UI and an improvement in the PI, indicating a possible involvement of the prostaglandin pathway.

Ethanol induced gastric hemorrhagic ulcer formation:

The macroscopic findings of the opened excised stomach were shown in fig 1 (I) which emphasizes that gastric ulcers covered with coagulated blood were more evident in the aspirin control group. There was inhibition of gastric ulcer with the extract treated group at the dose of 400 mg/kg. Secondly, the histopathological findings of gastric mucosa in aspirin treated rats revealed that there was an intact architecture, ulcers combined with distorted glands, a damaged epithelium, inflammatory exudates and cellular debris as showed in fig 1(II). In the test extract treated rats, there was an epitheliazation which indicated a repair of wounded area. Epitheliazation occurred in proliferative phase of wound healing.

The etiology of peptic ulcer unknown in most of the cases, yet it is generally accepted that it results from imbalance between aggressive factors and the maintenance of mucosal integrity through the endogenous defense mechanisms. To regain the balance, phytomedicines are used (in experimental animals) to inhibit the gastric acid secretion or to boost the mucosal defense mechanisms by increasing mucous production, stabilizing the surface epithelial cells, and enhancing prostaglandin synthesis (Mahattanadul S et al., 2009). The present results demonstrated that the methanolic extract of *Hibiscus tiliaceus* protected the rat gastric mucosa against hemorrhagic lesion produced by aspirin. This was a convenient way of screening plant extracts for anti-ulcer effect and cytoprotection in macroscopically visible lesions.

Hibiscus tiliaceus L. had significantly protected the gastric mucosa against ethanol challenge as shown by reduced values lesions compared to control group suggesting its potent cytoprotective effect (Matsumoto T et al., 2002). It showed a significant inhibition of gastric ulcer and also decreased mucosal parameters like acid concentration, gastric volume and increased the pH values. Hence, it was suggested that methanolic extract of *Hibiscus tiliaceus* L. can suppress the gastric damage induced by aggressive factors. The phytochemical screening of the extract of *Hibiscus tiliaceus* L. revealed the presence of flavonoids, tannins, glycosides, triterpenes and saponins (Bi W P, 2014). Any of these metabolites may be responsible for the antiulcer activity of *Hibiscus tiliaceus* L. Further, additionally the presence of terpenoids might be responsible for more effect on ulcer inhibition.

Conclusion:-

The test extract showed protection against mucosa against gastric lesions induced by ethanol. This antiulcer effect of MEHT may be due to both reductions in gastric acid secretion and gastric cytoprotection. However, further investigation is to be carried out to elucidate the exact mechanism of anti-ulcer activity through the use of additional experimental models.

Conflicts of interest:

The authors have no conflicts of interest with anyone.

References:-

1. Alkofahi A, Atta AH., Pharmacological screening of the antiulcerogenic effects of some Jordanian Medicinal Plants in rats. *J Ethnopharmacol.* 1999; 65: 341-5.
2. Bi W P, Man H B, Man M Q. Efficacy and safety of herbal medicines in treating gastric ulcer: A review. *World J Gastroenterol.* 2014; 20 (45): 17020-17028.
3. Borelli F, Izzo AA. The plant kingdom as a source of anti-ulcer remedies, *Phytother Res.* 2000; 14: 581-91.
4. Borhade PS, Dalal PS, Pachauri AD, Lone KD, Chaudhari NA, Rangari PK. Evaluation of anti-inflammatory activity of *Hibiscus tiliaceus* Linn wood extract. *Int J Res Pharm Biomed Sci.* 2012; 3(3):1246–1250
5. Cabral B, Siqueira E M S, Bitencourt M A O. Phytochemical study and anti-inflammatory and antioxidant potential of *Spondias mombin* leaves. *Revista Brasileira de Farmacognosia.* 2016; 26(3): 304–311.
6. Dhandapani R, Sabna B. Phytochemical constituents of some Indian medicinal plants. *Anc Sci Life.* 2008; 27(4):1–8
7. Kokate C K, Purohit A P, Gokhale S B. *Text Book of Pharmacognosy.* 33th Ed. Nirali Prakashan, 2001; Pune; 593-597.
8. Mahattanadul S, Nakamura T, Panichayupakaranant P, Phdoongsombut N, Tungsinmunkong K, Bouking P. Comparative antiulcer effect of bisdemethoxycurcumin and curcumin in a gastric ulcer model system. *Phytomedicine.* 2009; 16: 342-351
9. Matsumoto T, Sun XB, Hanawa T, Kodaira H, Ishii K, Yamada H. Effect of the antiulcer polysaccharide fraction from *Bupleurum falcatum* L. on the healing of gastric ulcer induced by acetic acid in rats. *Phytother Res.* 2002; 16: 91-93.
10. Melese E, Asres K, Asad M, Engidawork E. Evaluation of the antipeptic ulcer activity of the leaf extract of *Plantago lanceolata* L. in rodents. *Phytother Res.* 2011; 25: 1174-1180.
11. OECD, 425: Acute oral toxicity-fixed dose procedure. OECD Guidelines for Testing of Chemicals Section. 2001:1–14.
12. Peskar BM, Maricic N. Role of prostaglandins in gastroprotection. *Dig Dis Sci.* 1998; 43:S23-9.
13. Raju D, Ilango K, Chitra V, Ashish K. Evaluation of Anti-ulcer activity of methanolic extract of *Terminalia chebula* fruits in experimental rats. *J Pharm Sci Res.* 2009;1(3):101-107.

14. Sharma M C, Sharma S, Kohli D V. Phytochemical and anti-ulcer investigations of 95% ethanolic benzene-chloroform leaf extract of *Hibiscus tiliaceus* Linn. In albino rat model. *Annals of Biological Research*. 2010;1(1): 15-20.
15. Toma W, Hiruma-Lima CA, Guerrer RO Souza AR., Preliminary studies of *Mammea Americana* L (Guttiferae) bark/latex extract point to an effective antiulcer effect on gastric ulcer models in mice, *Phytomedicine*. 2005; 12: 345-50.
16. Zamora Rodríguez Z B, González Álvarez R, Guanche D. Antioxidant mechanism is involved in the gastroprotective effects of ozonized sunflower oil in ethanol-induced ulcers in rats. *Mediators of Inflammation*. 2007. 65873.
17. Zhongzhi Wang, Junichi Hasegawa, Xinhui Wang, Akiko Matsuda, Takahiro Tokuda, Norimasa Miura and Tatsuo Watanabe. Protective effects of Ginger against Aspirin induced gastric ulcers in rats. *Yonaga Acta Medica*. 2011; 54: 11-19.