



Journal Homepage: [-www.journalijar.com](http://www.journalijar.com)

## INTERNATIONAL JOURNAL OF ADVANCED RESEARCH (IJAR)

Article DOI: 10.21474/IJAR01/10394  
DOI URL: <http://dx.doi.org/10.21474/IJAR01/10394>



### RESEARCH ARTICLE

#### CARDIAC HYDATID CYST IN THE INTERVENTRICULAR SEPTUM

**B. Abdelaoui, A. Benbahia, Y. Malki, J. Safi, M. Ztati and M. Hattaoui**

Cardiology Department - CHU Mohammed VI - Marrakech.

#### Manuscript Info

##### Manuscript History

Received: 30 November 2019

Final Accepted: 31 December 2019

Published: January 2020

#### Abstract

Isolated cardiac location is an uncommon presentation of echinococcus (0.2 -3%), and involvement of the interventricular septum is even rarer. it may conduct to life-threatening complications including cyst rupture; anaphylactic shock; tamponade; pulmonary, cerebral or peripheral arterial embolism; acute coronary syndrome; dysrhythmias; infection; ventricular or valvular dysfunction, as well as sudden death. The diagnosis is based on a range of arguments, here we report the case of a 15years old girl who was diagnosed to have a hydatid cyst of the interventricular septum , the presentation, management and follow-up of the patient is discussed.

*Copy Right, IJAR, 2020.. All rights reserved.*

#### Introduction:

Hydatid disease is a zoonotic infection caused by the metacestode stage of *Echinococcus granulosus*, *E. multilocularis*, or *E. vogeli* (Taeniadae family). Humans can be infected as intermediary carriers after ingestion of the parasite eggs in unwashed or uncooked vegetables[1-2] cardiac involvement is not a common presentation in human echinococcosis, is seen in only 0.2-3% of patients with hydatid disease and the location of a hydatid cyst in the interventricular septum is just 4% of cardiac cases, it may conduct to life-threatening complications including cyst rupture; anaphylactic shock; tamponade; pulmonary, cerebral or peripheral arterial embolism; acute coronary syndrome; dysrhythmias; ventricular or valvular dysfunction, as well as sudden death.

The diagnosis is based on a range of clinical , biological specialy serogicals arguments combined with a cardiac imaging by various modalities like echocardiography which is highly sensitive and specific in the diagnosis of hydatid cysts .[1]

Here we reported a case of a 15 years old girl who was diagnosed with a hydatid cyst of the interventricular septum. Presentation, management and follow-up of the patient is discussed

#### Case presentation:

In December 2018, 15 years old girl was admitted to the cardiology department, reported atypical chest pain and a lack of appetite over 6 months, Physical examination revealed nothing unusual, with normal heart sounds and a normal pulmonary auscultation.

Electrocardiography revealed sinus tachycardia at a rate of 108 beats per minute, right axis deviation, and right bundle-branch block without ST segment or T wave abnormalities, and Her chest x-ray was normal.

**Corresponding Author:- B. Abdelaoui**

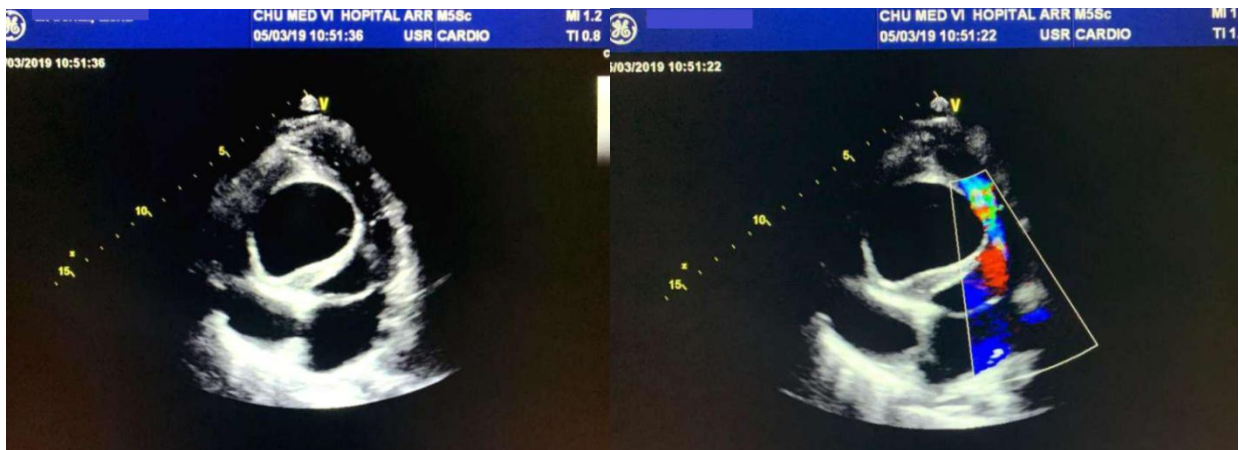Address:- Cardiology Department - CHU Mohammed VI - Marrakech.

Routine laboratory test examination showed leukocytosis of 13 400/mm<sup>3</sup> and marked eosinophilia. The erythrocyte sedimentation rate was 60 mm and C-reactive protein was in the normal range. The chest radiography was unremarkable.

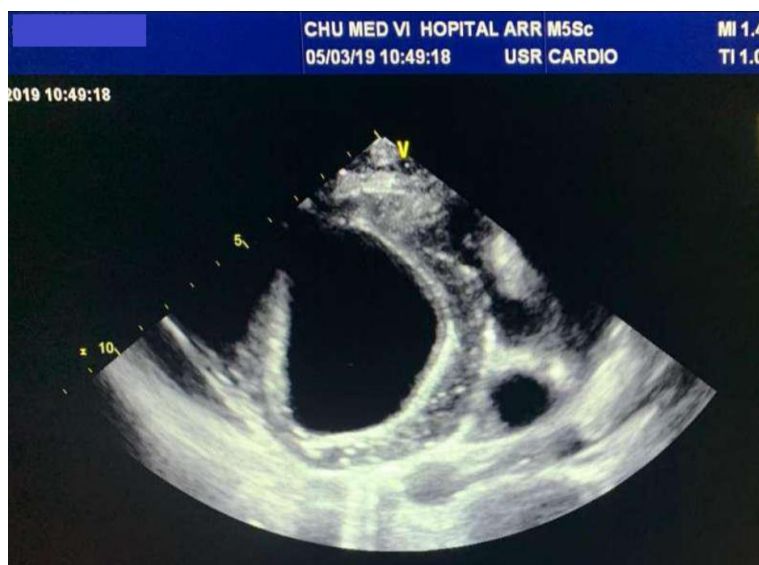
We performed a transthoracic echocardiography that showed a single large well-defined intramyocardial cystic mass in the interventricular septum. (Fig 1 and 2). Body CT scan confirmed the location in interventricular septum, with no attachment to the adjacent organs and no other cyst was present.

Urgent surgical excision of the cardiac hydatid cyst was planned. The patient underwent surgery via a sternotomy. Standard cardiopulmonary bypass and potassium cardioplegia with aortic crossclamping were used. After diastolic arrest, the operative field was isolated with towels moistened with 1% povidone iodine solution. A longitudinal interventricular septum incision was performed. The cyst was opened and the cyst contents and germinative membrane were removed. There was no communication between the cystic cavity and the right and left ventricular chambers.

The cavity was closed by obliteration and plication. Albendazole was started at 200 mg twice a day in 3 cycles of treatment for 28 days with a break of 14 days. The postoperative course was satisfactory, and the patient was discharged on the 5th postoperative day without any complication.



**Figure 1-2:-** Echocardiographic examination ( Apical four chamber view)shows the hydatid cyst in interventricular septum.



**Figure 3:-** A parasternal short axis view shows the hydatid cyst.

**Discussion:-**

Echinococcus granulosus is a helminth parasite, which causes a zoonotic disease known as echinococcosis or hydatid disease.

Cardiac hydatid cysts are very uncommon, found in fewer than 2% of cases of hydatidosis[3]. The most common cardiac locations are the left ventricular wall (60%) followed by the right ventricle (10%), pericardium (7%), left atrium (6-8%), right atrium (4%), and the interventricular septum(4%). In 50% of such cardiac cases, there is multiple organ inclusion (Eckert and Deplazes, 2004). Majority of the patients with cardiac hydatidosis are asymptomatic[4]. When symptomatic, the presentations count anaphylaxis; symptoms of low cardiac output (can act as a space-occupying lesion, as ventricular outflow obstruction, or as constrictive pericarditis); palpitation (due to irritation of conduction fibers in the ventricular septum); systemic or pulmonary emboli (rupture of the cyst in the cardiac chambers) or rapid and progressive pulmonary hypertension (as a result of embolization of high number of solices into the pulmonary circulation).[5-6-7]

Electrocardiographic can show some abnormalities such as inverted T waves in the inferior leads . When present, this signs should raise the suspicion of cardiac hydatidosis in patients living in endemic regions even when clinical symptoms are absent.[8] the EKG may also shows a Q waves in different leads. Chest X-rays shows a low contribution in the diagnosis ,Echocardiography is highly sensitive and specific and is the diagnostic method of choice for early detection of intracardiac cysts.[8] The cyst usually appears as an echolucent rounded structure, clearly contrasting with the surrounding myocardium and at times can have a loculated internal appearance due to the presence of membranes and/or septa within it. When a hydatid cyst ruptures into a cardiac chamber or undergoes a degenerative process, the typical echolucent appearance of the cyst becomes. CT tomography and MRI magnetic resonance imaging are needed either to rule out other cystic mass diagnoses or to clarify their reports.

Surgical excision is the treatment of choice to prevent further fatal complications and is associated with a high recovery rate(60%). Albendazole therapy (400 mg twice daily) is typically prescribed for at least 4 days preoperatively and for 4 to 12 weeks postoperatively [9]. to avoid recurrence.

**Conclusion:-**

The hydatid cyst of the interventricular septum is a rare entity and can also prove to be a fatal disease, the diagnosis should be suspected in patients who live in endemic regions and present unexplained cardiac symptoms, the echocardiography is the method of choice for early detection of intracardiac cysts and the surgical excision is the treatment of choice to prevent fatal complication and must be associated with a medical therapy(Albendazole) to avoid recurrence.

**References:-**

1. Shojaei E, Yassin Z, Reza Hosseini O. Cardiac hydatid cyst: a case report. Iran J Public Health. 2016;45:1507–10. 2.
2. Besir Y, Gucu A, Surer S, Rodoplu O, Melek M, Tetik O. Giant cardiac hydatid cyst in the interventricular septum protruding to right ventricular epicardium. Indian Heart J. 2013;65:81–3.
3. Dighiero J, Canabal EJ, Aguirre CV, Hazan J, Horjales JO. Echinococcus disease of the heart. Circulation. 1958;17:127–32. [PubMed] [Google Scholar]
4. Miralles A, Bracamonte L, Pavie ABV, Rabago G, Gandjbakhch I, Cabrol C. Cardiac echinococcosis. Surgical treatment and results. J Thorac Cardiovasc Surg.
5. Heyat J, Mokhtari H, Hajaliloo J, Shakibi JG. Surgical treatment of echinococcal cyst of the heart: Report of a case and review of the world literature. J Thorac Cardiovasc Surg. 1971;61:755–64. [PubMed] [Google Scholar]
6. Saad RA, Amer KMA, Migliore M, Aziz T, Azzu A. Right intraventricular hydatid cyst of the heart. Asian Cardiovasc Thorac Ann. 2003;11:160–162. [PubMed] [Google Scholar]
7. Ozer N, Aytemir K, Kuru G, et al. Hydatid cyst of the heart as a rare cause of embolization: Report of 5 cases and review of published reports. J Am Soc Echocardiogr. 2001;14:299–302. [PubMed] [Google Scholar]
8. Yague D, Lozano MP, Lample C, Nunez ME, Sanchez F. Bilateral hydatid cyst of pulmonary arteries: MR and CT findings. Eur Radiol 1998; 8:1170–1172
9. Ipek G, Omeroglu SN, Goksedef D, et al. Large cardiac hydatid cyst in the interventricular septum. Tex Heart Inst J. 2011;38:719– 22.