



Journal Homepage: - [www.journalijar.com](http://www.journalijar.com)

## INTERNATIONAL JOURNAL OF ADVANCED RESEARCH (IJAR)

Article DOI: 10.21474/IJAR01/10526  
DOI URL: <http://dx.doi.org/10.21474/IJAR01/10526>



### RESEARCH ARTICLE

#### A CASE OF BILIPTYSIS CAUSED BY A CHOLECYSTECTOMY

**Ratbi El Amine, Raiss Mohamed and Alaoui Mhamdi Mouna**

Surgical Clinic C, University Hospital IbnSina, Rabat, Morocco.

#### Manuscript Info

##### Manuscript History

Received: 17 December 2019

Final Accepted: 20 January 2020

Published: February 2020

#### Abstract

Copy Right, IJAR, 2020,. All rights reserved.

#### Introduction:-

Biliobronchial fistula (BBF) is a rare condition characterized by abnormal communication between the bronchial tree and the biliary system (1). The first case was reported by Peacock's in 1850 in a 20-years-old woman with hepatic echinococcosis (2). The diagnosis remains essentially clinical guided by the presence a bilious sputum, is a known but rare complication of biliary stenosis, tumor, trauma and surgery (3). We present the case of patient admitted to our service with unusual disorder.

#### Case Presentation:

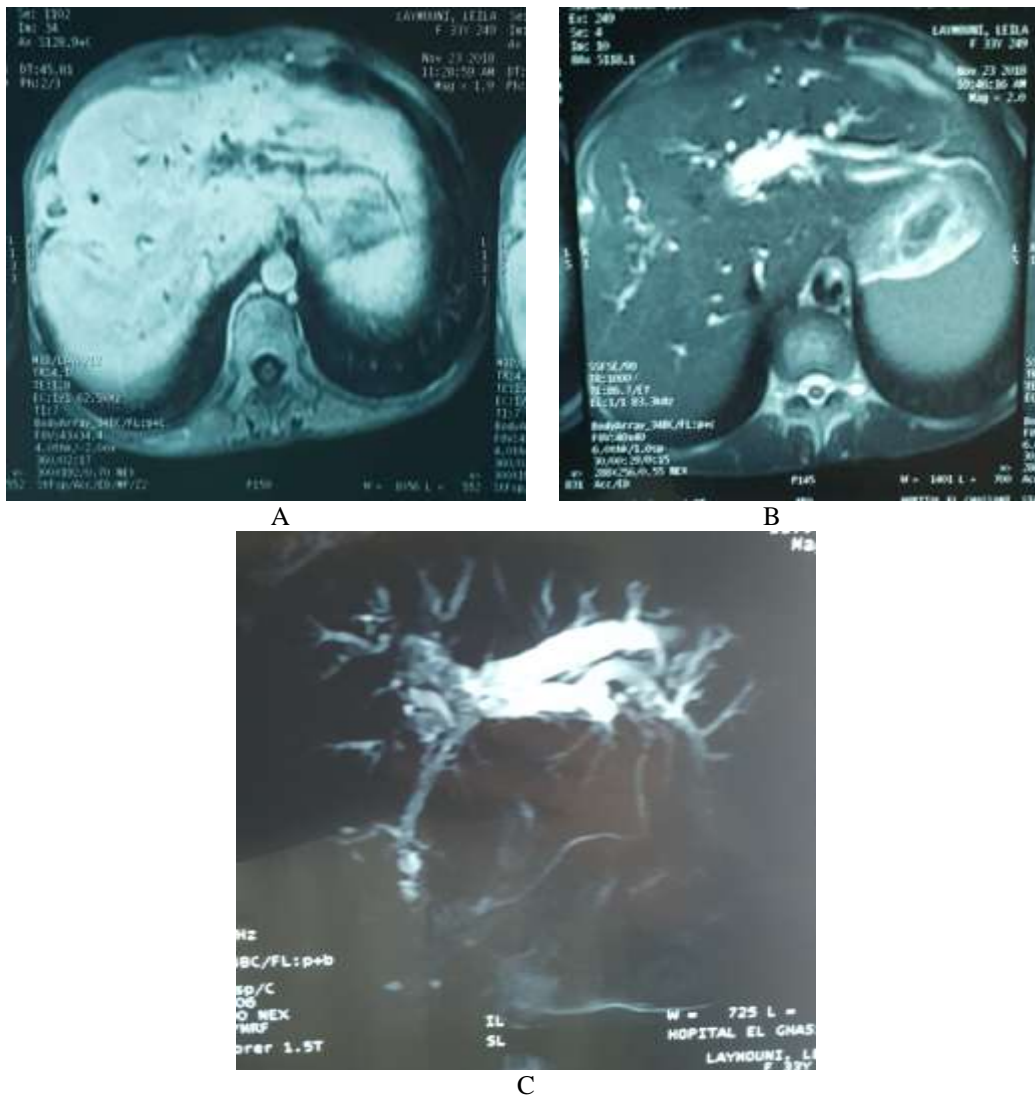
A 40-year-old female was seen with biliptysis pain of 1 year. History included cholecystectomy at laparotomy in 2017 for gallstones in a district hospital, the postoperative course was marked by the appearance of jaundice on the seventh day, some months after ictere was regressed and which biliptysis developed, was no fever or pain. In 2018, biliptysis developed more, the patient was referred to our hospital in 2019.

At our hospital, the patient's abdomen was soft and flat. She no longer showed abdominal pain and tenderness. The results of laboratory evaluations were as follows: PAL: 477 IU/L; GGT: 448 IU/L.

MRI scans showed intrahepatic parietal formation appearing to have a wall and fluid content measuring 19x17mm: subphrenic collection and biliobronchial fistula and intrahepatic biliary ductal dilatation especially at the level of the left lobe. Laparotomy revealed a 3x3 cm abscess collection in the right lobe of the liver communicating with the right lower lobe of the lung and bile duct injury type E4 according to Strasberg classification of biliary injury: Stricture of the hilus with involvement of confluence and loss of communication between right and left hepatic ducts. The patient underwent a decortication of the abscess cavity with closure of the diaphragmatic fistula and reparation of the bile duct injury by the Roux-en-Y hepaticojejunostomy elongated to the left hepatic duct. The postoperative course was uneventful. After 06 months of follow up, patient had excellent outcome.

**Corresponding Author:- Ratbi El Amine**

Address:- Surgical Clinic C, University Hospital IbnSina, Rabat, Morocco.



**Fig. 1:-** Magnetic resonance imaging and magnetic resonance cholangiography show fistulous tract between the biliary tree and bronchus of the right lobe and right subphrenic collection (A) et (B) also biliary duct dilatation of the left lobe(C).

### Discussion:-

BBF is a rare complication caused by several mechanisms whose l'obstruction biliary after surgery haptobiliary, which produces an inflammatory reaction in the subdiaphragmatic space, with subsequent rupture into the bronchial system, this one favoured by the differential pressure gradient between the abdominal and thoracic cavity (1).

The diagnosis is usually clinical, but the presence of bilitysia is the sine qua non of a BBF. Imaging studies used to confirm the diagnosis (CT scan, MRI and endoscopic retrograde cholangiopancreatography) must demonstrate the fistulous tract (2).

There is no general agreement on how to deal with BBFs. Management is often multimodal and directed at the underlying etiology. Ong et al used subcutaneous octreotide and succeeding in reducing bilous sputum in a patient and allows closure of the fistula, but its use is limited and is not practical in case of infection, neoplasia or obstruction (4).

Indeed, other conservative interventions can be used for reducing the pressure in the biliary tract, such as endoscopic retrograde cholangiography to treat BBF as a complication of gallstone, hepatic trauma and bil duct injury. Although

there is little doubt that other factors may be implicated in the continuance of a BBF, the most notable of which appears to be sepsis, the importance of these factors cannot be conclusively established (5).

Our patient did not have an endoscopic retrograde cholangiography given the type of bile duct injury evoked on the MRI.

The definitive treatment is surgical and should have the repair of lesions of bile duct with biliary diversion or stents to relieve the obstruction and fistulectomy with soft tissue reconstruction (6). Adams reported two BBFs associated with common bile duct stricture, he also emphasized the importance of early and adequate drainage to prevent the occurrence of acute necrotizing bronchitis and pneumonitis caused by infected bile. In the discussion of this presentation it was recommended that the primary method of treatment should be laparotomy to correct the basic biliary disease rather than any type of thoracotomy. Subsequent pulmonary resection may become necessary if there are severe structural changes in the lungs (7).

Biliptysis is a rare complication of biliary tract surgery remains of easy diagnosis but specific management.

**References:-**

1. Velayutham V, Satyanesan J, A case of recurrent biliptysis: Department of surgical Gastroenterology, Government Stanley Medical College Hospital, Chennai-600001, Tamilnadu, India. *J Thorac Cardiovasc Surg* 2007;133;1662-3.
2. Romina A, Maria ET, Anxo Martinez de A, Luis V, Late biliobronchial fistula: Pneumology Department, Hospital ClinicoUniversito, Santiago, Spain. *J. Pulmoe.* 2018.08.001.
3. Liao GQ, Wang H, Zhu GY, Zhu KB, Lv FX, Tai S. Management of acquired bronchobiliary fistula: a systematic literature review of 68 cases published in 30 years. *World J Gastroenterol* 2011 September 7; 17(33): 3842-3849.
4. Ong M, Moozar K, Cohen LB. Octreotide in bronchobiliary fistula management. *Ann Thorac Surg.* 2004;78: 1512-3
5. Sing B, Moodley J. Author reply to comment on Ann thorc Surg. 2002;73:1088-91 [letter]. *Ann Thorac Surg.* 2004; 78:1513.
6. Sing B, Moodley J, Sheik-Gafoor MH, Dhooma N, Reddi A. Conservative management of thoracobiliary fistula. *Ann Thorac Surg.* 2002; 73:1088-91.
7. Kamal M, Emory University Clinic, Atlanta, Georgia 30322. *DIS. CHEST*, Vol. 56, NO. 6, December 1969.