



Journal Homepage: -[www.journalijar.com](http://www.journalijar.com)

## INTERNATIONAL JOURNAL OF ADVANCED RESEARCH (IJAR)

Article DOI:10.21474/IJAR01/10640  
DOI URL: <http://dx.doi.org/10.21474/IJAR01/10640>



### RESEARCH ARTICLE

#### THE CONCEPT OF GUIDED TISSUE REGENERATION IN LARGE PERIRADICULAR BONY DEFECT: A CASE REPORT

Khalid Tarek Karkar<sup>1</sup> and Ahmed Mohamed Galbat<sup>2</sup>

1. Assistant Lecturer of Oral and Maxillofacial Surgery, Faculty of Dentistry, October 6 University (BDS, MFDS RCSEd, MDS).
2. Teaching Assistant of Endodontics, Faculty of Dentistry, October 6 University (BDS, MFDS RCSEd).

#### Manuscript Info

##### Manuscript History

Received: 10 January 2020

Final Accepted: 12 February 2020

Published: March 2020

##### Key words:-

Guided Tissue Regeneration, Periapical Lesion, Periradicular/Periapical Surgery

#### Abstract

Periradicular (PR) bony defects are common consequence of chronic endodontic lesions. Occasionally, conventional root canal treatment is not appropriate for complete regression of the lesion. PR surgeries may be warranted in such selected cases. PR surgery provides a ready access for the complete removal of pathologic lesion from the periapical region. Recently, the attempt of regeneration of the destroyed PR tissues has gained more attention rather than repair of it. In order to promote regeneration after apical surgery, the principle of guided tissue regeneration (GTR) has proved to be very useful. This case presents the management of a large PR lesion in a 20-year-old female. The PR lesion associated with lower anterior teeth was treated using PR surgery and GTR concept. The case was followed up for nine months radiographically and clinically. The principle of GTR improved the clinical outcome and prognosis of the endodontically involved teeth with a large PR defect by restoring the labial plate.

Copy Right, IJAR, 2020.. All rights reserved.

#### Introduction:-

Radicular cyst (periapical) is the most common lesion encountered secondary to caries or trauma in oral and maxillofacial region.<sup>[1][2]</sup> If the offending tooth is not treated or extracted, the lesion continues to enlarge via the hyperosmolarity.<sup>[1]</sup> Periapical surgery is indicated in cases where there is infection persisting on the apical areas of the tooth, radicular cyst, and/or foreign body reactions.<sup>[3]</sup> Periapical surgery includes the surgical debridement of periapical lesion, root apex resection and root end cavity preparation to receive a filling material.<sup>[4]</sup>

The practice of conventional periapical surgery after surgical debridement of a large cystic lesion often resulted in healing by scar tissue formation. Histologically, this consisted of replacement of the periapical tissue with fibrous connective tissue.<sup>[5]</sup> Using immediate bone grafting in significant bony defect after periapical surgery,<sup>[1]</sup> with the guided tissue regeneration (GTR) concept of restriction of rapidly proliferating epithelial and gingival cells into the area of new bone formation,<sup>[6][7]</sup> will enhance the osseous healing and optimize the outcome of the surgical procedure.<sup>[8]</sup>

#### Corresponding Author:- Khalid Tarek Karkar

Address:- Department of Oral and Maxillofacial Surgery, Faculty of Dentistry, October 6 University, Elmehtar Elmarkazi, 6<sup>th</sup> October City, Giza 12585, Egypt.

**Case report:**

A 20 years old female medically free patient presented with chronic gingival swelling related to lower anterior teeth which subsides intermittently with antibiotic intake. The patient revealed a history of dentoalveolar trauma three years ago at this area and received multiple root canal treatment in these teeth after nine months from the incident.

On clinical examination, the two lower central incisors revealed mobility grade I. The radiological findings revealed a large periapical radiolucency related to the lower anteriors (centrals and laterals) and lower left canine. The canine showed a broken file at the full length of the canal.

A multidisciplinary approach consisting of endodontic therapy followed by periapical surgery with GTR procedure, was decided. A written consent was signed by the patient after illustration of benefits and risks.

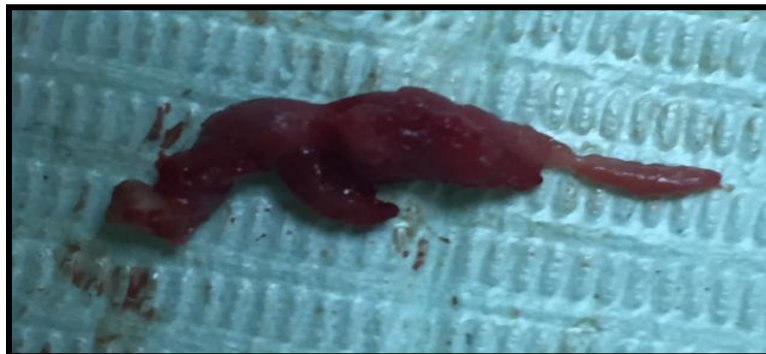First, endodontic retreatment was done to the affected teeth after removal the broken file by an endodontist.

Then, Bilateral mental nerve block was used for complete anesthesia and hemostasis. Three lines pyramidal flap with two vertical releasing incisions, extending from distal to mandibular right canine to distal to left canine,

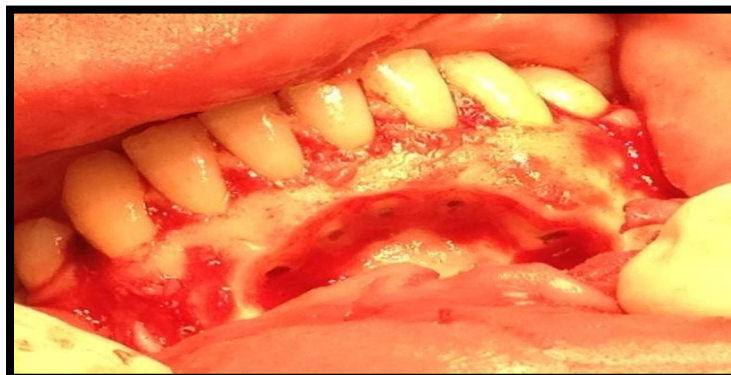A mucoperiosteal flap was elevated and the periapical area of lower anteriors was exposed.

A fenestration type of defect was noticed in the periapical region. This was further enlarged to gain complete access to the cystic lesion, which was finally enucleated [Figure 1]. Apicoectomy with retrograde filling of the offending teeth was performed [Figure 2].

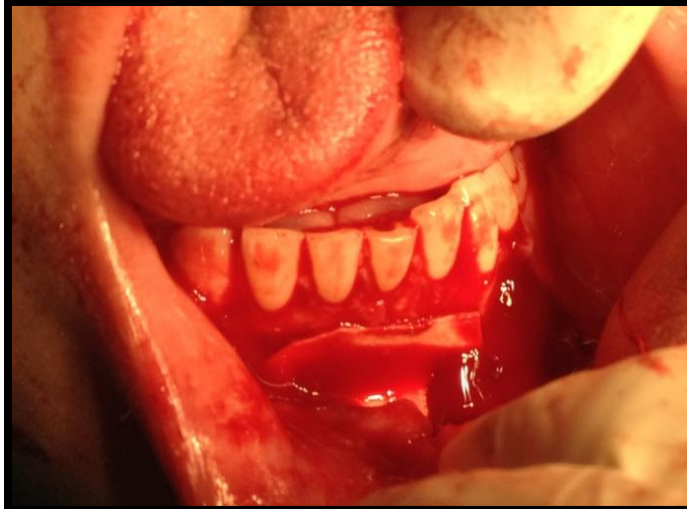
A large periapical defect (3x2x1.5 cm) resulted with relation to the apices of lower incisors and lower left canine. Complete curettage done and walls of the defect stimulated by round bur to produce bleeding.



**Figure 1:-** The main part of the enucleated cyst.



**Figure 2:-** Surgical enucleation with curettage, and apicoectomy with retrograde filling of the offending teeth  
A Collagen membrane, was placed to cover the boundaries of the defect. The membrane was secured in position lingually and apically by sutures to the overlying flap [Figure 3]. The flap was repositioned and sutured with 3-0 vicryl suture material.



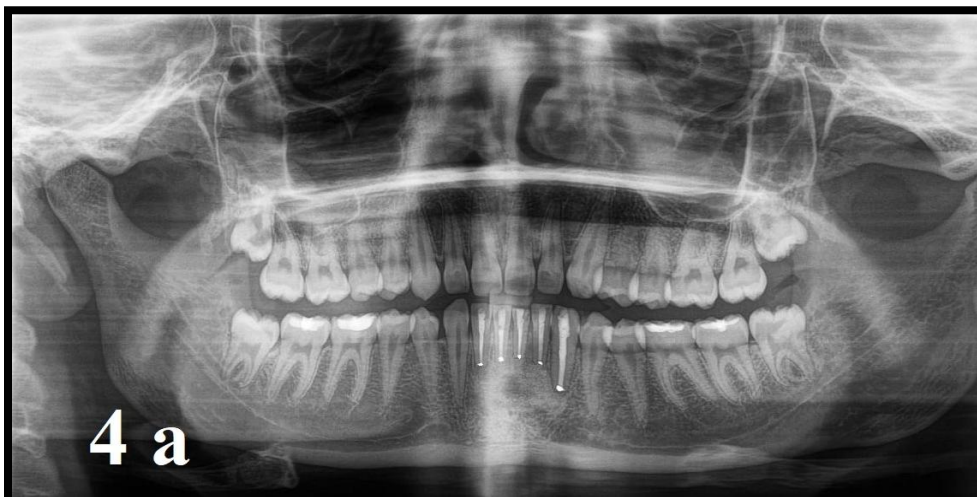**Figure 3:-** The membrane was secured in position by sutures to the base of the flap, then interdental sutures later.

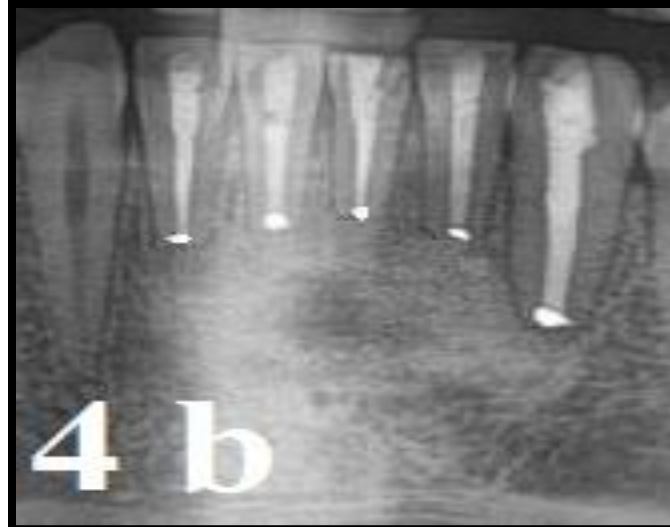Amoxicillin + clavulanic acid 1 g twice daily, and diclofenac potassium 50 mg thrice daily for five days were prescribed. An intramuscular injection of dexamethasone 8 mg was also administered once only to control the postoperative edema. The patient informed the post-operative instructions in a written manner and 0.125% chlorhexidine digluconate mouthwash was prescribed, as an aid for plaque control twice daily for five days starting from the second day postoperatively.

A histopathologic study of the cystic capsule was performed to confirm the provisional diagnosis of the periapical cyst.

The patient was recalled after one week then periodically every two weeks for follow up. All the adjacent teeth were vital, but the mobility of the lower central incisors was still evident. The patient was advised eating soft diet and maintaining good oral hygiene, i.e, tooth brushing, use of interdental hygiene aids such as dental floss and use of antimicrobial mouth rinse.

The patient received scaling and root planning treatment with local irrigation of tetracycline three times, once every two months. All the lower anterior teeth become stable after six months. A nine months post-operative panoramic radiograph revealed complete bony healing as indicated by increase in radiodensity [Figure 4].





**Figure 4:-** a- A 9 months post-operative panoramic xray, b- Cropped image from the panorama, which showed complete bony healing as indicated by increase in radiodensity.

### Discussion:-

Periapical pathology may persist, however an adequate endodontic treatment was done. In such cases, PR surgery will be a vital therapeutic option to salvage the tooth.<sup>[9]</sup> Conventional endodontic treatment demonstrated a high-risk of failure, particularly in cases of large periapical lesions.<sup>[10]</sup> GTR technique successfully used in clinical periodontal practice and may be applied as an adjunctive therapy in endodontic surgery. The described case report presents with a large PR lesion from endodontic origin, with no periodontal communication. In order to gain surgical access to the large cystic lesion, to facilitate its complete elimination, a loss of labial cortical plate ensued. The healing of PR defects with concomitant loss of labial cortical plate is compromised, involving poor regeneration of periapical tissues.<sup>[11]</sup>

The rationale of bone decortication is controversial, seems to cause some beneficial effects such as stimulation of a “regional acceleratory phenomenon” and advance the process of angiogenesis accompanied by the recruitment of pluripotential cells in the defect site. The blood clot thus formed may provide a hoard of cytokines and growth factors, accelerating the healing process.<sup>[12]</sup>

A barrier membrane was used to ward off epithelial cells and fibroblasts, facilitating repopulation of periodontal ligament cells.<sup>[13]</sup> The membrane must be secured in position for preventing the mobility and collapse of the membrane, thus facilitating space maintenance to improve the outcome.<sup>[14]</sup> In this case the securing done by suturing to the base of flap and to the lingual side. For more stability the titanium minipins can be used, which weren't available at the time of surgery.

Several authors have reported the successful resolution of periapical defects with using a combined application of membrane and bone grafts,<sup>[15][16][17][18][19]</sup> or with using a membrane alone (guided tissue regeneration).<sup>[20][21][22]</sup>

The present case report describes a successful resolution of a large PR lesion of endodontic origin, accompanied with loss of labial cortical plate. The outcome success may be attributed to the following factors:

Complete debridement of the PR defect, decortication of the bony defect at multiple sites, securing of the membrane and primary wound closure.

It is essential to carry out the PASS principle. PASS involves primary closure of surgical site (P), angiogenesis by providing adequate blood supply and the cell type necessary for regeneration (A), space creation and maintenance (S) and finally stability of the blood clot (S).<sup>[14]</sup>

**Conclusion:-**

The effect of GTR procedures can be virtually improved by securing the membrane in place by sutures. A successful resolution of a large PR lesion, unresponsive to conventional endodontic therapy can be achieved with application of GTR. GTR may improve the prognosis of teeth with large PR lesion.

**References:-**

1. Fonseca, Raymond J. Oral and Maxillofacial Surgery, volume 2, Third edition. St. Louis, Missouri : Elsevier, [2018]
2. Robert E. Marx, Diane Stern. Oral and Maxillofacial Pathology: A Rationale for Diagnosis and Treatment, Second edition. 2012 Quintessence Publishing Co, Inc.
3. Wu MK, Dummer PM, Wesselink PR. Consequences of and strategies to deal with residual post-treatment root canal infection. *Int Endod J.* 2006;39:343–56.
4. Kim S, Kratchman S. Modern endodontic surgery concepts and practice: A review. *J Endod.* 2006;32:601–23.
5. Molven O, Halse A, Grung B. Incomplete healing (scar tissue) after periapical surgery – Radiographic findings 8 to 12 years after treatment. *J Endod.* 1996;22:264–8.
6. Melcher AH. On the repair potential of periodontal tissues. *J Periodontol.* 1976;47:256–60.
7. Gutman J, Harrison J. *Surgical endodontics* Cambridge: Blackwell scientific 1991:3-25.
8. Pinto vs, Zuolon ML, Mellowing J.T: Guided bone regeneration in the treatment of a large Periapical lesion: A case-report *Practical Perio. and Esth., Dent, Vol.7, No. 2I 76-82.*
9. Caliskan MK. Prognosis of large cyst-like periapical lesions following nonsurgical root canal treatment: A clinical review. *Int Endod J.* 2004;37:408–16.
10. Weiger R, Rosendahl R, Löst C. Influence of calcium hydroxide intracanal dressings on the prognosis of teeth with endodontically induced periapical lesions. *Int Endod J.* 2000;33:219–26.
11. Skoglund A, Persson G. A follow-up study of apicoectomized teeth with total loss of the buccal bone plate. *Oral Surg Oral Med Oral Pathol.* 1985;59:78–81.
12. Greenstein G, Greenstein B, Cavallaro J, Tarnow D. The role of bone decortication in enhancing the results of guided bone regeneration: A literature review. *J Periodontol.* 2009;80:175–89.
13. Douthitt JC, Gutmann JL, Witherspoon DE. Histologic assessment of healing after the use of a bioresorbable membrane in the management of buccal bone loss concomitant with periradicular surgery. *J Endod.* 2001;27:404–10.
14. Wang HL, Boyapati L. “PASS” principles for predictable bone regeneration. *Implant Dent.* 2006;15:8–17.
15. Tseng CC, Chen YH, Huang CC, Bowers GM. Correction of a large periradicular lesion and mucosal defect using combined endodontic and periodontal therapy: A case report. *Int J Periodontics Restorative Dent.* 1995;15:377–83.
16. Brugnami F, Mellonig JT. Treatment of a large periapical lesion with loss of labial cortical plate using GTR: A case report. *Int J Periodontics Restorative Dent.* 1999;19:243–9.
17. Dietrich T, Zunker P, Dietrich D, Bernimoulin JP. Periapical and periodontal healing after osseous grafting and guided tissue regeneration treatment of apicomarginal defects in periradicular surgery: Results after 12 months. *Oral Surg Oral Med Oral Pathol Oral Radiol Endod.* 2003;95:474–82.
18. Taschieri S, Del Fabbro M, Testori T, Saita M, Weinstein R. Efficacy of guided tissue regeneration in the management of through-and-through lesions following surgical endodontics: A preliminary study. *Int J Periodontics Restorative Dent.* 2008;28:265–71.
19. Lin GH, Chang LY, Lin WC, Lee SY, Lai YL. Interdisciplinary approach for treating a large through-and-through periapical defect using guided tissue regeneration: A case report. *Int J Periodontics Restorative Dent.* 2014;34:e1–8.
20. Abramowitz PN, Rankow H, Trope M. Multidisciplinary approach to apical surgery in conjunction with the loss of buccal cortical plate. *Oral Surg Oral Med Oral Pathol.* 1994;77:502–6.
21. Pecora G, Kim S, Celletti R, Davarpanah M. The guided tissue regeneration principle in endodontic surgery: One-year postoperative results of large periapical lesions. *Int Endod J.* 1995;28:41–6.
22. Marín-Botero ML, Domínguez-Mejía JS, Arismendi-Echavarría JA, Mesa-Jaramillo AL, Flórez-Moreno GA, Tobón-Arroyave SI. Healing response of apicomarginal defects to two guided tissue regeneration techniques in periradicular surgery: A double-blind, randomized-clinical trial. *Int Endod J.* 2006;39:368–77.