



Journal Homepage: -[www.journalijar.com](http://www.journalijar.com)

## INTERNATIONAL JOURNAL OF ADVANCED RESEARCH (IJAR)

Article DOI:10.21474/IJAR01/11522  
DOI URL: <http://dx.doi.org/10.21474/IJAR01/11522>



### RESEARCH ARTICLE

#### CEREBRAL VENOUS THROMBOSIS DURING PREGNANCY IN PARTURIENT WITH CHRONIC INFLAMMATORY BOWEL DISEASE: CASE REPORT AND REVIEW OF THE LITERATURE

Safia El Ayoubiâ, Nezha Oudghiri Â. and Anas Tazi Saoudâ

#### Manuscript Info

##### Manuscript History

Received: 15 June 2020  
Final Accepted: 17 July 2020  
Published: August 2020

#### Abstract

**Introduction:** Pregnancy and post partum represent major risk factors for Cerebral venous thrombosis (CVT) and this last is exceptional in inflammatory bowel disease. We report the case of a parturient with ulcerative colitis who presented a CVT in the immediate postpartum. We want through this case, and a review of the literature, to expose an atypical clinical presentation of CVT appearing in the postpartum. Observation: 20 years old women, followed for ulcerative colitis, received in the immediate postpartum, antibiotic therapy for endometritis. Then transferred to intensive care for further management, with a stable haemodynamic state, aphasic, behavior trouble, SOFA score at 2. She was maintained on antibiotic and put on antidepressant for a diagnosed depression. Later, the patient presented a generalized tonic-clonic seizure and right hemiparesis. A cerebral CT scan was performed showing thrombophlebitis of the upper longitudinal sinus. Low molecular weight heparin anticoagulation curative dose and anti seizure drugs have been started. The evolution was favorable.

**Discussion:** Approximately 2-20% of pregnancy-related strokes are due to CVT. Several studies have suggested a correlation between thromboembolic events and IBD with a relative risk of 3.6 and an annual incidence of 0.5 to 6.7. In the literature, the diagnosis of CVT is mainly based on clinical suspicion and radiological confirmation. The pregnancy doesn't modify the clinical manifestations of CVT. The median delay between the first symptom and the diagnosis is 7 days. The diagnosis of CVT can be confused with other diagnoses and delay management. Otherwise mental status disorders, especially somnolence are more common in obstetric CVT. Cerebral CT scan is the first examination to be performed in front of a suspicion of CVT. Anticoagulation is currently the main treatment. The prognosis is variable, ranging from complete recovery to death. Depending on the timing of diagnosis and thus the treatment.

**Conclusion:** Cerebral thrombophlebitis during pregnancy is infrequent, and generally of good prognosis except when the diagnosis is delayed because of atypical manifestations especially neuropsychiatric. Otherwise pregnant women with chronic inflammatory bowel disease should be more rigorously monitored for the occurrence of a thromboembolic events in general, and for cerebral events in particular.

---

**Introduction:-**

Cerebral venous thrombosis (CVT) is a rare condition that accounts for 0.5-1% of all strokes; its incidence is estimated at 3-4 cases per million in adults. [1-2]

Pregnancy and post partum, by their physiological changes, represent major risk factors for CVT. [3] European researchers reported a prevalence of 20% among all listed CVTs during pregnancy. [4]

Moreover, the CVT has multiple clinical manifestations. Which can be responsible of a delay of treatment. And thus aggravate the prognosis, by leading to complications such as cerebral ischemia, cerebral hemorrhage in 30 to 40% of cases. [5-6]

Cerebral venous thrombosis is exceptional in inflammatory bowel disease (IBD) compared with other thromboembolic events. 60 cases have been published since its first description in 1967 by Harrison. [7]

We report the case of a parturient with ulcerative colitis (UC), in a moderate active phase, who presented a TVC in the immediate postpartum.

We want through this case, and a review of the literature, to expose an atypical clinical presentation of TVC appearing in the postpartum.

**Observation:-**

Mrs D.S, 20 years old, followed for UC on immunosuppressive drugs (salicylated type 5 aminosalicylic), in a moderate active phase, admitted to the obstetric hospital for term delivery. The bleeding vaginal delivery gave birth to a female newborn, APGAR 10/10, weighted 2900 g. The next day, the patient is febrish at 39°C with fetid lochia with uterine mobilization pain. She received antibiotic therapy for endometritis with transfusion of 02 packed red cells for a hemoglobin at 6.5 g / dl, then transferred to intensive care for further management. On admission, the patient was haemodynamically stable, aphasic, behavior trouble, SOFA score at 2, maintained on antibiotic and put on antidepressant for a diagnosed depression. At the end of the day, the patient presented a generalized tonic-clonic seizure and right hemiparesis. Cerebral CT scan was performed showing thrombophlebitis of the upper longitudinal sinus with secondary bilateral infarction (figure 1-2). Low molecular weight anticoagulation curative dose and anti seizure drugs have been started. The occurrence of a second tonic-clonic crisis with post-critical coma imposed an oro-tracheal intubation with invasive ventilation. The patient was tracheotomized on day 5. The patient was discharged from the intensive care unit after 28 days with favorable evolution, and progressive recovery of the neurological deficit.

**Discussion:-**

Pregnancy and postpartum are common causes of transient thrombotic states. [8] Approximately 2-20% of pregnancy-related strokes are due to CVT [4,9]. Its frequency is estimated at 12 cases per 100,000 deliveries. [10] In a study conducted in Mexico, 50% of CVTs occurred during pregnancy especially in the third trimester or during postpartum. [11]

The pathophysiology of the onset of CVT during pregnancy remains poorly understood. But factors associated with coagulation disorders seem to favor its appearance such as young age (14-25 years), high blood pressure, vomiting, dehydration, anemia, blood loss, traumatic obstetric maneuvers, caesarean section and infection. [12] Which is the case for our patient, a young woman of 20 years, anemic (bleeding during childbirth), dehydrated, infected and followed for IBD.

Several studies have suggested a correlation between thromboembolic events and IBD with a relative risk of 3.6 and an annual incidence of 0.5 to 6.7. [13] Three mechanisms appear to be dominant in the pathogenesis: coagulation disorders (increased factor V and VIII activity, and decreased antithrombin III activity), primary hemostasis abnormalities, and abnormalities of fibrinolysis (decreased tissue plasminogen activator and increased inhibitors).

Moreover, during IBD there is an increase in the release of inflammatory mediators which induce endothelial lesions and a state of hypercoagulation; some studies suggest that when the thromboembolic event occurs during the active phase of IBD, it is likely due to the state of hypercoagulability, and when it occurs during the remission phase, it would be secondary to the individual causes of thrombophilia. [14]

In the literature, the diagnosis of TVC is mainly based on clinical suspicion and radiological confirmation. The pregnancy doesn't modify the clinical manifestations of TVC. They depend on the mechanism responsible of the neurological failure, and are divided into two categories. Those related to increased intracranial pressure and those related to focal brain injury (ischemia or haemorrhage). [15] In general, most symptoms are due to both mechanisms simultaneously. They are summarized in headaches, seizures, neurological deficit, papillary edema and alteration of consciousness. Psychoses have also been reported. [14]

The median delay between the onset of the first symptom and hospitalization is 4 days, and between the first symptom and the diagnosis is 7 days. For our patient, the latter was 3 days. The diagnosis of CVT can be confused with other diagnoses and delay management. [16-17] There are diagnostic pitfalls to consider : Intra-cerebral haemorrhage is associated in 30-40% of cases with CVT, and the latter must be identified as a cause in order to determine the therapeutic behavior. Isolated Headache on idiopathic intracranial hypertension is observed in 25% of patients with CVT. [18] and vice versa 10% of patients with idiopathic intracranial hypertension (ICHT), had a CVT on MRI. [19]

Otherwise mental status disorders, especially somnolence/ drowsiness are more common in obstetric CVT. [20] Our patient also showed the TVC by psychic disorders such as depression and behavioral trouble, which confused the diagnosis, delaying the diagnosis of TVC.

Cerebral CT scan is the first examination to be performed in front of a suspicion of CVT. Without injection of iodinated contrast, it is often normal, but may show indirect signs (hyperdensity in the cortical or dural veins). With injection, CT may show the classic sign of the "empty delta", which may not be found during the first days.

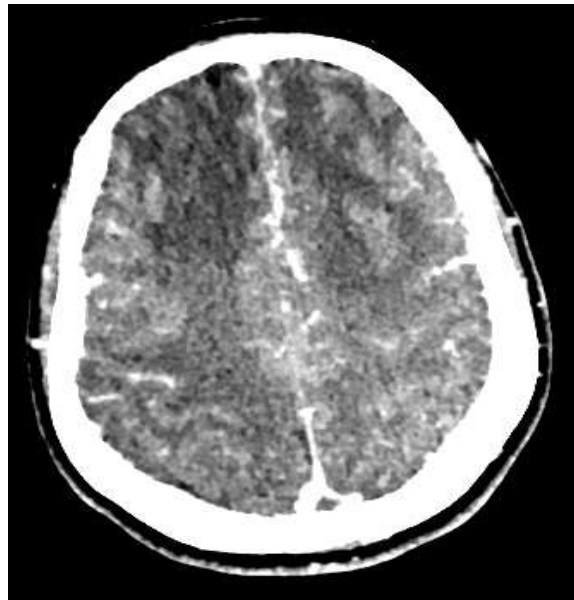
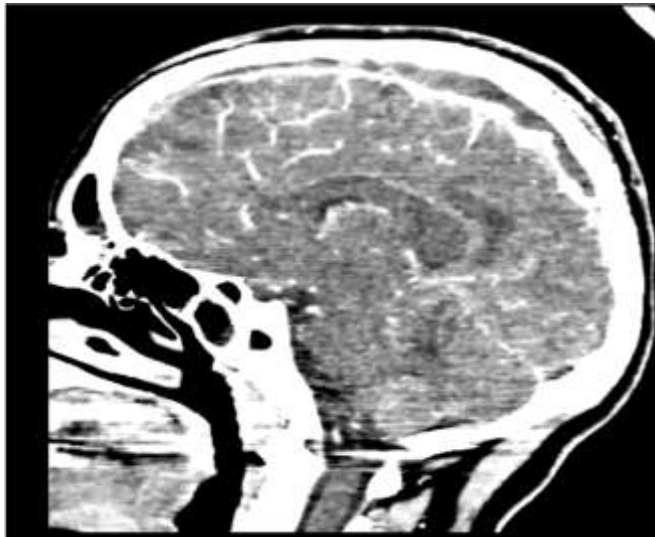
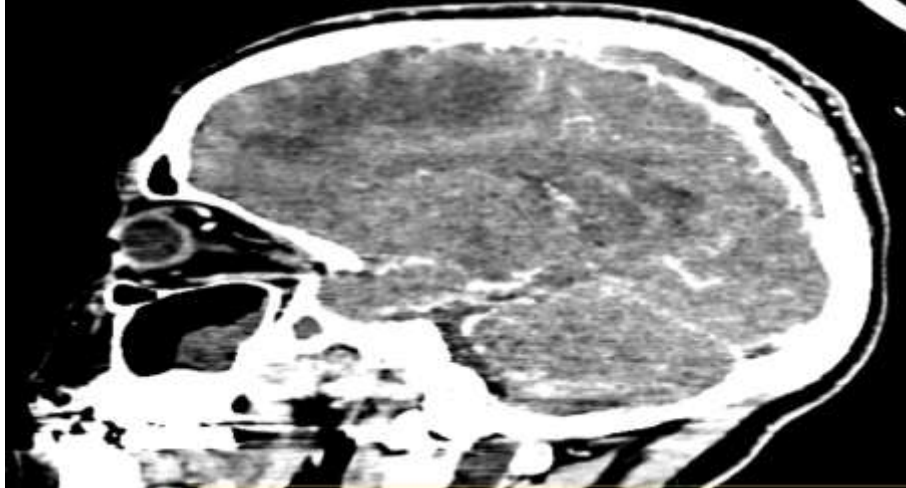
MRI is the key to diagnosis. More sensitive than the CT for the detection of the CVT. The intensity of the MRI signal differs according to the age of the thrombus. Acute thrombus is seen as a weak intensity. During the first week, it is in the form of an iso signal in T1 and a hyposignal in T2. And during the second week, it is in the form of a high signal in T1 and T2. [21]

The management of CVT during pregnancy is based on the treatment and prevention of seizures, the control of ICHT, as well as the research and treatment of infection. [15] Anticoagulation is currently the main treatment, in order to limit the existing thrombus and prevent the appearance of other thrombi. If there is a major counter-indication to anticoagulation, the benefit-risk balance should be studied in relation to the clinical condition. Low molecular weight heparin (LMWH) was used in our case with a good evolution.

The prognosis is variable, ranging from complete recovery to death. Depending on the timing of diagnosis and thus the treatment. [12]

### **Conclusion:-**

Cerebral thrombophlebitis during pregnancy is infrequent, and generally of good prognosis except when the diagnosis is delayed because of atypical manifestations especially neuropsychiatric; our patient presented with a frontal syndrome initially attributed to postpartum depression and sepsis. Otherwise pregnant women with chronic inflammatory bowel disease should be more rigorously monitored for the occurrence of a thromboembolic events in general, and for cerebral events in particular.



**References:-**

1. Stam J (2005) Thrombosis of the cerebral veins and sinuses. *N Engl J Med* 352:1791–1798
2. Martinelli I, Passamonti SM, Rossi E, De Stefano V (2012) Cerebral sinus-venous thrombosis. *Intern Emerg Med Suppl* 3:S221–S225
3. Pabinger I, Grafenhofer H, Kyrle PA, Quehenberger P, Mannhalter C, Lechner K, Kaider A. Temporary increase in the risk for recurrence during pregnancy in women with a history of venous thromboembolism. *Blood*. 2002;100:1060–1062.
4. Ferro JM, Canhao P, Stam J, Bousser M-G, Barinagarrementeria F; for ISCVT Investigators. Prognosis of cerebral vein and dural sinus thrombosis: results of the international study on cerebral vein and dural sinus thrombosis (ISCVT). *Stroke* 2004;35:664-70.
5. Wasay M, Bakshi R, Bobustuc G, Kojan S, Sheikh Z, Dai A, Cheema Z. Cerebral venous thrombosis: analysis of a multicenter cohort from the United States. *J Stroke Cerebrovasc Dis*. 2008;17:49–54.
6. Girot M, Ferro JM, Canha o P, Stam J, Bousser MG, Barinagarre- menteria F, Leys D; ISCVT Investigators. Predictors of outcome in patients with cerebral venous thrombosis and intracerebral hemorrhage. *Stroke*. 2007;38:337–342.
7. Harrison MJ, Truelove SC. Cerebral venous thrombosis as a complication of ulcerative colitis. *Am J Dig Dis* 1967; 12: 1025–8.
8. Pabinger I, Grafenhofer H, Kyrle PA, Quehenberger P, Mannhalter C, Lechner K, Kaider A. Temporary increase in the risk for recurrence during pregnancy in women with a history of venous thromboembolism. *Blood*. 2002;100:1060–1062.
9. James AH, Bushnell CD, Jamison MG, Myers ER. Incidence and risk factors for stroke in pregnancy and the puerperium. *Obstet Gynecol*. 2005;106:509 –516.
10. Rufz-Sandoval JL, Cantu C, Barinagarrementeria F. Intracerebral hem- orrhage in young people: analysis of risk factors, location, causes, and prognosis. *Stroke*. 1999;30:537–541.
11. Cantu C, Barinagarrementeria F. Cerebral venous thrombosis associated with pregnancy and puerperium: review of 67 cases. *Stroke*. 1993;24: 1880 –1884.
12. Bhojo A. Khealani1, Uzma U. Mapari2, Rozina Sikandar3. Obstetric Cerebral Venous Thrombosis Neurology section, Department of Medicine1, The Aga Khan University, Karachi, Royal College2, UK, Department of Obstetrics and Gynecology3, The Aga Khan University, Karachi. *J Pak Med Assoc* Vol. 56, No. 11, November 2006
13. Talbot RW, Heppell J, Dozois RR, Beart RW Jr. Vascular complications of inflammatory bowel disease. *Mayo Clin Proc* 1986; 61: 140–5.
14. Cerebral venous thrombosis and inflammatory bowel disease: reflections on pathogenesis A.Awab, B. Elahmadi, R. Elmoussaoui, A. Elhijri, M. Alilou and A. Azzouzi
15. Colorectal Disease Ó 2012 The Association of Coloproctology of Great Britain and Ireland. 14, 1152–1154 Gustavo Saposnik, MD, MSc, FAHA, Chair; Fernando Barinagarrementeria, MD, FAHA, FAAN; Robert D. Brown, Jr, MD, MPH, FAHA, FAAN; Cheryl D. Bushnell, MD, MHS, FAHA; Brett Cucchiara, MD, FAHA; Mary Cushman, MD, MSc, FAHA; Gabrielle deVeber, MD; Jose M. Ferro, MD, PhD; Fong Y. Tsai, MD; on behalf of the American Heart Association Stroke Council and the Council on Epidemiology and Prevention. *Diagnosis and Management of Cerebral Venous Thrombosis A Statement for Healthcare Professionals From the American Heart Association/American Stroke Association*
16. Leach JL, Fortuna RB, Jones BV, Gaskill-Shibley MF. Imaging of cerebral venous thrombosis: current techniques, spectrum of findings, and diagnostic pitfalls. *Radiographics*. 2006;26(suppl 1):S19 –S41.
17. Yamini B, Loch Macdonald R, Rosenblum J. Treatment of deep cerebral venous thrombosis by local infusion of tissue plasminogen activator. *Surg Neurol*. 2001;55:340 –346.
18. Crassard I, Bousser MG. Headache in patients with cerebral venous thrombosis [in French]. *Rev Neurol (Paris)*. 2005;161:706–708.
19. Lin A, Foroozan R, Danesh-Meyer HV, De Salvo G, Savino PJ, Sergott RC. Occurrence of cerebral venous sinus thrombosis in patients with presumed idiopathic intracranial hypertension. *Ophthalmology*. 2006; 113:2281–2284.
20. Cantu C C, Barinagarrementeria F. Cerebral venous thrombosis associated with pregnancy and puerperium: review of 67 cases. *Stroke* 1993;24:1880-4.
21. Yuh WT, Simonson TM, Wang AM, Koci TM, Tali ET, Fisher DJ, Simon JH, Jinkins JR, Tsai F. Venous sinus occlusive disease: MR findings. *AJNR Am J Neuroradiol*. 1994;15:309–316.