



Journal Homepage: -[www.journalijar.com](http://www.journalijar.com)  
**INTERNATIONAL JOURNAL OF  
 ADVANCED RESEARCH (IJAR)**

Article DOI: 10.21474/IJAR01/11639  
 DOI URL: <http://dx.doi.org/10.21474/IJAR01/11639>



### RESEARCH ARTICLE

#### INCREASE IN RETENTION OF THE TOTAL REMOVABLE MANDIBULAR PROSTHESIS: ROLE OF THE RHEIN 83 ATTACHMENT

Dr. A. Taouili<sup>1</sup> and Pr. S. Bellemkhannate<sup>2</sup>

1. Resident doctor, Department of Removable Prosthodontics, Faculty of Dentistry, Hassan II University of Casablanca, Morocco.
2. Professor and Head of the Removable Prosthodontics service at the Casablanca dental consultation and treatment center (CCTD). Department of Removable Prosthodontics, Faculty of Dentistry, Hassan II University of Casablanca, Morocco.

#### Manuscript Info

##### Manuscript History

Received: 05 July 2020  
 Final Accepted: 10 August 2020  
 Published: September 2020

##### Key words:-

Complete Removable Prosthesis, Axial Attachment, Overdenture, Residual Roots

#### Abstract

The complete mandibular prosthesis is a challenge for the practitioner and the unfavourable anatomophysiological factors, including the small bearing surface and the importance of resorption often compromises prosthetic retention. The use of root stumps is also a reliable alternative leading to a better prosthetic integration by increasing retention, if the total prosthesis is connected to these root stumps via axial ball or bar connection attachments. In addition, this prosthetic alternative considerably improves the patient's masticatory coefficient and their comfort during the performance of their oral functions, provided that the imperatives of root conservation as well as clinical and laboratory techniques are respected. We propose to illustrate by means of a clinical case where we used the Rhein83 attachment .

Copy Right, IJAR, 2020.. All rights reserved.

#### Introduction:-

Retention and instability problems are the main complaint in full mandibular prosthesis. However, the use of complementary means of retention, when conditions permit, is a precious recourse. In this context, the indication of supra-radicular attachments for therapeutic purposes of sustentation or retention is largely justified in the mandible because of the small bearing surface. the supra-radicular prosthesis has several advantages, namely

1. The maintenance of the bone capital by avoiding the process of alveolar resorption...
2. Maintenance of desmodontal proprioception,
3. Improvement of the retention and stabilization of the prosthesis
4. Improving comfort
5. The absence of fibromucosal overload.(1)

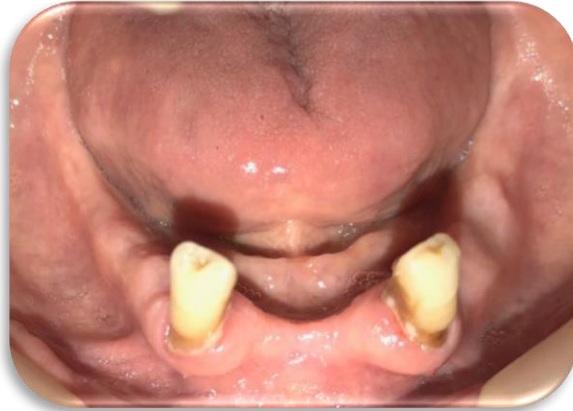#### Clinical case:

A 68 year old patient, balanced diabetic, consults for a prosthetic rehabilitation, demanding on the aesthetic level and especially on the functional level, he expresses his desire to keep his residual teeth.

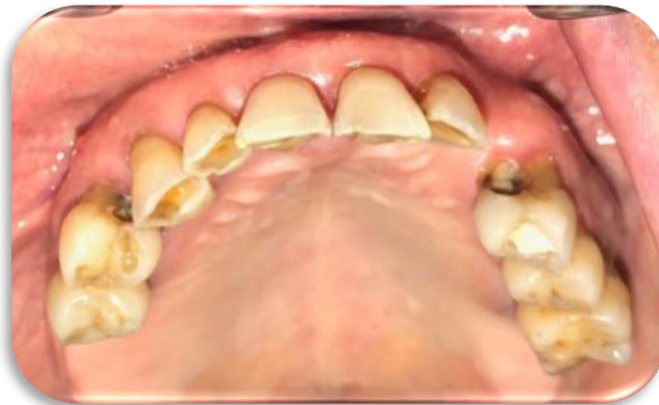Endobuccal examination shows partial edentulism in the maxilla of cl I mode 1 of kennedy (fig. 2) and subtotal edentulism in the mandible with persistence of canines (fig. 1).

Panoramic radiography reveals canines of sufficient root height with bone volume covering 2/3 of the root and well executed endodontic treatment (fig. 3).

The quality of the periodontal , the favorable bone level and the financial conditions of the patient led us to the realization of a supra-radicular mandibular prosthesis with two axial attachments of the Rhein 83 .

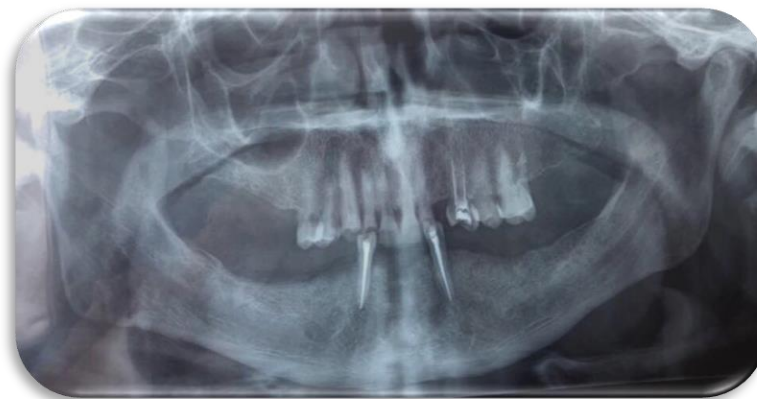

**Figure 1:-** Subtotal mandibular edentulism with persistence of 33 and 43.



**Figure 2:-** Subtotal mandibular edentulism with persistence of 33 and 43 .

+



**Figure 3 :-** Panoramic radiograph before treatment.

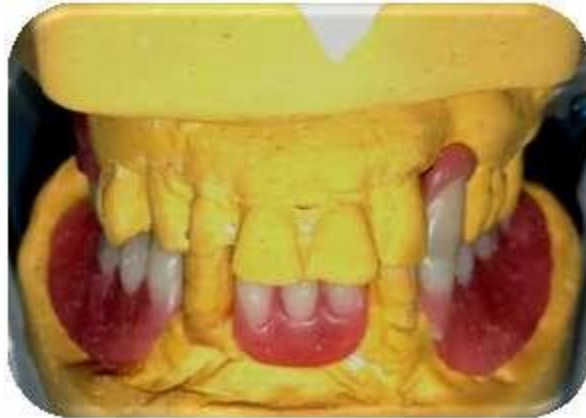**Diagnostic and therapeutic approach :****Diagnostic phase:**

The study phase is an essential prerequisite, it allows to analyze the occlusion plane and to assess the functional space.

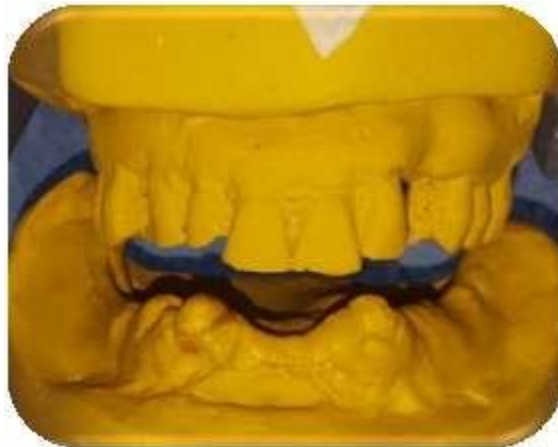As a result, The models are then mounted on an articulator in order to evaluate the height necessary for good integration of the attachments and prosthetic teeth within the framework of a suitable aesthetics (fig. 4).

The realization of a direct assembly materializing the prosthetic project will make it possible to: (fig. 5,6,7).

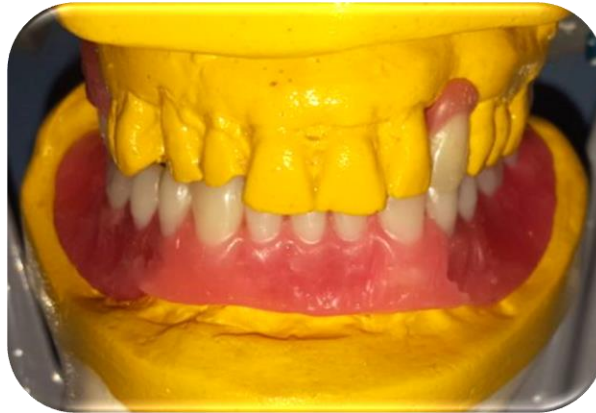1. Validate the aesthetic result
2. Realize the vestibular and lingual keys guiding the positioning of the attachments
3. Validate the occluso-prosthetic scheme



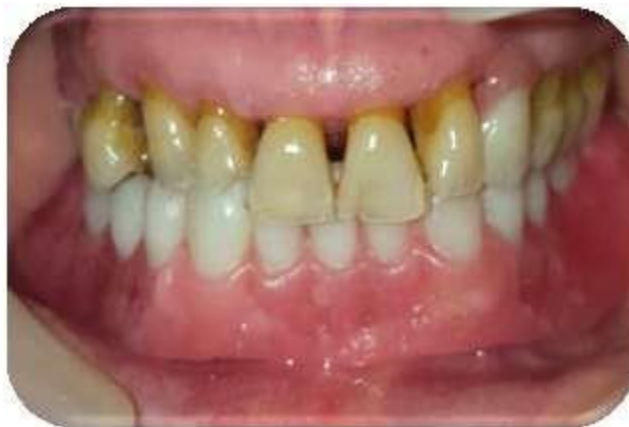**Figure 4:-** Evaluation of the prosthetic height available on study models.



**Figure 5:-** Director assembly objectivizing the space sufficient prosthetics in the sagittal, transverse and antero-posterior directions.



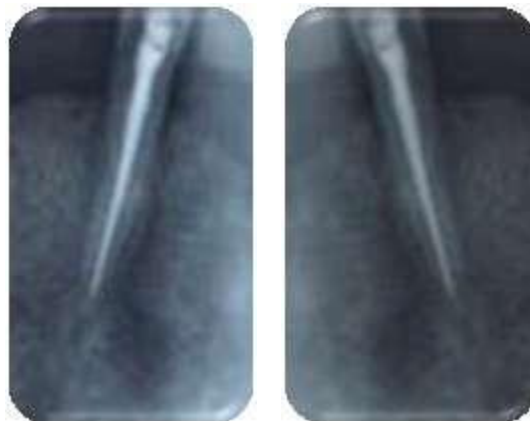
**Figure 6:-** Director assembly after simulation overdenture on the plaster model.



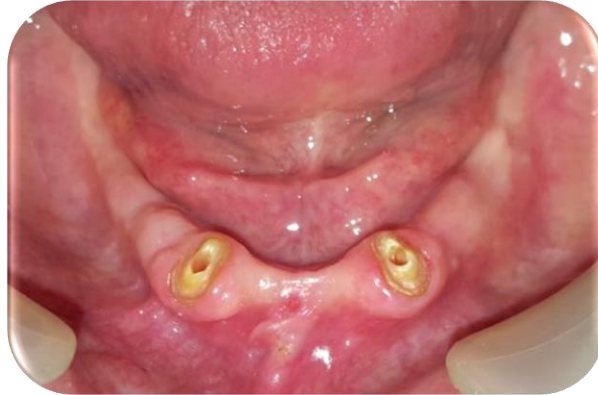**Figure 7:-** Fitting of the directing assembly for validation of the DVO and the relationship maxillomandibular.

**Pre-prosthetic phases:**

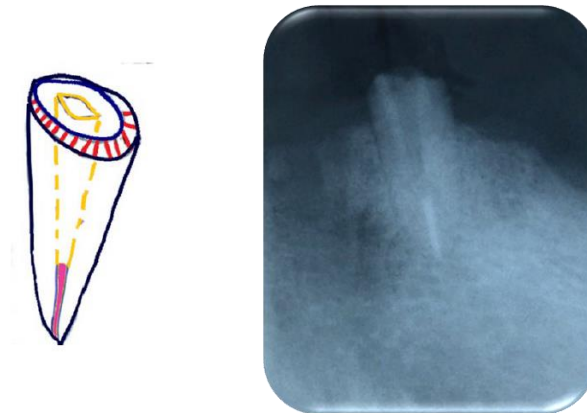
The canines have long roots, with good bone anchoring. Endodontic preparation is performed followed by a tight filling of the 33 and 43 (Fig. 8).



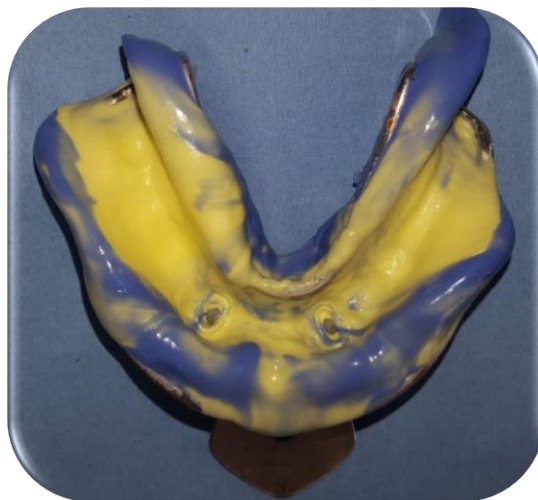
**Figure 8:-** Endodontic treatment on 43/33.



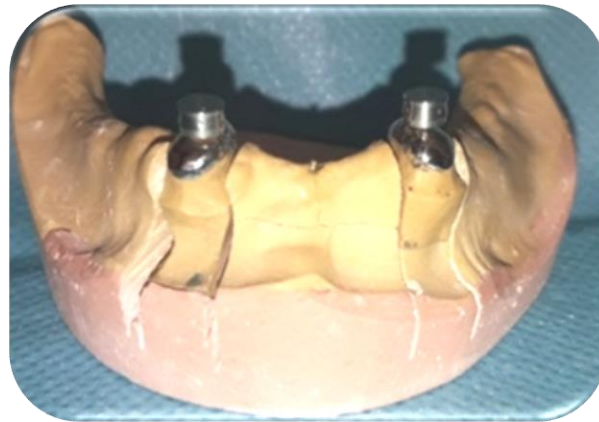
**Figure 9:-** Peripheral juxta gingival preparation with 1.5 mm leave



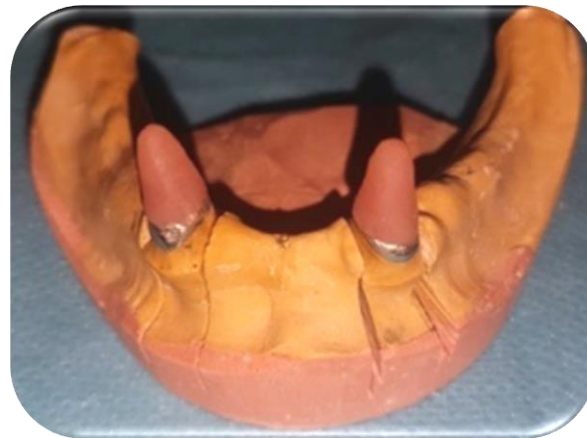**Figure 10:-** Preparation of 2/3 of the intra-radicular anchorage.



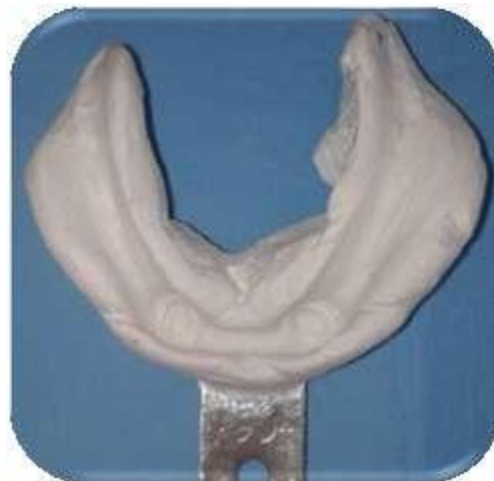**Figure 11:-** Impression in one time with an elastomer in two viscosities for the realization of the supradicular caps.



**Figure 12:-** Rhein 83 attachments.



**Figure 13:-** Surmounted copings resin cylinders.



**Figure 14:-** Primary plaster impression.

**Prosthetic phase:****Peripheral preparation and development of the canal housing**

1. Peripheral juxta gingival preparation with a peripheral leave of 1.5 mm which follows the shape of the gingival festoon (fig. 9)
2. Occlusal tray with 1mm thick residual walls
3. Ovoid preparation of the canal entry orifice
4. Canal preparation at 2/3 of the root and leaving 4 mm of obturation apically; (fig. 10)

**Impression of canal housing**

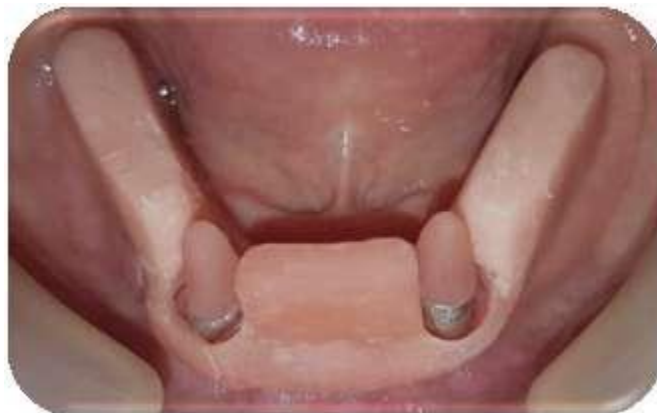A double-mix impression is made by injecting a low-viscosity elastomer into the canals, placing the stakes and the whole is covered with an impression tray charged with a high-viscosity elastomer (Fig. 11).

**Attachment placement**

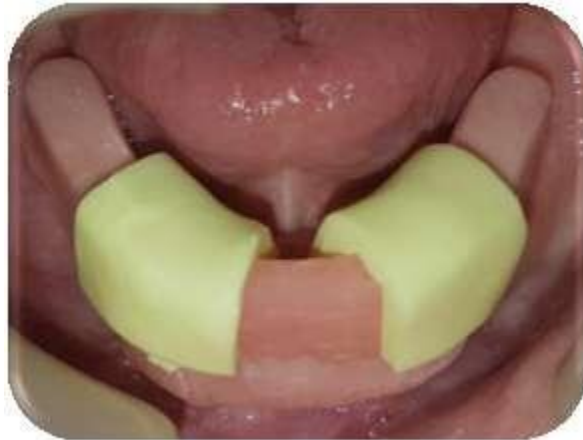The preparation of the attachments in the laboratory must respect a strict parallelism on the one hand between the two attachments and on the other hand between the attachments and the axis of the anterior ridge (fig. 12)

**Fitting and Validation of the copings topped by the resin cylinders and primary impression of the prosthetic support surfaces.**

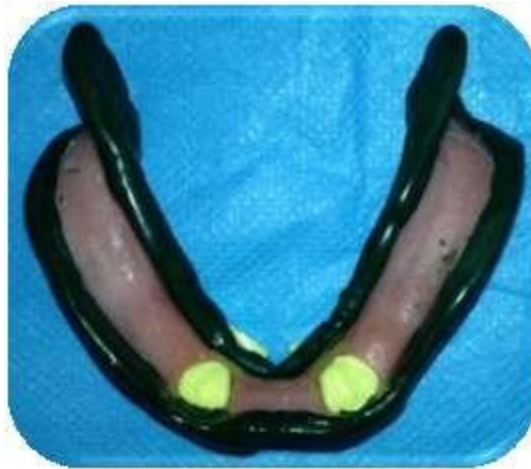After validating the adaptation of the copings and the retention has been checked (Fig. 13), a primary plaster impression (Fig. 14) of the entire mandibular support surface is made with a commercial impression tray in order to make an individual impression tray that is notched opposite to the roots (Fig. 15).



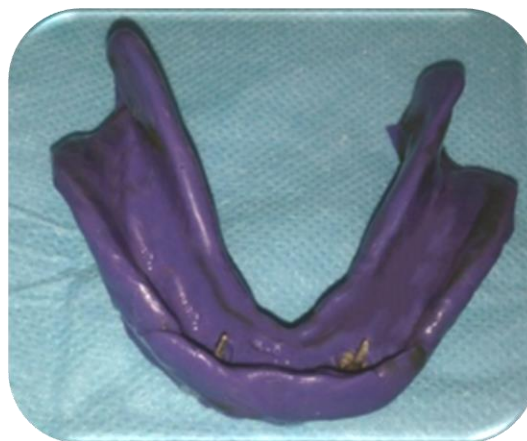**Figure 15:-** Perforated mandibular individual impression tray opposite the roots.



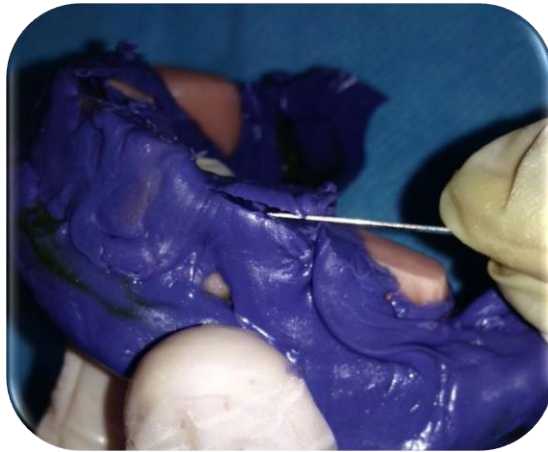
**Figure 16 :-** Perforations filled with a high viscosity elastomer.



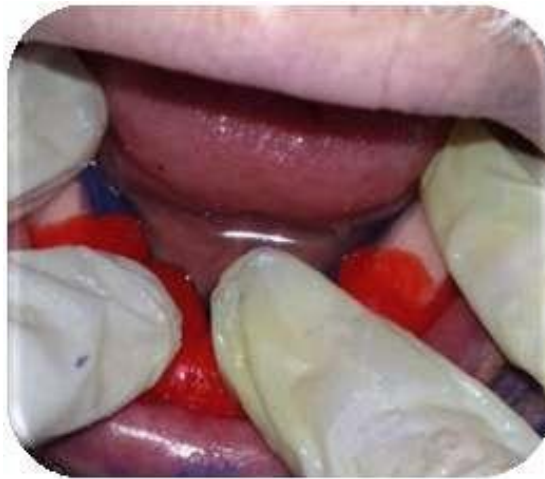**Figure 17:-** Peripheral and sublingual joint registration



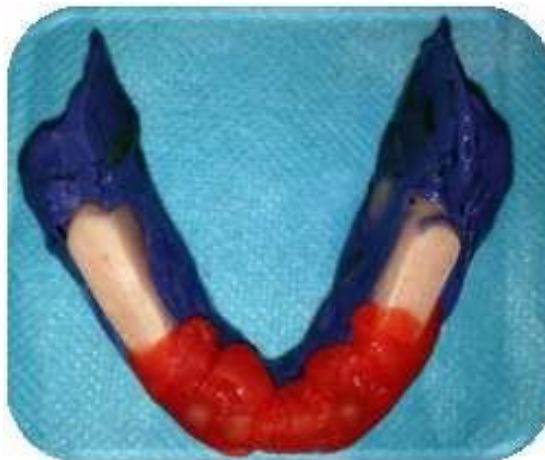**Figure 18:-** Secondary impression with a polyether (Impregum).



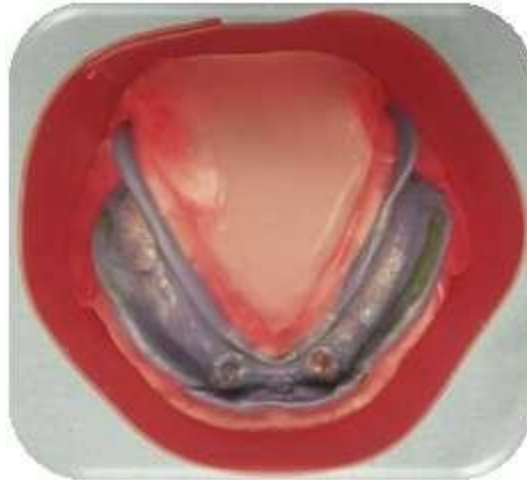**Figure 19:-** Removal of excesses.



**Figure 20:-** Bonding of the copings to the secondary impression with DURALEY resin.



**Figure 21:-** Extrados of the secondary impression.



**Figure 22:-** Formwork of the overall impression taking the copings.

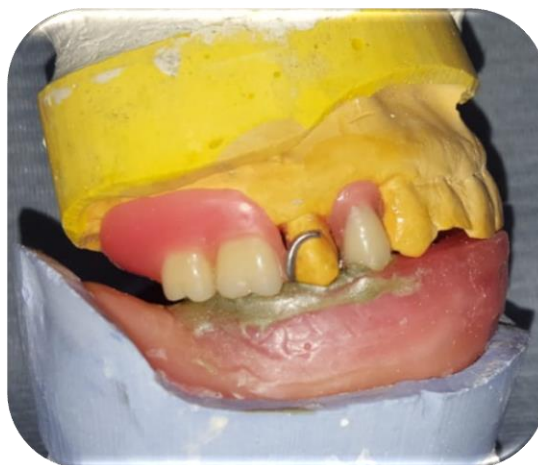#### **Functional secondary impression**

The remarginage (fig. 17) is carried out classically as in conventional PAT after having closed the fenestrations with a high viscosity elastomer, the objective of which is to ensure the continuity of the bead and the hermeticity of the base of the PEI, necessary for check the effectiveness of the sublingual joint (fig. 16)(3,4)

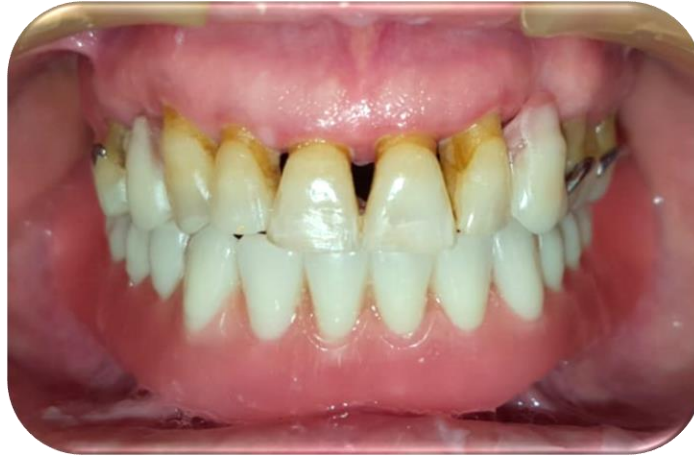Next, the Light Silicone coated posts are inserted, then the individual impression tray is filled with an Impregum-type polyether is inserted in the mouth, applied to the osteomucosal support surfaces, then a digital pressure is exerted on the beads while the patient is invited to mobilize his peripheral and lingual musculature in extreme functional movements(fig. 18).(5)

After the impression material has completely set and the excess material has been removed (fig. 19) to proceed the bonding of the resin beads to the copings using DURALEY resin (fig. 20,21) (5)

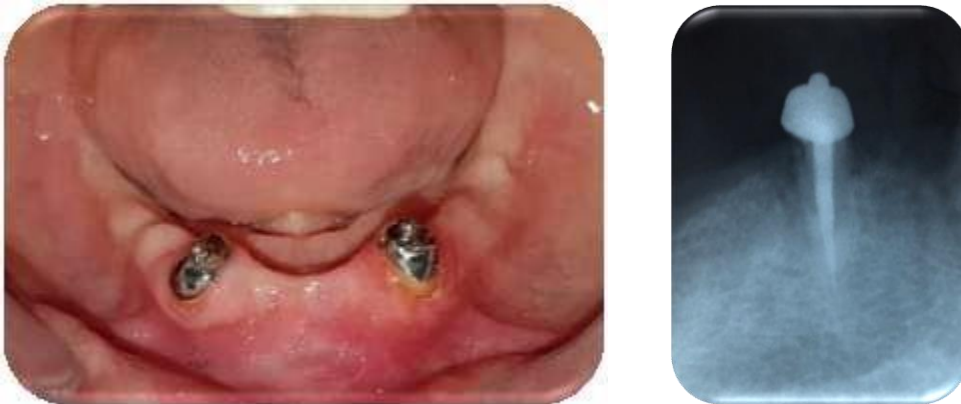Obtaining a global impression (fig. 22) taking into account the maximum tissue depressibility of the fibromucosal support surface and the desmodontium of the residual roots.(6)



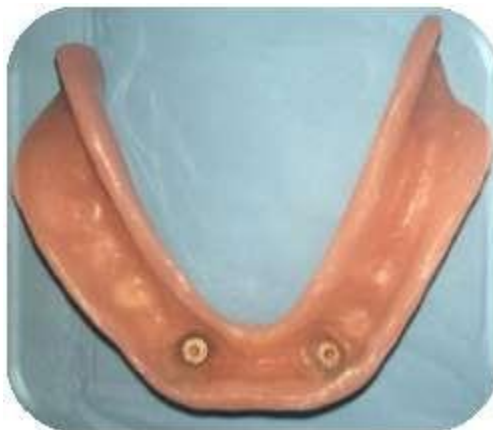**Figure 23:-** Recording of the RIM with the provisional maxillary prosthesis.



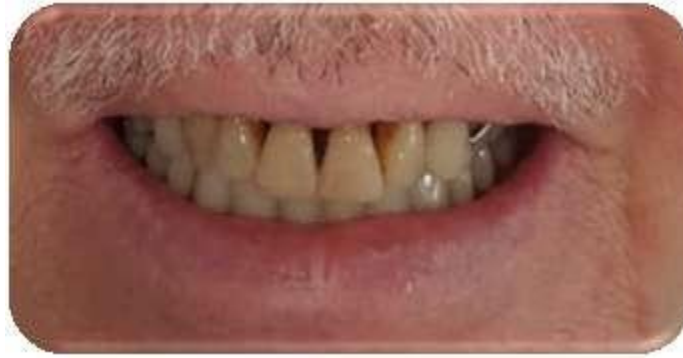**Figure 24:-** Clinical validation of the assembly of the teeth



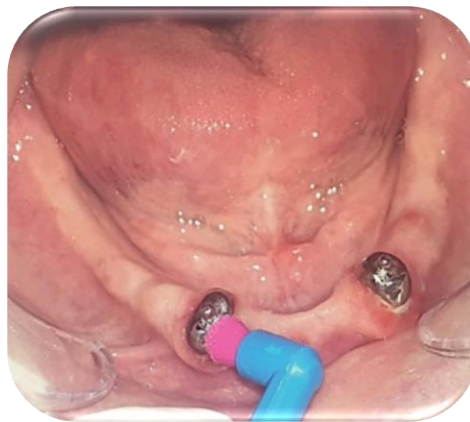**Figure 25:-** Definitive sealing of copings with glass ionomer cement.



**Figure 26:-** Fixing of the female part in the laboratory.



**Figure 27** :Patient satisfaction smile



**Figure 28:-** Demonstration for the patient of the use of the single-tooth brush.

#### **Recording of RIM and transfer of models to articulator (fig. 23)**

The recording of the intermaxillary report is carried out through the polymerized direct assembly of the prosthetic project with the correct vertical dimension and in centered relationship.(7)

#### **Aesthetic and functional assembly and fitting in the mouth(fig. 24)**

the choice of prosthetic teeth is followed by the assembly respecting the aesthetic and functional rules: respect of the prosthetic corridor, orientation of the occlusal curves, inter-arch relations and respect of the fully balanced occlusion scheme. The assembly of the teeth is tested at the same time as that of the cast maxillary partial denture.

#### **Polymerization and insertion in the mouth**

The sealing of the copings is carried out using a glass ionomer cement under digital pressure, the excess cement is removed, all validated by a radio control. (fig. 25)

Fixation of the female part (Fig. 26) can be carried out in the laboratory or directly in the mouth. (8)

In our case, it was done in the laboratory, then the prosthesis is placed in the mouth under occlusal pressure, the patient is not allowed to remove it for 24 hours until the cement has set to avoid any risk of loosening. (fig. 27)

#### **Maintenance and prosthetic follow-up**

Prosthetic success in the medium and long term is closely linked to the Control and maintaining rigorous hygiene of both at the level of the dental abutments and at the level of the prostheses using a single tooth brush (fig. 28) and dento-periodontal-prosthetic maintenance sessions are carried out at 1 week after placement of the prosthesis, then at 1 month and then every 6 months for 2 years and then once a year.

#### **Discussion:-**

1. Several factors affect prosthetic stability at the mandibular level, in particular the degree of resorption, the reduced support surface, the presence of the tongue, the disappearance of the desmodontal proprioception as well as the quality of the salivary flow resulting in prosthetic imbalance and a masticatory inefficiency.(9)

2. The success of prosthetic rehabilitation is based on respect for the triad of equilibrium including stabilization, sustentation and retention.
3. Improvement of the above factors can be improved either by the reasoned use of the support surface and the peri-prosthetic environment, or optimized by the use of complementary retention means.
4. In a supraradicular prosthesis, sustentation and stabilization in addition to retention are clearly enhanced by the attachment system connected to the root pillars .(10)
5. There is a wide range of axial attachment types: The RHEIN 83 attachment system used in this case is a :
  - a. Spherical attachment
  - b. Type " push button " or ball
  - c. Providing an articulated mechanical connection
  - d. The male part is most often attached to the dental abutment which is inserted into the female part included in the intrados of the removable prosthesis. (11)
6. RHEIN 83 has elastic retention, allows to control flexion and resilience as well as shock absorption.(12)

### Conclusion:-

The root-anchored prosthesis remains a high-performance technique for optimizing the prosthetic balance of a complete removable prosthesis.

The conservation and exploitation of the residual roots, is of major interest in the aesthetic and functional improvement of conventional removable prostheses.

However, the long-term success of this restoration depends on many factors, including the mastery of the technique, the appropriate choice of retention means and the quality of the occlusion.

The prognosis depends on the patient's oral hygiene and prosthetics, and on the quality of maintenance during periodic inspection visits to the dental practice.

### References:-

1. Amzalag G, Batarec E, Schoendorff R, Buch D, Assemat-Tessandier X. Prothèses supraradiculaires «overdentures». Paris : Éditions CdP 1988.
2. M Gargari, V Prete, M Pujia, FmCeruso. Development of patient-based questionnaire about aesthetic and functional differences between overdentures implant-supported and overdentures tooth-supported. Study of 43 patients with a follow up of 1 year. Oral & implantology – Anno V-N. 4/2012.
3. Schoendorff R , Millet C . Rétention en prothèse complète . EncyclMédChir (Paris- France), stomatologie-odontologie II, 23-325-B-05, 1995, 6p.
4. Martin JP, Citterio H, Coeuriot JL. Amélioration de la stabilité dynamique des prothèses adjuvées totales ; proposition pour une conduite anatomo-physiologique de la restauration prothétique . RevodontoStomatol 1993;22(5).
5. Rignon-Bret CH. Attachement et prothèses complètes supra radiculaires et supra- implantaires. ÉditionCdp 2008.
6. Rignon-Bret CH, Rignon-Bret JM. Prothèse amovible complète prothèse immédiate prothèse supraradulaire et implantaire. Collection JPIO, Edition CdP, 2004.
7. Taddei C, Metz M, Waltmann E. Prothèse amovible complète : les
8. solutions au maxillaire pour les cas difficiles. Cah. Prothèse. Juin 2002, n°
9. 118.
10. Rignon-Bret C, Rignon-Bret JM. Intérêt et conception des prothèses amovibles supra-radiculaires. In : Prothèse amovible complète. Prothèse immédiate, prothèse supra-radulaire et implantaire. Reuil-Malmaison : CdP, 2002 : 177-186.
11. Gibert Y, Soulet H, Blandin M. Phénomènes rétentifs en prothèse adjointe complète. EncyclMédChir (Paris, France), Odontologie, 23325 B05, 4-1987, 6p.
12. Unger F, Hoornaert A, Estrabaud Y. Indication et mise en œuvre attachements axiaux supra-radiculaires. RéalitésCliniques 1998.
13. K. Jayasree • M. Bharathi • V. Dileep Nag , Precision Attachment: Retained Overdenture J Indian ProsthodontSoc (Jan-Mar 2012).
14. Deshraj Jain, Prosthodontic Rehabilitation using Attachment Retained Overdenture-Case Reports, September 2015, 10.9790/0853-14821723.