



Journal Homepage: [-www.journalijar.com](http://www.journalijar.com)

INTERNATIONAL JOURNAL OF ADVANCED RESEARCH (IJAR)

Article DOI:10.21474/IJAR01/11839
DOI URL: <http://dx.doi.org/10.21474/IJAR01/11839>



RESEARCH ARTICLE

A CASE REPORT ON TAKAYASU ARTERITIS

Hari Chandana Pুনukula, Bospali Kavya Sree, Vaka Pratyusha and Swetha Bospali

Manuscript Info

Manuscript History

Received: 10 August 2020

Final Accepted: 12 September 2020

Published: October 2020

Key words:-

Takayasu Arteritis, Renal Artery
Stenosis, Hypertension

Abstract

Takayasu's arteritis primarily affects young women. Takayasu arteritis (TA) is a type of primary systemic vasculitis mainly affecting the medium and large arteries. The signs and symptoms are due to systemic inflammation or ischemia of an organ or limb and include angiodynia, claudication, peripheral pulselessness, murmurs, ischemic stroke, myocardial infarction and severe systemic arterial hypertension. The disease tends to affect more women than men. The current case of Takayasu arteritis type V focuses on a 21 year female who complained of cold, cough, fever, facial puffiness since 2 months, along with bilateral renal artery stenosis, and resistant hypertension.

Copy Right, IJAR, 2020,. All rights reserved.

Introduction:-

Takayasu arteritis (TA), also known as "pulseless disease", is a type of primary systemic vasculitis affecting medium and large arteries, including the aorta and its branches, as well as the pulmonary and coronary arteries. It is a chronic inflammatory disease of unknown origin characterized by granulomatous vasculitis, leading to thickening, dilatation, stenosis, and/or aneurysm formation of the involved vessels. Furthermore, the signs and symptoms exist due to systemic inflammation or ischemia of an organ or limb, and encompass angiodynia, claudication, peripheral pulselessness, murmurs, ischemic stroke, myocardial infarction, severe systemic arterial hypertension, etc. TA tends to affect females more than males, with 80% of patients being female.

Furthermore, TA is associated with significant morbidity and can be life threatening. Around 20% of patients experience monophasic and self-limited disease, whereas others can have a progressive or relapsing/remitting disease. Moreover, the overall 10-year survival rate for this disease is approximately 90% which can be reduced in the presence of major complications. Here we present a case of TA in a 21-year-old female.

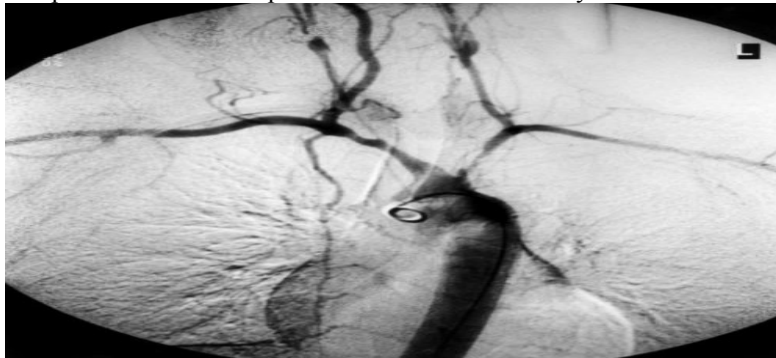


Fig 1:- Takayasu arteritis.

Clinical features:

1. Diminished or absent pulses in 84–96% of patients associated with limb claudication and blood pressure discrepancies.
2. Vascular bruits in 80–94% of patients, often multiple, and particularly affecting the carotids, subclavian, and abdominal vessels.
3. Hypertension in 33–83% of patients, generally reflecting renal artery stenosis, which is seen in 28–75% of patients.
4. Takayasu retinopathy in up to 37% of patients.
5. Aortic regurgitation resulting from dilatation of the ascending aorta, separation of the valve leaflets, and valve thickening in 20–24%.
6. Congestive cardiac failure associated with hypertension, aortic regurgitation, and dilated cardiomyopathy.
7. Neurological features secondary to hypertension and/or ischaemia, including postural dizziness, seizures, and amaurosis.
8. Pulmonary artery involvement in 14–100% of patients, depending on the method used to assess pulmonary vasculature. Oligoemic lung fields on plain chest X-ray correlate with pulmonary vasculopathy in approximately a third of cases. Pulmonary artery disease shows little correlation with the systemic pattern of arterial involvement, but can be useful in the differential diagnosis by helping to confirm Takayasu arteritis.
9. Other symptoms include dyspnoea, headaches, carotodynia, myocardial ischaemia, chest wall pain, and erythema nodosum.

Treatment:

Medical management of Takayasu arteritis depends on the disease activity and the complications that develop. Some patients have only mild forms of Takayasu arteritis; others deteriorate considerably. The two most important aspects of treatment are controlling the inflammatory process and controlling hypertension.

Corticosteroids:

Corticosteroids are the mainstay of therapy for active Takayasu arteritis. However, some patients may also require cytotoxic agents, to achieve remission and taper of long-term corticosteroid treatment.

Oral corticosteroids are started at 1 mg/kg daily or divided twice daily and tapered over weeks to months as symptoms subside.

Long-term, low-dose corticosteroid therapy may be required. Osteoporosis prevention when patients are started on corticosteroids should be seriously considered.

IL-6 receptor inhibitor:

Evidence supports interleukin-6 (IL-6) as a major component in the inflammatory process of large-vessel vasculitis, and case reports and observational studies have shown that the humanized monoclonal antibody tocilizumab, which blocks the soluble IL-6 receptor, can produce clinical responses and have a steroid-sparing effect in patients with refractory Takayasu arteritis, including patients refractory to tumor necrosis factor (TNF) inhibitors.

B-cell depletion:

Rituximab, a chimeric IgG1 antibody that binds to CD20 expressed on the surface of B cells, has been shown to improve clinical signs and symptoms of Takayasu arteritis.

Cytotoxic agents:

Cytotoxic agents are used for patients whose disease is steroid resistant or relapsing. These agents are usually continued for at least 1 year after remission and are then tapered to discontinuation. Methotrexate, azathioprine, and cyclophosphamide are among the drugs used in Takayasu arteritis.

Cardiovascular procedures:

Bypass graft surgery is the procedure with the best long-term patency rate. Percutaneous balloon angioplasty can provide good outcomes for short lesions. Angioplasty and stenting have been used to treat recurrent stenosis. Conventional stents seem to be associated with high failure rates in patients with Takayasu arteritis. Other procedures include aneurysm clipping and revascularization.

Cardiovascular risk factors:

Strict management of traditional cardiovascular risk factors such as dyslipidemia, hypertension, and lifestyle factors that increase the risk of cardiovascular disease is mandatory to minimize secondary cardiovascular complications. These complications are the major cause of death in Takayasu arteritis.

Hypertension is treated with antihypertensive agents, and aggressive therapy is necessary to prevent complications. Low-dose aspirin may have a therapeutic effect in large vessel vasculitis.

Antiplatelet agents and heparin may prove useful in preventing stroke. Warfarin also has been used. The literature reports a case of improvement in renal and systemic function with low-dose intravenous (IV) heparin therapy (10,000 U/d) followed by oral anticoagulant and antiplatelet agents.

Pregnancy:

Pregnancy is an important concern in Takayasu arteritis; these patients require aggressive treatment. Pregnancy may exacerbate hypertension and/or cardiovascular complications and can increase the risk for maternal and fetal morbidity and mortality. Pregnancy may be safer during presumed remission of Takayasu arteritis. Fetal monitoring is indicated in patients with suspected complications of pregnancy.

Surgical Therapy:

Critical stenotic lesions should be treated by angioplasty or surgical revascularization during periods of remission. Indications for surgical repair or angioplasty are as follows:

Renovascular stenosis causing hypertension

Coronary artery stenosis leading to myocardial ischemia

Extremity claudication induced by routine activity

Cerebral ischemia and/or critical stenosis of 3 or more cerebral vessels

Aortic regurgitation

Thoracic or abdominal aneurysms larger than 5 cm in diameter

Severe coarctation of the aorta.

Case report:

A 21 year old female patient reported to Asian institute of gastroenterology and oncology in department of cardiology, somajiguda, Hyderabad on 24-02-20 complaining of:

1. Cold
2. Cough
3. Fever
4. Facial puffiness
5. Bilateral Renal artery stenosis
6. Resistant hypertension

Physical examination:

| PARAMETERS | OBSERVED RANGE |
|----------------------|-----------------------|
| BLOOD PRESSURE(BP) | 170/110mm/Hg |
| Pulse rate(PR) | 106bpm |
| Respiratory rate(RR) | 18 breaths per minute |
| Heart rate(HR) | 106bpm |
| Temperature | 100 ⁰ F |

Diagnostic tests:

1. CBP
2. Liver function tests
3. Electrolytes
4. Renal functional tests
5. Renal angiogram
6. Other investigations i.e, cholesterol, triglycerides, HDL, LDL.

Based on history, clinical manifestations and above laboratory findings it was confirmed that the patient is suffering from Takayasu arteritis type V and bilateral renal artery stenosis, resistant hypertension.

Discussion:-

Takayasu's disease is a chronic inflammatory disease of large and medium sized arteries, involving the aorta and its main branches, the pulmonary arteries, and the coronary tree. Since the original report of Takayasu's disease in 1908, the estimated worldwide incidence is 2.6 cases per million per year, with women more commonly affected than men. Cardiac features are present in up to 40% of cases. Patients usually have no risk factors for atherosclerosis and yet have atheromatous aorta, suggesting the importance of inflammation in atherosclerosis.

Vascular changes lead to main complications, including hypertension, most often due to renal artery stenosis or, more rarely, stenosis of the suprarenal aorta; aortic insufficiency due to aortic valve involvement; pulmonary hypertension, and aortic or arterial aneurysm. Cardiomyopathy, myocarditis, and pericarditis have been also reported. Patients with pulmonary arterities may develop pneumonia, interstitial pulmonary fibrosis, and alveolar damage. Other clinical manifestations include vertebra-basilar ischemia, carotid stenosis, and hypertensive encephalopathy. Takayasu's disease has also been associated with inflammatory bowel disease, glomerulonephritis, systemic lupus, rheumatoid arthritis, and ankylosing spondylitis. Less common associations have been seen with sensorineural hearing loss. The retinopathy originally described by Takayasu's is seen in only about one-quarter of patients and is usually associated with carotid artery involvement.

In this case the patient was observed with BP- 170/110 and pulse rate-106bpm, respiratory rate was 18breaths per minute, temperature was observed to be 100°F.

The Complete Blood Picture of the patient shows that the haemoglobin was found to be 10.9%; RBC count 4.19million cells/ cumm; WBC count 13.80cells/cumm; platelet count 2.4laks cells/ cumm; lymphocyte count was 3.82; monocytes 1.19; eosinophils-0.06; neutrophils-8.69; ESR-41mm; MCV-75.2fl; MCH-21.8pg; MCHC-29.1g/dl.

Liver function tests shows that total bilirubin was 0.73mg/dl; direct bilirubin-0.12mg/dl; SGPT (ALT)-18.13U/L; SGOT (AST)-14.58.

Renal function tests with a urea level of42.8mg/dl and serum creatinine of 0.91mg/dl. Other investigations shows cholesterol level-202.6mg/dl; triglycerides-130mg/dl; HDL-42mg/dl; LDL-130mg/dl.

The patient was treated with corticosteroid (Prednisolone)-40mg once a day for 5 days; calcium channel blocker (clonidine)-10mg twice a day for 7 days; beta blocker (metoprolol)-50mg twice a day for 7days. The patient was followed up for 10 days by administering iron supplements and multivitamin and beta lactum antibiotics and was planned for discharge as there were no further complaints.

References:-

1. Lupi-Herrera E, Sánchez-Torres G, Marcushamer J, et al. Takayasu arteritis. Clinical study of 107 cases. Am Heart J 1977; 93: 94–103. [PubMed] [Google Scholar]
2. Numano F, Okawara M, Inomata H, et al. Takayasu's arteritis. Lancet 2000; 356: 1023–5. [PubMed] [Google Scholar]
3. Numano F, Kakuta T. Takayasu arteritis—five doctors in the history of Takayasu arteritis. Int J Cardiol 1996; 54: S1–10. [PubMed] [Google Scholar]

4. Takayasu M. A case with peculiar changes of the retinal central vessels [in Japanese]. Acta of the Ophthalmic Society of Japan 1908; 12: 554–5. [Google Scholar]
5. Shimizu K, Sano K. Pulseless disease. Journal of Neuropathology and Clinical Neurology 1951; 1:37–1.47. [PubMed]
6. Hall S, Barr W, Lie JT, et al. Takayasu arteritis. A study of 32 North American patients. Medicine 1985; 64: 89–99. [PubMed] [Google Scholar]
7. Ishikawa K. Natural history and classification of occlusive thromboangiopathy (Takayasu's disease). Circulation 1978; 57: 27–35. [PubMed] [Google Scholar]
8. Shelhamer JH, Volkman DJ, Parrillo JE, et al. Takayasu's arteritis and its therapy. Ann Intern Med 1985; 103: 121–6. [PubMed] [Google Scholar]
9. Subramanyan R, Joy J, Balakrishnan KG. Natural history of aortoarteritis (Takayasu's disease). Circulation 1989; 80: 429–37. [PubMed] [Google Scholar]
10. Kerr GS, Hallahan CW, Giordano J, et al. Takayasu arteritis. Ann Intern Med 1994;120 : 919–29. [PubMed] [Google Scholar]
11. Mont'Alverne AR, Paula LE, Shinjo SK: Features of the onset of Takayasu's arteritis according to gender. Arq Bras Cardiol. 2013; 101(4): 359–63. PubMed Abstract | Publisher Full Text | Free Full Text
12. Lalmachhuani PC, Daime SL, Ralte RL, et al.: A case of takayasu arteritis in elderly male patient. Indian Journal of Medical Research and Pharmaceutical Sciences. 2017; 4(12). Publisher Full Text
13. Ishikawa K. Natural history and classification of occlusive thromboangiopathy (Takayasu's disease). Circulation. 1978; 57(1):27-35. doi pubmed
14. Sharma BK, Sagar S, Singh AP, Suri S. Takayasu arteritis in India. Heart Vessels Suppl. 1992; 7: 37-43. doi pubmed
15. Kelly PJ, Furie KL, Kistler JP, Barron M, Picard EH, Mandell R, Shih VE. Stroke in young patients with hyperhomocysteinemia due to cystathionine beta-synthase deficiency. Neurology. 2003; 60(2):275-279. doi pubmed
16. Bracken P, Coll P. Homocystinuria and schizophrenia. Literature review and case report. J Nerv Ment Dis. 1985; 173(1):51-55. doi pubmed
17. Miles EW, Kraus JP. Cystathionine beta-synthase: structure, function, regulation, and location of homocystinuria-causing mutations. J Biol Chem. 2004; 279(29):29871-29874. doi pubmed.