

 <p>ISSN NO. 2320-5407</p>	<p>Journal Homepage: <a href="http://www.journalijar.com">www.journalijar.com</a></p> <h2 style="text-align: center;">INTERNATIONAL JOURNAL OF ADVANCED RESEARCH (IJAR)</h2> <p style="text-align: center;">Article DOI:10.21474/IJAR01/11858 DOI URL: <a href="http://dx.doi.org/10.21474/IJAR01/11858">http://dx.doi.org/10.21474/IJAR01/11858</a></p>	 <p>INTERNATIONAL JOURNAL OF ADVANCED RESEARCH (IJAR) ISSN 2320-5407 Journal Homepage: <a href="http://www.journalijar.com">http://www.journalijar.com</a> Article DOI:10.21474/IJAR01/11858</p>
---	--	---

### RESEARCH ARTICLE

#### COMPARISON BETWEEN STANDARD AND MOBILE DENTAL PHOTOGRAPHY

**Martin Mariyanov**

Assistant Professor, Medical University of Sofia, Bulgaria, Faculty of Dental Medicine, Department of Orthodontics.

#### Manuscript Info

##### Manuscript History

Received: 15 August 2020

Final Accepted: 18 September 2020

Published: October 2020

##### Key words:-

Mobile Dental Photography, Extraoral Photos, Intraoral Photos

#### Abstract

**Introduction:** With the constant improvement of technology in recent years, mobile dental photography is gaining more and more popularity. Mobile phones have almost completely replaced compact cameras in everyday life.

**Aim:** The aim is to determine whether a mobile phone can be used to take standard pictures of patients in daily dental practice.

**Material and methods:** A total of 330 extraoral photographs were taken of 33 patients. 10 photos were taken of each of them (5 extraoral and 5 intraoral). From the five photos there were one taken with a DSLR camera and four with a mobile phone with different magnification x2, x3, x4 and x5 and respectively from different distances. Eleven linear parameters were measured and compared.

**Results:** In the photos taken with a mobile phone there is a deformation of the image compared to the photos taken with a DSLR camera at all magnifications. The largest deformation is at twice the magnification. The image is close to the photos taken with a DSLR camera at four and five times the magnification.

**Conclusion:** The mobile phone is applicable for the extraoral dental photography. At four times magnification (x4) and distance of 110 cm the deformation of the image is negligible and the quality of the photos is good. For the intraoral photos if there is a need for an image with the correct and as close as possible to the actual proportions of the teeth, the first choice is the DSLR camera.

*Copy Right, IJAR, 2020,. All rights reserved.*

#### Introduction:-

Nowadays dental photography is an important part of the clinical practice in Dental Medicine. In some disciplines, such as Orthodontics, quality photographs are a mandatory part (Mariyanov et al., 2018). In other specialties, they are an integral part of the work protocol of dentists who publish scientific articles and/or present their cases to colleagues.

It is still believed that taking quality photos requires a DSLR camera or the most contemporary mirrorless full-format cameras. In recent years, compact cameras with removable lenses, which are smaller and more comfortable to work with, as well as smartphones, have become very popular. With the advancement of technology, the mobile phone is replacing more and more traditional devices such as dictaphones, calculators, cameras, video cameras and more. In

**Corresponding Author:- Martin Mariyanov**

Address:- Assistant Professor, Medical University of Sofia, Bulgaria, Faculty of Dental Medicine, Department of Orthodontics.

recent years mobile dental photography is gaining more and more popularity. The question is can the mobile phone replace the "irreplaceable" DSLR camera.

The main disadvantage of mobile phones is that when shooting with them, image distortion occurs (Samawi, 2017). The reason is that the lenses that integrate into them have very little focal length. The optimal focal length of a lens for dental photography is 100 mm (Kolarol et al., 2017 and Lozano, 2018), and in phones the focal length is from 2 mm to a maximum of 5 mm. The software in the phones solves this problem to some extent.

### Aim:-

The aim is to determine whether a mobile phone can be used to take standard pictures of patients in daily dental practice.

To achieve the formulated goal, the following tasks were set:

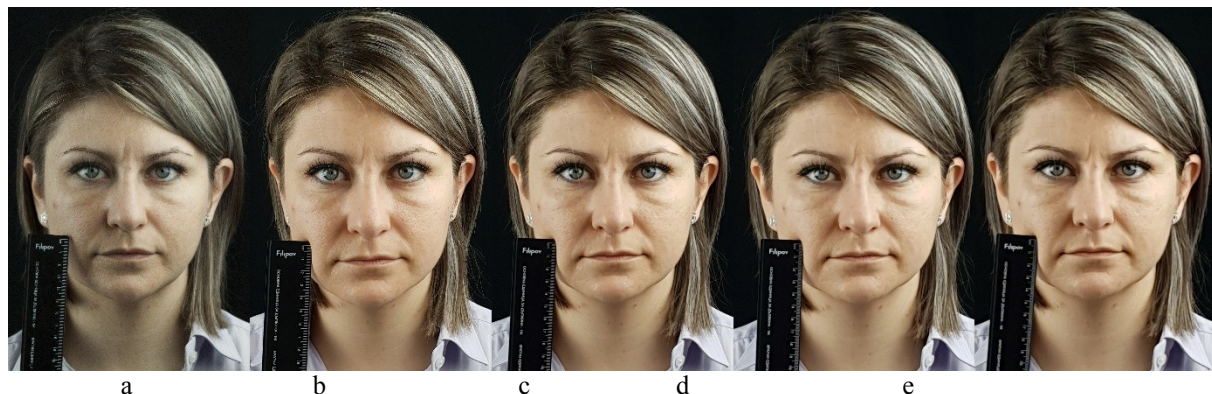
1. To compare the extraoral photos of patients taken with a DSLR camera and a mobile phone;
2. To compare the intraoral photos of patients taken with a DSLR camera and a mobile phone;
3. To give recommendations for the optimal distance from the photographed subject when shooting with a mobile phone in order to create quality photos.

### Material And Methods:-

A total of 330 extraoral photographs were taken of 33 patients. 10 photos were taken of each of them (5 extraoral and 5 intraoral). From the five photos there were one taken with a DSLR camera and four with a mobile phone with different magnification x2, x3, x4 and x5 and respectively from different distances (for extraoral photos: 10 cm, 20 cm, 30 cm and 40 cm, and for the intraoral photos: 50 cm, 80 cm, 110 cm and 140 cm). The purpose of zoom shooting was to increase the distance from the lens to the subject to reduce image distortion. In each extraoral photo, five linear indicators were measured - two in the vertical direction and three in the horizontal, and for the intraoral photos six linear parameters were measured - three in the vertical direction and three in the horizontal.

The extraoral photos were taken according to the established rules and requirements for dental photography (Mariyanov et al., 2017) for capturing the frontal view of the patient (fig.1):

1. The whole face, from hair to neck, should be visible;
2. The mouth should be closed with relaxed lips;
3. The vertical midline of the face should be in the middle of the image;
4. Both ears should be visible.

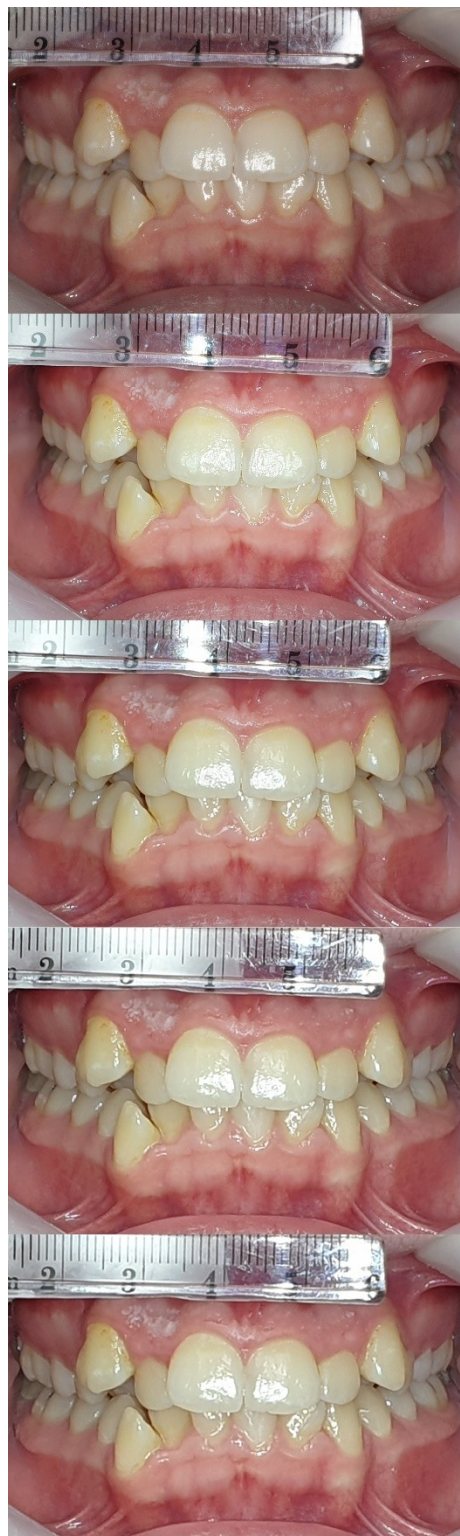

**Figure 1:-** The protocol for the extraoral photographs: a - taken with DSLR camera; b – taken with a mobile phone with magnification x2; c - taken with a mobile phone with magnification x3; d - taken with a mobile phone with magnification x4; e - taken with a mobile phone with magnification x5

The intraoral photos were also taken according to the established rules and requirements for dental photography (Pasquale and Pascoletti, 2012) for capturing the upper and lower dentition in a central occlusion (fig. 2):

1. The patient bites in a central occlusion
2. The camera should be positioned at the level and parallel to the occlusal plane

3. Teeth from molar to molar should be visible
4. The focus is on the maxillary canines



**Figure 2:-** Intraoral photographs taken with: a) a DSLR camera; b) mobile phone with magnification x2; c) mobile phone with magnification x3; mobile phone with magnification x4; mobile phone with magnification x5.



The mobile phone is a SAMSUNG GALAXY 9 PLUS (Samsung Electronics Co., Ltd.). The telephoto camera of the phone was used, which gives twice the optical magnification of the image. The settings of the camera of the phone when shooting are: professional mode; aperture-2.4, ISO 100, speed 1/50s. The matrix of the phone is 12MP Back-lit CMOS. The SMILE LITE MDP device (fig. 3) by Smile Line Europe GmbH with only side lights on was used for lighting for the intraoral photos.

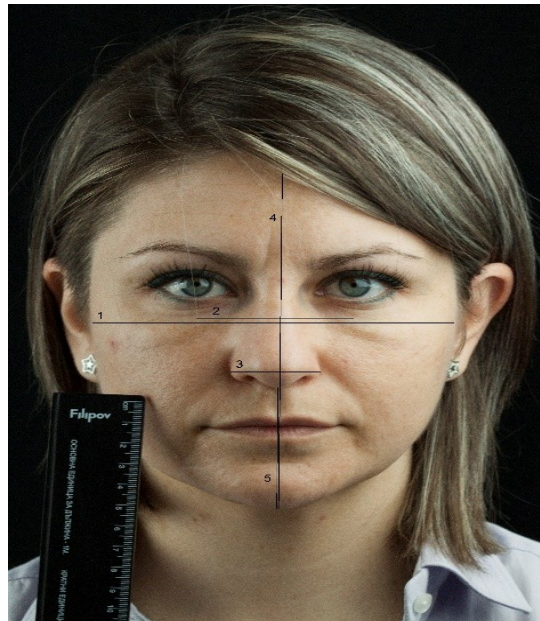


**Figure 3:-** Smile Lite MDP.

The DSLR camera is CANON EOS 500D with Canon EF 100mm f/2.8 Macro lens (Canon Inc). Reference points were selected to compare the different photos. The photos were done with a ruler and were calculated in IC Measure software. For the intraoral photos the method of Normando et al (2011) was used in which the ruler is attached to the cheek retractor. Linear measurements were used, and the measured distances were in the vertical and horizontal directions.

Linear measurements of the extraoral photos that were used are: (fig.4):

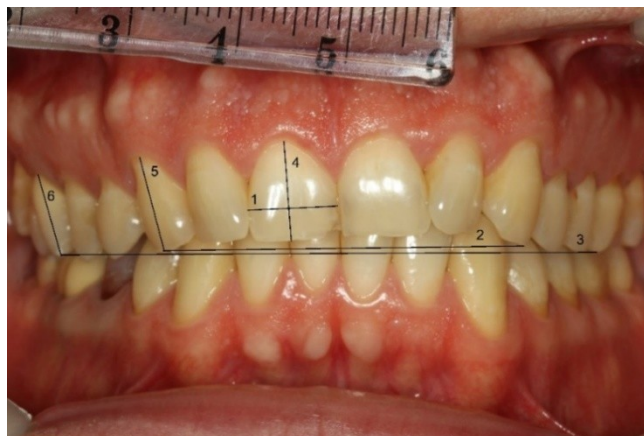
1. ZA-ZA – upper face width
2. Or-Or – distance between points Orbitale
3. Ac-Ac – distance between points Ac (nasal alar crest - most lateral point in the curved base of nasal alar)
4. Tr-Me – Physiognomic face height
5. Sn-Me – lower face height



**Figure 4:-** Linear measurements: 1. ZA-ZA; 2. Or-Or; 3. Ac-Ac; 4. Tr-Me; 5. Sn-Me.

The following distances were measured in the analysis of intraoral images(fig. 5):

1. Inc width - the mesiodistal width of the tooth 11
2. 3-3 - the distance between the incisal edges of the upper canines
3. 6-6 - the distance between the tips of the mesiobuccalcusps of the upper first molars
4. Inc height - the distance from the most apical point of the gingival margin to the incisal edge of tooth 11
5. Canine height - the distance from the most apical point of the gingival margin to the incisal edge of the tooth 13
6. Molar height - the distance from the most apical point of the gingival margin to the tip of the mesiobuccal cusp of tooth 16



**Figure 5:-**Parameters used in the analysis of intraoral photos: (1) Inc width; (2) 3-3; (3) 6-6; (4) Inc height; (5) Canine height; (6) Molar height

The data was processed with the IBM SPSS Statistics 25.0 statistical package. A 95% confidence interval( $p < 0.05$ ) was chosen for a significance level at which the null hypothesis was rejected. Descriptive, variational, and graphical analysis, Mauchly test for multivariate normality, Shapiro-Wilk test for normality distributions, nonparametric Friedman test for hypothesis for difference between several dependent samples, and nonparametric Wilcoxon test for two dependent samples were applied.

### Results:-

The results of table 1 show that significant differences of the subsequent measurements of the extraoral photos compared to the photos taken with DSLR camera are established with variables ZA-ZA, Or-Or and Sn-Me. The exact differences are shown in table 2.

**Table 1:-** Dynamics of the studied variables\*- the same letters horizontally mean no significant difference from the first dimension, and different - the presence of such ( $p < 0.05$ ).

Variable	n	Type of the extraoral photographs									
		DSLR camera		Mob. phone x2		Mob. phone x3		Mob. phone x4		Mob. phone x5	
		$\bar{X}$	SD	$\bar{X}$	SD	$\bar{X}$	SD	$\bar{X}$	SD	$\bar{X}$	SD
ZA-ZA	33	13,07 <sup>a</sup>	0,79	12,49 <sup>b</sup>	0,71	12,79 <sup>b</sup>	0,77	12,99 <sup>b</sup>	0,78	13,16 <sup>b</sup>	0,80
Or-Or	33	5,95 <sup>a</sup>	0,36	5,98 <sup>a</sup>	0,33	5,98 <sup>a</sup>	0,34	6,00 <sup>b</sup>	0,33	6,05 <sup>b</sup>	0,34
Ac-Ac	33	3,64 <sup>a</sup>	0,31	3,66 <sup>a</sup>	0,34	3,63 <sup>a</sup>	0,31	3,62 <sup>a</sup>	0,31	3,62 <sup>a</sup>	0,35
Tr-Me	33	17,67 <sup>a</sup>	1,64	17,82 <sup>a</sup>	1,59	17,73 <sup>a</sup>	1,69	17,74 <sup>a</sup>	1,67	17,73 <sup>a</sup>	1,64
Sn-Me	33	6,42 <sup>a</sup>	0,61	6,16 <sup>b</sup>	0,60	6,17 <sup>b</sup>	0,63	6,28 <sup>b</sup>	0,61	6,34 <sup>b</sup>	0,62

**Table 2:-** Comparative analysis of the differences in the studied variables compared to the first measurement point (photos taken with a DSLR camera).

Variable	n	Difference compared to photos taken with a DSLR camera							
		2 - 1		3 - 1		4 - 1		5 - 1	
		$\bar{X}$	SD	$\bar{X}$	SD	$\bar{X}$	SD	$\bar{X}$	SD
ZA-ZA	33	-0,58	0,34	-0,28	0,28	-0,07	0,20	0,09	0,19
Or-Or	33	0,03	0,15	0,04	0,12	0,05	0,10	0,10	0,08

Ac-Ac	33	0,02	0,15	-0,01	0,15	-0,02	0,15	-0,02	0,16
Tr-Me	33	0,16	0,47	0,06	0,35	0,07	0,27	0,06	0,22
Sn-Me	33	-0,26	0,25	-0,25	0,22	-0,13	0,19	-0,07	0,19

For ZA-ZA the average values of measurements 2, 3 and 4 are significantly lower than the first, and for 5 - statistically significantly higher (fig. 6). The largest in absolute value difference compared to the first measurement is observed in measurements 2, and the smallest - in measurement 4.

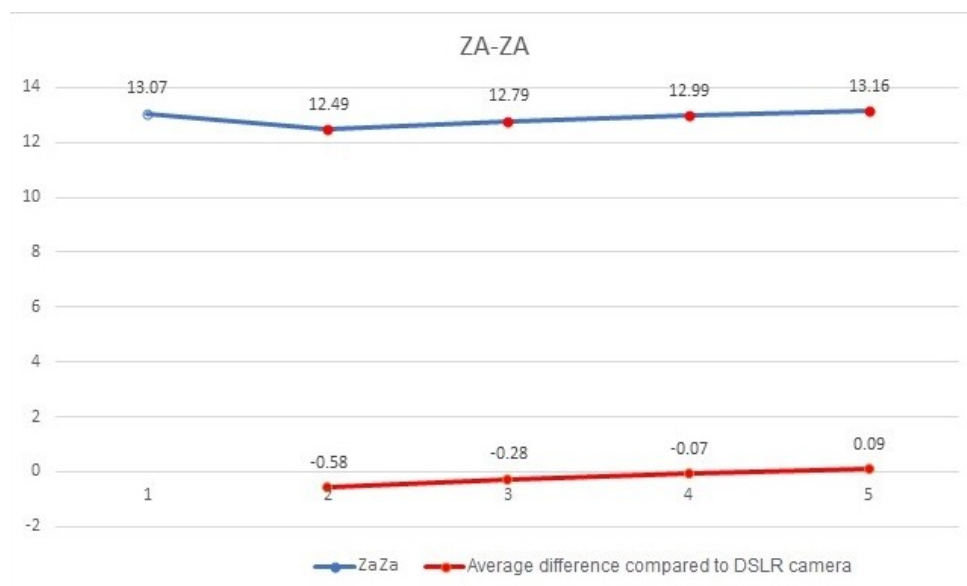


Figure 6:- Dynamics of the ZA-ZA variable.

In the case of Or-Or, significantly higher average values compared to the first measurement are observed only in measurements 4 and 5 (fig. 7). The largest difference is observed in measurement 5, and the smallest - in measurement 2.

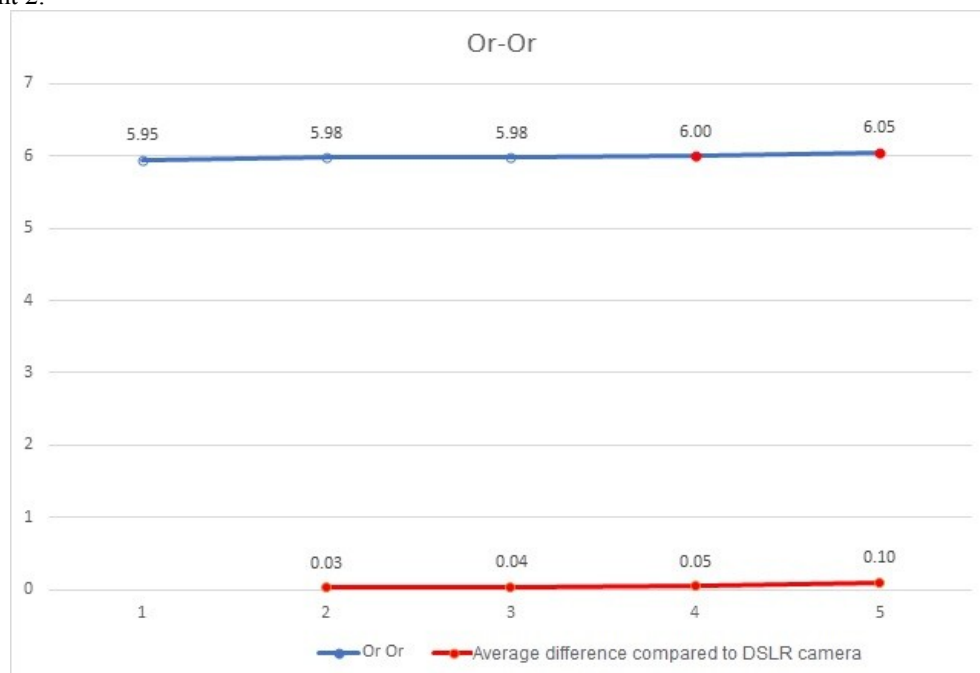
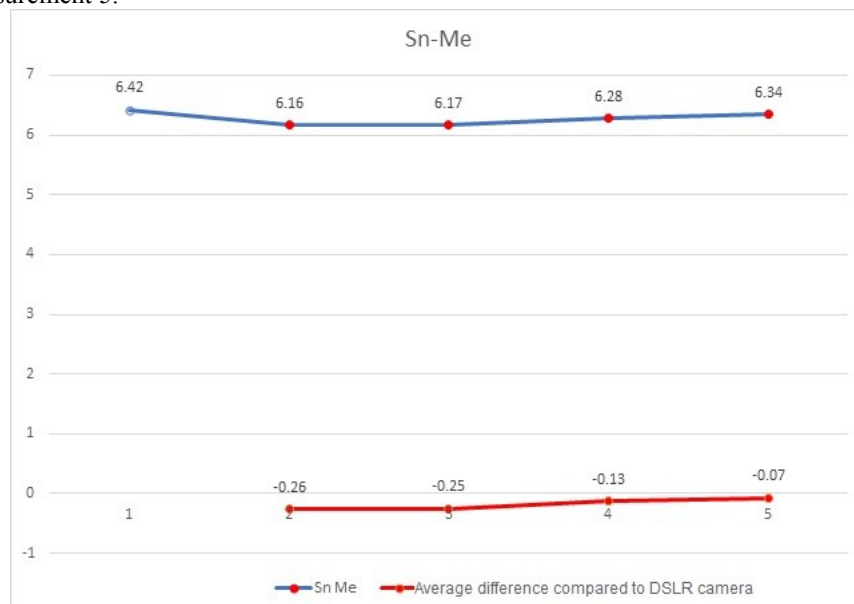


Figure 7:- Dynamics of the Or-Or variable.

For Sn-Me, the average values of measurements 2, 3, 4 and 5 are significantly lower than the first (fig. 8). The largest in absolute value difference compared to the first measurement is observed in measurement 2, and the smallest - in measurement 5.



**Figure 8:-** Dynamics of the Sn-Me variable.

In the analysis of the measurements of the intraoral images the following results were obtained (table 3):

At Inc height and Canine height, the average values of the measurements in the photos taken with mobile phone with magnification x2, x3 and x4 are significantly lower than that of the photos taken with a DSLR camera, and at magnification x5 - statistically identical to its average value;

At Molar height, Inc width, 3-3 and 6-6 significantly lower mean values compared to the values measured in photos taken with DSLR camera were observed in all other measurements.

From table 4 it is clear that in all six parameters the largest in absolute value difference compared to the measurements of the photographs taken with a DSLR is observed in the photographs taken with a mobile phone with magnification x2, and the smallest - at magnification x5.

**Table 3:-** Dynamics of the studied parameters\*- the same letters horizontally mean no significant difference from the first dimension, and different - the presence of such ( $p < 0,05$ ).

Parameter	n	Type of the photos									
		DSLR camera		Mob. phone x2		Mob. phone x3		Mob. phone x4		Mob. phone x5	
		$\bar{X}$	SD	$\bar{X}$	SD	$\bar{X}$	SD	$\bar{X}$	SD	$\bar{X}$	SD
Inc height	33	8,96 <sup>a</sup>	1,02	8,25 <sup>b</sup>	1,03	8,61 <sup>b</sup>	1,07	8,80 <sup>b</sup>	1,03	8,99 <sup>a</sup>	1,07
Canine height	33	7,44 <sup>a</sup>	1,56	6,69 <sup>b</sup>	1,44	7,05 <sup>b</sup>	1,52	7,25 <sup>b</sup>	1,55	7,46 <sup>a</sup>	1,60
Molar height	33	4,98 <sup>a</sup>	1,14	3,90 <sup>b</sup>	1,03	4,39 <sup>b</sup>	1,05	4,61 <sup>b</sup>	1,06	4,87 <sup>b</sup>	1,14
Inc width	33	8,43 <sup>a</sup>	0,58	7,77 <sup>b</sup>	0,60	8,06 <sup>b</sup>	0,60	8,24 <sup>b</sup>	0,58	8,38 <sup>b</sup>	0,59
3-3	33	33,35 <sup>a</sup>	2,08	29,77 <sup>b</sup>	1,89	31,27 <sup>b</sup>	2,05	32,16 <sup>b</sup>	2,07	32,85 <sup>b</sup>	2,08
6-6	33	47,54 <sup>a</sup>	1,99	40,12 <sup>b</sup>	1,98	43,38 <sup>b</sup>	2,14	45,32 <sup>b</sup>	2,23	46,60 <sup>b</sup>	2,14

**Table 4:-** Comparative analysis of the differences in the studied parameters compared to the values of the photos taken with a DSLR camera.

Parameter	n	Differences from the measurements of the values from the photos taken with a DSLR camera (1)
-----------	---	--

		2 – 1		3 – 1		4 – 1		5 – 1	
		$\bar{X}$	SD	$\bar{X}$	SD	$\bar{X}$	SD	$\bar{X}$	SD
Inc height	33	-0,71	0,25	-0,35	0,20	-0,16	0,17	0,03	0,18
Canine height	33	-0,74	0,25	-0,38	0,23	-0,19	0,18	0,02	0,20
Molar height	33	-1,08	0,43	-0,59	0,27	-0,37	0,25	-0,11	0,25
Inc width	33	-0,66	0,21	-0,37	0,15	-0,19	0,14	-0,05	0,14
3-3	33	-3,58	0,70	-2,08	0,63	-1,19	0,61	-0,50	0,56
6-6	33	-7,42	1,23	-4,16	1,11	-2,22	0,99	-0,94	0,99

Following the dynamics of the parameters inc height (fig.9) and canine height (fig. 10), the largest difference compared to the values when shooting with a DSLR camera is observed at twice the magnification. At three and four times magnification there is a permanent increase in the values and at five times they are statistically the same.

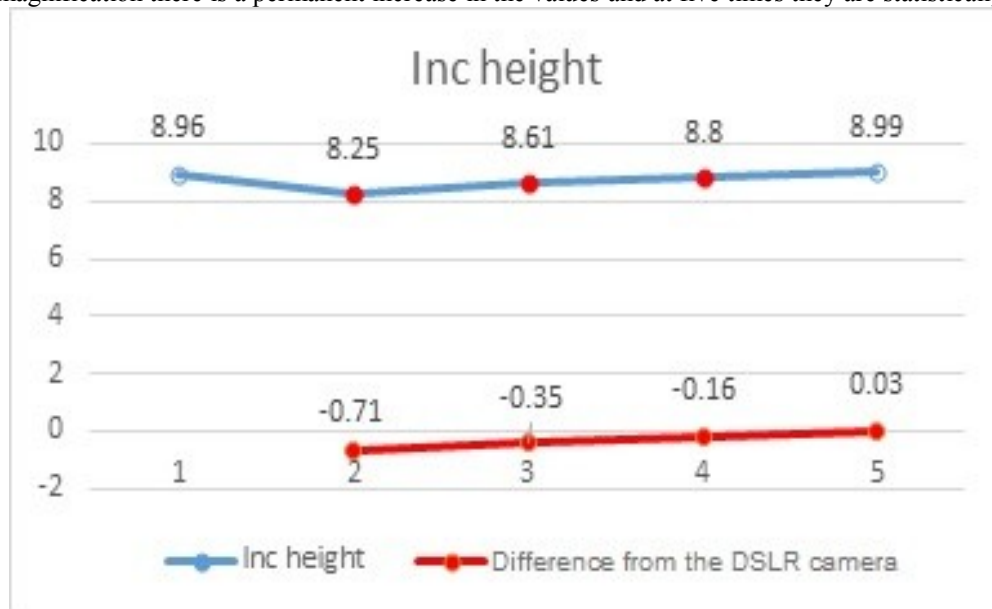

Figure 9:- Dynamics of the Incheight parameter.

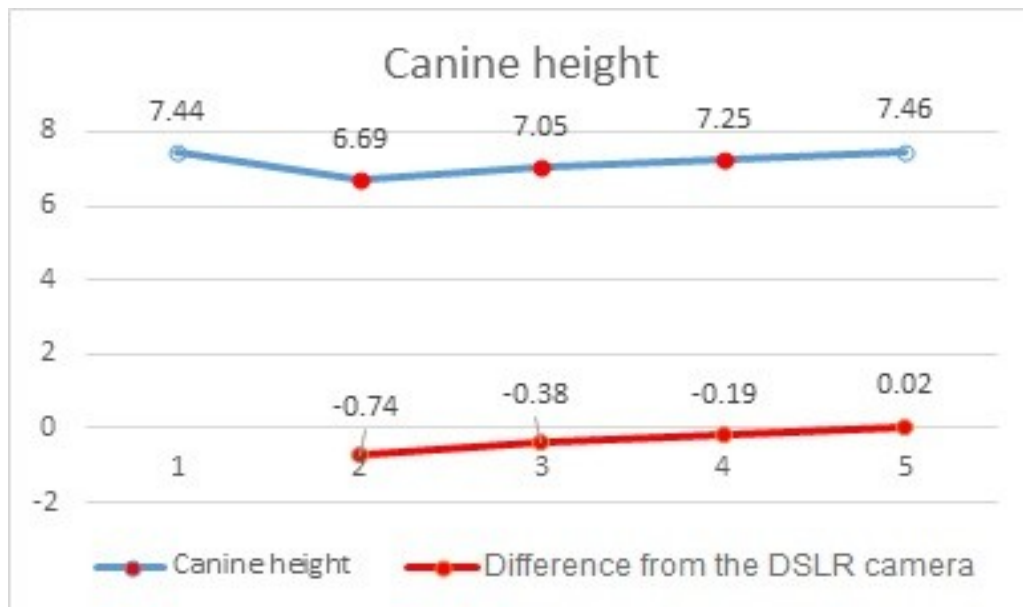
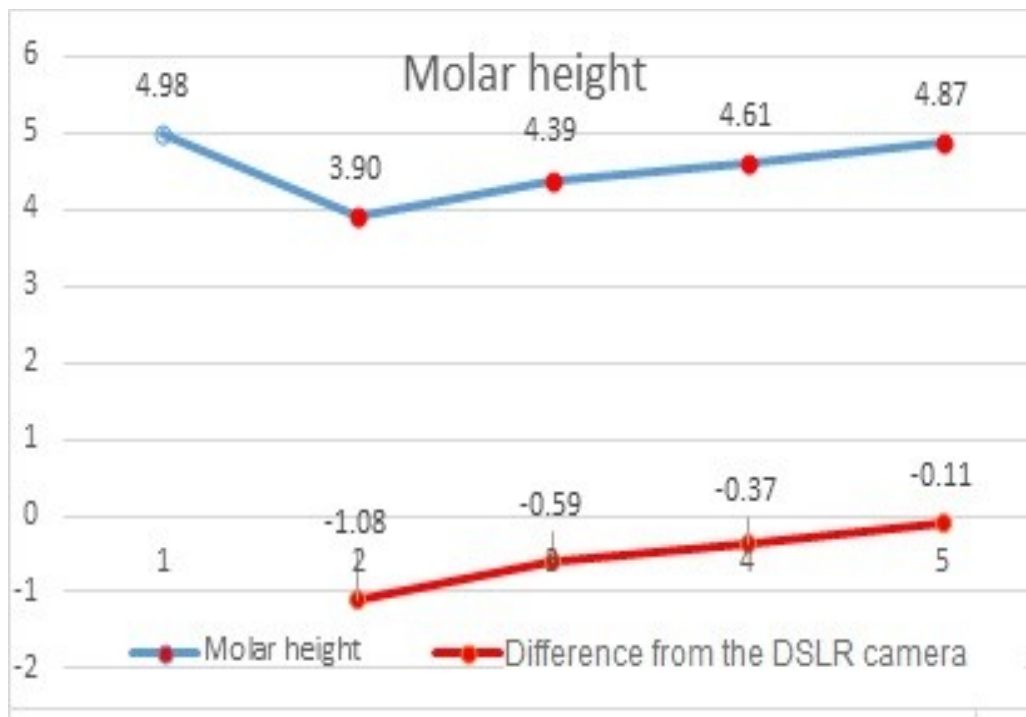


Figure 10:- Dynamics of the Canineheight parameter.

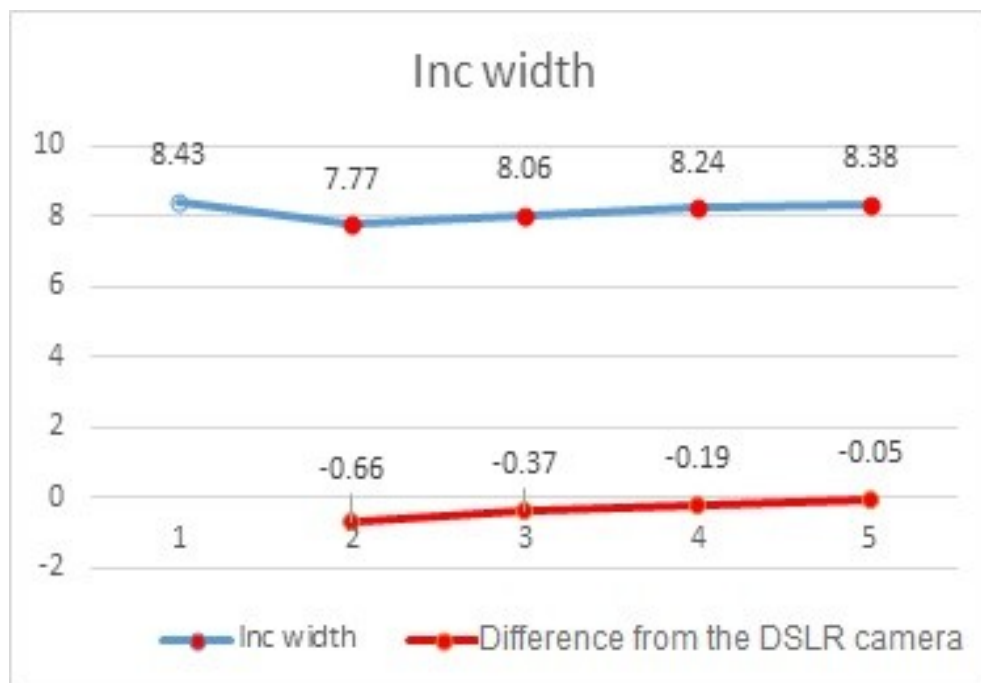


For the parameters molar height (fig. 11), inc width (fig.12), 3-3 (fig.13) and 6-6 (fig. 14) the following changes are observed:

1. At twice the magnification, there is the biggest difference from the values when shooting with a DSLR camera.
2. At each subsequent magnification (x3, x4 and x5) there is a permanent increase in the values, as the difference in the five times magnification compared to the values when shooting with a DSLR camera is the smallest.



**Figure 11:-** Dynamics of the Molarheight parameter.



**Figure 12:-** Dynamics of the Incwidth parameter.

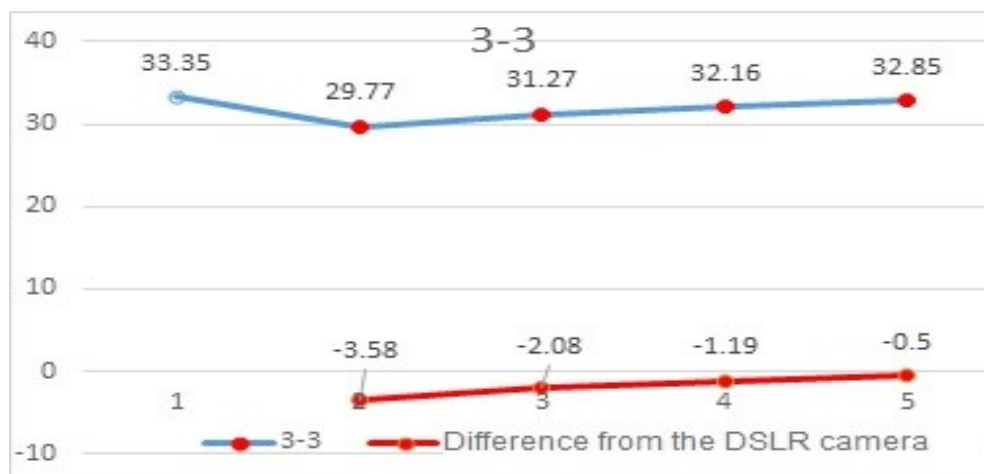


Figure 13:- Dynamics of the 3-3 parameter.

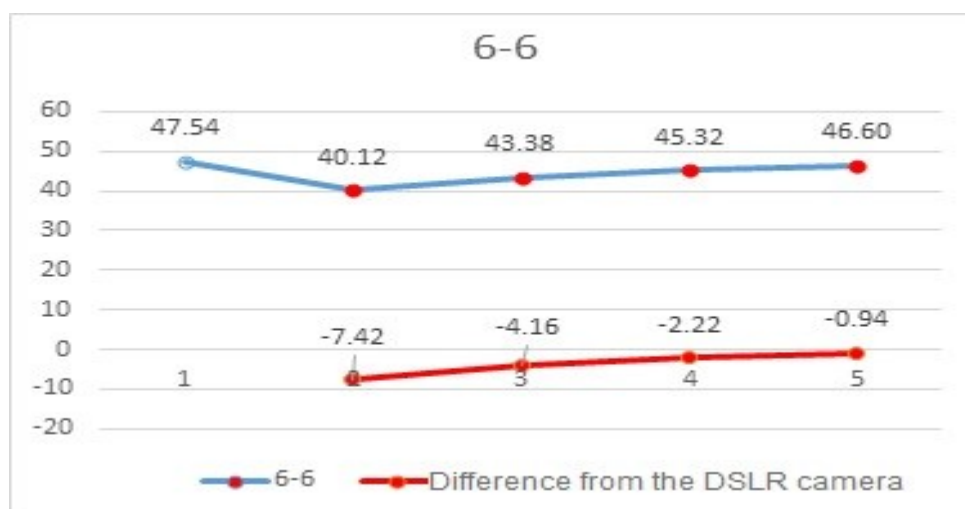

Figure 14:- Dynamics of the 6-6 parameter.

### Discussion:-

The working hypothesis that image deformation will be observed when shooting with a mobile phone has been confirmed. The main reason is the perspective, as the objects that are closer to the lens appear larger than those that are further away. The small lens of mobile phones and the short focal length cause visible image distortion. The closer the photos are taken, the more deformed the image, as the objects located in the center are close to normal sizes and with the distance to the periphery the dimensions decrease.

Significant differences are observed for variables ZA-ZA, Or-Or and Sn-Me. The change in ZA-ZA (upper face width) indicates a decrease in width - the face looks narrower. The biggest change is at magnification x2 (-0.58 cm), and the least at magnification x4 (-0.07 cm). It is noteworthy that at a magnification x5 the width increases compared to photos taken with a DSLR camera (+ 0.09 cm).

The distance between the Orbitale points increases with each larger magnification, and the difference from the photo taken with a DSLR camera at magnification x4 and x5 is statistically significant. At magnification x3 the difference is 0.04 cm, and at four times - 0.05 cm, i.e. the difference is negligible.

In all the photos taken, a statistically significant change in the values for the Sn-Me distance was observed, i.e. the height of the lower facial third appears to be reduced, but not at the expense of the total height of the face (there is no statistically significant difference in the Tr-Me variable). The smallest difference is at five times magnification (-

0.07 cm), followed by four times magnification ( -0.13 cm) The decrease of the lower third is compensated by a slight increase of the upper two thirds of the face.

The change in distance in the widest part of the nose Ac-Ac begins with a slight increase, followed by a monotonous decrease at magnification x3, x4 and x5. No statistical significance was observed for any of the values.

It is noteworthy that the values for the height of the clinical crown of the central incisor and canine are with similar changes, and at five times magnification there is no statistically significant difference from the photos taken with a DSLR camera. When measuring the height of the molar, a difference is observed even at magnification x5.

Measurements of the parameters in the horizontal direction show a decrease in the width of the incisor, the intercanine and intermolar distance. The most pronounced are the changes in the width of the dental arch in the area of the mesiobuccal cusps of the first permanent molars. The difference is noticeable even without measuring when comparing the photos taken with mobile phone with different magnification with the one taken with a DSLR camera (Fig. 2). However, at five times magnification, the difference is less than 1 mm, which is acceptable when the images are used for comparison between the different stages of treatment and not for diagnosis with biometric measurements. In the area of canine teeth, the changes are less pronounced. At five times magnification, there is a statistically significant difference even for the width of the central incisor, but it is only 0.05 mm.

There are not enough publications in the literature to compare measurements made on photos taken with a mobile phone with different magnification and a DSLR camera. In his study, Lui M. et al. (2020) obtain results only for the intraoral photos that differ from those obtained from this study. They recommend using four times digital zoom when imaging the front teeth, with no difference in the height and width of the central incisor or in the ratio between the widths of the upper anterior teeth compared to a DSLR camera. The authors do not recommend an exact distance from which to take photos.

### Conclusion:-

The best magnification for taking extraoral photos in dental practice is the four times magnification(x4) and the distance to the patient - 110 cm.

The optimal magnification for taking intraoral photos in dental practice with a mobile phone is five times and the distance between the camera and the object – 40 cm.

The mobile phone can be used for the extraoral dental photography, but The DSLR camera remains an indispensable device in the arsenal of equipment of the Dentist for the intraoral photos. Mobile phones still cannot be relied on to take intraoral photos in which the size and proportions of the teeth are as close as possible to the real ones.

### References:-

1. Kolarov R, Vasileva R, Nikolov N (2017):[A guide to dental photography], Bulgaria, p 77.
2. Liu M, Zhang JD, Ye HQ, Zhao YJ, Zhao XB, Zhao WY et al. (2020): [Application and exploration of Smile Lite MDP portable photography system in aesthetic photography of anterior teeth]. China. Beijing Da Xue Xue Bao Yi Xue Ban. 18;52(1):187-192.
3. Lozano JrF. (2016): Overview of Dental Photography Lenses and their effects. Forum Implantologicum, Quintessence Publishing Group. 12(1): 36-39.
4. Normando D, Lima P, Mendes AM. (2011): A clinical photogrammetric method to measure dental arch dimensions and mesio-distal tooth size. J Orthod. 33(6):721-6
5. Mariyanov M, Dilkova N, Petunov VI, Andreeva L. (2017): [Photographic documentation in orthodontic practice – extraoral images] Bulgaria, Orthodontic review. 19(2):11-20
6. Mariyanov M, Dilkova N, Petunov VI, Andreeva L. (2018): [Photographic documentation in orthodontic practice – intraoral images] Bulgaria, Orthodontic review. 20(1):18-23
7. Pasquale L, Pascoletti L. (2012): Photography in dentistry: theory and techniques in modern documentation. Quintessence Publishing Company. p 336
8. Samawi S. (2017): There's Something About MDP(Mobile Dental Photography). Available from: <<https://theorthodonticnotefile.blog/2017/08/10/theres-something-about-mdp-mobile-dental-photography/>>.