



Journal Homepage: - www.journalijar.com

INTERNATIONAL JOURNAL OF ADVANCED RESEARCH (IJAR)

Article DOI: 10.21474/IJAR01/12527

DOI URL: <http://dx.doi.org/10.21474/IJAR01/12527>



RESEARCH ARTICLE

DIGITAL IMPLANT PLANNING: A BRIEF NARRATIVE REVIEW

W.El Khourani and A.El Yamani

Mohammed V University.

Manuscript Info

Manuscript History

Received: 23 December 2020

Final Accepted: 25 January 2021

Published: February 2021

Abstract

Recently, the development of radiology, and software engineering, has led to the development of a new protocol called computer-assisted implantology (CAI) or guided implantology. CT / CBCT scanners allow the dentist to visualize a patient's anatomy in 3 dimensions. Define the precise measurement of bone for implant placement, soft tissue thickness, proximity and adjacent root anatomy. The exact location of the maxillary sinuses, and other relevant vital structures such as mandibular canal, mental and incisal foramen canal. Once the images are imported, to the software the clinician can then virtually begin treatment planning. The type and size of the planned implant, its position in the bone, its relationship to the restoration and adjacent teeth and/or implants, and its proximity to vital structures can be determined prior to surgery. Computer-generated surgical drill guides can then be manufactured from the virtual treatment plan.

Copy Right, IJAR, 2021,. All rights reserved.

Introduction:-

In recent years, the evolution of modern implantology, imaging techniques, and the digital engineering, has led to the development of a new protocol called computer-assisted implantology (CAI) or guided implantology. This innovative technique allows dental implants to be placed using a digitally manufactured guide.

The primary goal of this surgical technique is to help the implantologist to preserve the anatomical structures of the jaws, but also to enable the implantologist to achieve immediate loading and esthetics while being less invasive.

This article discusses the principle of guided implantology, the different steps of the protocol, the technique for manufacturing the guide.

Cone beam (CBCT):

Many anatomical information, treatment planning and treatment benefit levels increased with the use of 3-D imaging techniques. The use of virtual 3D pre-treatment planning techniques allowed for optimized implant placement and improved clinical outcomes. The development of 3D scanning, such as cone-beam computed tomography (CBCT) instead of flat films, has improved the visualization and understanding of anatomy in areas where implant placement is planned.[1][2]

The cone beam uses a conical X-ray beam of constant width. The concept is identical to that of conventional radiology used by practitioners on a daily basis. The equipment rotates around the object under examination and

Corresponding Author:- W.El Khourani

Address:- Mohammed V University.

projects it into a digital sensor with each pulse. The conical beam makes it possible to directly obtain the volume of the object by computer calculation from the multiple 2D projections acquired during the rotation of the device. [3]

Both CT and CBCT are stored in the universal format for “Digital Imaging and Communication in Medicine” (DICOM-format). Amongst imaging data, geometric and mathematical information, practical information such as acquisition details and settings are included in the DICOM file.

Volumetric imaging data is displayed in 2D cross-sectional images aligned to the prospective implant position. 3D surface models of CT or CBCT data are displayed using segmentation. CT or CBCT does not sufficiently display the tooth surface for the prosthetic set-up and for drill guide production. Especially in the presence of restorations, therefore, CT or CBCT scans and a virtual dental model obtained either from an intraoral optical scan or an extraoral scan of impression or stone casts are aligned to each in implant planning software. [4][5]

Implant planning software :

Recent Pre-implant simulation software are programs that provide clinicians excellent tools for pre-operative implant planning. to make digitally the placement of implants and different prosthetic components. These programs, for the most advanced ones, can also offer the possibility to design a surgical guide from the computer project, and even to foresee the design of the future prosthesis.

This software does not necessarily revolutionize the surgical procedure, but above all improves the conditions of reliability and security. They allow the practitioner to anticipate the positioning of the implant and the resulting surgical procedure. [6]

Most implant planning systems use CT or CBCT DICOM data for bone diagnostics. Three-dimensional reconstructions and multiplanar cross-sections oriented along the alveolar process in the implant region are available in all systems to review important parameters for the implant position. [7]

imaging artefacts can occur distorting the tooth surface and bone volume. Implant planning software systems provide automatic segmentation of bone, teeth or soft tissues; however due to artifacts these default settings could not be used to display specific anatomical structures. Manual segmentation by limiting the window of grey values for the display of three-dimensional models is necessary and possible in all systems. [8]

The importation, segmentation and pre-processing of radiographic data is crucial for the accurate transfer of the planned implant position to the surgical site. Radiographic data and virtual dental models are aligned with each other using either the tooth surface displayed both in CT or CBCT and in virtual dental models or with the help of reference markers in a radiographic splint. Incorrect matching between CT or CBCT and virtual models is known to happen after registration in relation to the number of existing metallic restorations. [9]

It is possible to use either an intra-oral optical scan or an impression or model scan, respectively, to produce a virtual dental model if the data is imported in STL format.

Intra-oral optical scanning reduces the steps and thus the time required to produce virtual models. In addition to the promising efficiency of intra-oral scanners, the accuracy of intra-oral optical scanning is still not fully validated in vivo. On the other hand, extraoral optical scanning of stone casts has shown high accuracy (10 µm). [10]

This means that depending on the implant system used, the drilling sequence and insertion of the implant is either performed in one step or through the drill guide. The software used in the examination has enabled guided implant placement for a number of integrated systems. The choice of implant planning software therefore depends on the specific implant systems used in daily routine.

The positioning of the drill guide on the teeth and mucosa, respectively, allows a more precise transfer of the implant position than the bone support. The operator is able to choose between the three support surfaces. The time required for the personal design and/or manufacture of the drill guide and the cost of the software must be taken into account by the user when using or selecting virtual implant planning software. [11]

It has to be considered that the user's experience plays an important role in any CAD software. According to the user's experience and affinity for digital products, the learning curve may vary. In conclusion, the authors find that one planning software is more intuitive than the other, which is very subjective. Before choosing a system, it is recommended to test as much as possible to find a satisfactory product.

Drilling guide:

Three types of computer-generated surgical guides are currently available: supported by teeth, mucosa and bone. Tooth-supported guides are used in cases of partial edentulism [12].

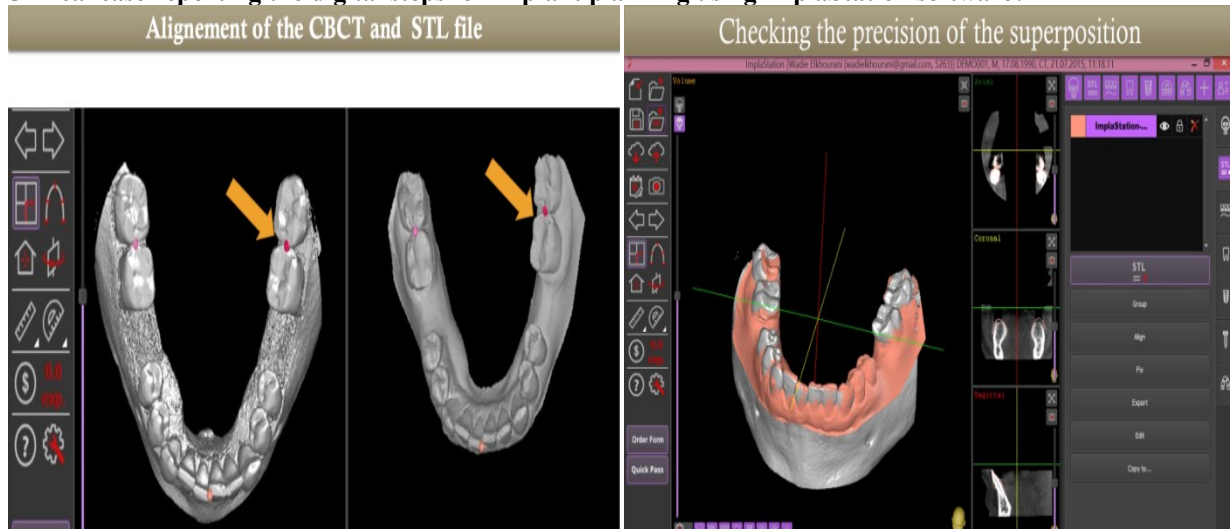
The surgical guide is conceived to rest on other teeth in the arch to ensure a precise fit of the guide. Mucosa-supported guides are primarily used in fully edentulous cases and are designed to rest on the mucosa. Accurate registration of the occlusion between the arches is of critical importance when these guides are used to ensure accurate positioning of the surgical guide [13] and placement of screws or pins prior to implant placement. In addition, pins or provisional implants can be placed with all systems to facilitate fixation of the drill guide during the procedure.

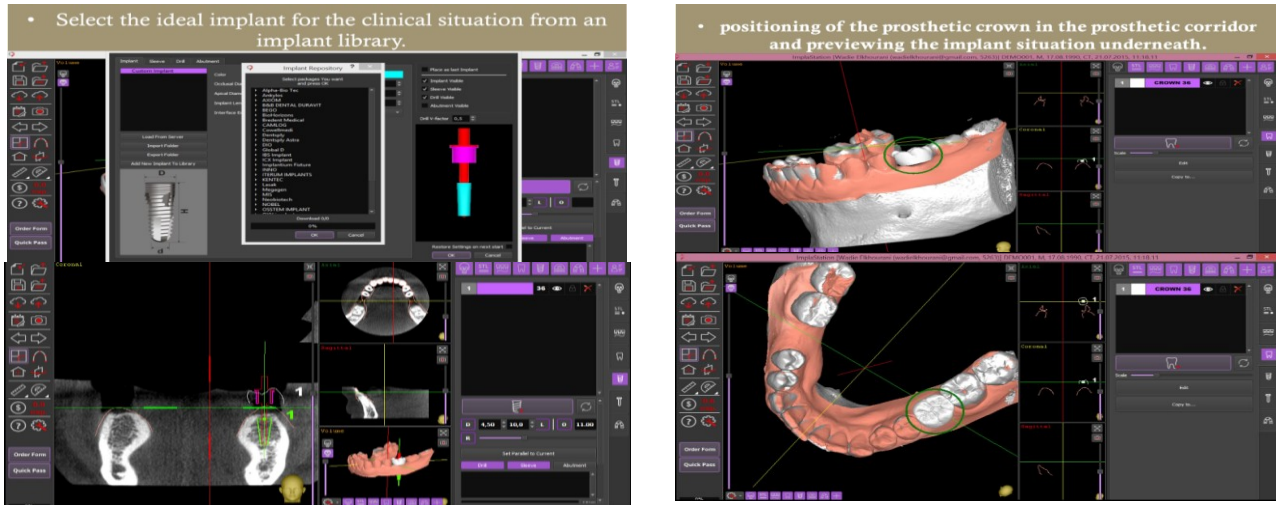
The individual design of the drill guides allowed the user to choose the supporting surfaces according to the individual patient case. While most systems (NC, SIM, CDX, IST) suggest a closed design of the guide, an "open" design may be beneficial for more visibility, accessibility and less risk of interference with hard or soft tissue. Consequently, the insertion of windows in the closed design becomes important. Because of the centralized design and production of drill guides, the user must provide individual information for any design specialty before manufacturing. Bone supported guides can be used in partially toothless or fully edentulous cases, but are mostly used in fully edentulous cases where there is significant crestal atrophy and where the proper seating of a mucosa-supported guide is doubtful. Such guides require the elevation of a thick flap to expose the bone in the intended implant sites and adjacent areas for a complete and stable seating of the guide on the bony ridge.[14]

The placement of dental implants using CT-guided drill guides is known to improve safety over the freehand technique as well. Based on the NobelGuide protocol, when the guided abutment is used to secure the immediate restoration, the accuracy should be sufficient to insert a final prefabricated restoration at the time of implant surgery. However, no CT-guided drill guide technology exists today with absolute accuracy. The literature on stereolithographic guides shows errors in all dimensions between virtual planning and the resulting implant positions [16].

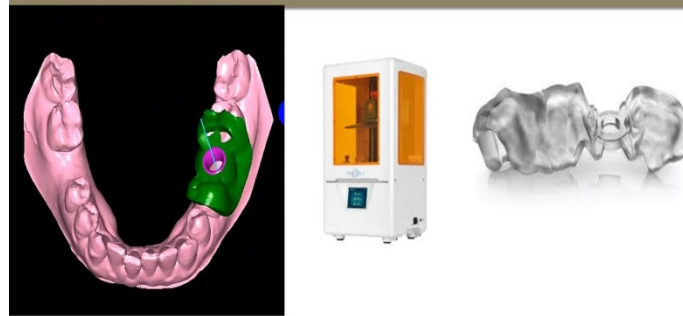
According to the literature, implants placed by bone-supported guides have the highest mean deviations, while implants placed by mucosa-supported guides have smaller deviations. Dental-supported guides have the smallest measured deviation. A single guide, using metal guide sleeves and rigid screw or pin fixation with specific drilling instrumentation, further minimizes the error.[15]

Clinical case reporting the digital steps for implant planning using implaStation software:





Design of a surgical guide according to the chosen position + Fabrication



Conclusion:-

The implant guided surgery can offer many advantages to this discipline, like precision, predictability of the results and more simple steps in the prosthetic steps, a learning curve must be conducted before facing complex cases, the clinician must understand the limitations and advantages associated with guided surgery so as to apply the benefits of this rapidly evolving technology when appropriately indicated.

Reference:-

- 1- Greenberg A. Basics of Cone-Beam CT and CT Guided Dental Implant Surgery. *Selected Readings in Oral and Maxillofacial Surgery* 2011;19(5):1-48.
- 2- Benavides E, Rios HF, Ganz SD, An CH, Resnik R, Reardon GT, Feldman SJ, Mah JK, Hatcher D, Kim MJ, Sohn DS, Palti A, Perel ML, Judy KW, Misch CE, Wang HL. Use of cone beam computed tomography in implant dentistry: the International Congress of Oral Implantologists consensus report. *Implant Dent.* 2012 Apr; 21(2):78-86 Bornstein MM, Horner K, Jacobs R. Use of cone beam computed tomography in implant dentistry: current concepts, indications and limitations for clinical practice and research. *Periodontol* 2000. 2017;73(1): 51-72
- 3- Yamashina A, Tanimoto K, Sutthiprapaporn P, et al. The reliability of computed tomography (CT) values and dimensional measurements of the oropharyngeal region using cone beam CT: comparison with multidetector CT. *DentomaxillofacRadiol*2008;37:245
- 4- Al-Rawi, B., Hassan, B., Vandenberghe, B. & Jacobs, R. (2011) Accuracy assessment of three-dimensional surface reconstructions of teeth from cone beam computed tomography scans. *Journal of Oral Rehabilitation* 37: 352-358
- 5- Verhamme, L.M., Meijer, G.J., Boumans, T., De Haan, A.F., Berg_e, S.J. &Maal, T.J. (2013) A clinically relevant accuracy study of computerplanned implant placement in the edentulous maxilla using mucosa-supported surgical templates. *Clinical Implant Dental Related Research* 24: 1265-1272.
- 6- Joda T, Gallucci GO. The virtual patient in dental medicine. *Clin Oral Implants Res.* 2015;26(6):725-6.

- 7- Greenberg AM. Digital technologies for dental implant treatment planning and guided surgery. *Oral Maxillofac Surg Clin North Am.* 2015 May;27(2):319-40. doi: 10.1016/j.coms.2015.01.010. PMID: 25951962.
- 8- Flügge TV, Schlager S, Nelson K, Nahles S, Metzger MC. Precision of intraoral digital dental impressions with iTero and extraoral digitization with the iTero and a model scanner. *Am J OrthodDentofacOrthop.* 2013;144(3):471– 8.
- 9- Tahmaseb A, Wismeijer D, Coucke W, Derksen W. Computer technology applications in surgical implant dentistry: a systematic review. *Int J Oral Maxillofac Implants.* 2014;29(Suppl):25.
- 10- Mora MA, Chenin DL, Arce RM. Software tools and surgical guides in dental-implant-guided surgery. *Dent Clin North Am.* 2014 Jul;58(3):597-626. doi: 10.1016/j.cden.2014.04.001. PMID: 24993925
- 11- Alevizakos V, Mitov G, Stoetzer M and Von See C. A retrospective study of accuracy of template guided versus free hand implant placement: A non-radiologic method. *Jb Oral Maxillofac Surg,*2019;128:220-6.
- 12- Pieralli S, Spies BC, Hromadnik V, Nicic R, Beuer F, Wesemann C. How Accurate Is Oral Implant Installation Using Surgical Guides Printed from a Degradable and Steam-Sterilized Biopolymer? *J Clin Med.* 2020 Jul 22;9(8):2322. doi: 10.3390/jcm9082322. PMID: 32707759; PMCID: PMC7463912
- 13- VarunArora et al 2018 IOP Conf. Ser.: Mater. Sci. Eng. 422 012019
- 14- Turbush SK, Turkyilmaz I. Accuracy of three different types ofstereolithographic surgical guide in implant placement: an in vitro study. *JProsthetDent.*2012;108(3):181–8.
- 15- Kalaivani G, Balaji VR, Manikandan D, Rohini G. Expectation and reality of guided implant surgery protocol using computer-assisted static and dynamic navigation system at present scenario: Evidence-based literature review. *J Indian Soc Periodontol.* 2020 Sep-Oct;24(5):398-408. doi: 10.4103/jisp.jisp_92_20. Epub 2020 Sep 1. PMID: 33144766; PMCID: PMC7592620.
- 16- Cassetta M, Di Mambro A, Giansanti M, Stefanelli LV, Cavallini C. The intrinsicerror of a stereolithographic surgical template in implant guided surgery. *IntJ Oral Maxillofac Surg.* 2013;42(2):264–75.