



Journal Homepage: - [www.journalijar.com](http://www.journalijar.com)

## INTERNATIONAL JOURNAL OF ADVANCED RESEARCH (IJAR)

Article DOI: 10.21474/IJAR01/12604

DOI URL: <http://dx.doi.org/10.21474/IJAR01/12604>



### RESEARCH ARTICLE

#### NEUTRAL ZONE RECORDING USING DIE PINS AND TISSUE CONDITIONER: A CASE REPORT

**Dr. Soundaria Saravanan<sup>1</sup>, Dr. Chalakupuzhiyil Abraham Mathew<sup>2</sup> and Dr. Biju K.A<sup>3</sup>**

1. Post Graduate Student, Department of Prosthodontics, KSR Institute of Dental Science and Research, KSR Kalvi Nagar, Tamil Nadu 637215.
2. Professor and Head, Department of Prosthodontics, KSR Institute of Dental Science and Research, KSR Kalvi Nagar, Tamil Nadu 637215.
3. Senior Lecturer, Department of Prosthodontics, KSR Institute of Dental Science and Research, KSR Kalvi Nagar, Tamil Nadu 637215.

#### Manuscript Info

##### Manuscript History

Received: 20 January 2021

Final Accepted: 24 February 2021

Published: March 2021

#### Abstract

The primary goal of providing complete denture prosthesis is to restore function and esthetics. Arbitrary placement of teeth may cause dislodgment during function. Neutral zone is a concept which emphasize on placing the teeth in a zone where the forces between the tongue and cheeks or lips are equal. In this case report a novel dental technique is to be discussed which uses, used die pins to retain the tissue conditioning material to record the neutral zone.

*Copy Right, IJAR, 2021,. All rights reserved.*

#### Introduction:-

Bone is a dynamic tissue that undergoes continuous remodeling throughout life. Residual ridge resorption (RRR) may be defined as continuous reduction in size of the residual ridge, largely due to bone loss after tooth extraction<sup>4</sup>. It is a chronic, progressive and irreversible process and the resorption rate is fastest in the first 6 months after extraction. In some patients RRR is much more faster which could be influenced by metabolic and systemic factors.

The primary goal of providing complete denture prosthesis is to restore function and esthetics. Oral functions such as speech, swallowing, mastication are highly complex and involve great co-ordination between the muscles of mastication and muscles of facial expression<sup>1</sup>. When prosthesis is given to the patient, it has to be in harmony with the neuromuscular system, to be effective and stable during function. Arbitrary placement of teeth may cause dislodgment during function. Neutral zone is a concept which emphasize on placing the teeth in a zone where the forces between the tongue and cheeks or lips are equal. According to GPT-9 neutral zone is defined as the potential space between the lips and cheeks on one side and the tongue on the other; that area or position where the forces between the tongue and cheeks or lips are equal<sup>7</sup>.

Sir Wilfred Fish in 1931 first described a technique where teeth were placed in a dead space, and later this dead space was coined as neutral zone by Beresin and Schiesser in 1976<sup>1</sup>. Historically many names were used to describe the neutral zone, which includes dead zone, stable zone, zone of minimal conflict, zone of equilibrium, zone of least interference, biometric denture space, denture space, and potential denture space<sup>2</sup>. However neutral zone is the most commonly used terminology

The main aim of the neutral zone is to construct a denture with muscle balance (figure-1). That is a denture which is in harmony with its surrounding structures to provide optimum stability, retention and comfort. Normal oral and

**Corresponding Author:- Dr. Soundaria Saravanan**

Address:- Post Graduate Student, Department of Prosthodontics, KSR Institute of Dental Science and Research, KSR Kalvi Nagar, Tamil Nadu 637215.

peri-oral muscles exert forces during function, and this force could be used to retain a complete denture rather than dislodging the denture<sup>2</sup>.

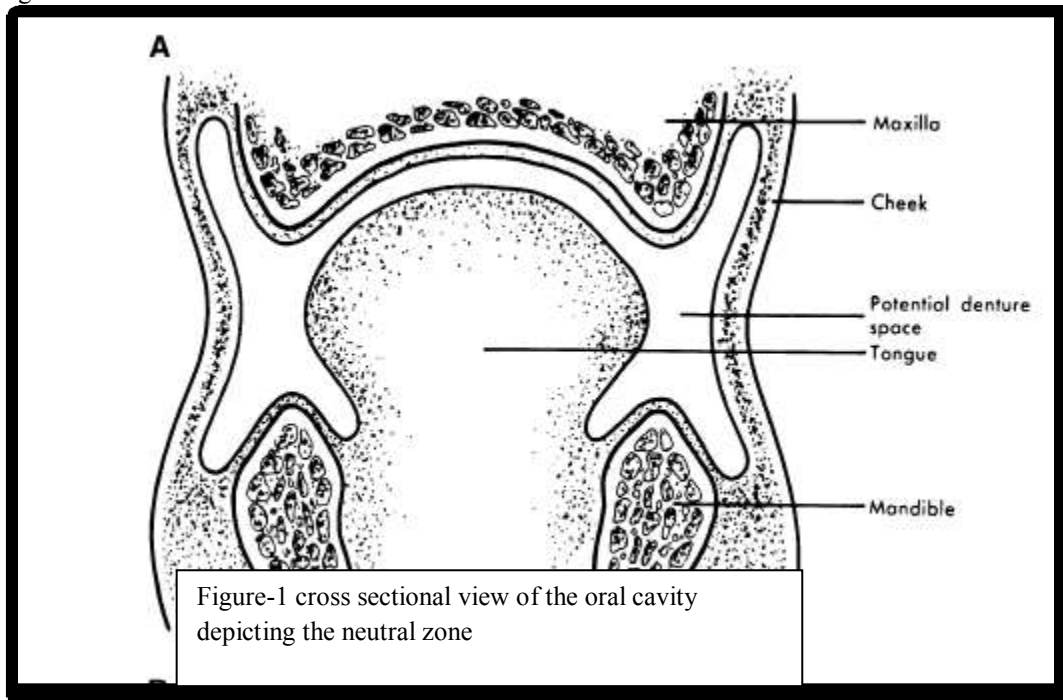


Figure-1 cross sectional view of the oral cavity depicting the neutral zone

Arranging teeth in neutral zone is highly recommended for patients with highly atrophied mandible, for patients who have had numerous unstable, unretentive lower complete dentures<sup>2</sup>. Patients with Partial glossectomy and/ or Mandibular resections or Motor nerve damage to the tongue which have led to atypical movement which may dislodge the denture.

The advantages of arranging teeth in the neutral zone is that it will improve the stability and retention of complete denture by correctly positioning the posterior teeth, allowing sufficient tongue space, and also reduces the food trapping adjacent to the molar teeth<sup>2</sup>. This technique also provides good aesthetics due to facial support.

The primary disadvantage of this technique is that increased laboratory time and cost is required and the Laboratory technician must be trained to support this clinical procedure<sup>2</sup>.

Several materials like modelling plastic impression compound, soft wax, silicone, polyvinylsiloxane, tissue conditioners, and polyether have been used to record the neutral zone. Here in this article a dental technique is to be discussed which uses used die pins to retain the tissue conditioning material to record the neutral zone.

#### Case Report:

A 55 year old female patient, who reported to the department of Prosthodontics crown and bridge, KSR institute of dental science and research, to replace her lost natural teeth with an artificial teeth set, to improve her chewing efficiency.

She revealed no relevant medical history. She lost most of her natural teeth due to grade III mobility. On intraoral examination maxillary arch size was Class 3 (small) with Class 3 (ovoid) Arch Form (according to M. M. HOUSE classification). She had a flat palatal vault form. Residual Alveolar Ridge of Mandibular arch was knife edged with inadequate vestibular depth all around. Lateral throat form was Class 3 (according to NEIL'S classification). Tongue Size was enlarged and the position was Normal. Since the prognosis was doubtful, and to improve the stability of the complete denture, it was planned to fabricate the denture using neutral zone technique.

Primary impression of both the arches were made using impression compound and after providing sufficient relief, alginate wash impression was made. Primary cast was poured using type-II dental plaster. Special trays were

fabricated and border moulding was done using low fusing compound and secondary impression of the maxillary arch was made using polyether. All green impression technique was followed for the mandibular arch. Master cast was poured using type-III dental stone and occlusal rims were fabricated. Jaw relation was done and was mounted on a mean value articulator (figure-2).

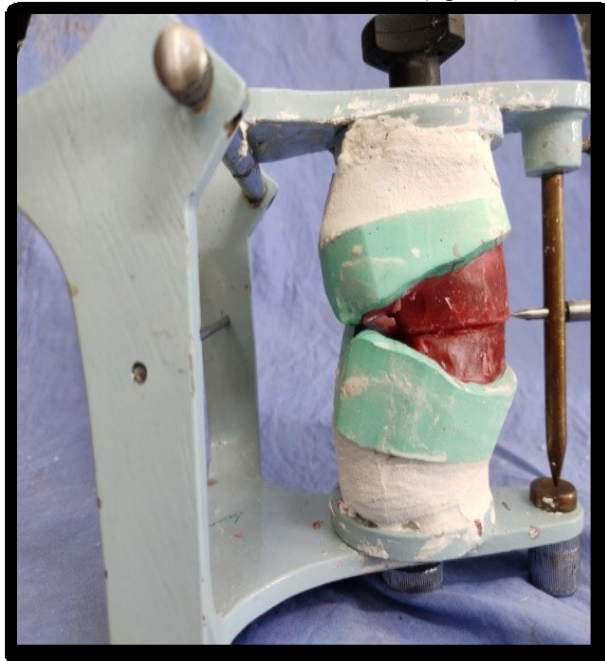


Figure 2:- Jaw relation done and mounted on mean value articulator.

A new temporary denture base was fabricated for both the master casts. Dual die pins were retrieved from the old working cast of fixed partial denture, and the head portion was cut using carborandum disc and fixed to the temporary denture base using autopolymerizing acrylic resin (figure-3). The length of the dual end die pin was adjusted according to the interocclusal space available. It was checked by placing it against the opposing occlusal rim (figure 4).

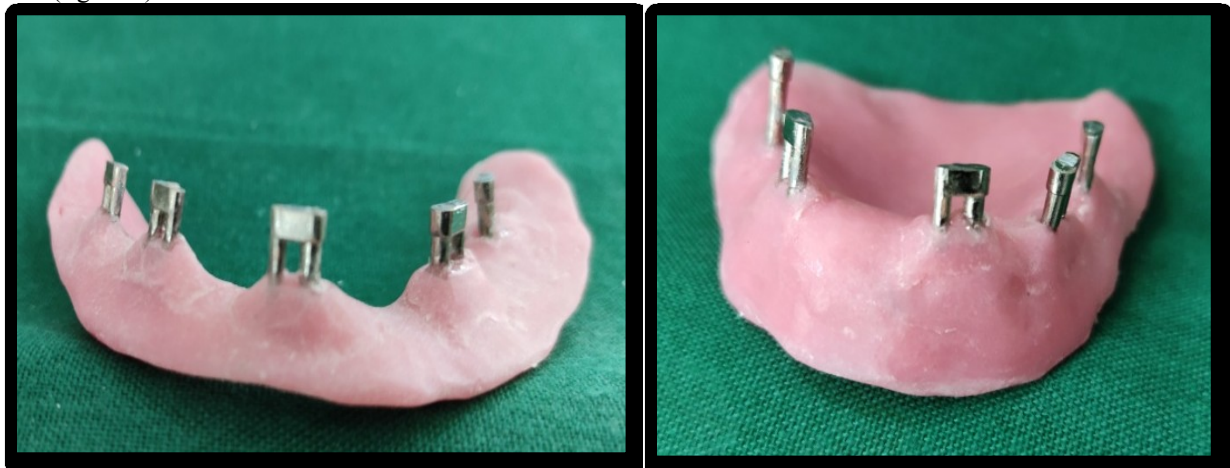
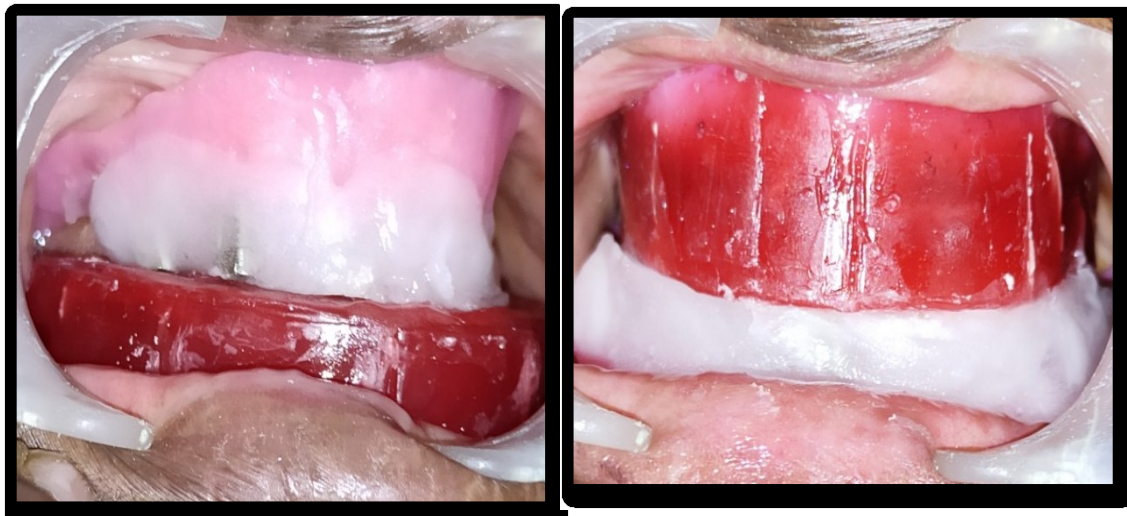

Figure 3:- Die pins were attached to the new denture base.

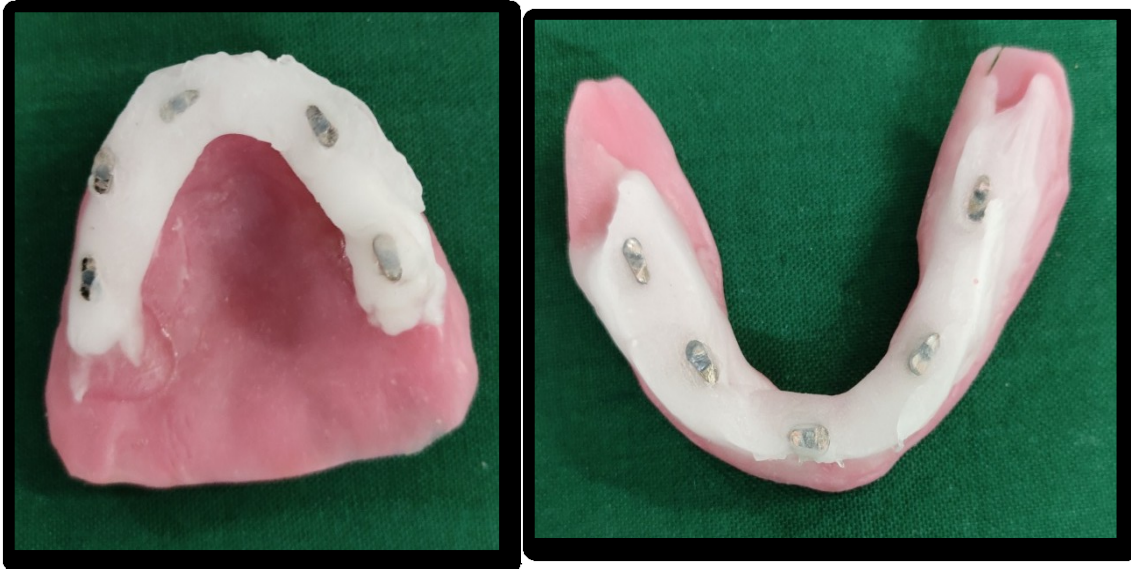

**Figure 4:-** Denture base with die pins were checked against the opposing occlusal rims.

Tissue conditioner was mixed and adapted against the die pins and patient was asked to perform the functional movements like swallowing, whistling etc, and she was asked to bite against the opposing wax occlusal rim. Patient was also asked to pronounce words that included sibilant, and palatolingual sounds (figure5).

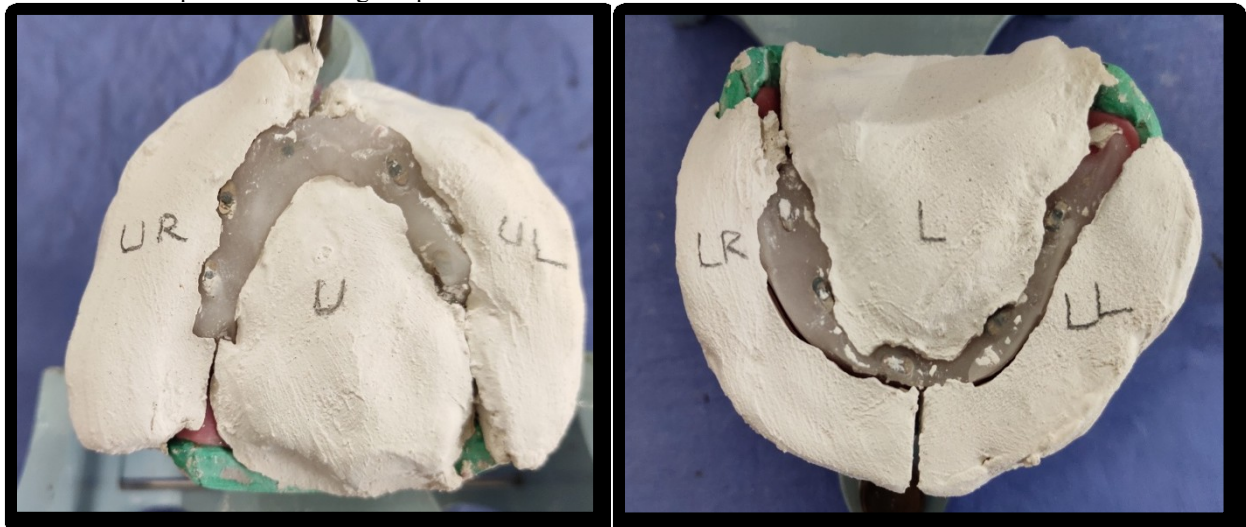


**Figure 5:-** Neutral zone recording done at established vertical dimension.



**Figure 6:-** Neutral zone recording done using tissue conditioning material.

Once the neutral zone was recorded, it was examined and excess material was trimmed off (figure-6). A 'v' shaped notch was carved in the land area of the master cast. The casts were lubricated using petroleum jelly and using a thick mix of type-II dental plaster, index was made to register the neutral zone. This index extended few millimeter away from the land area of the cast. The height of the plaster index was kept parallel to the height of the occlusal rims (figure-7). Now the die pin along with the tissue conditioning material was removed from the temporary denture base and wax occlusal rim was fabricated according to the new plaster index. V shaped notch made on the master cast helped in reorienting the plaster index on the master cast.



**Figure 7:-** Plaster index fabricated using type II plaster.

Teeth were arranged in the neutral zone, which was obtained using functional and phonetic method. Try in was done (figure 8). Once it was found to be satisfactory, the external surface was recorded using light body condensation silicone for both the arches on labial, buccal, lingual / palatal region. Patient was asked to protrude her lips as in sucking and swallowing (figure-9). It was checked again to confirm whether teeth arrangement was confined to the neutral zone by placing the plaster index against the teeth arrangement (figure-10)

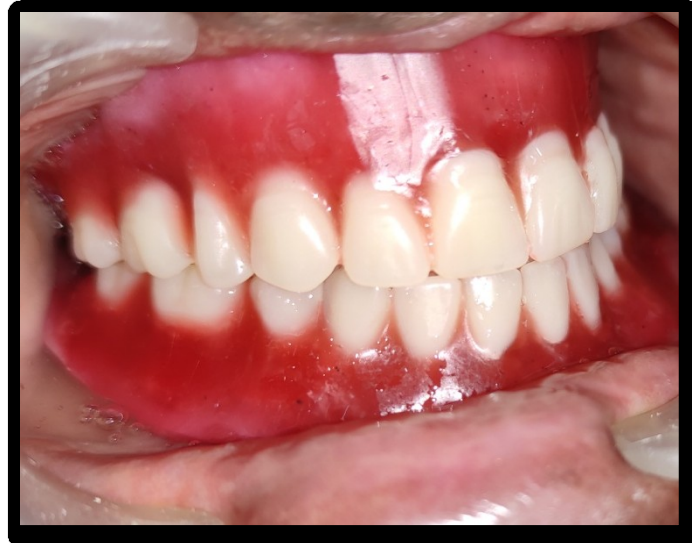

Figure 8:- Try in was done.

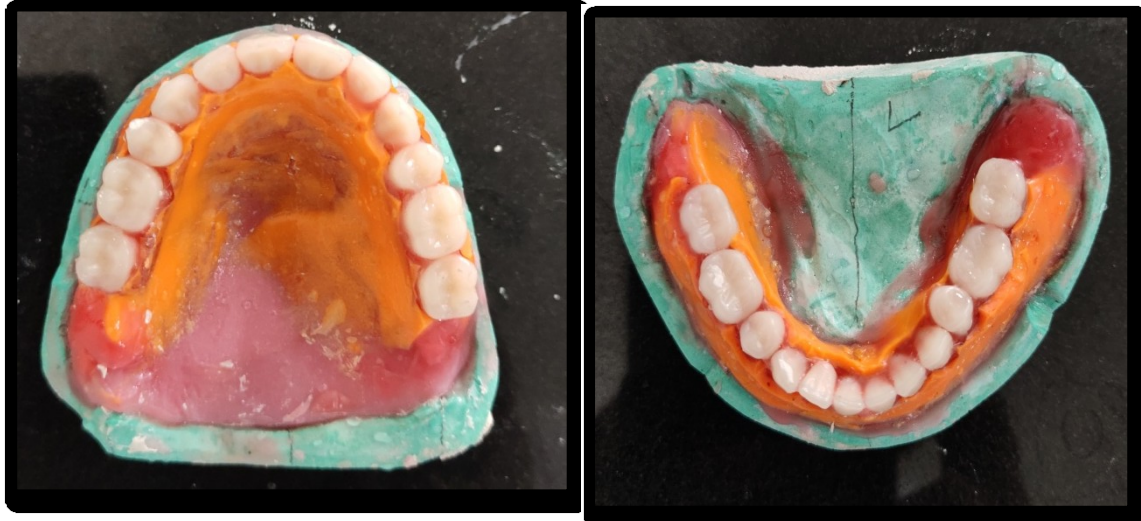
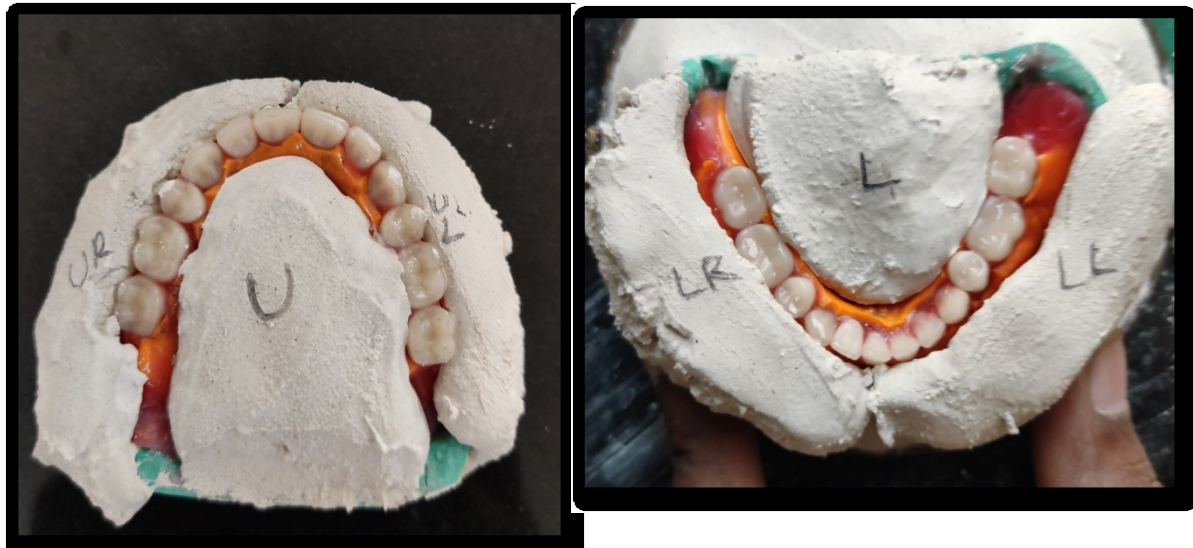
Figure 9:- External surface recording done.



**Figure 10:-** Teeth arrangement was confined to the neutral zone record.

The dentures were processed and insertion was done. Post insertion instructions were given. Patient was reviewed, and she was satisfied with the esthetics and stability of the denture

### **Discussion:-**

The success of a prosthesis depends mainly on the patient acceptance and willingness to use the prosthesis. Stability and retention will be compromised in patients with severely resorbed residual ridges. To improve the stability of the mandibular denture, all green technique was followed. Since the patient had a large tongue and severely resorbed ridges, several treatment options like, implant retained fixed prosthesis, implant supported over denture, complete dentures with neutral zone was recommended for the present case. Due to financial reasons, patient was not willing for implant retained restorations. Hence this case was rehabilitated with complete dentures using neutral zone.

In literature, acrylic pillars and orthodontic wires were used as pillars to retain the recording material. Thicker acrylic pillar or varying the position of the acrylic pillars may cause inaccurate recording of the neutral zone. Achieving exact vertical dimension with orthodontic wires is a quite tedious process. Here in this case report, used die pins were used. The head portion was cut so that it provided a flat surface against which the wax occlusal rims can be occluded. The height was also easily trimmed using carborandum disc, so that it can be accommodated to the pre-established vertical dimension of occlusion. Tissue conditioning material was used as it was easy to handle, can be added incrementally and had sufficient working time to register all the functional movements.

Makzoume et al stated that the neutral zone recorded in the phonetic technique is significantly narrower when compared with that recorded in the swallowing technique. Dentures fabricated using one functional movement to shape the neutral zone may be unstable during other functions. Hence both types of functional movements like phonetics and swallowing were used to record the neutral zone

The external surface of the denture was recorded so that there won't be any interference between the polished surface of the denture and tissues/ muscles during function<sup>2</sup>.

### **Conclusion:-**

This case report presented an over view about the need for carrying out the neutral zone technique, materials used and also the indications, advantages and disadvantages were discussed. A novel idea to retain the impression material with the used die pins was also discussed. This procedure can be used in routine clinical practice as readily available materials were used to record the neutral zone.

**References:-**

- 1 Porwal A, and Sasaki K;Current status of the neutral zone: A literature review; J Prosthet Dent 2013;109:129-134)
2. Cagna DR, Massad JJ, Schiesser FJ. The neutral zone revisited: from historical concepts to modern application. J Prosthet Dent 2009;101:405-12.
3. Beresin VE, Schiesser FJ. The neutral zone in complete dentures. J Prosthet Dent 1976; 36:356-67.
4. Jahangiri L, Devlin H, Ting K, and Nishimura I; Current perspectives in residual ridge remodeling and its clinical implications: A review; J Prosthet Dent 1998;80:224-37.
5. Makzoume JE. Morphologic comparison of two neutral zone impression techniques: a pilot study. J Prosthet Dent 2004;92:563-8.
6. Lynch CD, Allen PF. Overcoming the unstable mandibular complete denture: the neutral zone impression technique. Dent Update 2006;33:21-2, 24-6.
7. The glossary of prosthodontic terms ninth edition The Journal Of Prosthetic Dentistry Volume 117 Issue 5S.