



RESEARCH ARTICLE

ASSESSING BREAST DISORDERS AND FEASIBILITY OF BREAST-I LED MACHINE AMONG WOMEN OF RURAL AREA OF CHANDIGARH, INDIA

Anjali Sharma, Dr. Shushma Kumari Saini, Kmendalin Nongspung, Meenakshi, Arti, Bhupinder Kaur, Arwinder Kaur and Dr. Nilesh Patil

Manuscript Info

Manuscript History

Received: 15 January 2021

Final Accepted: 19 February 2021

Published: March 2021

Key words:-

Breast Cancer, Clinical Breast Examination, BREAST-i LED Machine

Abstract

Background: Breast cancer is the most common cancer in India causing highest cancer deaths in India as per GLOBOCAN 2018. Early diagnosis and treatment helps in improving prognosis and prolonging life. BREAST-i LED machine is one of the technology, for screening breast cancer at early stage. The present study was undertaken to evaluate the feasibility of BREAST-i LED machine to screen breast cancer.

Methods: Across-sectional study was conducted on 300 convenient selected women in the age group of 30-60 years. Data was collected by house-to-house survey and all the women in surveyed house were registered for the study. They were interviewed as per the interview schedule comprised of a) Socio-demographic profile b) reproductive profile c) cancer related history and sign/symptoms. By using BREAST-i LED machine the breast examination was done and the clinical breast examination was done there after to screen any sign of breast cancer. Identified cases were referred for confirmation of diagnosis. The data entry and analysis was done on SPSS (version 20).

Results: The majority of the participants were between the age of 40-50years (42%) and majority of them (89.33%) began their menstruation between the age of 11-15 years. More than half (53.66%) had their first pregnancy between the age of 21-30years; More than half (58%) had not attained their menopause and 99.3% had no family history of breast cancer. A high level of suspicion of breast cancer using Breast-i-LED instrument was found among four women (1.33%). Same results were observed by clinical breast examinations as well. These women were referred for further confirmation of diagnosis.

Conclusion: BREAST-i LED machine can be used in community for quick screening of suspicion of breast cancer.

Copy Right, IJAR, 2021,. All rights reserved.

Corresponding Author:- Dr. Nilesh Patil, drnileshpatil01@gmail.com, +919474202953

Address: ANIIMS, Port Blair, 744102, Andaman and Nicobar Islands.

Introduction

Breast cancer is a global health issue and a leading cause of death among women internationally. In 2018, 1.1 million new cancer cases and 0.78 cancer death were reported in India as per the GLOBOCAN 2018⁽¹⁾. Breast cancer is the most common cancer (i.e. 14% of the total cases) and leading cause of cancer death (11.1% of the total cases). Breast cancer is distinguished from other types of cancer by the fact that it occurs in a visible organ and can be detected and treated at an early stage. Five to ten percent of breast cancers are due to the inherited mutation of BRCA1 and BRCA2 genes. The other causes include obesity, unhealthy lifestyle, family history, hormonal therapy, use of alcohol and over expression of leptin gene in adipose tissue ⁽²⁾.

Recommended preventive techniques to reduce breast cancer mortality and morbidity include breast self-examination (BSE), clinical breast examination (CBE), and mammography. Besides this there are many other screening techniques which are used in prognosis of cancer like mammography, Breast MRI, Ultrasound, CT-scan, Nuclear imaging, Needle biopsy, PET Scan etc.⁽³⁾ Breast-self-examination (BSE) is most recommended method of early identification of any suspicion to breast cancer and require motivation and sensitization among women. Among illiterate and low income community women the regular BSE practice is low BE and mammography require hospital visit and specialized equipment and expertise ⁽⁴⁾

Breast cancer screening, is mainly recommended for women between 30-35 years of age, Community based screening of Breast cancer can be done by clinical breast examination by nurses and other health professionals working in community, which is time consuming at least 15-20 minutes per women. So there is always, need of new screening modality, which is quick and handy. Breast-i-LED machine is such kind of modality to assess breast malignancy. In this trans-illumination is used as an aid in the diagnosis of breast lesions. This was first used by Cutler in 1929 followed by Angquist and colleagues in 1981. The science behind this device is that due to the associated angiogenesis (that supplies oxygen and nutrients to cancer cells) the optical images of breast cancer can be seen when red blood cells (oxyhaemoglobin) absorb light at about 615nm. Study done in Sub Saharan countries results that Breast-i-LED machine is an effective tool for detecting early tumor related angiogenesis of breast cancer. ⁽⁵⁾ Another study done on accuracy of red light reports 66.66% sensitivity, 51.06% specificity and 52% accuracy. The positive and negative predictive value was 8% and 96% respectively. Which conclude that this device cannot be used alone to detect breast malignancy because of high false positive outcome and low sensitivity and specificity⁽⁶⁾.

So a survey was planned to detect suspicion to breast malignancy using clinical breast examination and Breast-i-LED machine in Chandigarh. The aim of the survey was to assess the efficacy of Breast -i-LED machine in detecting suspicion to breast cancer and to provide prompt referral for early diagnosis and treatment.

Objective

To assess the efficacy of Breast-i-LED machine to screen the suspicion to breast malignancies among 30-60 year of women in Dhanas and Daddu Majara Colony, Chandigarh

Materials And Methods

A cross sectional survey was done on 300 women of Dhanas and Daddu Majara Colony (DMC), Chandigarh in November – December 2017 among women with age 30-60 years. A house-to-house survey was done by using a survey Performa and all the women 30-60 years were registered for screening them for breast cancer suspicion. The tool used were 1) interview schedule comprised of two parts; Part-1: a) Socio-demographic data and Part-1: b) Menstrual history and 2) Assessment Performa to record Findings of clinical breast examination (CBE) and Breast-i-LED machine. Protocol for use of breast -i- LED machine and clinical breast examination were prepared. The tools and protocols were prepared and validated by experts in the field of Nursing.

Part 2: The written consents were taken and information was collected by interviewing participants as per the interview schedule Breast examination was done by using Breast-i-LED machine followed by Clinical breast examination (CBE). Breast-i-LED machine is a trans-illumination aid, which provides optical image of the breast when red blood cell absorbs light at about 615 nanometer. This machine has a hand held probe (**Figure No. 1**) which emits red light (615nm). Red light transilluminates in the breast tissue, in the breast tissue haemoglobin absorbs the light and represents the vascularity of the breast lesions (**Figure No.2**). With the help of Breast-i LED machine we can check the vascularity of the breast lesions. The darker spot indicate high vascularity, which

represent the suspicion of any breast lesion like adenoma or malignant tumour (**Figure No. 3**).The privacy of participant was maintained adequately.The overall duration of interview and clinical examination was 10-15minutes per participant. At the end of the interview and examinations, results of examination were revealed to participants and if required prompt referral was provided to secondary level hospital for further investigations. Opportunity was also utilised for educating women on Breast Self examination. The descriptive analysis was done using SPSS software version 20 and data was presented in the form of tables.



Fig.1:- BREAST-i LED machine Probe.




Fig.2 : Normal results

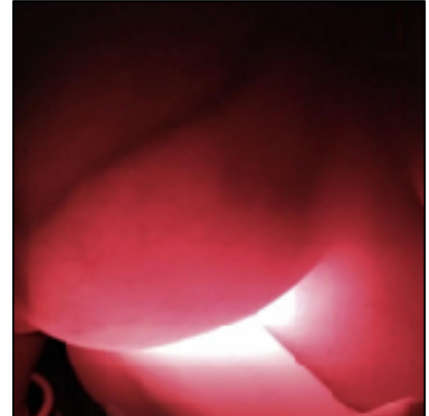


Fig. 3: Dark spot indicating suspicion of any breast lesion

Results

Table 1 represent the socio demographic profile of 30-60 year of women of DMC and Dhanas, Chandigarh. The 42% women were in the age group of 41-50 years, 89.33% of women had achieved menarche between 11-15 years of age, 53.66% had their first pregnancy between 21-30 years of age.

Variables	Frequency (%)
Age of participants (in years)	
30-40	98 (32.66)
41-50	126(42)
51-60	86 (28.66)
Age at first menstruation (in years)	
11-15	259 (86.33)
16-20	41(13.6)
Age at first pregnancy (in years)	
≤20	103(34.33)
21-30	161(53.66)
31-40	36 (12)
Age at menopause (in years)	N=126
45-50	118(93.6)
51-55	08(6.4)
Age at last pregnancy (in years)	
20-30	256 (85.33)
30-40	44(14.6)

Table1:- Socio-Demographic profile of 30-60year women residing in Dhanas and Daddu Majara Colony, Chandigarh N=300

Table 2, represents menopausal and family history of breast cancer of women between 30-60 years of age residing in Dhanas and Daddu Majara Colony, Chandigarh. In the present study, 42% of women were menopausal and 0.66% reported a family history of breast cancer.

Variables	Frequency(%)
Menopausal	
Yes	126(42)
No	174(58)
Family history of breast cancer	
Yes	02(0.66)
No	298(99.33)

Table 2:- Menopausal and family history of breast cancer of 30-60 years of women residing in Dhanas and Daddu Majara Colony, Chandigarh N=300

Table 3, represents the level of suspicion of breast malignancies through clinical breast examination ; i.e. 1.66% (CBE) and 1.34% using Breast-i-led machine.

Level of suspicion of breast malignancies	Clinical breast examination (CBE)f (%)	Breast-i-LED machinef (%)
Suspicious	5(1.66)	4(1.34)
Not suspicious	295(98.34)	296(98.66)

Table 3:- Level of suspicion through clinical breast examination (CBE) and Breast-i LED machine N=300.

Discussion

Breast cancer is the top cancer in women in both the developed and the developing countries. The progression of breast cancer is increasing more vigorously in child bearing age as compared to the older women and the reason behind increase in mortality is due to lack of knowledge and information regarding breast cancer⁽⁷⁾. The current study was undertaken and to screen the suspect breast malignancies using Clinical breast examination (CBE) and Brest-i-Led machine.

Early diagnosis of the breast cancer in order to improve breast cancer outcome and survival remains the cornerstone of breast cancer control. At present people have more drug options for the chemoprevention of breast cancer and there is little solution to improve patients' quality of life. (Biological prevention- humanized monoclonal antibody).⁽⁸⁾ Hence, early diagnosis strategies focus on providing timely access to cancer treatment by reducing barriers to care and/or improving access to effective diagnostic services.

Screening consists of testing women to identify cancers before any symptoms appear. Various methods have been evaluated as breast cancer screening tools, including Screening mammography, Full filled digital mammography and computer aided detection programme, clinical breast examination, breast self-examination, Magnetic Resonance Imaging (MRI), Ultrasounds etc⁽³⁾. However, in developing countries due to scarcity of health resources all these modern techniques of breast screening are not fully available until grassroots level.

The result of clinical breast examination was noted as positive and negative findings. The positive findings (1.66%) in this study were breast pain during examination and while lying down, and presence of palpable nodule in the

breast and abnormal discharge from the breast. While negative findings indicated absence of any clinical breast abnormality. After examination by with the help of Breast-i-LED machine. The second examination was done by clinical breast examination.

Breast-i-LED machine, which we used in this study, is a trans-illumination aid, which provides optical image of the breast. The examination was done in a dark room with the probe turned on and was pressed tightly against the breast. The whole breast is examined with the help of the probe including nipples. After assessment examiner noted down the findings as positive or negative. The positive finding (1.34%) indicated presence of darker spot means presence of lesion which could be adenoma or could be malignant tumour (**Figure No. 3**). The negative findings mean absence of any breast abnormality or malignancy (**Figure No. 2**). During Clinical breast examination, examiner taught the steps of breast self-examination to the participant and participants with positive findings were referred to the urban health centre – Daddu Majara Colony.

In one study it has been explained that how this machine works i.e. in this machine the degree of light absorption determined by the number of blood cells per unit volume of breast tissue produced shadows in the case of blood filled cysts, abscess, hematomas, and neoplastic tumours. Thus, a normal healthy breast will appear red with uniform brightness along with well-defined black vein structure. A benign lesion, which has no associated angiogenesis, will not give the dark shadow. However, any angiogenesis or similar breast abnormality will give rise to a dark area or shadow enabling the detection of suspicious lesions even if it is not palpable⁽⁵⁾.

In this present study the level of suspicion was 1.66% using clinical breast examination and 1.44% using Breast-i-LED machine. The women were referred for further investigation. Further follow-ups were not planned due to lack of time, which is the limitation of this study. One another study concluded that optical imaging using hand held devices and probes are still remain an extensive work to be performed to assess optical devices as potential future breast prescreening devices⁽⁹⁾.

A study done in Iraq on 150 female patients who visited the Main Training and Research Centre for early detection of breast cancer using Hope light device and then the findings were compared with the results of clinical breast examination, mammography, ultrasound, and fine needle aspiration cytology (FNAC) as the gold standard for sensitivity and specificity. The study findings include Breast cancer in 24% of the cases, positive findings in 80.56% (True Positive), negative findings 19.44% (False Negative) using hope light device. FNAC revealed benign pathology in 73.72%. Of those, negative findings were recorded using the device in 53.47%, (True Negative), while in the remaining 46.53% the device yielded false positive findings. The author concluded that there was a significant accuracy of Hope light Light in detecting palpable malignant breast lumps, while there was a high false positive detection rate and the significantly low specificity in excluding malignancy preclude its use as a screening tool for breast cancer⁽¹⁰⁾. Another study done in Yazd Iran in 2013 on 500 women showed that the efficacy of Breast light in detection of breast changes as domestic apparatus was appropriate. However, it is recommended further studies to evaluate the Breast light efficacy and accuracy in detection of breast lesions⁽¹¹⁾.

A systematic review results on Near Infra Red Fluorescence imaging (NIRF) shows that it helps to identify the key anatomical landmark and pathological structures for oncological and non-oncological procedures. Although the level of evidence is predominantly low and longer follow ups are needed to assess the impact of these new technologies on long term ontological and functional outcomes.⁽¹²⁾ Another study in Cairo University results that these breast illumination methods with Breast light apparatus is a easy to use tool to screen for breast cancer at primary level⁽¹³⁾.

Conclusion

BREAST-i-LED machine worked as an immediate source to provide prompt referral for women who were suspected to be suffering with certain breast malignancy. Further study could be helpful to provide exact information regarding true sensitivity and specificity of this BREAST-i-LED machine.

Funding: None.

Conflicts of Interest: None.

References

1. Burden of cancer in India: GLOBOCAN 2018 Estimates Incidence, Mortality, prevalence and future projections of cancer in India" [Internet]. ResearchGate. [cited 2020 May 27]. Available from: https://www.researchgate.net/publication/338912612_Burden_of_cancer_in_India_GLOBOCAN_2018_Estimates_Incidence_Mortality_prevalence_and_future_projections_of_cancer_in_India
2. Majeed W, Aslam B, Javed I, Khaliq T, Muhammad F, Ali A, et al. Breast Cancer: Major Risk Factors and Recent Developments in Treatment. *Asian Pac J Cancer Prev* [Internet]. 2014 Apr 30 [cited 2020 Aug 22];15(8):3353–8. Available from: <http://koreascience.or.kr/journal/view.jsp?kj=POCPA9&py=2014&vnc=v15n8&sp=3353>
3. Jacob TC, Penn NE. The Need and Value of Breast Self-examination. *J Natl Med Assoc.* 1988 Jul;80(7):777–87. WHO | Breast cancer: prevention and control [Internet]. WHO. World Health Organization; [cited 2020 May 27]. Available from: <http://www.who.int/cancer/detection/breastcancer/en/>
4. Ghartey FN, Watmough D, Debrah S, Morna M, Anyanful A. Breast-i Is an Effective and Reliable Adjunct Screening Tool for Detecting Early Tumour Related Angiogenesis of Breast Cancers in Low Resource Sub-Saharan Countries [Internet]. Vol. 2018, *International Journal of Breast Cancer*. Hindawi; 2018 [cited 2020 Jun 25]. p. e2539056. Available from: <https://www.hindawi.com/journals/ijbc/2018/2539056/>
5. Research (IJSR) IJ of S and. Accuracy of Hopelight (Mammolight) Imaging in Detection of Breast Cancer. *Int J Sci Res IJSR* [Internet]. [cited 2020 Jun 22]; Available from: https://www.ijsr.net/get_abstract.php?paper_id=ART20176232
6. Ahmed A, Zahid I, Ladiwala ZFR, Sheikh R, Memon AS. Breast self-examination awareness and practices in young women in developing countries: A survey of female students in Karachi, Pakistan. *J Educ Health Promot.* 2018;7:90.
7. Sun Y-S, Zhao Z, Yang Z-N, Xu F, Lu H-J, Zhu Z-Y, et al. Risk Factors and Preventions of Breast Cancer. *Int J Biol Sci* [Internet]. 2017 Nov 1 [cited 2020 Aug 22];13(11):1387–97. Available from: <https://www.ncbi.nlm.nih.gov/pmc/articles/PMC5715522/>
8. Godavarty A, Rodriguez S, Jung Y-J, Gonzalez S. Optical imaging for breast cancer prescreening. *Breast Cancer Targets Ther* [Internet]. 2015 [cited 2020 Jun 26];7:193. Available from: <https://www.ncbi.nlm.nih.gov/pmc/articles/PMC4516032/>
9. (26) (PDF) Evaluating the Accuracy of the “Breastlight” as a Screening Tool for Breast Cancer in Iraq [Internet]. ResearchGate. [cited 2020 Aug 22]. Available from: https://www.researchgate.net/publication/297229165_Evaluating_the_Accuracy_of_the_Breastlight_as_a_Screening_Tool_for_Breast_Cancer_in_Iraq
10. Shiryazdi SM, Kargar S, Nasaj HT, Neamatzadeh H, Ghasemi N. The accuracy of Breastlight in detection of breast lesions. *Indian J Cancer* [Internet]. 2015 Jan 10 [cited 2020 Aug 22];52(4):513. Available from: <http://www.indianjancer.com/article.asp?issn=0019-509X;year=2015;volume=52;issue=4;spage=513;epage=516;aulast=Shiryazdi;type=0>
11. Cacciamani GE, Shakir A, Tafuri A, Gill K, Han J, Ahmadi N, et al. Best practices in near-infrared fluorescence imaging with indocyanine green (NIRF/ICG)-guided robotic urologic surgery: a systematic review-based expert consensus. *World J Urol* [Internet]. 2020 Apr 1 [cited 2020 Aug 22];38(4):883–96. Available from: <https://doi.org/10.1007/s00345-019-02870-z>
12. Labib NA, Ghobashi MM, Moneer MM, Helal MH, Abdalgaleel SA. Evaluation of BreastLight as a Tool for Early Detection of Breast Lesions among Females Attending National Cancer Institute, Cairo University. *Asian Pac J Cancer Prev* [Internet]. 2013 [cited 2020 Aug 22];14(8):4647–50. Available from: <http://koreascience.or.kr/article/JAKO201332479512386.page>.