

 <p>ISSN NO. 2320-5407</p>	<p>Journal Homepage: - www.journalijar.com</p> <p>INTERNATIONAL JOURNAL OF ADVANCED RESEARCH (IJAR)</p> <p>Article DOI: 10.21474/IJAR01/12834 DOI URL: http://dx.doi.org/10.21474/IJAR01/12834</p>	 <p>INTERNATIONAL JOURNAL OF ADVANCED RESEARCH (IJAR) ISSN 2320-5407</p> <p>Journal Homepage: http://www.journalijar.com Journal DOI: 10.21474/IJAR01</p>
---	--	---

RESEARCH ARTICLE

STUDY ON CLINICAL PROFILE , MANAGEMENT & OUTCOME OF GASTROINTESTINAL DUPLICATION IN CHILDREN

Dr. C. Sankkarabarathi¹ and Dr. R. Dhinesh Kumar²

1. Associate Professor Dept of Paediatric Surgery, Madras Medical College Institute of Child Health, Egmore Chennai.
2. Assistant Professor Dept. of Paediatric Surgery, Kanyakumari Government Medical College.

Manuscript Info

Manuscript History

Received: 10 March 2021
Final Accepted: 14 April 2021
Published: May 2021

Abstract

Duplication of the gastrointestinal tract occur any part of the alimentary tract from the tongue to the anus. Male have slightly more predominance than females. Gastrointestinal duplication will have a varied presentation. Ileum and the oesophagus are most commonly involved. Colonic duplication is rare and can present with diagnostic difficulties. Gastrointestinal duplication has presence of well developed coat of smooth muscle, intimately attached to the gastrointestinal tract in the mesenteric region and show a common blood supply with the native bowel. Sometime it will have an epithelial lining representing some portion of the alimentary tract.

Copy Right, IJAR, 2021,. All rights reserved.

Introduction:-

In 1733 Calder reported first case of gastrointestinal duplication. William E. Ladd coined the term gastrointestinal duplication in 1930, that included congenital anomalies of the foregut, midgut and hindgut. The incidence is of 1 in every 4500 autopsies. Enteric duplications are multiple in 10% to 20% cases. Duplication of the gastrointestinal intestinal tract occur any part of the alimentary tract from the tongue to the anus. Male have slightly more predominance than females. Gastrointestinal duplication will have a varied presentation. Ileum and the oesophagus are most commonly involved. Colonic duplication is rare and can present with diagnostic difficulties. Gastrointestinal duplication has presence of well developed coat of smooth muscle, intimately attached to the gastrointestinal tract in the mesenteric region and show a common blood supply with the native bowel. Sometime it will have an epithelial lining representing some portion of the alimentary tract.

Aim of the study

1. Analyzing the antenatally suspected gastrointestinal duplication postnatally and the associated anomalies.
2. Analyzing location of the duplication and the type of the duplication.
3. Analyzing the management of the gastrointestinal duplication, complication and outcome of the above.

Literature Review:-

Embryology of gastrointestinal duplication:

The embryogenesis theory of gastrointestinal duplication and enteric cyst was postulated by splitting the dorsal midline structures including the neural plate and the notochord in *Cynopus pyrrhogaster* (amphibian embryos)¹ and there by inducing separation of the notochord and gut endoderm herniation. They were traced morphologically,

Corresponding Author:- Dr. C. Sankkarabarathi

Address:- Associate Professor Dept of Paediatric Surgery, Madras Medical College Institute of Child Health, Egmore Chennai.

histologically and observed gastrointestinal duplication and enteric cyst with spina bifida, vertebral anomaly, sub cutaneous manifestations and split cord malformations. Together these anomalies called as “split notochord syndrome”. Gross RE, they are simple mechanical accidents during embryogenesis and explained that gastrointestinal duplications are non-chromosomal, non-hereditary, non-pathogenic^{2,3}.

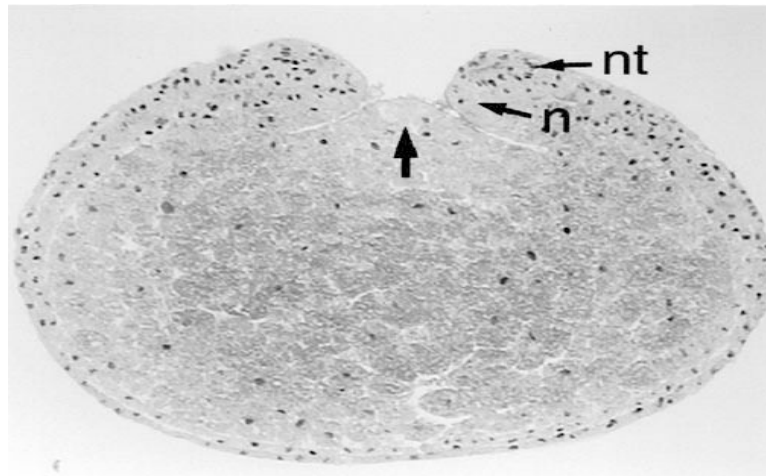


Fig 1:- Arrow showing herniated gut anlage endoderm between nt-neural tube, n-notochord.

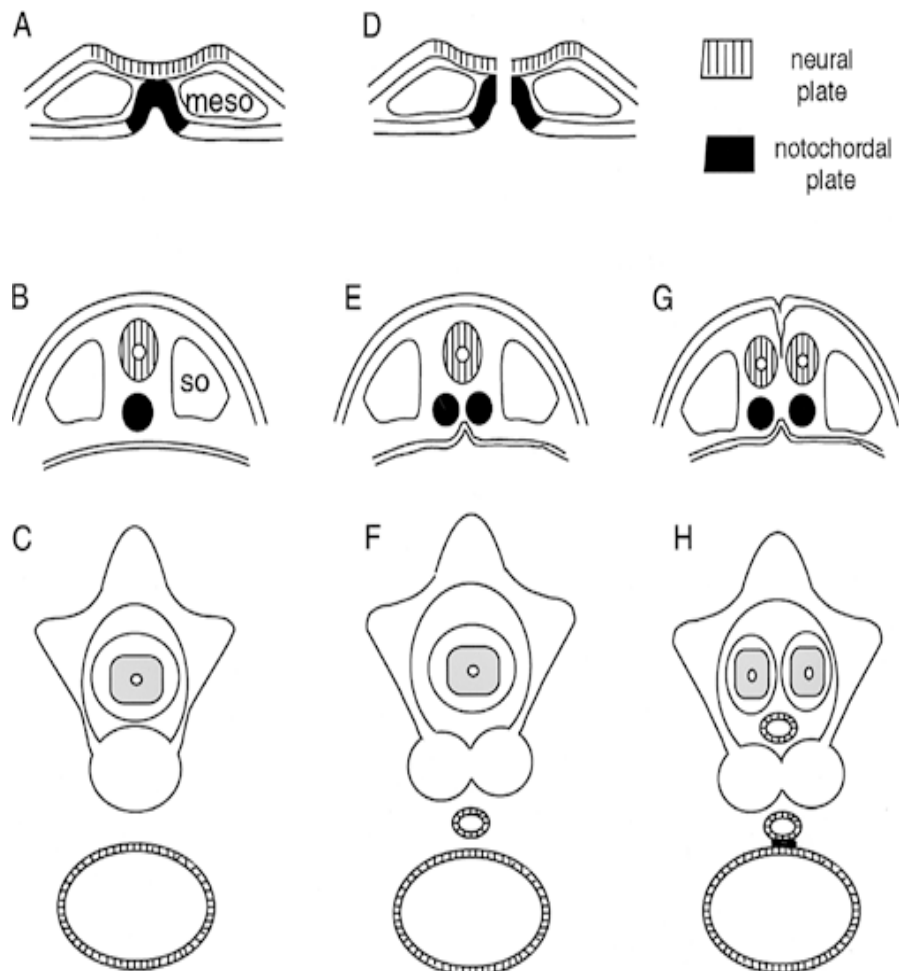


Fig 2:- Embryonic pathogenesis of enteric cyst and gastrointestinal duplication (so – somite, meso – mesoderm).

A. The notochord tube attached laterally to surface ectoderm and ventrally to the gut endoderm

- B. The neural folds fuse and get covered by the surface ectoderm. The notochord lies dorsally after getting pinched off and it will lie separated from the gut endoderm. Somatic cells lying ventromedially migrate and form vertebral bodies around the notochord.
- A. The costal and neural processes form after the sclerotome surrounds the vertebral body
- B. The notochord gets separated by the midline lesion

Through the separated notochord, the gut endoderm herniates

- A. Above incident lead to anterior spina bifida. Enteric cyst forms from the entrapped endodermal tissue.
- B. The surface ectoderm fuses in the midline and forms two notochord and two neural tubes
- C. Two spinal cord forms and the entrapped endodermal tissue forms the of gastrointestinal duplication

Etiology

1. Various theories proposed, for the explanation of gastrointestinal duplication. But no single theory explains all the variants
2. Bremers theory⁴ called the accessory neuroenteric canal. He described the accessory neuroenteric canal have the character of neuroenteric canal but differs in position and size.
3. This accessory neuroenteric canal split the neural epithelium and notochord in embryogenesis.
4. Partial or abortive twinning⁵, earlier split in primitive streak will cause caudal end of the fetus complete twinning. Late split in the primitive streak will cause only colonic duplication.
5. Theory of Beardmore and Wigglesworth⁶ explained the development of adhesion between the ectoderm and endoderm, dissects the notochord into two hemineural plates.
6. Saunders and co workers theory^{7,8} said the initial abnormality in the duplication of the notochord followed by ectodermal and endodermal interaction as secondary event.
7. Diverticula and canalization defects⁹, the fetal alimentary tract will be in solid state later it will recanalize from cranial to caudal direction, but this theory fails to explain heterotopic mucosa.
8. Environmental factors^{9,10} like trauma and hypoxia can produce gastrointestinal duplication

Clinical features

Prenatal ultrasonography will pick up gastrointestinal duplication^{11,12} in majority of cases. Within two yrs of age most of the gastrointestinal duplication are diagnosed¹⁴. Depending on the location (foregut, midgut, hindgut) the size of the duplication, the presence of heterotopic mucosa will have varied presentation. Some of the duplication will be diagnosed incidentally on evaluation of nonspecific symptoms like abdominal pain, constipation and cough. Some of them will present as emergency with symptoms like ulceration, bleeding and perforation from the heterotopic gastric mucosa in the gastrointestinal duplication. Most of the cases of ileal duplication are taken as emergency as acute appendicitis.

Gastrointestinal duplication can be either cystic or tubular, seen on the mesenteric border. Presence of gastrointestinal duplication in the thoracic cavity can have symptoms like respiratory distress, failure to thrive, dysphagia and vomiting. Hemorrhage and infection of the gastrointestinal duplication in the thoracic cavity can cause sudden increase in the size of the swelling and may present as chest pain and respiratory distress.

Associated anomalies

1. Vertebral anomalies, bifid or fused spines. More common with thoracoabdominal and thoracic duplication
2. Malrotation
3. Intestinal atresias
4. Anorectal malformation like rectovestibular fistula
5. Genitourinary malformation like extrophy bladder
6. Congenital cystic adenomatoid malformation, pulmonary sequestration
7. Cardiac malformation.

Diagnosis

Van Dam in 1984 diagnosed enteric duplication in an antenatal mother at 20 weeks¹⁵. Hughes¹¹ suspected gastric duplication noticed as cyst at the gestational age of 16 weeks in antenatal ultrasound. Correia Pinto et al diagnosed antenatally 14 cases of enteric duplication diagnosed by ultrasonogram (USG)¹³. Postnatal evaluation of the antenatally diagnosed cases will show an anechoic cysts. The two important ultrasound signs are the presence of peristalsis and the "double wall" sign. The "double wall" sign^{16,17} means the inner hyperechoic rim indicating

mucosa and submucosa and the outer hypoechoic indicating muscularis propria. The duplication cyst wall will show both smooth muscle and mucosa. Thoracic duplication presented as hydrops fetalis and in utero thoracoamniotic shunting done. Technetium TC 99m pertechnetate scan done in cases .

patients presenting with bleeding per rectum and ultrasound picks up a cystic lesion in the abdomen

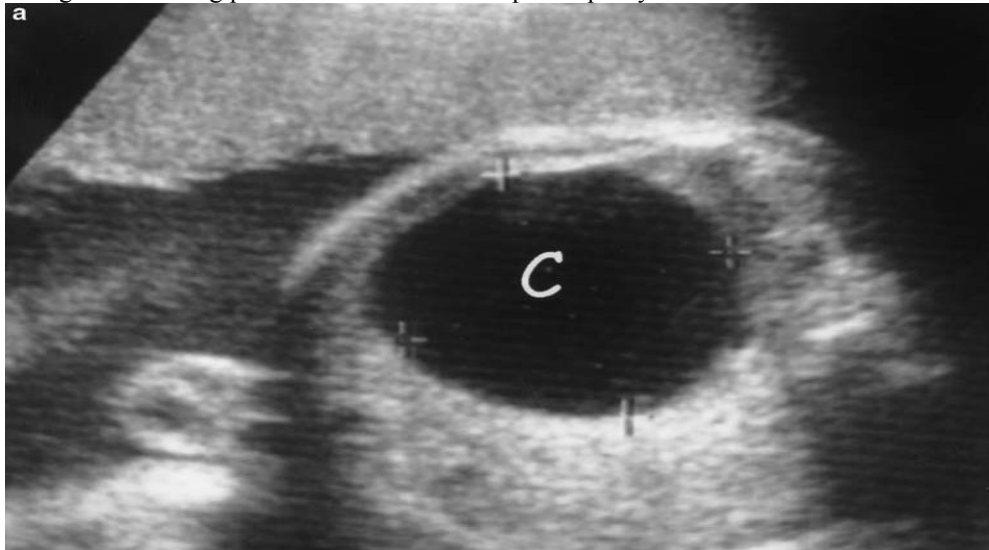


Fig 3:- Antenatal ultrasound showing cystic lesion upper abdomen.

Foregut duplication better diagnosed by the endoultrasonography. X-ray of the spine will show segmentation errors. Gastrointestinal contrast study will show the communication of the tubular duplication to the native bowel and compression by the cystic duplication in the adjacent bowel. Enteric duplication will have enhancing rim in computed tomography.

Magnetic resonance imaging (MRI) will help in the diagnosis and it is more accurate than ultrasound in delineating fetal anatomy. In fetal MRI Gastrointestinal duplications appear hyperintense in T1 – weighted images and hypointense in T2 – weighted images.

Cervical esophageal duplications

This is a rarest type of esophageal duplication. Blasius in 1971 reported first case of cervical esophageal duplication cyst¹⁸. The incidence is 1 in 8200. Duplication cyst of esophagus are benign, cystic lesion derived from primitive foregut that occur in neck, mediastinum or both. Two thirds of the duplication occur on the right side of the mediastinum.

About 80% of the cervical esophagus will not communicate with the esophageal lumen. Foregut duplication cyst are of three types bronchogenic, esophageal and neuroenteric. Among the duplication, esophagus is the second most commonest site of duplication.

In the mediastinum bronchogenic cyst is the most commonest cystic lesion. If the esophageal duplication cyst extends into spinal canal then it is called as neuroenteric cyst. About 60% occur in the lower one third of the esophagus . Most of them are incidentally noted. They usually present with respiratory distress that will need emergency intubation and the rest of them may present with the symptoms of either dysphagia, epigastric discomfort and retrosternal pain. Treatment is complete excision of the duplication or excision of the mucosa if excision of the duplication not possible . The approach for the excision of the cyst are axillary thoracotomy, cervical excision, median sternotomy or by thoracoscopy. Review of literature showed 18 cases reported as of cervical esophageal duplication cyst¹⁹. An early detection of cervical oesophageal duplication was done in an antenatal mother at 30 weeks and operated at 35 days of life due to respiratory failure. The differential diagnosis for the duplication cyst in the neck are thyroglossal cyst and lymphatic cyst.

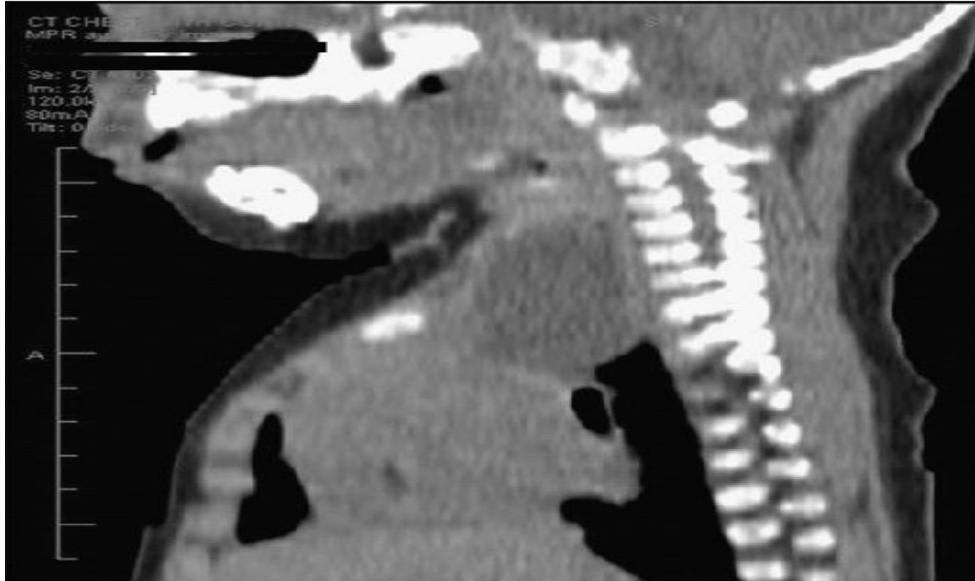


Fig 4:- Sagittal view of the CT showed cervical duplication

Thoracic and thoracoabdominal duplications

Majority of the duplication present in the posterior mediastinum lower half. As these duplications are connected to the spinal canal with vertebral anomalies they are referred as neuroenteric cyst. About 20% of the duplication arise in the thorax or thoracoabdominal²⁰. In thoracic duplication diagnosed antenatally in utero therapy is done if there is fetal distress.

Some of the duplication are noticed incidentally in chest x ray. Computed tomography (CT) of the thorax and the abdomen, done in cases of thoracic duplication, because of the association of the abdominal duplication in more than one fourth of the cases. To know the relation of the duplication to the spinal canal, magnetic resonance imaging (MRI) of the spine done

A oral contrast study will define the relation of the duplication cyst to the esophagus. The differential diagnosis of the mediastinal duplication are neurogenic tumors and the pericardial cyst. Technetium Tc 99m pertechnetate scan picks up presence of ectopic gastric mucosa in the thoracic duplication cyst.

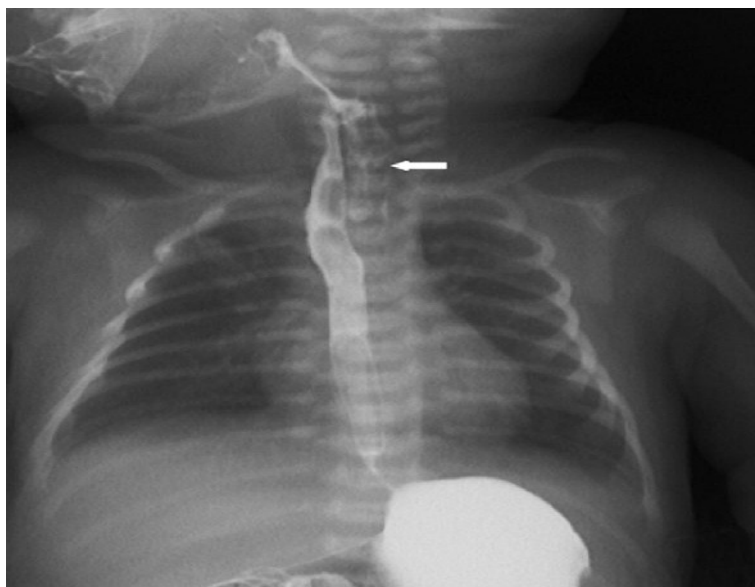


Fig 5:- Oral contrast study showing esophageal duplication near the native esophagus.

The excision of the duplication can be done either thoractomy or by thoracoscopically. If excision of the duplication not possible then excision of the mucosa of the duplication done to avoid recurrence and malignancy. Thoracoscopic aspiration of the cyst can be done in case of a large thoracic duplication before excision. In cases of thoracic duplication with intraspinal extension, intraspinous portion of the cyst should be done. Excision of large thoracoabdominal duplication may be done in staged procedure.

Abdominal foregut duplications

Along the greater curvature most of the gastric duplication occur. About 82% are cystic and non communicating but they will have a common blood supply and muscular layer²¹, 18% are tubular and communicating.

There are four case reports of isolated duplication cyst (IDC)²¹ which shows no connection with the alimentary tract but two of them showed gastric mucosa²¹. They present at younger age with the symptoms of abdominal distension, vomiting, pain abdomen, gastroesophageal reflux and with anemia due to the bleeding from the ectopic gastric mucosa. They may even present with pneumoperitoneum or hemoperitoneum. Ultrasound will pick up a large cystic mass in relation to the stomach.

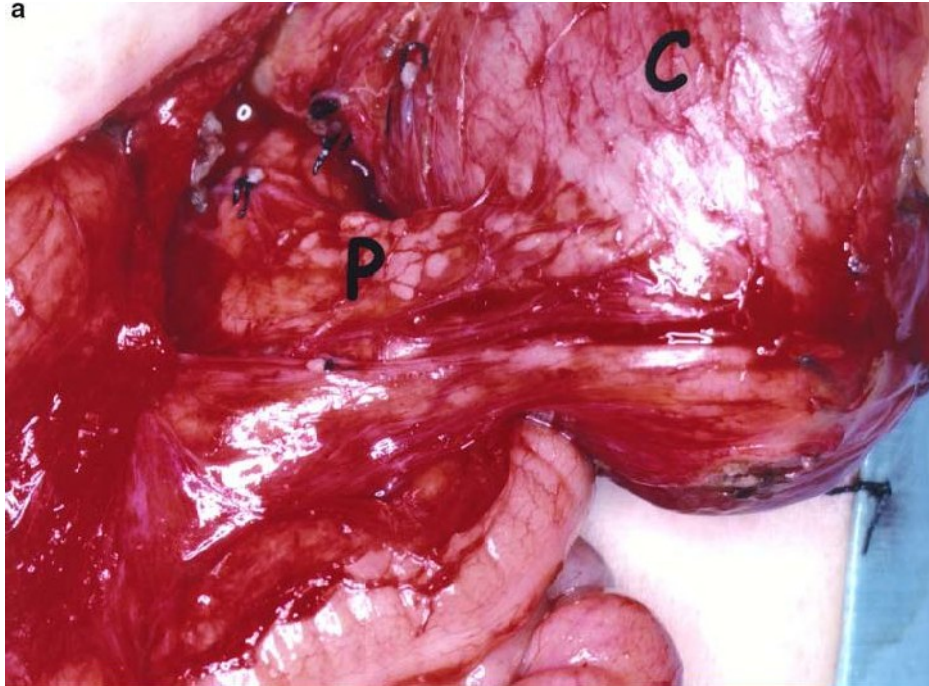


Fig 6:- Cystic gastric duplication(C)in relation to the tail of Pancreas(P).

Oral contrast study will help to know the relationship to the stomach and the extent of the lesion. The differential diagnosis of a large right hypochondrial gastric duplication is choledochal cyst.

The treatment of gastric duplication is complete excision if possible. If complete excision not possible, then partial cyst excision or segmental gastrectomy or excision of the mucosa can be done.

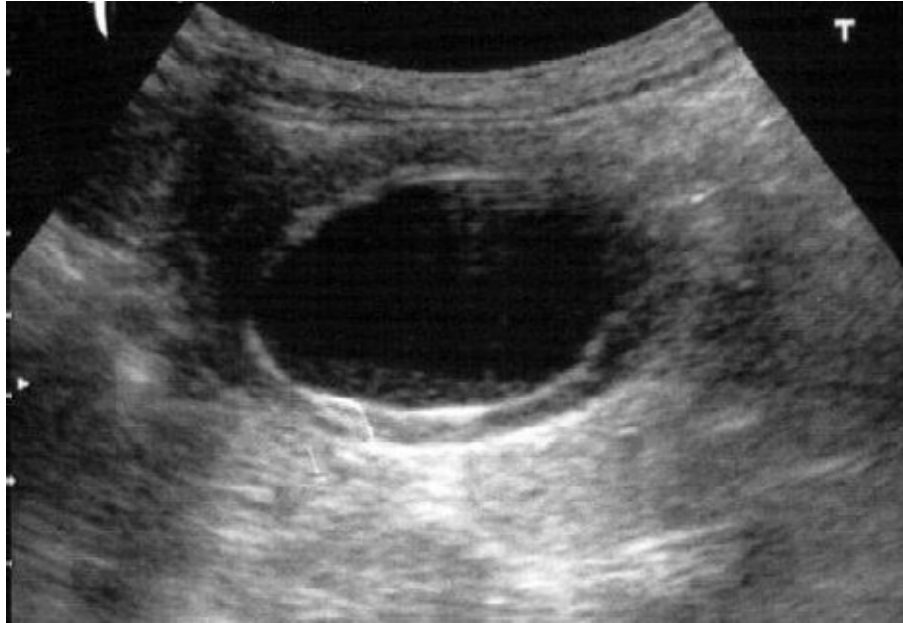

Fig 7:- Double wall sign in gastric cystic duplication.

Pyloric duplication

Pyloric duplication can present as early as six days of life. They usually present with symptoms that mimic hypertrophic pyloric stenosis. Ultrasonogram (USG) will be of little benefit in diagnosing pyloric duplication and very difficult in differentiating from hypertrophic pyloric stenosis. There are case reports of pyloric duplication with aberrant pancreatic duct²². Complete excision of the pyloric duplication is the treatment of choice.

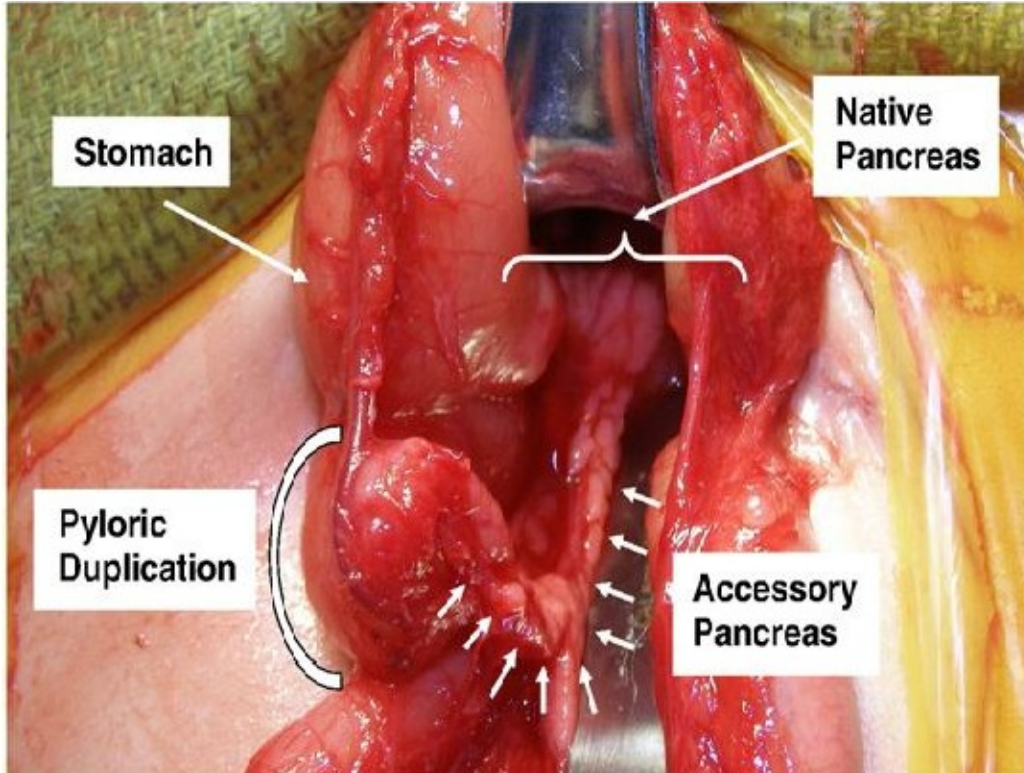


Fig 8:- Intraoperative picture showing pyloric duplication with accessory pancreas.

Duodenal duplication incidence is 5% - 7%. Normally located in the medial border of duodenum and will be non-communicating. They are more common in the first and second part of duodenum. It will have varied presentation like nausea, weight loss, vomiting, jaundice and gastrointestinal bleeding.

There are case reports of recurrent pancreatitis, due to the involvement of ampulla of vater in the wall of duodenal duplication. Adenocarcinoma arising from the Duodenal duplication reported.

The differential diagnosis of duodenal duplication in the right hypochondrium is choledochol cyst.

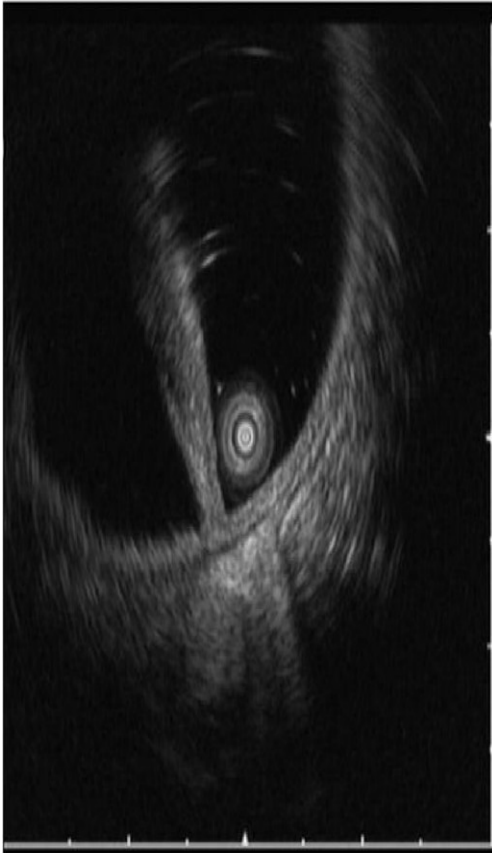


Fig 9:- EUS showing biliary tree duodenal duplication

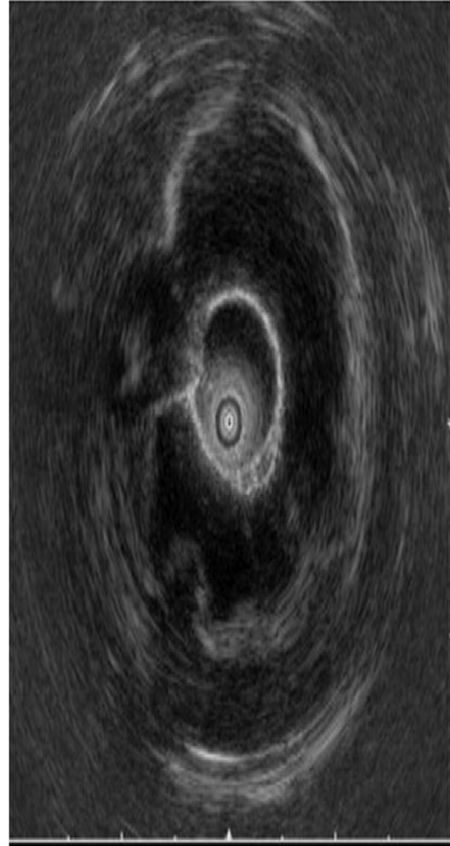


Fig10:- EUS showing without involvement in biliary tree involvement.

Endoscopic retrograde cholangiopancreatography (ERCP) and Magnetic resonance cholangiography (MRCP) will help in the diagnosis, whether duodenal duplication is communicating with ampulla of vater or not. Treatment is resection of the duodenal duplication and reconstruction with intraoperative cholangiography to know whether biliary communication is there or not. If resection not possible then either marsupialization of the cyst or Roux-en-Y loop of jejunum anastomosed to the cyst can be done. Cystic duplication can be treated by endoscopic incision if the ampulla of vater not involved. Short hospital stay and procedure time are the advantages of endoscopic excision.

Duplication of the small intestine

Most commonest gastrointestinal duplication. Majority occur in the ileum. Duplication of the small intestine can be either tubular (18%) or cystic (82%). Duplication may be communicating or non communicating.

Child can present with abdominal pain, distension and vomiting. In small bowel intussusceptions these cystic duplication may act as a lead point. They may present as bleeding and perforation from the ectopic gastric mucosa in the duplication cyst which can be diagnosed by the technetium-99m pertechnetate scan.

Depending upon the blood supply there are two type of duplicatons

Type I: (Parallel) the artery supplying the duplication will be on one side and the artery supplying the native bowel will be on the other side

Type II : (Intramesentric) the mesenteric vessel on both sides will pass through the duplication and will enter the native bowel

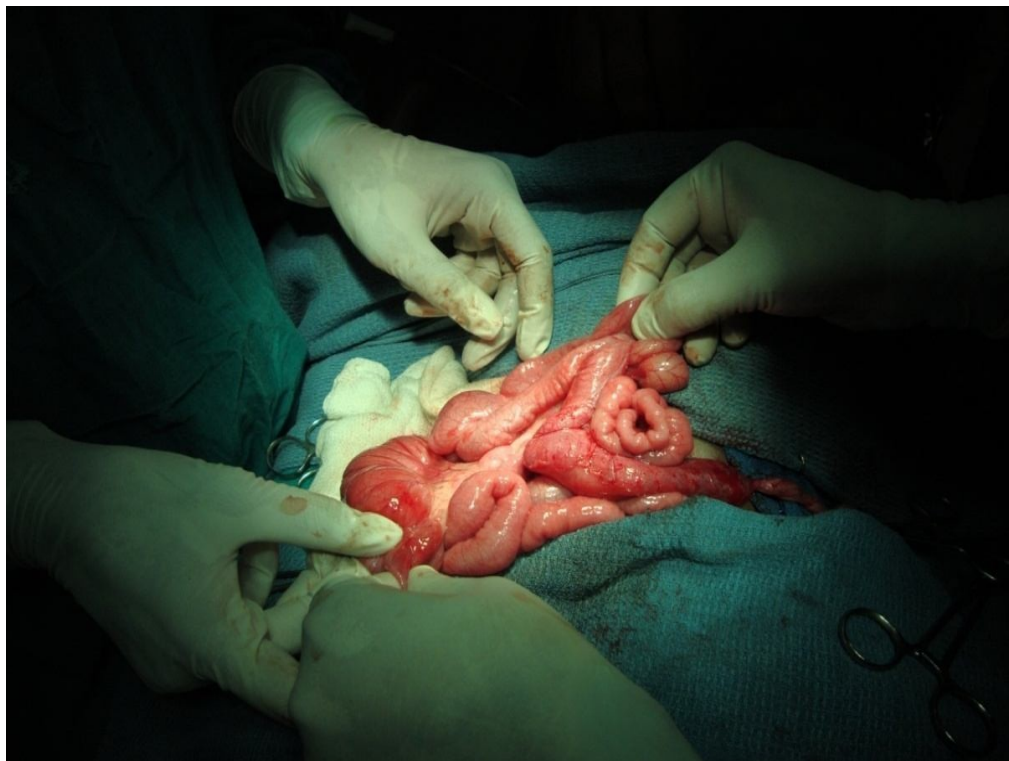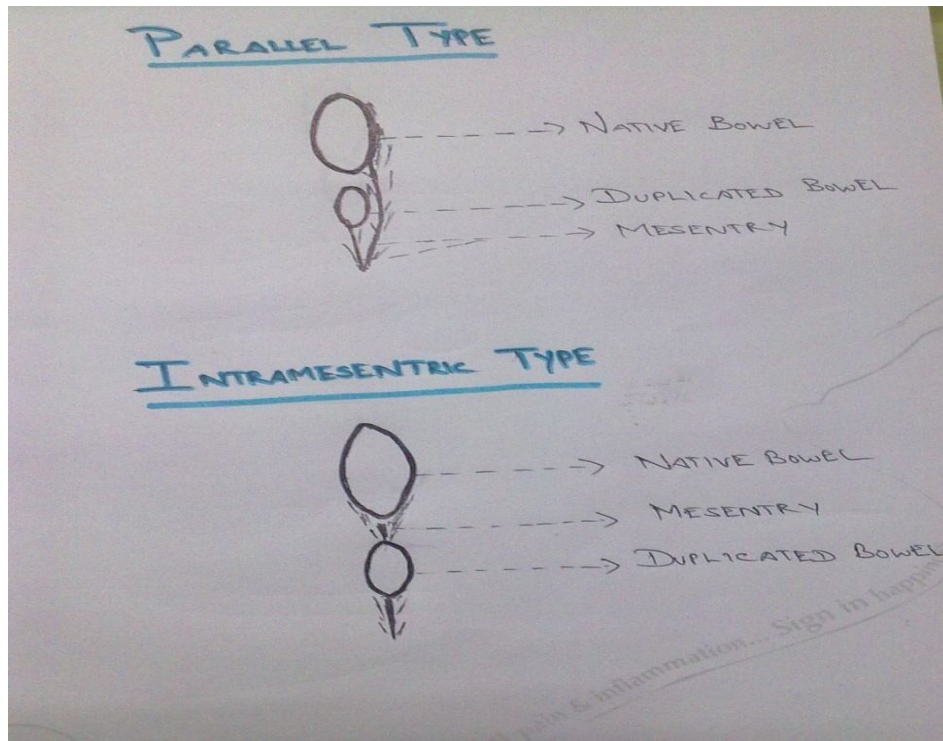


Fig 11:- Intraoperative picture showing complete tubular duplication of the small bowel.

Li and colleagues found 90% of the type II lesion had thoracic vertebral anomaly. The treatment for type I duplication is dividing the mesentery with straight artery and contralateral artery safe guarded. In type II the small branches of the straight arteries are divided and the duplication is enucleated²³. If duplication is not resectable then Roux- en-Y loop of jejunum anastomosed to the cyst.

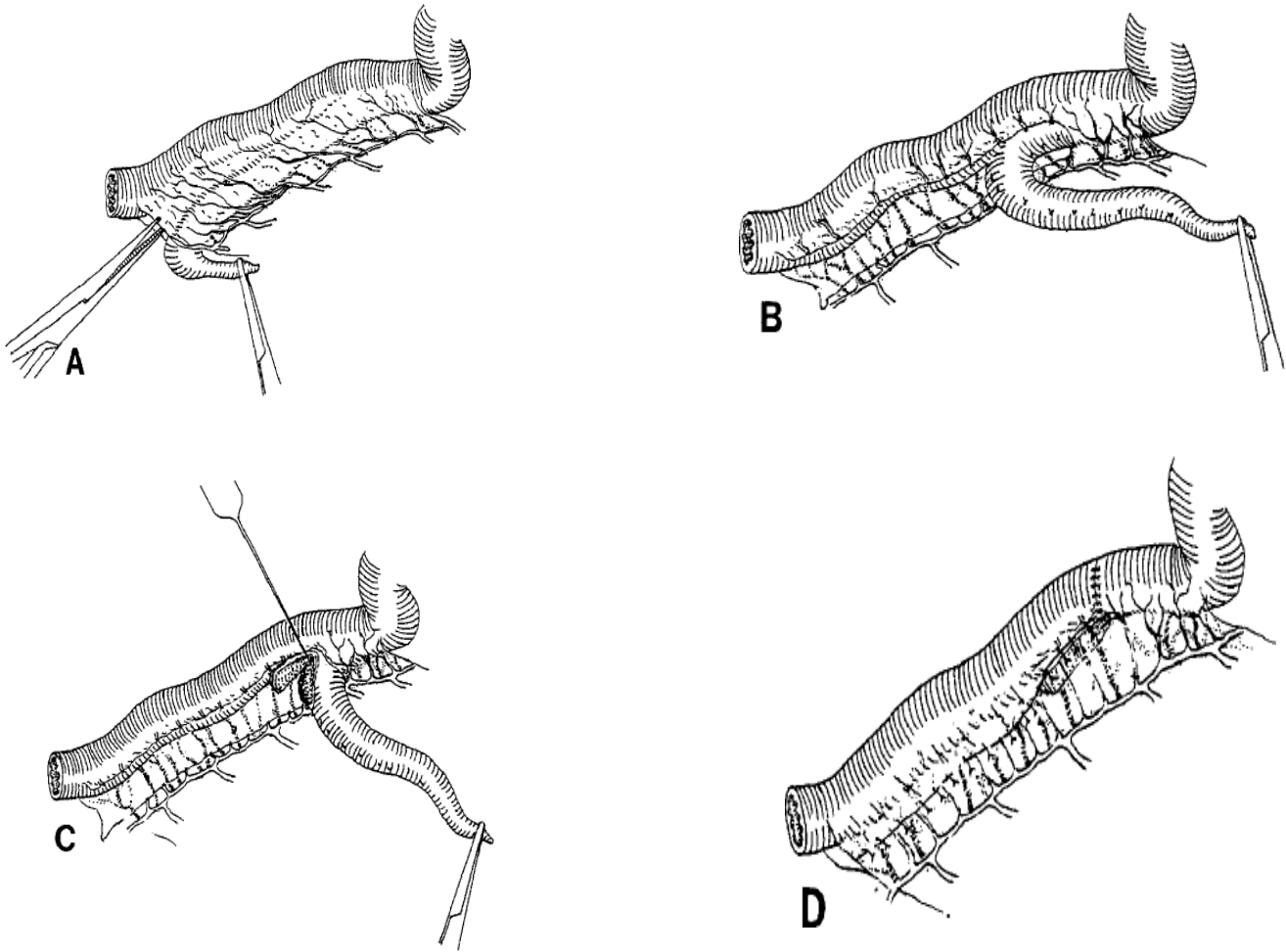


Fig 12:- Bianchi principle of bowel lengthening applied for the resection of the tubular duplication.

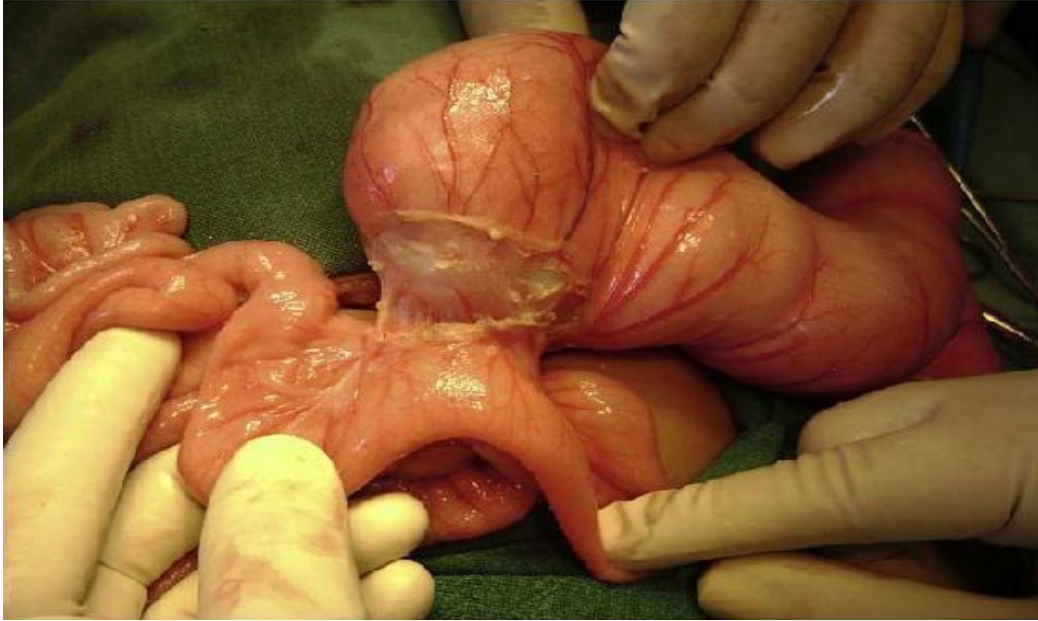

Fig 13:- Non communicating isolated duplication cyst of ileum.

Hindgut duplications

Colonic and rectal duplications constitute 17% of gastrointestinal duplication. They have been found in the conjoined twins and may be associated with duplication of the genitalia and urinary tract. Rectal duplication more often present as a cystic type in the presacral region behind the rectum. Sometimes the tubular duplication will be extensive involving the entire colon and present as second opening in the perineum or in the posterior wall of the vagina. Hindgut duplications are of three classes. The first class is the short tubular mass or cystic type seen in the mesentery of the colon and they are rare. The second class is the midline cystic mass behind the rectum

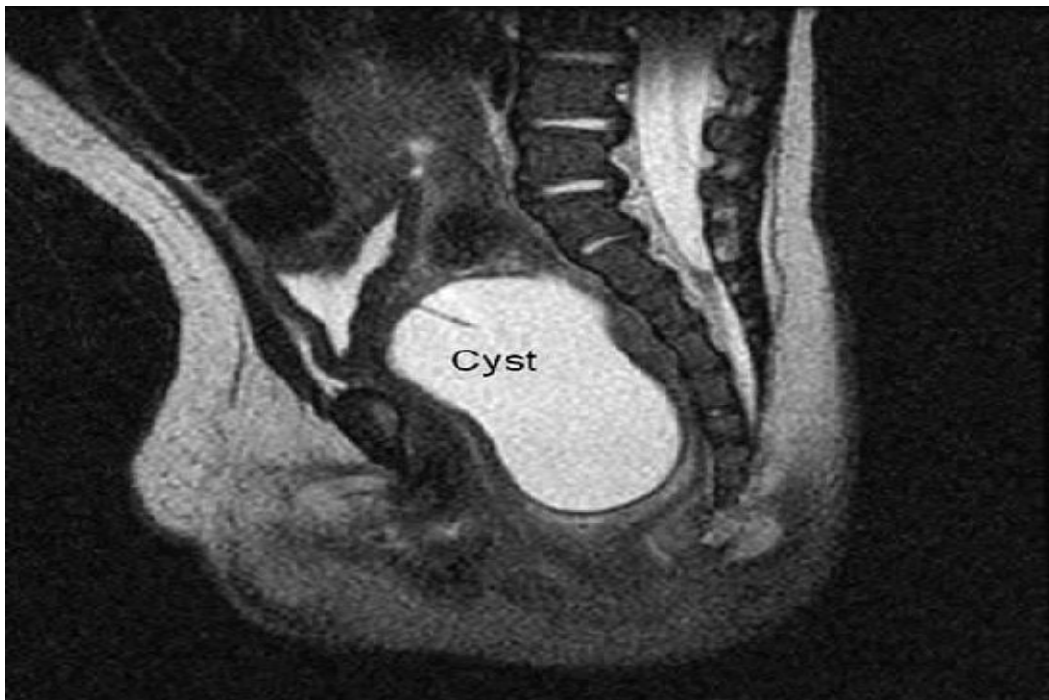

Fig 14:- Large rectal duplication in front of the sacrum pushing rectum anteriorly and in front of the sacrum or coccyx and sometimes they will extend into the peritoneal cavity. This can be removed without damaging the blood supply of the rectum. The third class is more common in females and they are side to side duplication of the rectum

and colon. They are more commonly associated with spina bifida and genitourinary anomalies. The treatment is fenestration of the duplication lumen and or partial resection.

Hindgut duplication can present as rectovaginal fistula, abdominal distension and constipation or passing flatus and feces through the vagina. Other presentations are rectal bleeding, perirectal abscesses or fistula. Computed tomography (CT), magnetic resonance imaging (MRI) and retrograde injection of the contrast media will show the relation of the duplication to the rectum and the extent of the duplication. An autosomal dominant condition called Curarino triad is the presacral mass along with the rectal stenosis and sacral anomalies.

Short cystic duplication can be treated with limited colon resection or excision of the duplication from the mesentery. Presacral duplication can be removed by posterior sagittal approach. In case of infected presacral duplication it is better to drain externally than into the rectum. Sometimes a combined abdominal and perineal approach may be needed for the excision of the duplication²⁴. During excision of the presacral lesion, the chance of injuring the bladder neck, sphincter and ureters are more, so preoperative stenting of the ureters may help in decreasing the injury. In case of non resectability of the lesion temporary diverting colostomy can be done. The commonest complication is recurrence if not properly

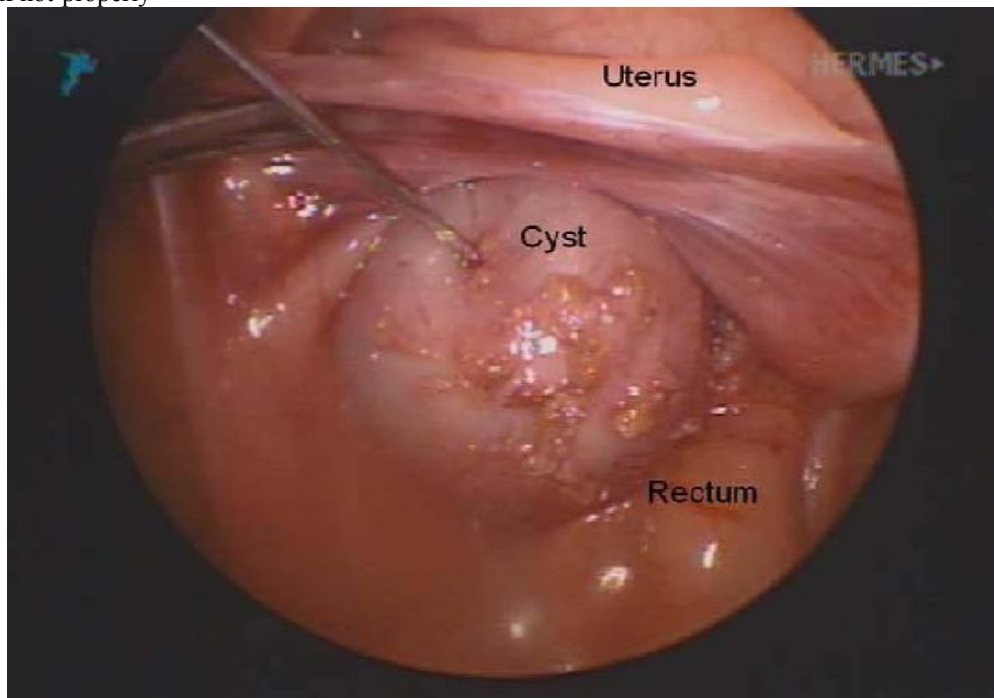


Fig 15:- Laparoscopic picture showing duplication cyst anterior to the rectum excised. In long-side -by-side duplication fenestrating the two lumina both proximally and distally can be done. In case of rectal duplication with two perineal openings excision of the duplication that does not pass through the sphincter is done and may also need sphincter muscle complex reconstruction²³.

Materials And Methods:-

Study Population:

Cases admitted and diagnosed as gastrointestinal duplication made on USG findings

Nature Of Study :

Prospective study

No Of Cases :

20

Study Period :

August 2010 to February 2013

Selection criteria Inclusion criteria

1. All cases of antenatally suspected gastrointestinal duplication in the postnatal period
2. All cases of foregut, midgut and hindgut duplication
3. All cases of cystic and tubular gastrointestinal duplication
4. All cases of communicating and non-communicating duplication

Exclusion criteria

1. Bronchogenic cyst
2. Omental cyst
3. Mesenteric cyst

Methodology:-

1. All the above patients were subjected to detailed history and clinical examination.
2. Relevant investigations were performed like x-ray chest and abdomen, Ultrasonogram abdomen(USG), Computed tomography (CT), Magnetic resonance imaging (MRI) and gastrograffin study done if needed.
3. The intraoperative findings like location of the duplication, the type of duplication, whether communicating or non-communicating
4. ,the number of duplication, resectability of the lesion analysed.
5. The analysis of the procedures like excision of the duplication only, excision of the duplication along with the native bowel and end to end anastomosis, mucosal excision of the duplication done. The complication during the surgery and in the postoperative period are studied. These patients are followed up to the available period. The results were analysed and tabulated.

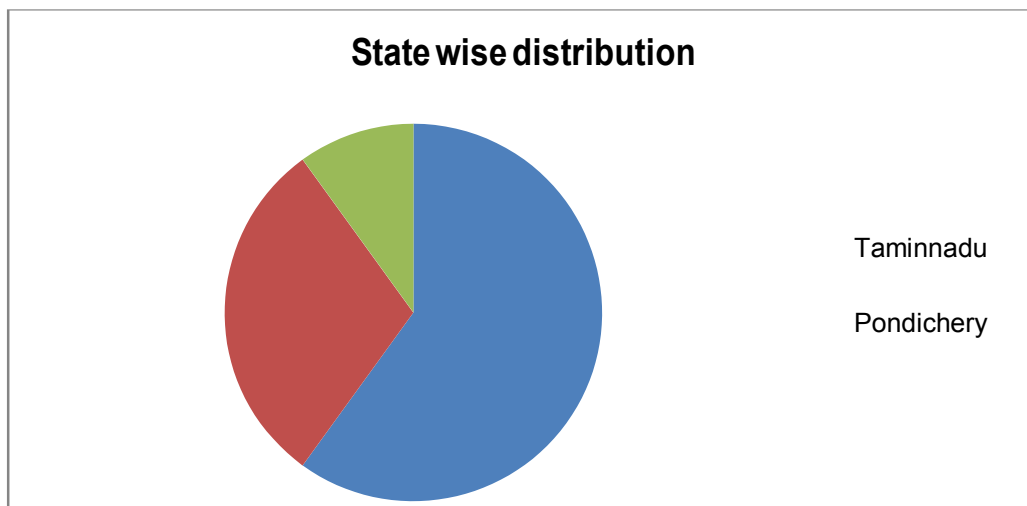
Observations And Results:-

This study of Gastrointestinal duplication presented to Department of Paediatric surgery, Institute of Child health and health centre, Madras Medical College, Chennai was undertaken between August 2010 to February 2013. The following facts were obtained.

During this study period, 20 patients who met the selection criteria were taken for analysis

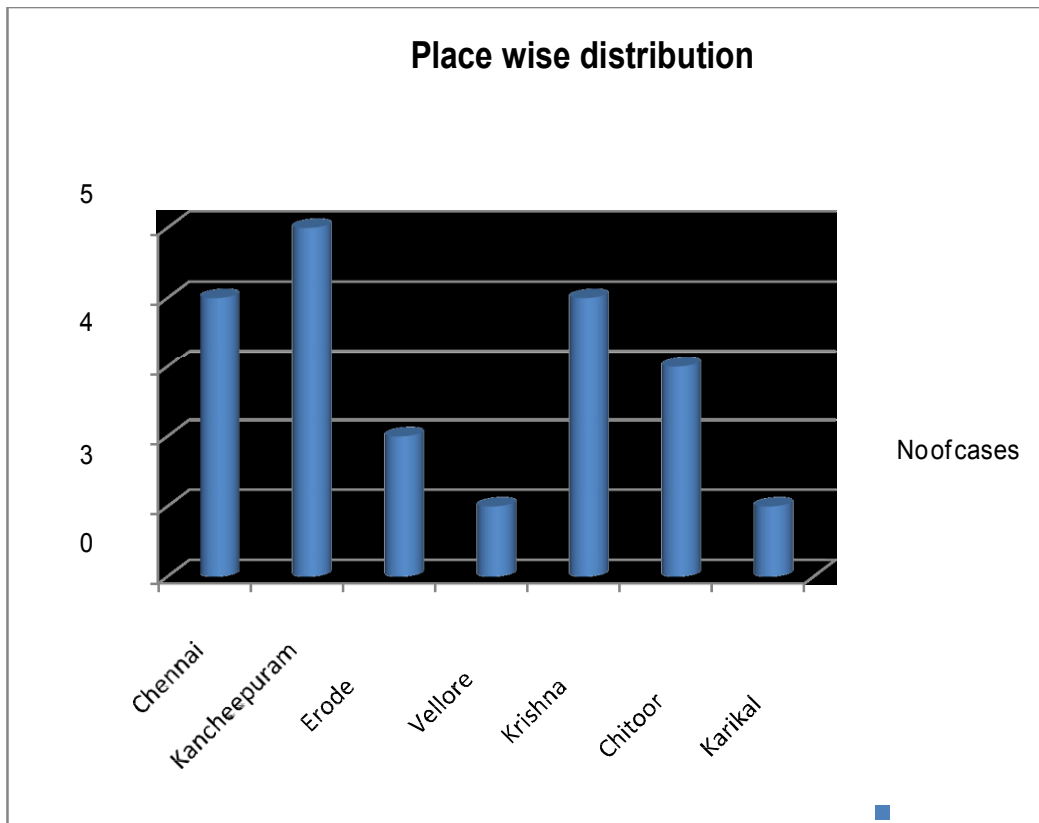
Distribution of the patients - State wise

State	No of cases
Tamilnadu	12
1) Pondichery	6
2) Andrapradesh	2
Total	20



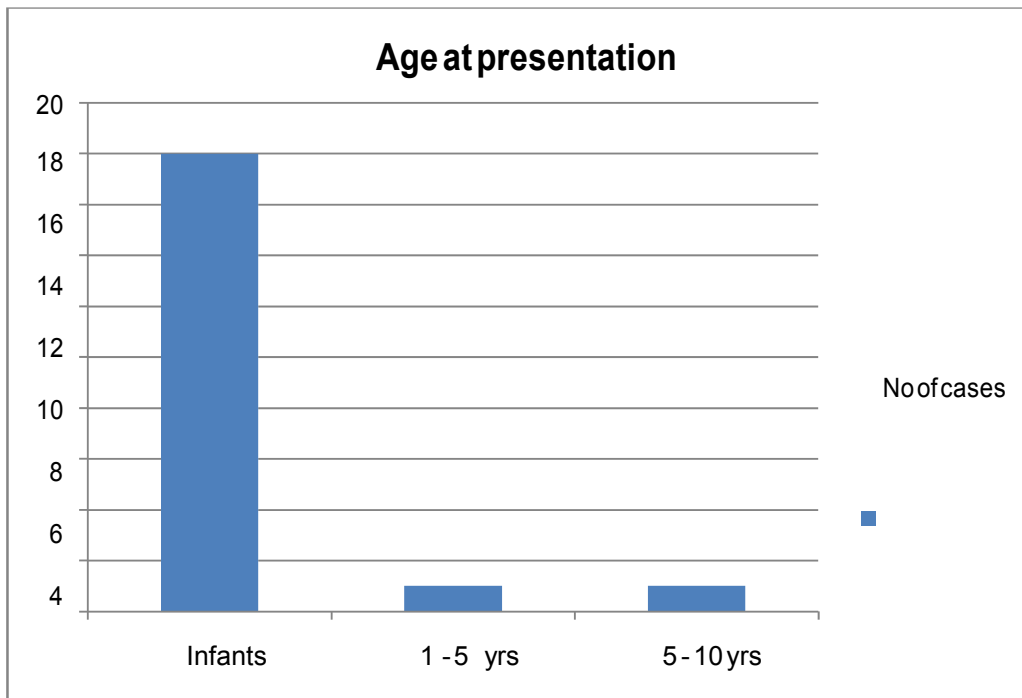
Distribution of patients – District wise

District	No of cases	
Chennai		4
Kancheepuram		5
Erode		2
Vellore		1
Krishna		4
Chittoor		3
Karikal		1
Total		20



Age distribution in numbers

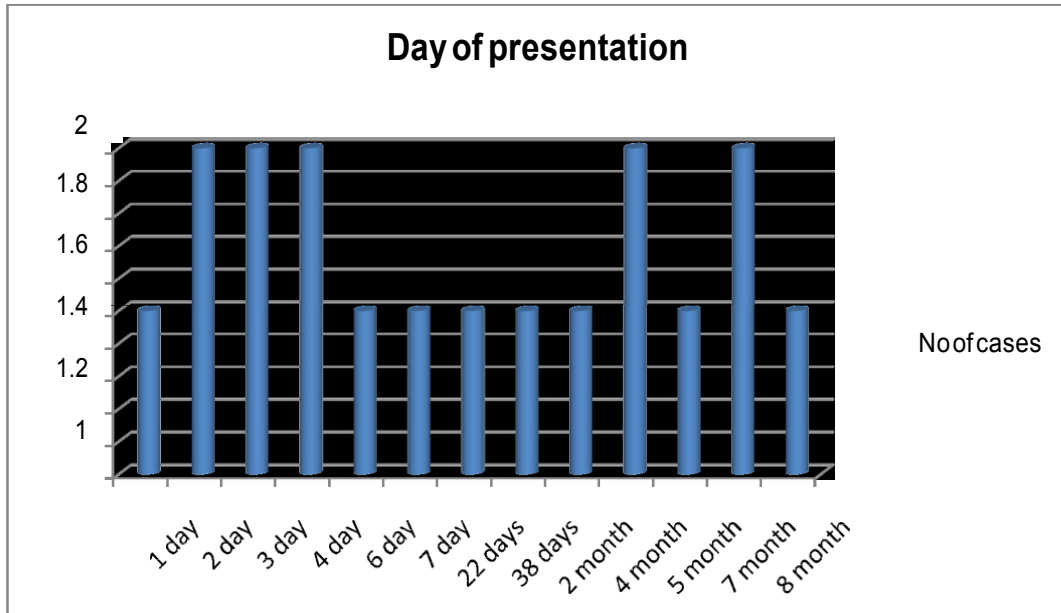
Age	No of cases
Infants	18
1 - 5 yrs	1
5 - 10 y	1
Total	20



Maximum number of cases are less than 1 year. In our study 18 cases are seen in less than one year of age.

Days of age at presentation

Infants	No of cases
1 day	1
3) 2 day	2
4) 3 day	2
5) 7 day	1
6) 38 days	1
7) 6 day	1
8) 22 days	1
Total	2 month 1
	5 month 1
	8 month 1

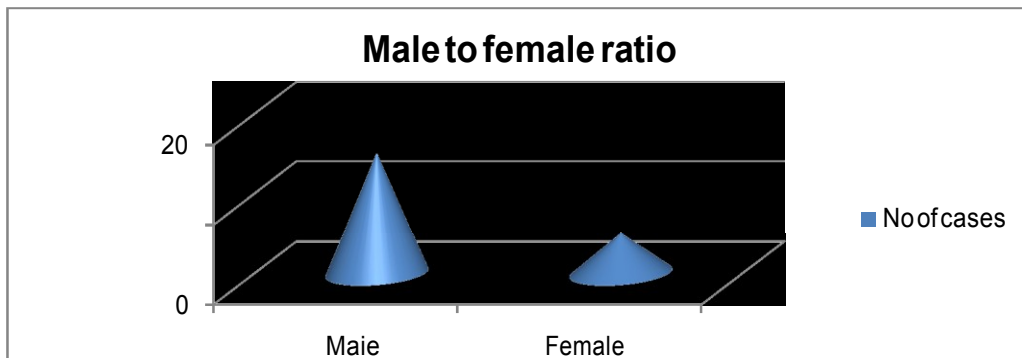


Among the cases presented less than 1 year ,most of them presented between first day of birth to within 7 months



9) Sex distribution (in Nos)


Sex	No of cases
Male	15
Female	5
Total	20



Maximum number of cases, 15 cases are male patients

10) Distribution of Ante-natal scan status

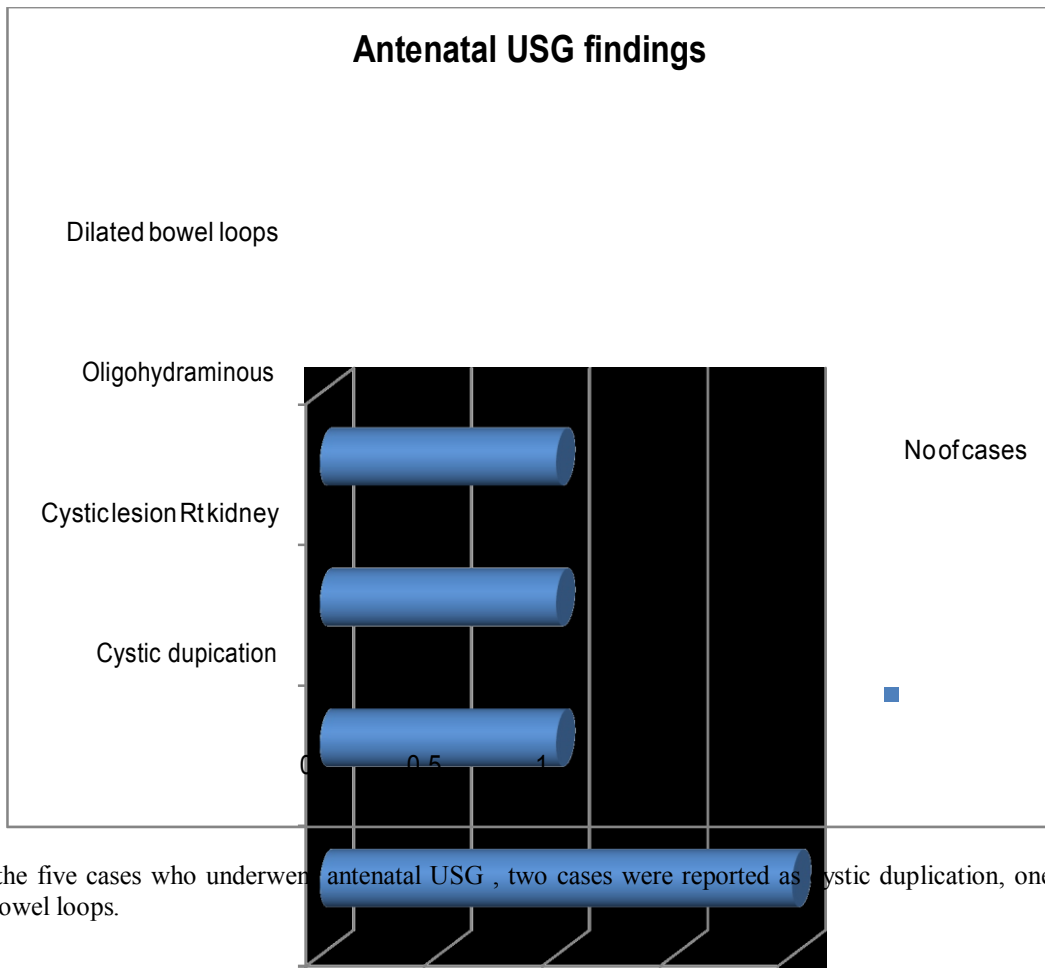
Antetatal USG cases	No of cases
Done	5
11) <i>Not done</i>	15
TOTAL	20



Antenatal scan findings

Among the antenatal USG Diagnosed

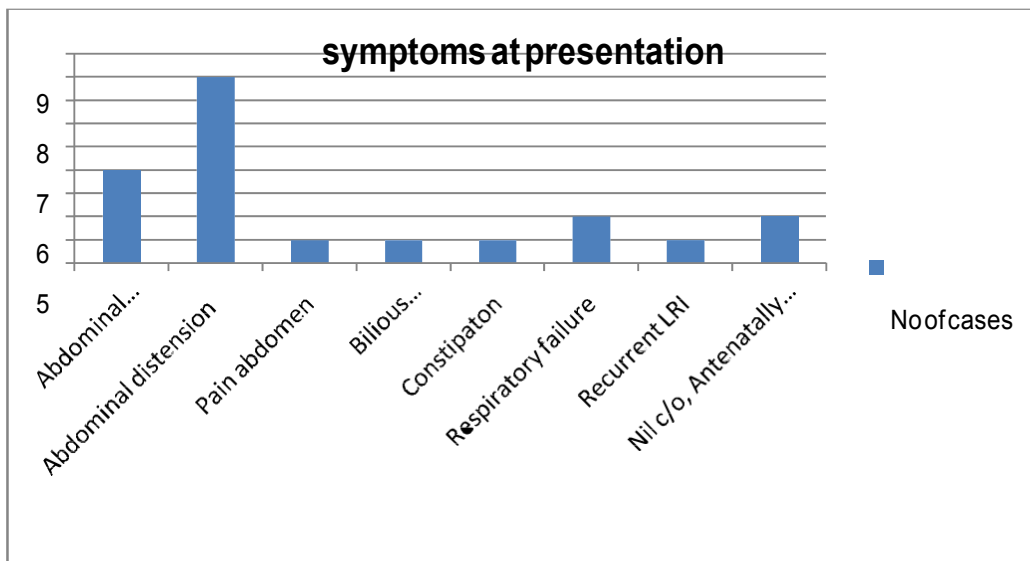
Diagnosed	No of cases
Cystic duplication	2
12) Cystic lesion Rt kidney	1
13) kidney	
14) Dilated bowel loops	1
15) Oligohydraminous	1
Total	5



Among the five cases who underwent antenatal USG , two cases were reported as cystic duplication, one case had dilated bowel loops.

16) Symptoms at presentation

Symptoms	No of cases
Abdominal distension, bilious vomiting	4
Abdominal distension	8
Pain abdomen	1
Bilious vomiting, constipation	1
Constipation	1
Respiratory failure	2
Recurrent LRI	1
Nil c/o, Antenatally diagnosed	2
Total	20

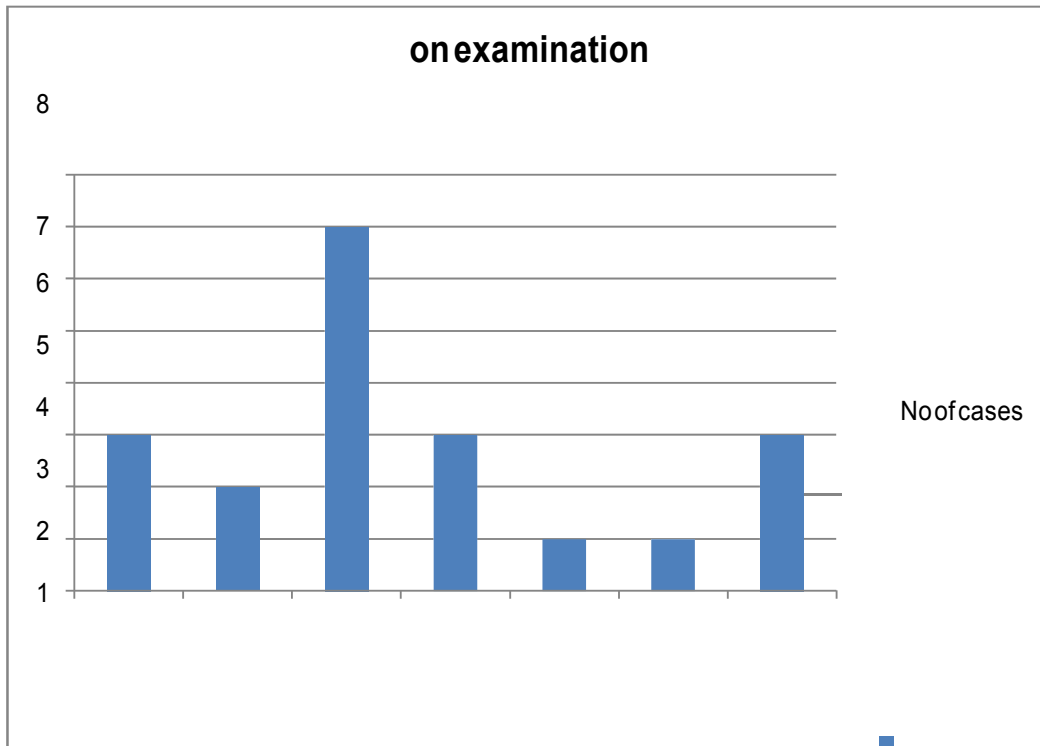


The most commonest presentation is the abdominal distension.

Eight cases presented only with abdominal distension.

17) Clinical examination findings

On examination	No of cases
Distension	3
18) Dilated bowel	2
19) loops	
20) P/A:Mass	7
21) a	
22) P/R: Mass felt	1
23) c	
Total	30
Clinically normal	3

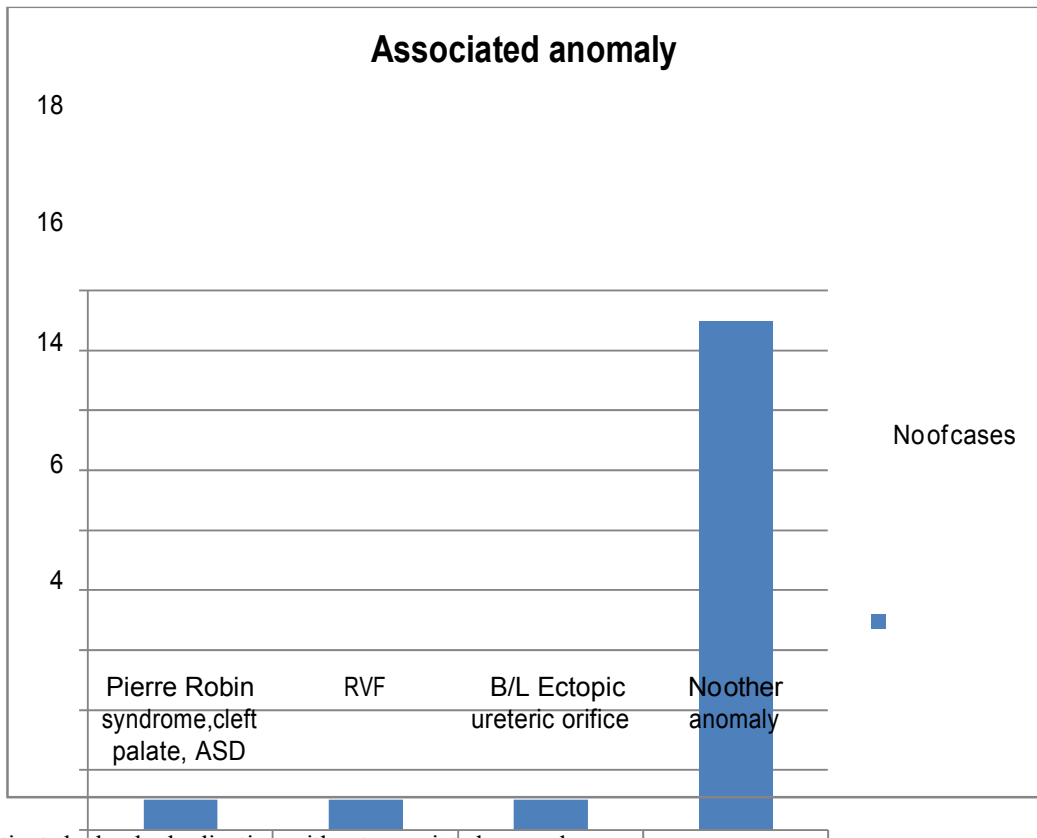


On examination of the abdomen the commonest finding is the mass felt in the right illac fossa. Seven cases had palpable mass

Distension
 Dilated bowel loops
 P/A: Mass palpable
 Respiratory distress
 P/R: Mass felt
 Two anal opening
 Clinically normal

24) Associated anomaly in distribution in Nos

Associated anomaly	No of cases
Pierre Robin syndrome, cleft palate, ASD	1
RVF	1
No other anomaly	15
B/L Ectopic ureteric orifice	1
Total	18

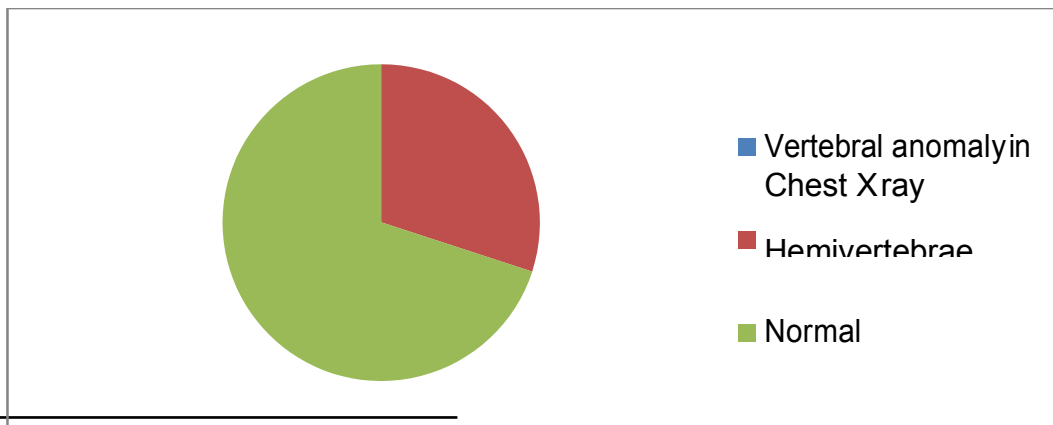


Many patients had only duplication without associated anomaly

25) Vertebral anomaly distribution in Nos

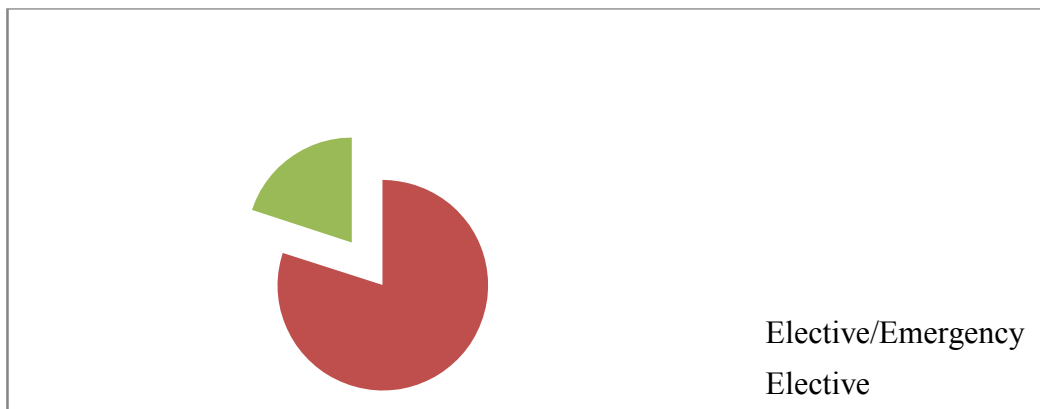
Vertebral anomaly in No of cases
Chest X ray

Hemivertebrae	6
Normal	14
Total	20



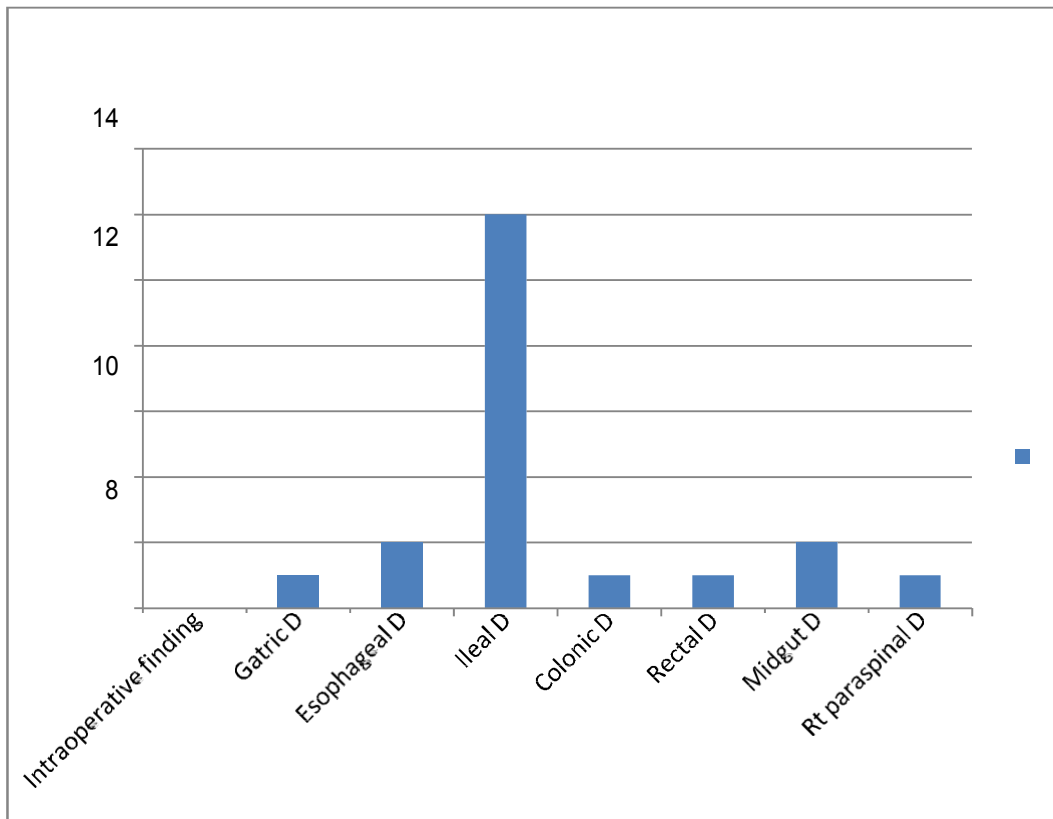
26) Elective/Emergency cases Elective/Emergency No of cases

Elective	16
Emergency	4
Total	20



Intraoperative findings

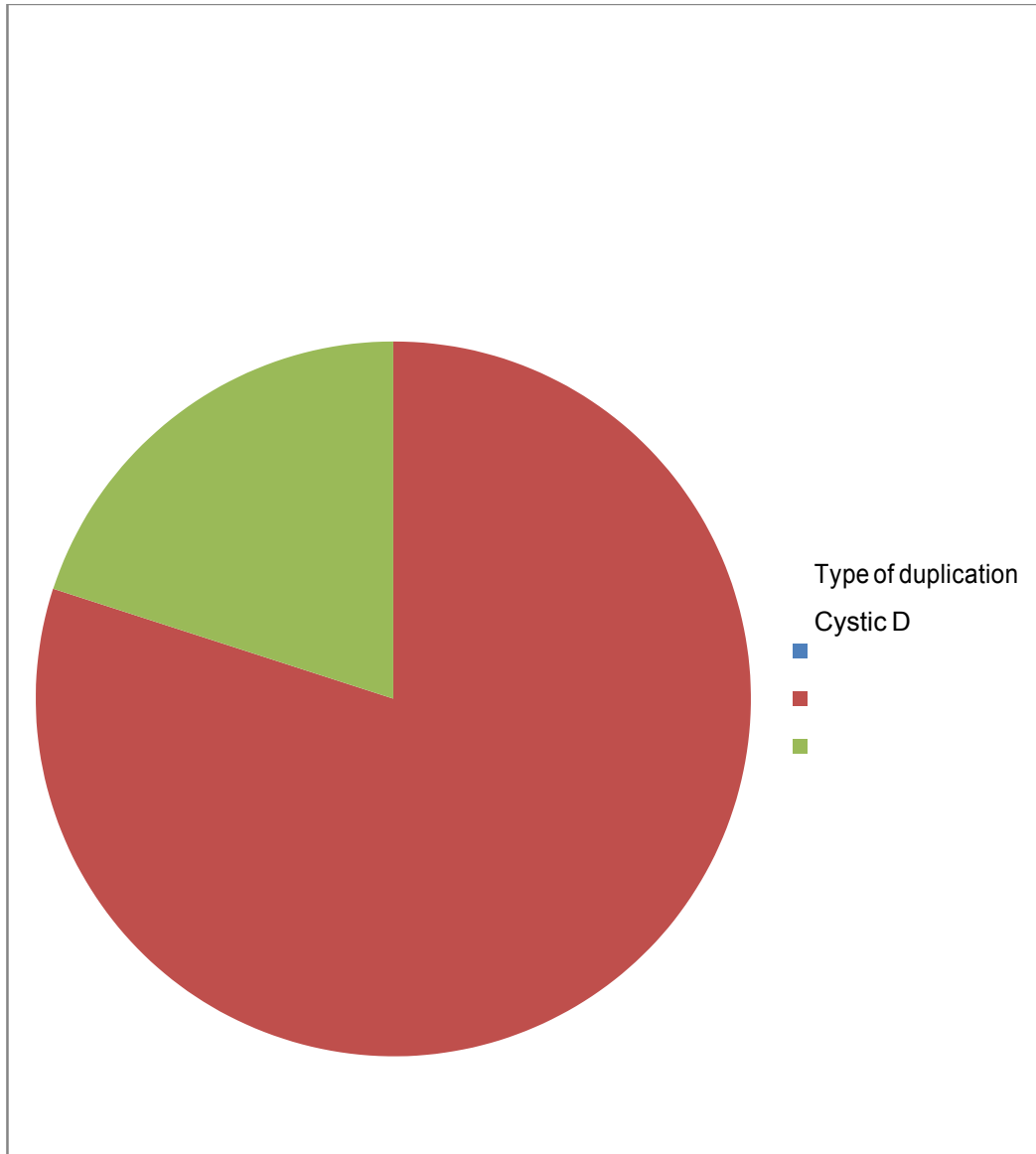
Intraoperative finding	No of cases
Gatric D	1
Esophageal D	2
Ileal D	12
Colonic D	1
Rectal D	1
Midgut D	2
Rt paraspinal D	1
Total	20



The commonest intraoperative finding is the ileal duplication, 12 cases had only ileal duplication.

27) Type of duplication distribution in Nos

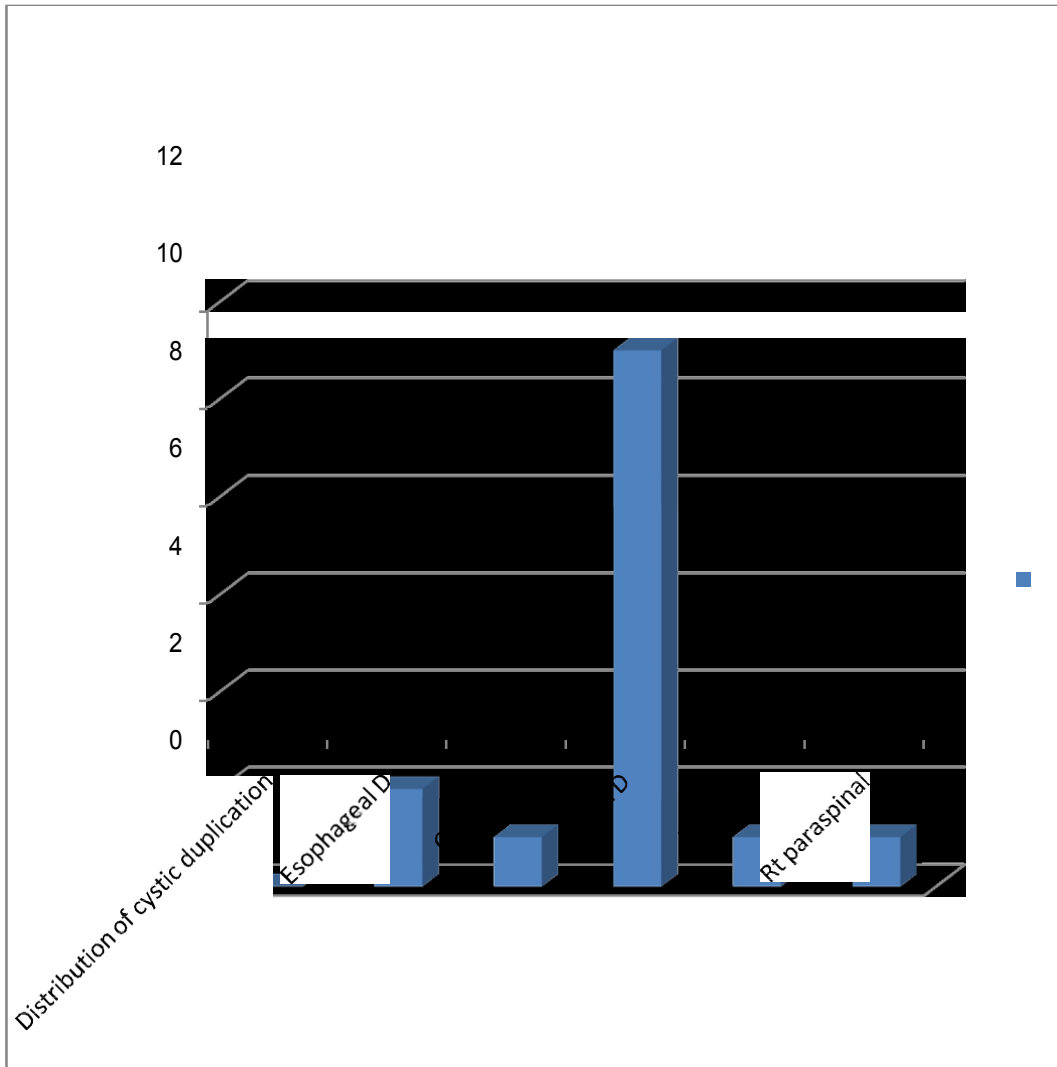
Type of duplication	No of cases
Cystic D	16
Tubular D	4
Total	20



Distribution of cystic duplication in Nos

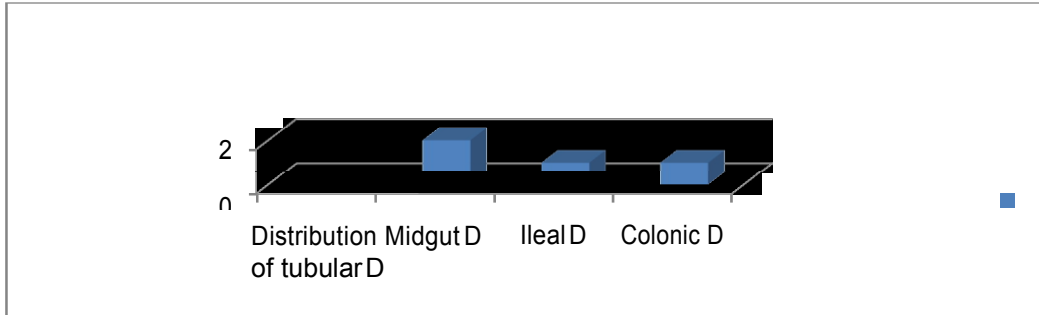
Distribution of cystic duplication

Distribution of cystic duplication	No of cases
Esophageal D	2
Gastric D	1
Ileal D	11
Rectal D	1
Rt paraspinal	1
Total	16



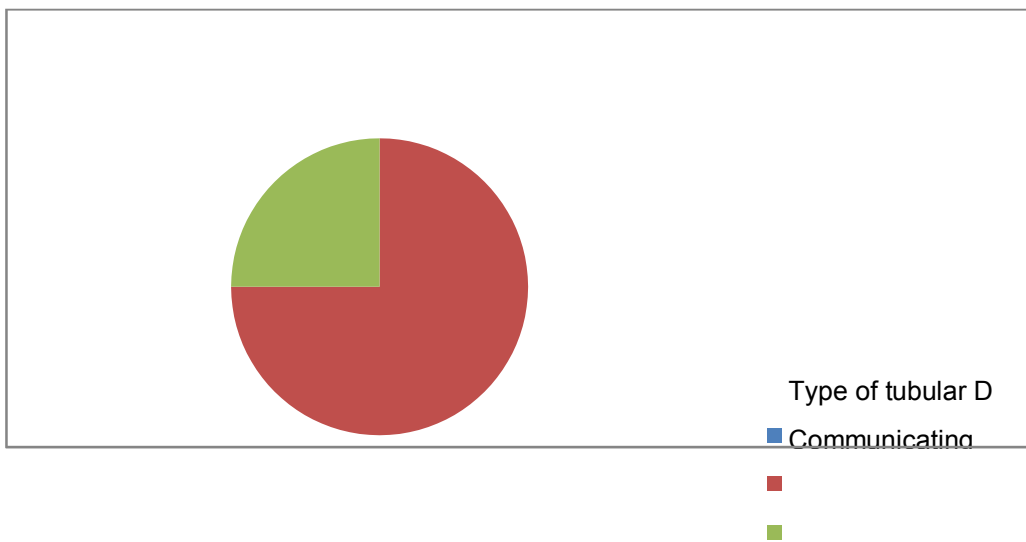
Distribution of tubular duplication

Distribution of tubular D	No of cases
Midgut D	2
Ileal D	1
Total Colonic D	1



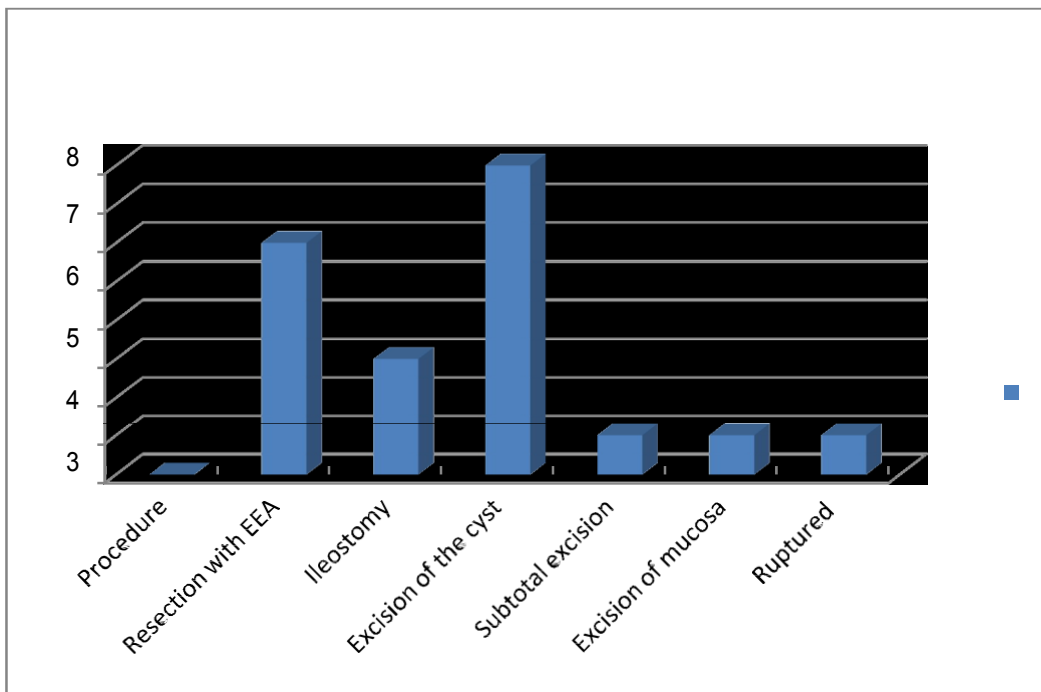
Type of tubular duplication

Type of tubular D	No of cases
Communicating	3
Non-communicating	1
Total	4



Type of Surgery

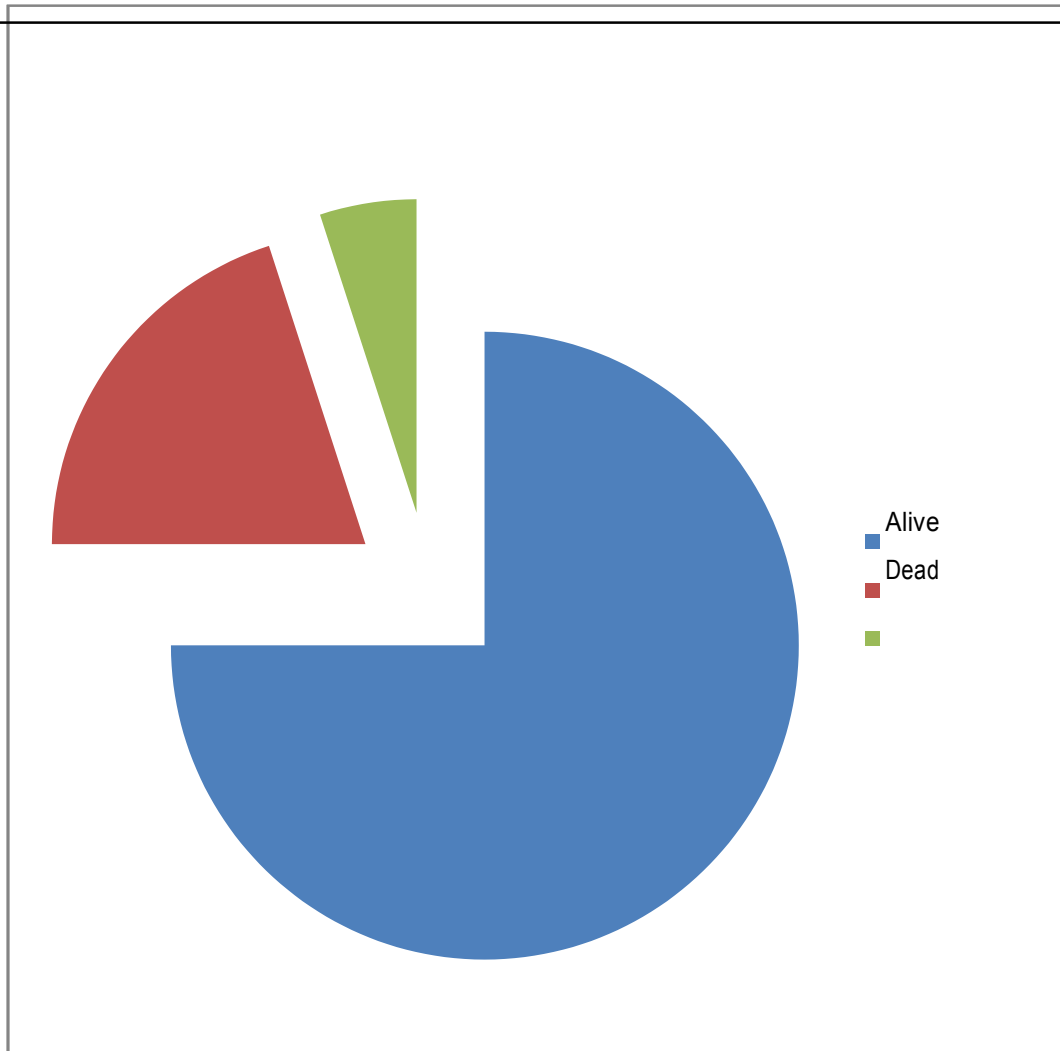
Procedure	No of cases
Resection with EEA	6
Ileostomy	3
Excision of the cyst	8
Subtotal excision of mucosa	1
Excision of mucosa	1
Ruptured	1
Total	20



Among the operative procedure eight cases underwent excision of the cyst followed by six cases underwent resection of the duplication and end to end anastomosis

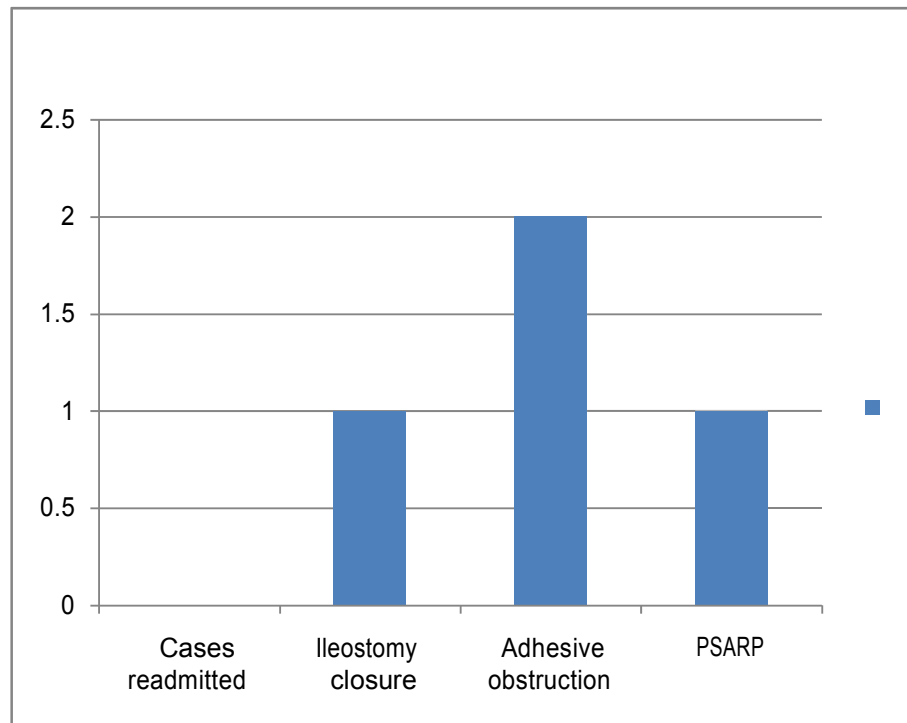
Follow up of patients

Alive	15
Dead	4
Lost follow up	1
Total	20



28) Cause for readmission

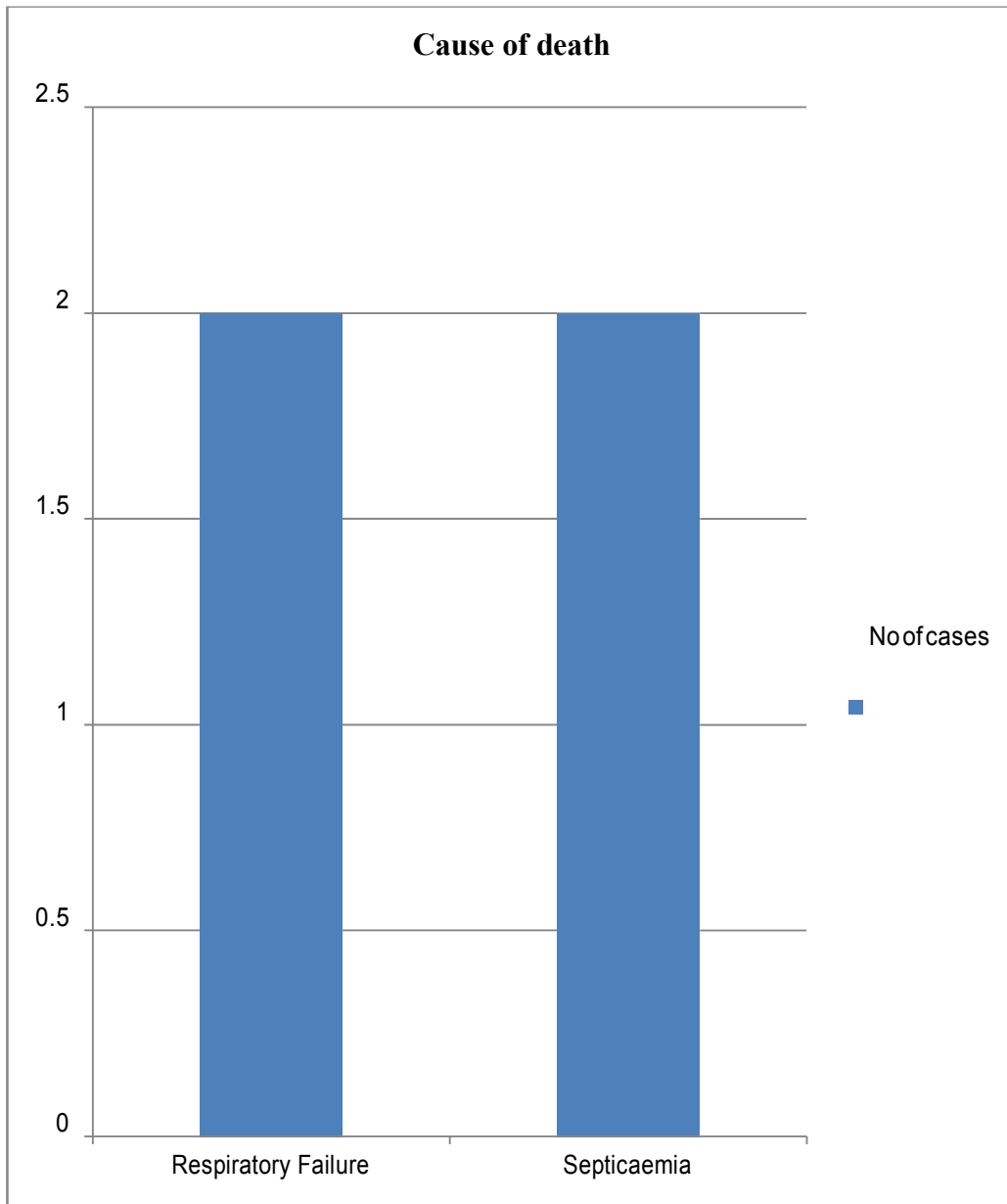
Cases readmitted of cases	No
Ileostomy closure	1
Adhesive obstruction	2
Total	1



Two cases readmitted with features of adhesive obstruction. One case managed conservatively , other case had laproscopic adhesiolysis.

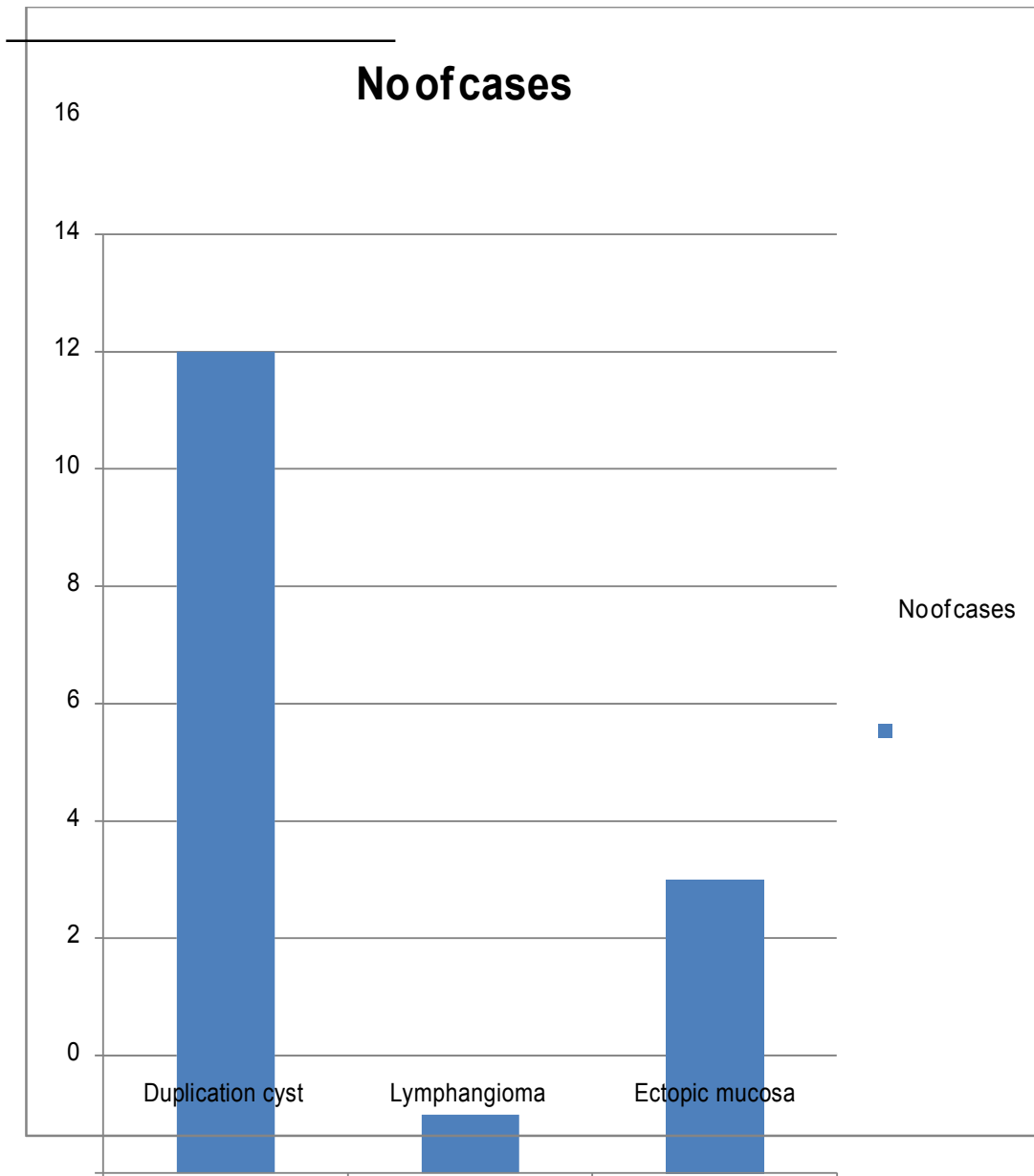
29) Cause of death

Cause of death	No of cases
Respiratory Failure	2
Septicaemia	2
Total	4



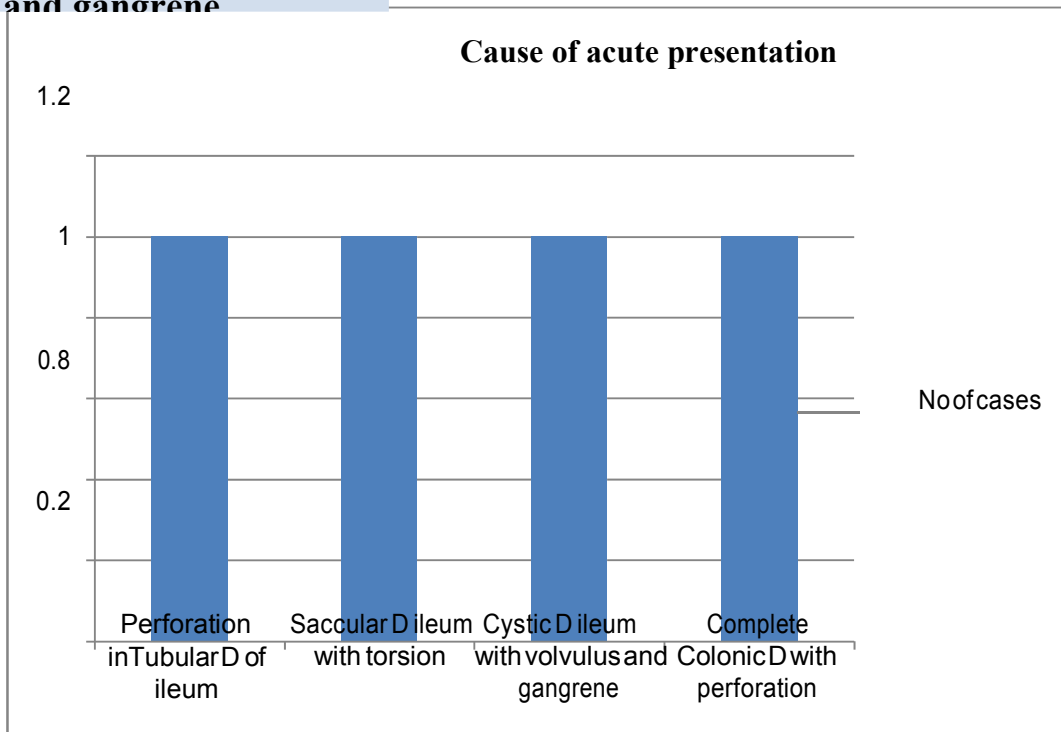
HPE report

HPE report	No of cases
Duplication cyst	14
Lymphangioma	1
Ectopic mucosa	5
Total	20



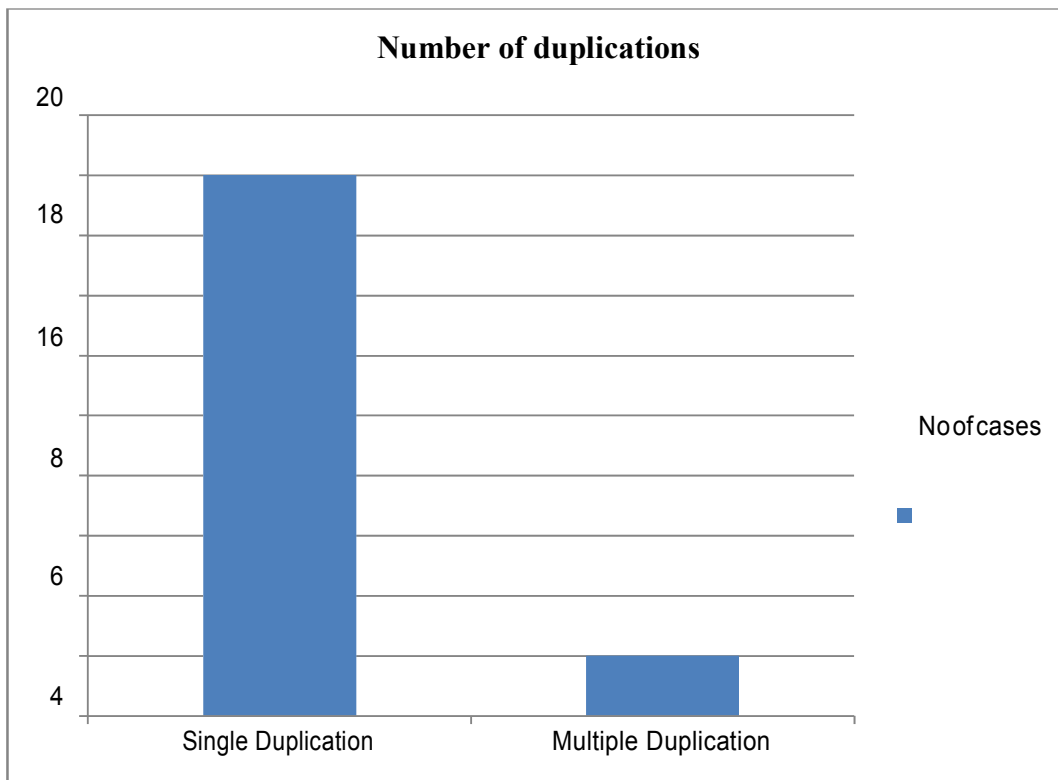
Cause of acute presentation (Emergency)

Cause of acute presentation	No of cases
Perforation in Tubular D of ileum	1
30) Saccular D	1
31) ileum with torsion	1
32) Complete Colonic D with perforation	1
Cystic D ileum with volvulus and gangrene	1



Number of duplication

No of Duplication	No of cases
Single Duplication	18
Multiple Duplication	2
Total	20



Eighteen cases had only single duplication

Discussion:-

During the period from August 2010 to February 2013 a total of 20 cases presented to the Department of paediatric surgery, ICH & HC, MMC, CHENNAI. who fulfilled the criteria of Gastrointestinal duplication were taken into study.

33) *The age and sex distribution*

In our study out of the 20 cases, 15 cases are male children (75%) and 5 cases are female children (25%). Many of the cases presented from within one day of life to 7 months and the oldest child was 8 years. This study was compared to the study conducted by Hacettepe university, Department of Pediatric Surgery, Ankara, Turkey by Karnak I, found 53% are male children and 69% presented within the age of 1 year²⁷.

34) *Antenatal scan*

Five cases had antenatal scan, out of that two cases was diagnosed possibility of gastrointestinal duplication. Karnak I in his study found that 70% - 80% of the cases are detected antenatally and out of that 30% will need emergency surgery²⁷. Puligandala diagnosed 31% of the duplication antenatally²⁶.

Mode of presentation and clinical examination

The commonest presentation observed is abdominal distension (40%) Two cases with respiratory failure and two cases with constipation noted. The commonest clinical finding is a mass palpable in the right iliac fossa and one case had two anal opening.

Karnak I in his study found that the mode of presentation depends upon the anatomic location of the cyst, pressure effect, complications like presence of ectopic gastric mucosa, torsion of duplication²⁷. Karnak I observed the most commonest presentation abdominal mass, abdominal distension constipation, respiratory distress and in 33% he felt the mass clinically²⁷.

Location, type of duplication and surgical procedure

The commonest site of duplication observed is ileum (55%) and cystic type of duplication is predominant (80%). 50% of the tubular duplication noticed in the midgut and 75% were communicating. Only two cases had multiple duplication (10%).

Four cases had emergency surgery out of the four cases two cases had perforation in the duplication and two had torsion with gangrene of the duplication. Karnak I observed 70% of the duplication observed in the ileum, 79% are cystic duplication, 21% are tubular duplication and 5.3% had multiple duplication²⁷. H.K. Ramakrishna in his study found that most of the duplication are in ileum, 74% are cystic duplication and 26% are tubular duplication²³.

Excision of the duplication done in 8 cases(40%), resection of the duplication and end to end anastomosis done in 6 cases(30%) and excision of the mucosa done in one case. Karnak I observed many of the cases had excision of the duplication(53%)²⁷. Li et al has done excision of the duplication without resection in 14 cases (6 – tubular,8cystic)²⁸.

Associated anomaly

Six cases had hemivertebrae(30%), one case had rectovestibular fistula with complete colonic duplication. Karnak I observed hemivertebrae in 26% of the cases²⁷. Blickman in his study found that association of colonic duplication with rectovestibular fistula²⁹.

Cause of acute presentation

Two cases had volvulus and two cases had perforation. Puliganda PS in his study found that volvulus was noticed in 26.3% of the duplication and 20% had perforation of the gastrointestinal duplication²⁶. None of our patients had intussusception and lower gastrointestinal bleeding.

Cause of death

Two cases had respiratory failure and two cases had septicaemia followed by death. Karnak I observed six cases died of unrelated cause²⁷. Cases presented with respiratory distress due to the duplication cyst in the thoracic cavity carries a poor prognosis.

Histopathological finding

In our series 5 patients had heterotopic mucosa. One case was reported as lymphangioma and the others reported as duplication cyst. Karnak I diagnosed 33% had heterotopic gastric mucosa²⁷.

Conclusion:-

1. A good antenatal ultrasound can pick up gastrointestinal duplication, requiring further evaluation and elective surgery
2. Incidentally noted gastrointestinal duplication should be operated electively to avoid complications like bleeding and perforation from the ectopic gastric mucosa.
3. Most of the gastrointestinal duplication will present within 1 year of age
4. Gastrointestinal duplication is more common in males
5. Ileum is the most commonest site for gastrointestinal duplication
6. Cystic and communicating type of gastrointestinal duplication are most common types of duplication

7. Complete excision of the duplication should be aim of the surgery.
8. The identification of vascular pattern (type I/II) helps in removing the duplication without injuring the native bowel.
9. Thoracic duplication presenting with respiratory distress carries poor prognosis.