



Journal Homepage: - www.journalijar.com

INTERNATIONAL JOURNAL OF ADVANCED RESEARCH (IJAR)

Article DOI: 10.21474/IJAR01/12977

DOI URL: <http://dx.doi.org/10.21474/IJAR01/12977>



RESEARCH ARTICLE

LIMITED URETHRAL MOBILIZATION PROCEDURE (LUMP) FOR DISTAL PENILE HYPOSPADIAS REPAIR, A SINGLE CENTRE RETROSPECTIVE ANALYSIS

Muhammad Riaz-ul-Haq¹, Arslan Raza Wasati², Mazhar Rafi³, Sohail Jamil⁴, Binish Naeem⁵ and Yasir Sultan⁶

1. Muhammad Riaz-ul-Haq, Associate Professor Paed. Surgery, AIMC and Jinnah Hospital Lahore.
2. Arslan Raza Wasati, FCPS, HOD, Paed. Surgery, AIMC and Jinnah Hospital Lahore.
3. Mazhar Rafi, Professor of Paed.Surgery, Sheikh Zayed Medical College Rahim Yar Khan.
4. Sohail Jamil, SR Paed.Surgery Jinnah Hospital Lahore. Mob: 03370407638
5. Binish Naeem, PGR, Paed.Surgery, Jinnah Hospital Lahore.
6. Yasir Sultan, PGR, Paed.Surgery, Jinnah Hospital Lahore.

Manuscript Info

Manuscript History

Received: 31 March 2021
Final Accepted: 30 April 2021
Published: May 2021

Key words:-

Distal hypospadias, Limited urethral mobilization, Urethrocutaneous fistula, Outcome

Abstract

Background: Distal penile hypospadias is one of the commonest varieties of hypospadias. Different techniques have been mentioned in literature. The success rate is usually assessed by rate of fistula formation and over all cosmetic appearance and functional outcome. Limited Urethral Mobilization Procedure (LUMP) for distal penile hypospadias is considered a good technique with almost zero fistula rate in some series. As no new urethral tube is constructed there is no risk of fistula.

Objective: To evaluate the results of the Limited Urethral Mobilization Procedure (LUMP) for distal hypospadias repair.

Methods. It is retrospective analysis of 32 patients aged up to 12 years who were treated with Limited urethral mobilization procedure for distal penile hypospadias in the Department of Paediatric Surgery Jinnah Hospital Lahore from December 2018 to November 2019. All patients were operated under general anesthesia. The urethra proximal to the meatus was mobilized adequately in such a way that it should reach the tip of glans easily without any ventral bending of penis. Then the urethra was placed in the glandular wings and reconstruction of glans was carried out. Dartos flap was also placed to cover the urethra as a safety measure to avoid urethrocutaneous fistula formation. Follow up was done for a period of 3 months with respect to fistula formation, meatal stenosis, retraction, chordee and over all cosmetic appearance.

Results: Age range of children was 9 months to 12 years. Operation time ranged from 60-80 minutes. Seven of 32 cases were previously operated for distal penile hypospadias but after disruption of repair meatus was lying at coronal or subcoronal level. They also underwent LUMP. Five cases had minor chordee, it was corrected at the time of urethral mobilization by simple excision of fibrous tissue in 4 patients while modified Nesbit dorsal placcation was done in one. Cosmetically normal looking circumcised penis with slit like meatus was achieved in all. Two cases got superficial wound infection, two had meatal stenosis,

Corresponding Author:- Muhammad Riaz-ul-Haq

Address:- Muhammad Riaz-ul-Haq, Associate Professor Paed. Surgery, AIMC and Jinnah Hospital Lahore.

one meatal retraction, one ventral chordee and one urethrocutaneous fistula.

Conclusion: LUMP for distal penile hypospadias is a simple and effective procedure with minimum complications. There is no chance for development of urethrocutaneous fistula, a major postoperative complication of other surgical techniques for urethroplasty. Postoperative management is simple and hospital stay is short.

Copy Right, IJAR, 2021.. All rights reserved.

Introduction:-

Hypospadias by definition is an abnormal development of the urethral spongiosum and ventral prepuce along with an abnormal penile curvature due to arrest in the normal embryological process which gives penis a normal curvature and fuses the urethral plates into normal urethra [1]. It is one of the most common congenital anomalies, which occurs in approximately 1 of 200 to 1 of 300 live births [2]. Distal hypospadias is one of the most common varieties of hypospadias, and occurs in almost 65% of all hypospadias cases. Distal hypospadias includes glandular, coronal, and subcoronal. Classification of distal hypospadias is based on meatal position. Glandular is distal to corona and coronal hypospadias is on the coronal sulcus while subcoronal is up to 3–4mm proximal to the coronal sulcus [2]. The main objectives in hypospadias surgery are penile straightening (orthoplasty), urethroplasty, meatoplasty, glanduloplasty, scrotoplasty and skin coverage. A number of techniques have been devised to achieve these goals [3]. In spite of the advancement in surgical techniques and various procedures for hypospadias repair, urethrocutaneous fistula is the most common complication throughout the world despite expert hands, the reported incidence being as high as 5-15% [4]. Rate of urethrocutaneous fistula is important in a sense because it is used to evaluate the success of hypospadias repair. The major objective of hypospadias surgery with various techniques is to achieve excellent cosmetic and functional results without complications. Urine stream should be straight from tip of penis and penis should look straight with normal appearance [5]. Urethral advancement for urethroplasty was first introduced in 1898 by Beck [6]. They undermined and mobilized the urethra and advanced it into the glans. Glans was not incised rather tunneling of the glans was done with the help of a trocar-like instrument. This procedure is based on the amenability of the urethra for mobilization and advancement to the tip of the glans [7]. Initially this procedure was not that successful due to resultant chordee, most probably due to limited mobilization of urethra [8]. Urethra is elastic and has good blood supply and many studies show that it may be safely mobilized in hypospadias repair [9]. The extent of mobilization varies and depends on type of hypospadias. In some cases minimal distal mobilization is needed while in others more extensive dissection down to the bulbar urethra [8]. Urethral mobilization and meatal advancement with many modifications was found to be a safe procedure in distal hypospadias repair [10].

The aim of the study was to evaluate results of urethral advancement in the repair of distal penile hypospadias without or with minor chordee with regard to feasibility, complication rate, and the final cosmetic appearance. We present our experience with limited urethral mobilization with coverage of dartos fascia for distal hypospadias repair with the hypothesis that native urethra without any tubularization would minimize complications such as urethrocutaneous fistula which is a hallmark of success in hypospadias surgery.

Materials and Methods:-

It is a retrospective single centre study which was carried out in the Department of Paediatric Surgery Jinnah Hospital Lahore between December 2018 and November 2019. 40 patients of hypospadias were dealt in total. 32 patients under 12 years but above 6 months of age with distal penile hypospadias (Glandular, Coronal and Subcoronal) with no or mild chordee ($< 30^\circ$) were included in this study and underwent Limited Urethral Mobilization Procedure (LUMP). 27 cases were new while 5 cases included were previously operated but their meatus was lying at coronal or subcoronal level due to failed repair. Children with mid penile or proximal hypospadias, severe chordee and crippled were excluded from the study. Informed consent was taken from all patient's parents/guardians. Age of patients, location of meatus, presence of chordee, duration of surgery, period of follow up, per-operative and post operative early and late complications were recorded.

Procedure:

All of the operations were carried out under general anesthesia. A 3/0 prolene suture was placed at the tip of the glans penis for traction. The distance between the tip of glans and urethral meatus was measured and recorded. A urethral catheter 6 to 10 Fr according to age of the patient was inserted into the urinary bladder. Catheter used was preferably a feeding tube. A circumcising incision with U shaped ventral extension proximal to the hypospadias meatus (meatal based) was carried out. This U shaped flap meatal based flap was used to give traction to the ventral aspect of meatus and urethra. The penile skin was degloved down to the penoscrotal area, and any skin or subcutaneous chordee was released. The meatus was circumscribed with a small dorsal skin flap to be used for traction of dorsal aspect of urethra and the urethra proximal to the meatus was mobilized circumferentially adequately for a distance that was sufficient to allow the urethra to reach the tip of the glans without any tension (figure 3) , after trimming the distal urethra in an oblique fashion. The length of the mobilized urethral tube was measured and recorded. The ventral aspect of glans penis was incised deeply into the corpora cavernosa. Excessive mucosa was excised on both sides and the glans wings were shaped and mobilized laterally. The glandular bed was prepared and then the mobilized urethra was placed in it (figure 4). The dorsal lip of the urethra was sutured to the glans tip with interrupted 5/0 vicryl sutures. Glans wings were wrapped around the urethra as in the normal configuration and sutured with 2 layers of interrupted 5/0 vicryl sutures. The deeper layer secured the urethra to the glandular tissue and the superficial layer approximated the glans wings. The anterior lip of the urethra was secured to the glans with interrupted sutures. A few 5/0 polyglactin interrupted sutures were applied through the tunica albuginea of corpus spongiosum to the corpora cavernosa. Dartos flap was dissected from the prepuce , rotated on ventral surface of penis and nude urethra proximal to glans was covered not to leave any chance of fistula formation (figure 5). The penile tourniquet was used during surgery for maximum 30 minutes continuously and if needed later, was applied intermittently. It was removed after glans approximation was achieved. Circumcision was done in all patients. A compression dressing was applied. The catheter was secured with a prolene suture which was applied for glans traction. Catheter remained in place in the urinary bladder for 7 days. Usually on 7th post-operative day the urinary catheter was removed and the patient was discharged after passing urine. All patients received broad spectrum intravenous antibiotics and continued for 5 days. Patients were advised sitz bath and local antibiotic ointment at the time of discharge. On 15th post-operative day, urethral calibration was performed with 6-10 Fr stent according to the age of the children. Patients were called for office visits after 2 weeks, 1 month of operation and then 3 monthly or they were advised to visit any time if any complication occurred to evaluate the cosmetic appearance and functional outcome. Cosmetic results were evaluated with a slit-like meatus at the tip of the glans , conical shaped glans and absence of chordee, while function was assessed with a good caliber, single and straight stream of urine.

Statistical analysis was performed using SPSS Version 20. Quantitative data was shown as mean \pm standard deviation. Student t test was performed and bias was set at $p < 0.05$ with confidence rate of 95%. Author first time used the term LUMP for this technique.

Figure 1:- Coronal Hypospadias.

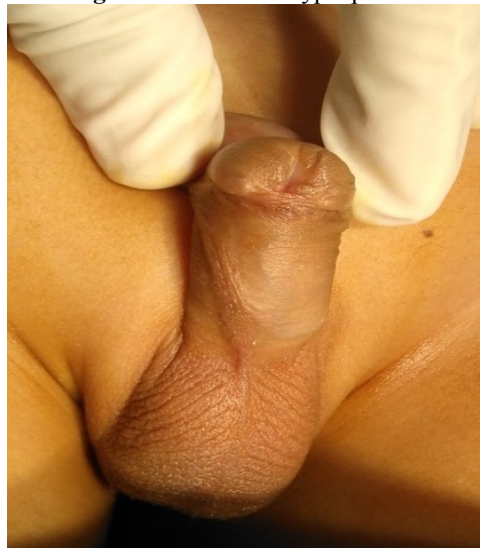

Figure 2:- Incision markings for LUMP.

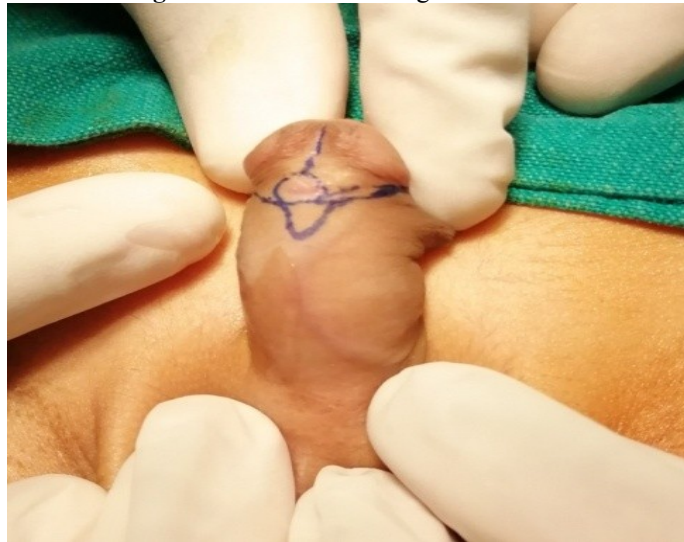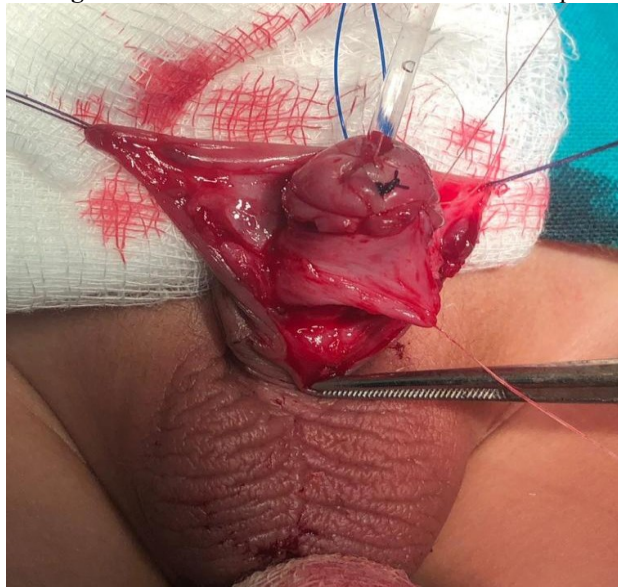


Figure 3:- Urethral Mobilization.

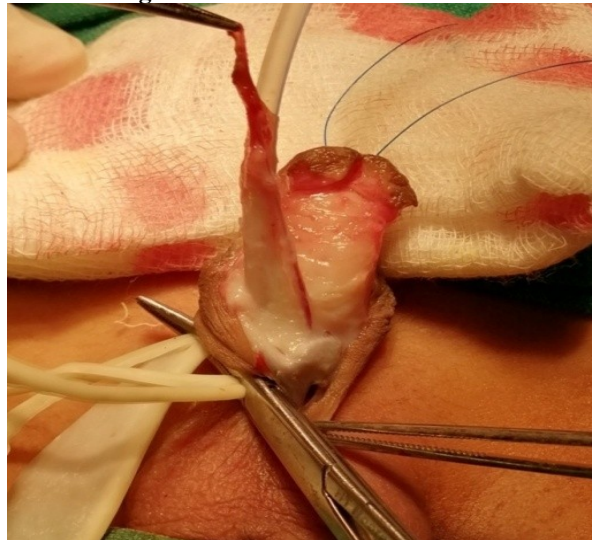

Figure 4:- Urethral meatus was fixed at tip of glans.

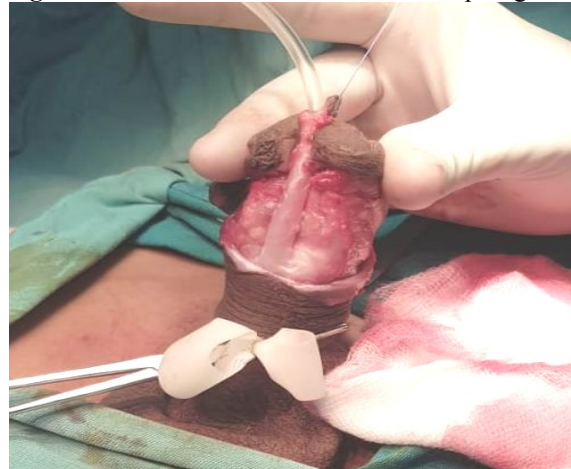

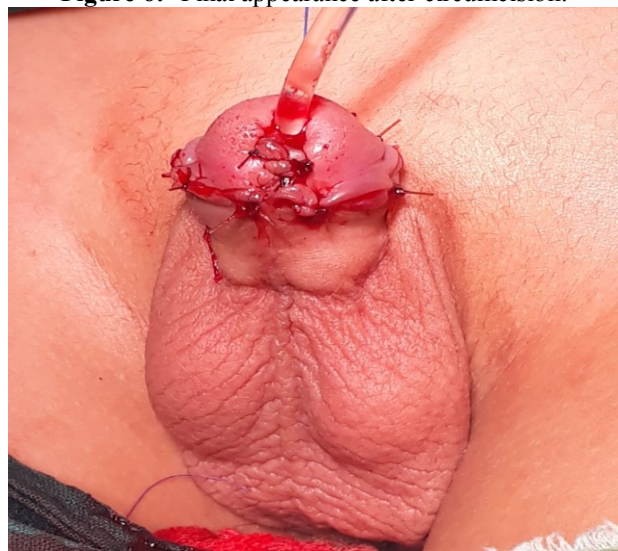Figure 5:- Urethra was covered with dartos flap.**Figure 6:-** Final appearance after circumcision.**Results:-**

Age range was 8 months to 12 years, mean 4.58 years. 3(32), 9.39% were less than 1 year while 16(50%) of our patients were >3-7 years, (figure 7). Regarding type of hypospadias, 15(46.87%) were subcoronal while only 3(9.37%) were glandular type of hypospadias, (table 1). 5 of 32 patients presented with mild chordee, 4(5) patients were managed with excision of fibrous tissue and 1(5) with dorsal placcation. 7 of our patients were previously operated for distal penile hypospadias with other procedures, they came to us with failed surgery. LUMP was done in all. The operative time ranged from 60 to 80 min, with a mean time of 71.5min. Distance between meatus and tip of glans ranged from 5mm to 12 mm, mean 8.08mm. In most of the patients 23(71.87%), distance between meatus and tip of glans ranged 6-10mm, (table 2). Length of urethral mobilization ranged from 9mm to 37mm, mean 22.28mm. 16(50%) patients needed >20mm mobilization of urethra, (table 2). Over all complications were 25%, 8(32). Only two patients needed redo surgery while others were managed conservatively with office based maneuvers (fig 8).

Figure 7:-
Age Groups n=32

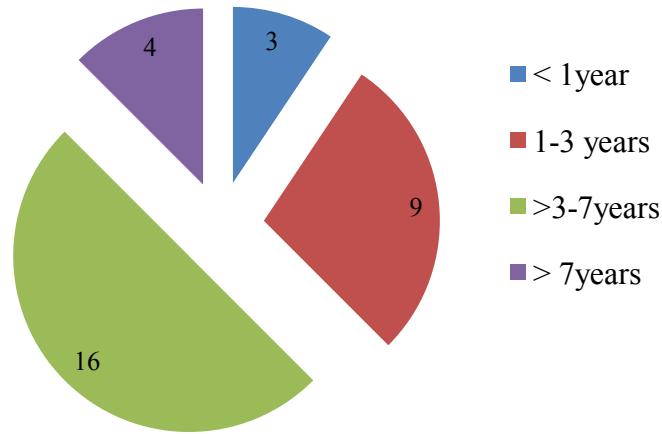


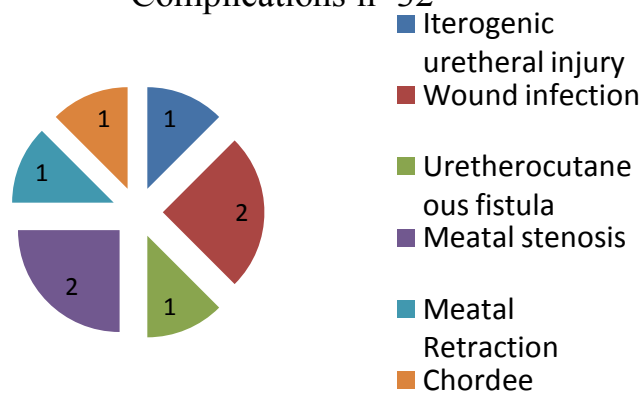
Table 1:- Type of hypospadias and other variables n=32.

Type	No	%age
Glandular	3	9.37%
Coronal	14	43.75%
Subcoronal	15	46.87%
With chordee	5	15.62%
Previously operated	7	21.87%

Table 2:- Distance between meatus and tip of glans and length of urethral mobilization n=32.

Distance between meatus and tip of glans		Length of urethral mobilization	
< 6mm	4 (12.5%)	<12mm	3 (9.37%)
6-10mm	23 (71.87%)	12-20mm	13 (40.62%)
>10-12mm	5 (15.62%)	>20mm	16(50%)

Figure 8:-
Complications n=32



Discussion:-

Around 100 years ago, Beck introduced advancement of distal urethra without mobilization of urethra adequately for correction of glandular hypospadias. Later on, Glassberg, Waterhouse, Belman, and Koff performed extensive mobilization of the urethral canal and corpus spongiosum [11]. Currently common procedures for distal penile hypospadias under practice are the MAGPI, the glans approximation procedure (GAP), the Mathieu, and the Snodgrass modification and urethral mobilization and advancement [12]. In our study, the age of our patients at operation ranged between 8 months and 12 years, with a mean 4.58 years. Ekinci et al [5] reported a mean age at surgery of 4.5 (range: 1–17) years. Our operative time ranged from 60 to 80 min, with a mean time of 71.5min, it is more or less similar to other authors [5].

Similar to many other case series, the patients with mild chordee, torsion, previously circumcised and previous unsuccessful surgery for hypospadias were included in our study. We used this technique in seven patients with complete or partial glanular dehiscence and meatal retraction and found very good cosmetic and function results. Elemen and Tugay performed same procedure for failed previous repairs in nine patients with very good results [3]. Some other authors reported acceptable results of secondary surgery with LUMP [14]. McGowan and Waterhouse mentioned that there is a fine network between the urethral branch of the internal pudendal and terminal branches of the dorsal penile vessels. This fine network of arteries play an important role in blood supply of urethra [15].

In our patients the distance between meatus and the tip of glans ranged from 5 to 12 mm, mean(8.08mm) and the mean length of mobilized urethra to achieve tension free anastomosis was 9mm to 37mm, mean 22.28mm. Almost same ratio (1.5-2.5cm) was reported by Elbatarny AM et al. [16]. Chakraborty AK mentioned that 2.7-3.2(3.1) fold urethral mobilization was adequate to secure anastomosis between urethra and glans without any fear of chordee [17]. In some series four to five fold mobilization of urethra is recommended to gain tension free anastomosis [8,18]. This much urethral mobilization may be required in midshaft and proximal hypospadias, such patients were not included in our study. In secondary reconstruction and patient with chordee require slightly more extensive mobilization. Hassan HS 2015, performed urethral mobilization to the proximal shaft in almost all cases of distal hypospadias with chordee [19]. Extensive urethral mobilization may compromise the blood supply and lead to ischemia and later on stricture formation. Whereas the inadequate urethral mobilization may result in chordee. However adequate and meticulous urethral mobilization is a gold standard in the success of this technique.

With regards to complications, urethrocutaneous fistula is very common complication of all sorts of hypospadias repairs. Karim S, reported urethrocutaneous fistula in 1.47% patients with LUMP and in 14.29% patients with modified Snodgrass repair [14]. High incidence of urethro cutaneous fistula with tubularized incised plate urethroplasty (TIP) has been reported in by many authors [20,21]. We faced only one case (3.12%) of urethrocutaneous fistula out of 32 patients who underwent LUMP. Hassan et al. [19] reported a series of 30 patient. They mentioned 2 cases (6%) of wound infection and were managed with antibiotics and daily dressing until infection settled down.. These results are very similar to our 2(6.25%) cases who developed superficial wound infection and were dealt with daily dressing. Awad Mohamed et al. [4] reported, among their 72 patients, one patient who developed a big fistula (1.3%) in which the urethra retracted back to its pre operative site due to wound infection followed by wound dehiscence. Four (5.5%) patients developed meatal stenosis and were managed by meatal dilatation twice weekly for 3 weeks with local anesthesia [4]. Ekinci et al. [5], among their 171 patients, reported 4 (2%) cases of meatal stenosis, 4 (2%) patients of fistula, 4 (2%) cases of meatal retraction and 4 (2%) cases of glandular dehiscence. Alkan et al. [2] reported 9(71) patients with different complications after urethral mobilization, three (4%) cases with a slightly glanular urethral meatus and six (8%) patients with a mildly poor stream during micturition, which responded to office based meatal dilatation. Our one (3.12%) patient got iatrogenic urethral injury which was repaired in the same sitting, one(3.12%) meatal retraction and another presented with chordee in follow up. As a whole 8(25%) developed complications, most of them were minor and were managed without another surgery. Shafiq-ur-Rehman et al. mentioned minor complications in their 187 patients [22].

Conclusion:-

Although many procedures have been mentioned in the literature for distal penile hypospadias but Limited Urethral Mobilization Procedure(LUMP) has minimum complications including uretherocutaneous fistula which is thought

to be a hallmark and gold standard in successful hypospadias surgery. The technique is simple, quick and very acceptable with respect to cosmetic and functional results in distal penile hypospadias.

Acknowledgement:-

Authors are thankful to the whole paediatric surgery team for assisting and facilitating in conducting this study.

Contribution of authors

MR designed the study, conducted the study, performed the surgeries, and wrote the manuscript.

ARW proofread the manuscript and helped in design of study. MR interpreted and analyzed the data and helped in writing the manuscript. SJ assisted surgeries, kept record of all patients, helped in the follow-up of the patients, and recorded findings. BN assisted the surgeries and helped in data collection. YS assisted and helped in data collection. All authors have read and approved the final manuscript.

References:-

1. Baskin LS, Ebberts MB. Hypospadias: anatomy, etiology, and technique. *J Pediatr Surg* 2006;41:463-72.
2. Alkan M, Oguzkurt P, Ezer SS, Ince E, Hicsonmez A. Evaluation of the results of eccentric circummeatal-based flap with combined limited urethral mobilization technique for distal hypospadias repair. *J Pediatr Urol* 2008;4:206-9.
3. Elemen L , Tugay M : Limited Urethral Mobilization Technique in Distal Hypospadias Repair with Satisfactory Results. *Balkan Med J.* 2012; 29: 21-25.
4. Awad MMS , Tolba AM , Saad KM, Zaghlool MR,Rozigque E , Gharib OH, Khalil SA: What is the best choice for repair of distal penile hypospadias: The tubularized incised plate urethroplasty or anterior urethral advancement technique? *Indian J Plast Surg.* 2007;40(2):182-188.
5. Ekinci S, C, iftc, i AO , Karnak I , Senocak ME. Eccentric circummeatal based flap with limited urethral mobilization: an easy technique for distal hypospadias repair. *J Pediatr Urol* 2015; 2:396–400
6. Beck C: A new operation for balanic hypospadias. *NY Med J.* 1898; 67: 147.
7. Cenk B. Evolution of hypospadias surgery: historical perspective, hypospadias surgery, Berlin Heidelberg: Springer; 2004; 3–17.
8. Atala A: Urethral mobilization and advancement for midshaft to distal hypospadias. *J Urol.* 2002;168: 1738-1741.
9. Koenig JF., Kottwitz M and McKenna PH :Urethral Mobilization for Distal and Mid Shaft Hypospadias with Chordee. *The journal of Urology.* 2013; 190:1545-1549.
10. El Saadi M.M. , Tolba A M , Sarhan A.E: Anterior Urethral Advancement in Repair of Hypospadias: A Modification of the Technique. *Annals of Pediatric Surgery.* 2010; 6(1):18-21.
11. Haider, N., Hashim, I., Iqbal, M.A. et al. Outcome of urethral mobilization and advancement after anterior hypospadias surgery. *Ann Pediatr Surg* 2019;**15**:6
12. Rafi M, Qureshi MA, Saleem M. Single stage repair of anterior and mid penile hypospadias. *PJMHS.* 2011;5(1):3–5.
13. Levent E & Melih T. Limited urethral mobilization technique in distal hypospadias repair with satisfactory results. *Balkan Med J* 2012; 29: 21-25.
14. Karim S, Aziz A, Rehman A, Parvin S. Limited urethral mobilization (lum) and modified tubularized incised plate (tip) Urethroplasty in distal hypospadias repair; A comparative study. *IJCMPR.* 2017; 3(8):2232-34
15. McGowan AJ Jr, Waterhouse K. Mobilization of anterior urethra. *Bull NY Acad Med* 1964;40:776-782
16. Elbatarny AM , Khirallah MG , Elsayaf ML Assessment of meatal mobilization (MEMO) technique for distal penile hypospadias. *Ain Shams Journal of Surgery.* 2015.
17. Chakraborty AK, Majumdar SK, Zahid MK, Biswas I, Palit P. Limited urethral mobilization technique in distal hypospadias repair: An overview. *Chattagram Maa-O-Shishu Hospital Medical College Journal.* 2017; 37-41.
18. Hassan HS, Almetaher HA, Negm M, Elhalaby EA. Urethral mobilization and advancement for distal hypospadias. *Ann Pediatr Sur.* 2015; 11(4): 239-43.
19. Hassan Hussam S, Almetaher Hisham A, Mohammed Negm, Elhalaby Essam A. Urethral mobilization and advancement for distal hypospadias. *Ann Pediatr Sur* 2015; 11:239–243.

20. Sheikh MA, Latif MA, Ahmad JAM. Hypospadias repair in children: 10-years' experience at Shaik Zayad Hospital Lahore. Professional Med J 2019; 26(7): 1020-1026.
21. Darawany HME, Damhogy MEA. Urethral Mobilization as an Alternative Procedure for Distal Hypospadias Repair. J.Urology 2017(104)183-186.
22. Shafiq-ur-Rehman, Makki Y, Ishtiaq F, Shamikha W, Aziz N, Fazal S. The outcome of limited urethral mobilization urethroplasty for anterior hypospadias. Professional Med J 020; 27(1):210-216.