



Journal Homepage: - www.journalijar.com

INTERNATIONAL JOURNAL OF ADVANCED RESEARCH (IJAR)

Article DOI: 10.21474/IJAR01/13275

DOI URL: <http://dx.doi.org/10.21474/IJAR01/13275>



RESEARCH ARTICLE

SUB-TALAR DISLOCATION: ABOUT 2 CASES AND LITERATURE REVIEW

M. Moussadiq, M. Haddou, E. Zim, M. Nassiri, A. Achkoun, M.A. Benhima and I. Abkari

Orthopedic Surgery and Traumatology Department Chu Mohammed VI, Arrazi Hospital Marrakech, Morocco.

Manuscript Info

Manuscript History

Received: 15 June 2021

Final Accepted: 19 July 2021

Published: August 2021

Key words:-

Subtalar Dislocation, Medial, Lateral, Reduction

Abstract

Subtalar dislocation is a rare injury in traumatology. The lateral variant is exceptional and provides more complications. This dislocation often occurs following high energy trauma and involves simultaneous dislocation of the subtalar and talo-navicular joints. We report two cases of subtalar dislocation, medial and lateral, with good evolution.

Copy Right, IJAR, 2021.. All rights reserved.

Introduction:-

Subtalar dislocation is a rare injury, especially when it is open. According to Leitner, it represents 1% of all dislocations observed in traumatology [1]. It is an orthopedic emergency that most often occurs following a high energy trauma resulting in damage to the talo-calcaneal and talo-navicular joints while the talo-crural joint remains intact.

The lateral variant is exceptional and provides more complications [2].

We report 2 cases of open subtalar dislocation stage II of Cauchoix-Duparc. The treatment was orthopedic with a very good functional result.

Patient and Observation:-

Case 1

It was a 21-year-old patient, a motorcyclist struck by a car, causing open trauma to his left ankle. The mechanism was an inversion on a foot locked in slope against the ground by the motorcycle according to the patient. On interrogation, the patient had pain with total functional impotence of the left lower limb. The clinical examination found localized pain with major deformation of the mid-tarsal region and a stuck foot in talus and a wound on the external side of the ankle measuring 5 cm (Figure 1a & 1b). The vasculo-nervous examination was normal. The radiological assessment objectified a medial subtalar and talo-navicular dislocation with fracture of the neck of the talus Hawkins I (Figure 2a & 2b). The orthopedic reduction was carried out in emergency, after trimming the wound, under general anesthesia by an external maneuver; traction with direct pressure on the projection of his talus and eversion of his foot With his knee in flexed position to relax her Achilles tendon, Reduction was achieved easily, we found a good stability after reduction and The radiological control showed good joint congruence after reduction.

Complementary compression using a plastered boot was performed and maintained for six weeks, and then rehabilitation was undertaken. At the last follow-up, the clinical examination revealed a painless subtalar. The mobility of the ankle is normal and the mobility of the subtalar is a little stiff, without pathological laxity. Standard radiographs are normal. After 12 months, the functional result was satisfactory

Corresponding Author:- M. Haddou

Address:- Orthopedic Surgery and Traumatology Department Chu Mohammed Vi, Arrazi Hospital Marrakech, Morocco.

Case 2

It was a 36-year-old man, with no significant medical history, victim of a work accident (fall into a well estimated to be 10 meters deep), causing him an open trauma to the left ankle and homolateral knee. he was admitted to our emergency unit with pain and total functional impairment of her left lower limb. clinical examination found diffuse edema of the foot, localized pain with major deformation of the mid-tarsal region and one foot stuck in eversion, plantar flexion and adduction and a stage II skin opening of Cauchoix-Duparc's classification on the internal side of the ankle (figure 3a & 3b). The vasculo-nervous examination was normal.

The radiological assessment objectified a lateral subtalar and talo-navicular dislocation without associated fracture (Figure 4). Orthopedic reduction was attempted as a matter of urgency, after trimming the wound, under general anesthesia by external maneuver, without success due to the interposition of the tendon of the posterior tibial muscle, an open hearth reduction was carried out, The scope control objectified a good articular congruence after reduction, A clinical testing objectified the instability of the subtalar joint which imposed a fixation by two talocalcaneal Kirschner wires during 6 weeks (figure 5). A posterior plastered splint, allowing the verification of the cutaneous state later, and a radiological control are carried out after reduction. A circular plaster was produced at the orthopedic consultation at 72 hours of the trauma and maintained for six weeks. Rehabilitation was undertaken. After a 6-month follow-up, the functional result was satisfactory.

Discussion:-**Frequency**

Subtalar dislocation is a rare condition, the first observations date back to 1803 by Hey [3], it represents 1% of all dislocation in trauma and 15% of peri-talar lesions [4].

The sex ratio is said to be 3 to 4 times higher in men [4].

The dislocation can be medial, lateral, anterior, or posterior.

The medial version is the most frequent with 80% of the cases reported in the literature [5]. Lateral dislocation represents 17% of cases [5].

Mechanism of injury

Subtalar dislocation has been used as a result of high-energy trauma mainly in accidents on the public highway, work accidents and sports accidents.

Lateral dislocation results from forced eversion, the foot being locked with pressure on the lateral side of the leg [6]. At first, the deltoid ligament ruptures back and forth. Then, the hedged ligament tears by stretching, with talocalcaneal dislocation. Finally, the stress continues and the internal rotation of the leg skeleton causes the rupture of the dorsal talo-navicular ligament, allowing the total escape of the foot under the talus outwards, while the medial dislocation results from a forced inversion of the blocked foot in equine.

Diagnostic

The diagnosis is generally easy. Clinically, the deformation is major, and the foot is fixed in eversion or inversion. Swelling and edema appear quickly and can mask the deformity.

The skin opening is internal in the lateral dislocations and occurs in 10 to 15% of cases [7]. Ischemia of the foot is more frequent in lateral dislocation because the posterior tibial artery is taken in the bridge at the talus [8].

The diagnosis is confirmed by standard profile radiography but especially from the front, showing the talus in place in the tibiofibular mortise while the foot is thrown inside. CT scan can confirm the diagnosis and assess the associated osteocartilaginous lesions.

Therapeutic principles

The treatment consists in an emergency reduction by external maneuver, the knee being in flexion to relax the sural triceps. The irreducibility must make suspect an interposition and impose a bloody reduction. 15 to 20% of lateral dislocations cannot be reduced by talo-navicular or tendon bone interposition (posterior tibial, long hallux flexor) [9].

The initial immobilization is done in a posterior plastered splint that stops below the knee and can be secondarily circularized and maintained for 6 weeks [9].

A clinical stability test is essential to detect any instability of the subtalar joint, if necessary, stabilization with KW can be considered.

A radiological control confirms the reduction and looks for associated bone lesions.

Prognosis and Complications

The prognosis is good if the reduction is made within hours of the accident. The immediate complications are mainly septic, if the dislocation is open, and cutaneous.

The outcome of these dislocations is interspersed with four major complications: stiffness is the most common complication, osteoarthritis, avascular necrosis of the talus, and instability of the subtalar joint [10, 11]. The functional results of these dislocations mainly refer to the American Orthopedic Foot and Ankle Society (AOFAS) specific hindfoot score of 0 to 100.

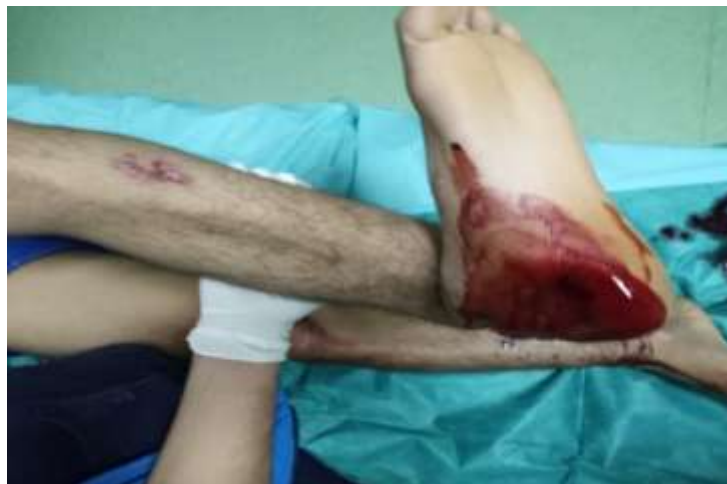

Figure 1:-

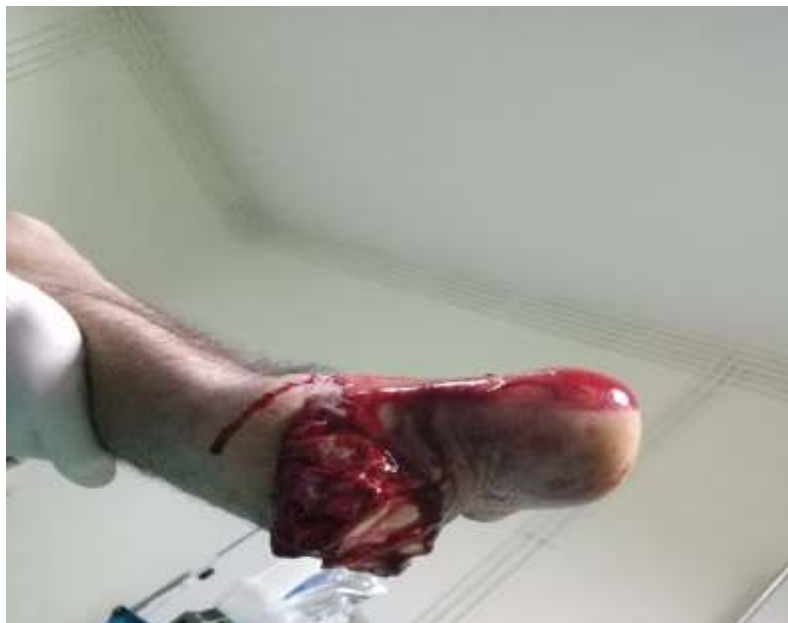

Figure 2:-

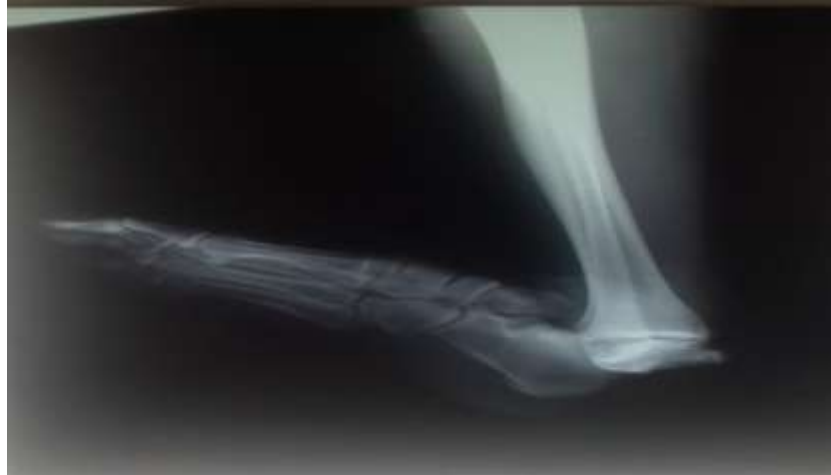

Figure 3:-

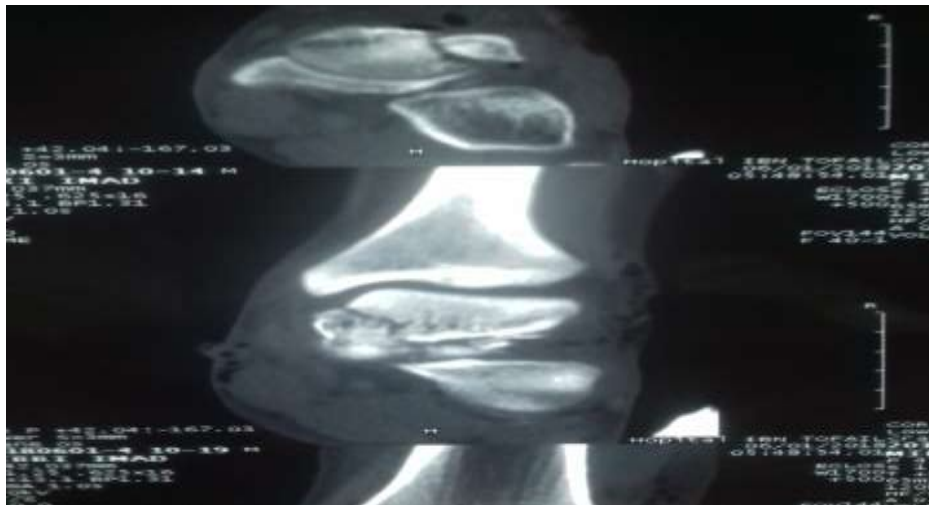


Figure 4:-

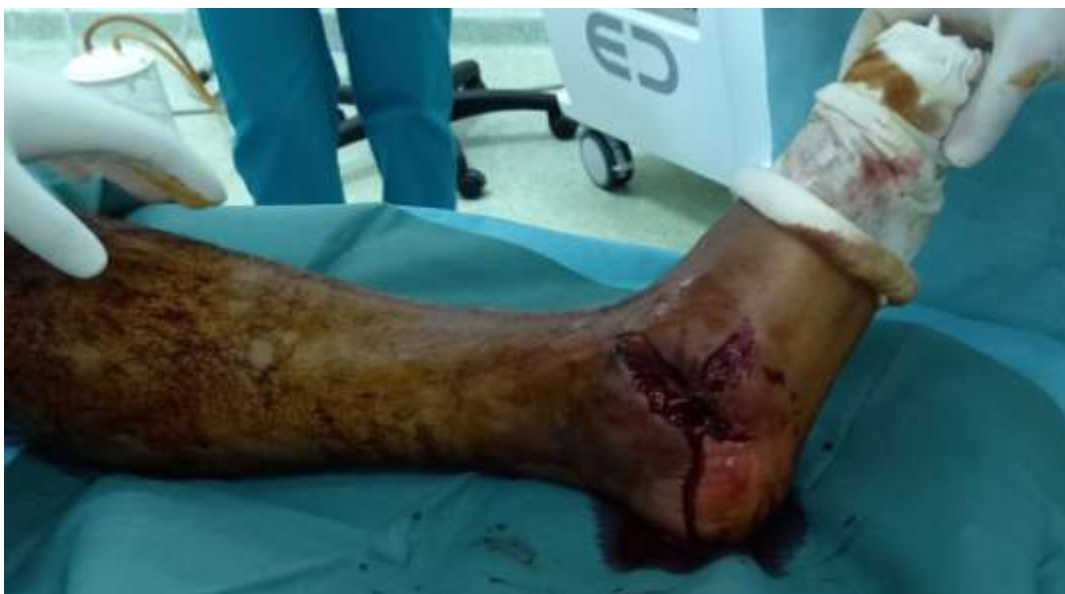

Figure 5:-

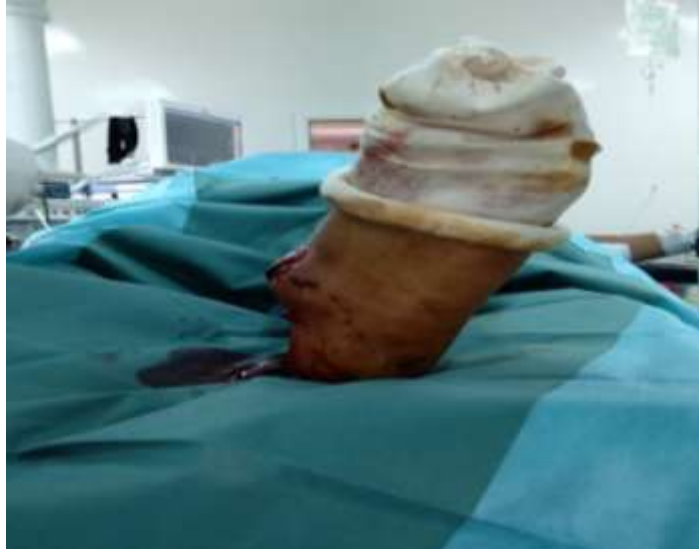

Figure 6:-

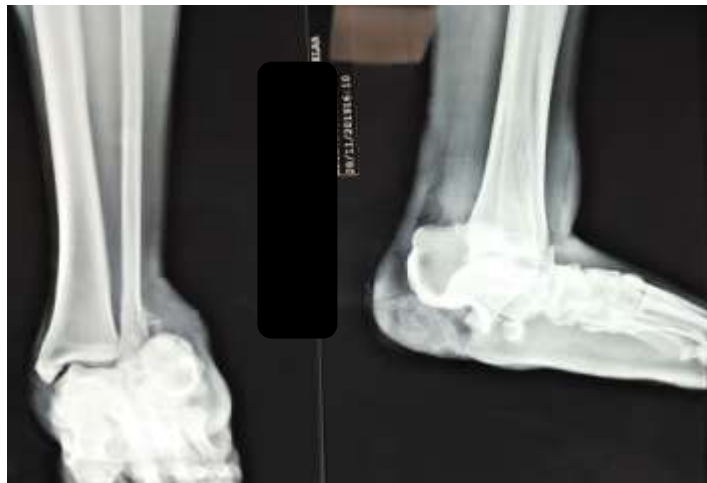

Figure 7:-

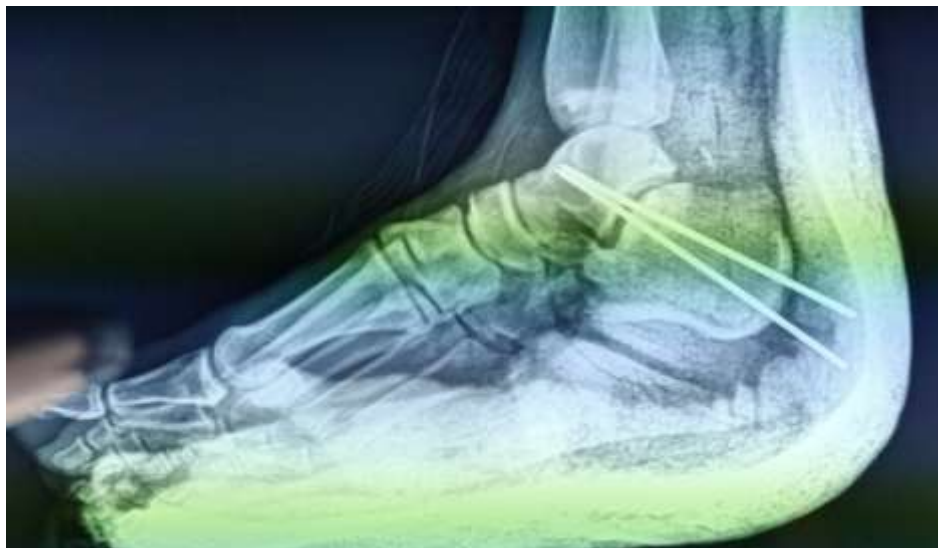

Figure 8:-

Conclusion:-

Subtalar dislocation is a rare lesion that occurs readily as a result of high energy trauma. In most cases, this dislocation is internal. The reduction is done by external maneuver, but this is sometimes impossible due to the incarceration of tendon elements. The prognosis is good except in the case of open dislocation and / or associated fractures.

Conflicts of interest

The authors declare that they have no conflicts of interest in relation to this article.

Author contributions

All the authors contributed to the conduct of this work. All authors also declare having read and approved the final version of the manuscript.

Figures legends

Figure 1: Medial view of ankle: deformation of the mid-tarsal region.

Figure 2: wound on the external side of the ankle measuring 5 cm.

Figure 3: X-Ray of ankle: internal subtalar dislocation with fracture of the talus.

Figure 4: ankle CT scan: internal subtalar dislocation.

Figure 5: Medial view: wound on the internal side of the ankle.

Figure 6: deformation of the ankle region.

Figure 7: X-ray external subtalar without associated fracture.

Figure 8: reduction and fixation by two talocalcaneal Kirschner wires.

Reference:-

1. Leitner B. Luxation sous-astragaliennne récente du pied avec subluxation tibiotarsienne de l'astragale. *Rev Chir OrthopReparatriceAppar Mot* 1954;40:232–235.
2. Y.Ouchrif, R.Ouakrim, M.Latif, M.Rhounimi, M.Benaissi, B.DeSomer, P.F.Palmari,Elouakili Lateral subtalar dislocation in a basketball player: Case report and literature review *Journal de Traumatologie du Sport* Volume 32, Issue 3, September 2015, Pages 129-132
3. Hey P. Bulletin de la faculté de Médecine de Paris. 1803. In Press.
4. Pesce D, Wethern J, Patel P (2011) Rare case of medial subtalar dislocation from a low-velocity mechanism. *Eur J Emerg Med* 6:121–4.
5. Tucker DJ, Burian G, Boylan JP. Lateral subtalar dislocation: review of the literature and case presentation. *J Foot Ankle Surg* 1998;37:239–47.
6. Marotte JH, Lord G, Samuel P, Moati JC. Les luxations sous astragaliennes externes: à propos de 4 cas. *Chirurgie*. 1979; 105: 389-92
7. Meyer JM, Hoffmeyer P. la luxation sous-astragaliennne. *Med et Hyg*. 1985; 43: 1520-2.
8. Tricoire JL, Colombier JA, Chiron P, Duraffour H, Puget J, Utheza G. Les luxations sous-astragaliennes: appréciation pronostique, attitude thérapeutique. Strasbourg, 9ème Congrès de Chirurgie d'Urgence. 1989.
9. de Palma L, Santucci A, Marinelli M, et al. Clinical outcome of closed isolated subtalar dislocations. *Arch Orthop Trauma Surg* 2008;128:593–8.
10. Nkaoui M, Boufettal M, Sasbou Y, et al (2017) Luxation sous-talienne pure: à propos d'un cas. *PAMJ* 27:123
11. Prada-Canizares A, Aunon-Martin I, Rico JV, et al (2016) Subtalar dislocation: Management and prognosis for an uncommon orthopaedic condition. *Int Orthop* 40:999–1007.