



Journal Homepage: -www.journalijar.com

INTERNATIONAL JOURNAL OF ADVANCED RESEARCH (IJAR)

Article DOI:10.21474/IJAR01/13662
DOI URL: <http://dx.doi.org/10.21474/IJAR01/13662>



RESEARCH ARTICLE

EVALUATION OF DIAGNOSTIC NASAL ENDOSCOPY AND CT SCAN IN VARIOUS SINONASAL DISEASES

Dr. Ranjan Kumar¹, Dr. Rajeev Chandra² and Dr. Om Prakash³

1. Associate Professor, Deptt. of ENT, A.N.M.M.C.H., Gaya.
2. Resident, Deptt. of ENT, A.N.M.M.C.H., Gaya.
3. Professor & Head Deptt. of ENT, A.N.M.M.C.H., Gaya.

Manuscript Info

Manuscript History

Received: 31 August 2021
Final Accepted: 30 September 2021
Published: October 2021

Key words:-

Nasal Endoscopy, CT Scan, Sinonasal Disease, Diagnosis

Abstract

Objective: To evaluate role of Diagnostic Nasal Endoscopy and CT scan in various Sinonasal diseases with regards to diagnosis and surgical intervention.

Patient and methods: This prospective study was carried out in Department of ENT, A.N.M.M.C.H., Gaya on 200 patients with clinical evidence of sinonasal disease who had presented between March 2016 to February 2019. All patients were evaluated with DNE using 0 degree 4mm endoscope and CT scan with 3 mm coronal cuts.

Result: Female patients (56%) were more as compared to male (44%) with majority between 21 - 40 yrs. Most common finding on Diagnostic Nasal Endoscopy (DNE) was mucopurulent discharge in middle meatus while on CT Scan was maxillary sinusitis (60%). Sinonasal polyp detection was better with DNE. CT has better detection rate of anatomical variation of osteomeatal complex.

Conclusion : DNE has become initial tool for diagnosis as it is cost effective and office based procedure. In patients where surgical intervention is required, CT scan has advantage as it provides detailed understanding of anatomical variations. So both DNE and CT scan should be used in collaborative fashion.

Source Of Support: Patients of A.N.M.C.H., Gaya.

Conflict Of Interest: None.

Copy Right, IJAR, 2021., All rights reserved.

Introduction:-

In recent years nasal endoscopy has become integral component as a diagnostic tool for various sinonasal diseases in day to day ENT practice. Nasal endoscopy allows a detailed examination of the sinonasal area not possible by standard examination such as anterior rhinoscopy using headlight or head mirror [1]. Hirshman made the first attempt at nasal and sinus endoscopy in 1901 using a modified cystoscope [2]. Messerklinger introduced ESS in Europe in 1967 and Stammberger, Wigand contributed further in evolution of diagnosis and management of sinonasal disease [3,4,5]. For Diagnostic Nasal Endoscopy both flexible and rigid nasal endoscopes are used. 4 mm & narrower 2.7 mm rigid endoscope are popular for adult and paediatric use respectively. Smaller diameter endoscope (2.7mm) has advantage of being easily negotiable in the nasal cavity in paediatric patients and also in adult patients with difficult passage in conditions like inferior turbinate hypertrophy, deviated nasal septum etc. causing less discomfort to the patients. 4 mm endoscope is however more durable, has more illumination thus

Corresponding Author:- Dr. Rajeev Chandra

Address:- Resident, Deptt. of ENT, A.N.M.M.C.H., Gaya.

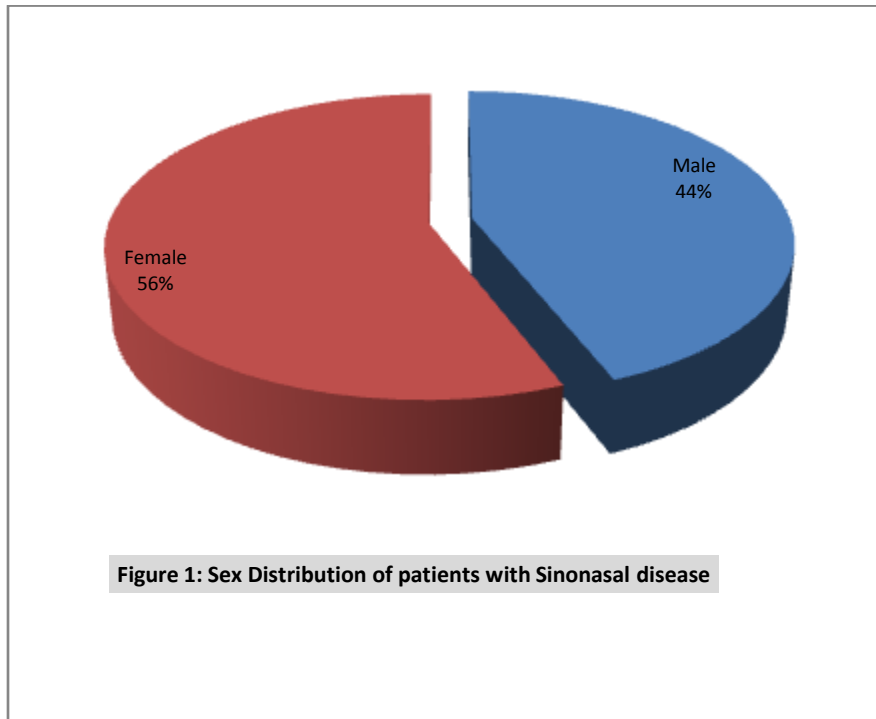
providing better images. Nowadays CT scan is the preferred method of investigation over plain radiography for radiological diagnosis of sinonasal diseases. CT scan has the advantage over plain radiography in showing sinonasal anatomy and its variation in detail. Better understanding of anatomical variations of osteomeatal complex helps the surgeon to perform surgery in the patient safely and avoid inadvertent consequences of damaging surrounding vital structures like the orbit and brain. The aim of this study was to evaluate the role of Diagnostic Nasal Endoscopy (DNE) and CT scan with regards to diagnosis and surgical intervention.

Materials And Methods:-

This prospective study was carried out in Department of ENT, A.N.M.M.C.H., Gaya over a period of 3 years from March 2016 to February 2019. A total of 200 patients with clinical evidence of sinonasal disease were evaluated with Diagnostic Nasal Endoscopy and CT scan. Nasal endoscopy was performed by 0 degree 4 mm endoscope which is available in A.N.M.M.C.H., Gaya. All patients were sent for plain CT scan of PNS with 3mm coronal cuts. Patient with acute sinusitis, below 10 years of age, pregnant ladies, patient with complications were excluded from this study.

Results:-

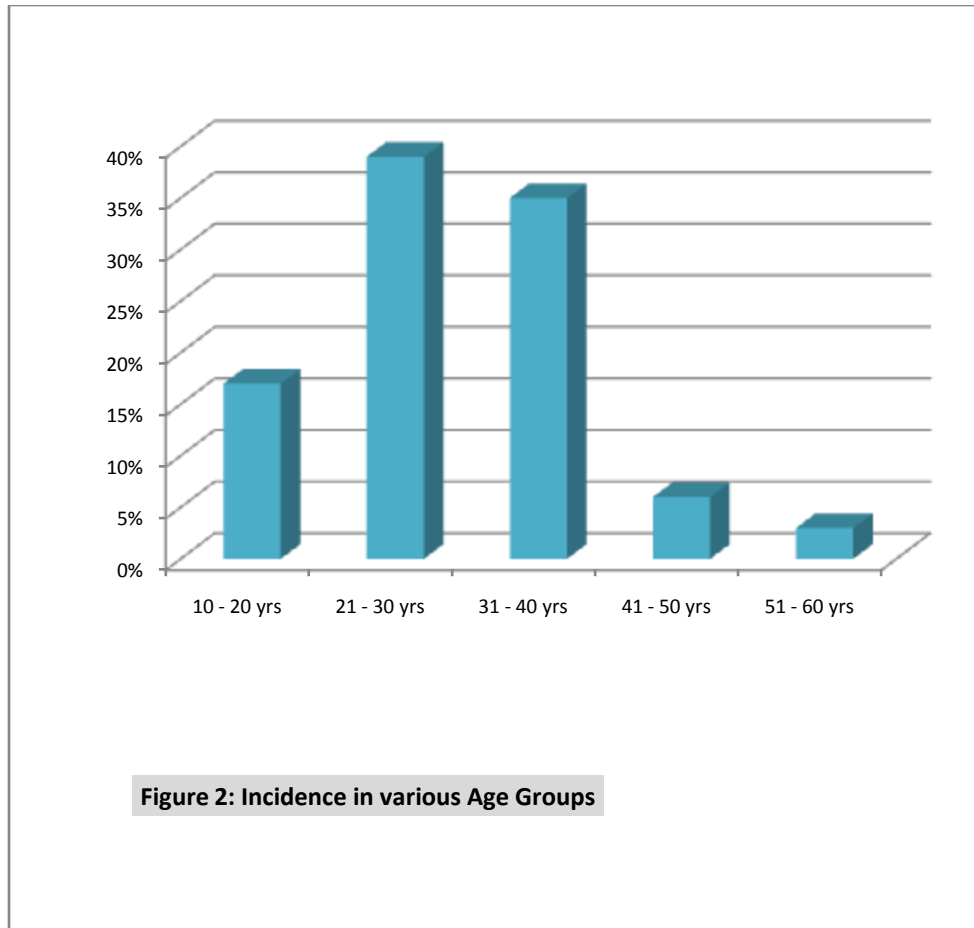
A total of 200 patients were studied out of which 112 were female and 88 were male.



The patients age ranged from 10 years to 60 years with maximum number of patients 78 (39%) were in the third decade of life. 70 patients (35%) were in the 30-40 years of age group.

Table 1:- Sex Incidence in Various Age Groups.

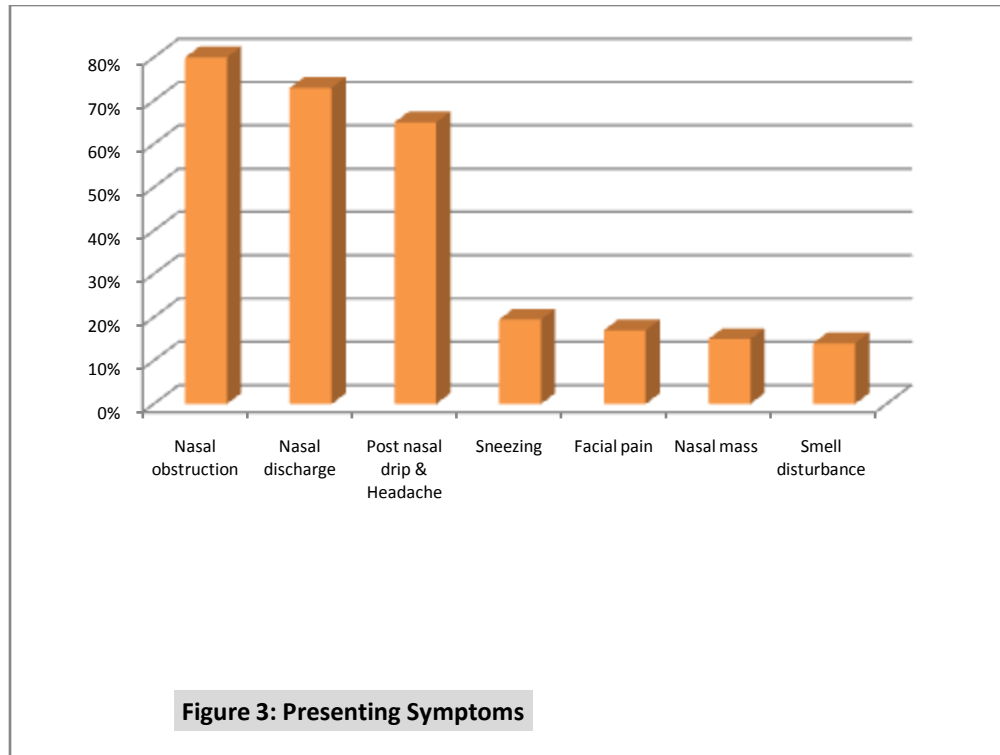
Age	Males	Female	Total	Percentage
10 - 20 yr	14	20	34	17%
21 - 30	36	42	78	39%
31 - 40	31	39	70	35%
41 - 50	5	7	12	6%
51 - 60	2	4	6	3%
Total	88	112	200	100%



The commonest presenting symptom was nasal obstruction in 160 cases (80%). Other symptoms were nasal discharge in 146 cases (73%), post nasal drip & headache in 130 cases (65%), sneezing in 39 cases (19.5%), Facial pain in 34 cases (17%), nasal mass in 30 cases (15%) and smell disturbance (anosmia, parosmia, cacosmia) were also observed among the patients.

Table 2:- Presenting Symptom of Patients.

Presenting Symptom	Percentage (%)	No. of People
Nasal obstruction	80%	160
Nasal discharge	73%	146
Post nasal drip & Headache	65%	130
Sneezing	19.50%	39
Facial pain	17%	34
Nasal mass	15%	30
Smell disturbance	14%	28



Most common finding on Diagnostic Nasal Endoscopy(DNE) was mucopurulent discharge in middle meatus in 120 cases (60%) followed by Deviated Nasal Septum 102 cases (51%), Inferior Turbinate Hypertrophy in 94 cases(47%), mucopurulent discharge between middle turbinate and septum suggestive of isolated posterior ethmoid and sphenoid disease in 20 cases(10%). Ethmoidal polyp were noted in 28 cases(14%) and Antrochoanal polyp were seen in 22 cases (11%). Middle turbinate abnormalities like Concha bullosa were seen in 18 cases (9%), paradoxically curved middle turbinate and Bifid middle turbinate were detected in 3 cases (1.5%) & 1 case (0.5%) respectively.

Table 3:- DNE finding of the Patients.

DNE Finding	(%)	No. of People
Mucopurulent discharge (middle meatus)	60%	120
Deviated Nasal Septum	51%	102
Inferior Turbinate Hypertrophy	47%	94
Mucopurulent discharge (between middle turbinate and septum)	10%	20
Ethmoidal polyp	14%	28
Antrochoanal polyp	11%	22
Middle turbinate : Concha bullosa	9%	18
Middle turbinate: Paradoxical	1.50%	3
Middle turbinate: Bifid	0.50%	1

The most common finding in CT Scan was maxillary sinusitis(60%) and commonest pathological finding was Inferior turbinate hypertrophy (44%), Deviated nasal septum (54%) with Ethmoidal sinusitis (25%), Ethmoidal polyp(12%), Frontal Sinusitis(15%), Pansinusitis(13%), Antrochoanal polyp(10%) and sphenoidal sinusitis(10%).

Table 4:- CT Finding of Patients.

CT Finding	Percentage	No. of People
Maxillary sinusitis	60%	120
Inferior turbinate hypertrophy	44%	88
Deviated nasal septum	54%	108

Ethmoidal sinusitis	25%	50
Ethmoidal polyp	12%	24
Frontal Sinusitis	15%	30
Pansinusitis	13%	26
Antrochoanal polyp	10%	20
Sphenoidal sinusitis	10%	20

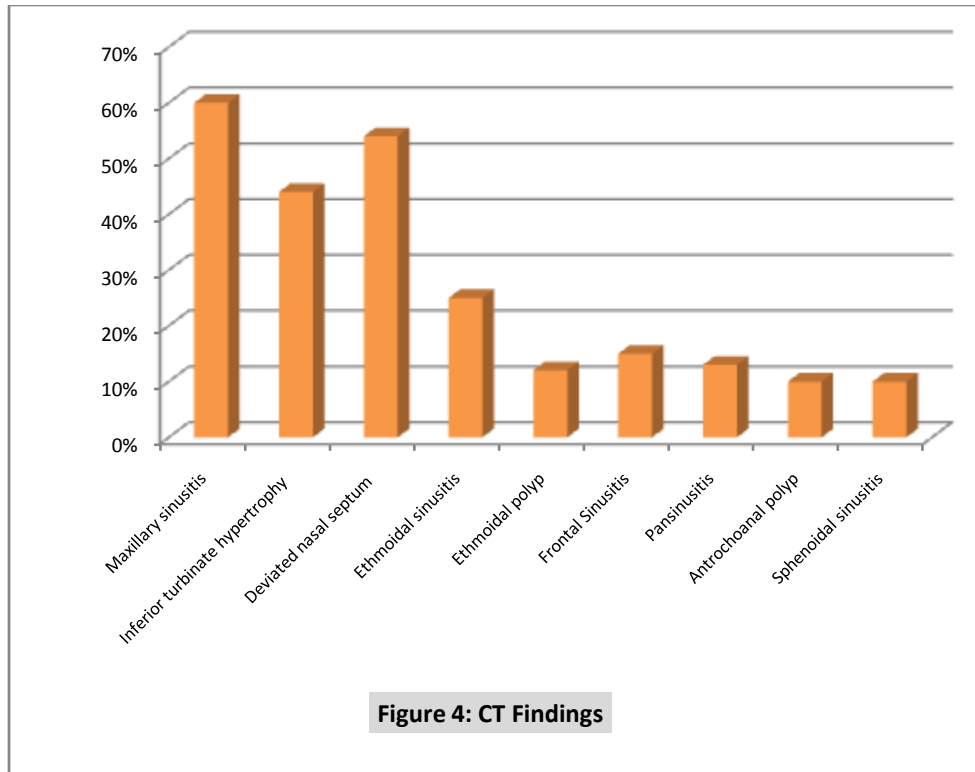


Figure 4: CT Findings

Anatomical variation in superior attachment of Uncinate process to Lamina papyracea, middle turbinate and skull base were 74%, 11% and 15% respectively. Aggernasi, Haller and Onodi cells were seen in 28%, 5% & 2% cases respectively.

Table 5:- CT Finding of Anatomical Variations.

CT Finding	%	No. of People
Middle turbinate : Concha bullosa	11%	22
Middle turbinate: Paradoxical	2.0%	4
Middle turbinate: Bifid	0.50%	1
Uncinate attachments: lamina papyracea	74%	148
Uncinate attachment: middle turbinate	11%	22
Uncinate attachments: skull base	15%	30
Aggernasi cells	28%	56
Haller cells	5%	10
Onodi cells	2%	4

Discussion:-

In the current study, female patients outnumbered male patients. This was different from other studies by Zojaji et al, Sheetal et al which showed male predominance [6,7]. This variation could be attributed to the fact that female population are more exposed to indoor pollutants especially in kitchen as conventional method of cooking is still prevalent in rural areas. Majority of patients belong to age group 21-40 yrs and it can be inferred that this age group is more exposed to the environmental pollutants and disease causing respiratory pathogens. This was similar to

studies by Zojaji et al, Sheetal et al, Sancheti et al [6, 7, 8]. CT scan was able to diagnose septal deviation in 54% cases while DNE in 51% cases. This was due to the fact that in case of gross anterior deviation and extensive nasal mass occupying lesion CT scan is better than DNE [8].

Sinonasal polyp detection was better with DNE(25%) over CT Scan(22%). Similar observation was made by Srivastava M et al. [8]. Hypertrophy of turbinates were better visualized by DNE (47%) as compared to CT scan (44%).

Middle meatal secretion was seen in DNE (60% cases) but not picked up by CT scan. Uncinate process can be appreciated by both CT scan and DNE but to assess the superior attachment of Uncinate process to lamina papyracea, middle turbinate and skull base CT Scan provided improved visualization. Frontal recess patency can be better visualized by CT scan than DNE[9]. CT has high specificity for Agger nasi cells. Haller cells & Onodi cells could only be visualized in CT scan. In this study Concha bullosa was seen in 11% cases in CT while 9% by DNE. CT has better detection rate of Middle turbinate abnormalities similar to Maru YK et al observation [10]. CT scan thus has advantage in providing better understanding regarding extent and spread of the disease.

Conclusion:-

Both DNE and CT scan have their own importance, share of advantage over each other in diagnosing and surgical planning of various sinonasal disease. But DNE being cost effective and OPD based procedure, it has become initial tool to assess sinonasal disease. CT on the other hand holds advantage in group of patients who require FESS where detailed understanding of anatomical variation is the key for safe and successful surgery and to avoid potentially dreadful complication. Thus both DNE and CT scan should be used in collaborative fashion depending upon patient's need.

Reference:-

1. Soudry E, Nayak JV (2011). Nasal endoscopy. American Rhinologic Society: (Revised Sep 2011)
2. Draf W. Endoscopy of the Paranasal Sinuses. New York: Springer-Verlag, 1983
3. Messerklinger W. Über die drainage der menschlichen nasennebenhöhlen unter normalen und pathologischen Bedingungen II: die stirnhöhle und ihre ausführungssysteme. *Monatssch Ohrenheilkd* 1967;101: 313–326
4. Stammberger H. Endoscopic endonasal surgery—concepts in treatment of recurring rhinosinusitis. Part I. Anatomic and pathophysiologic considerations. *Otolaryngol Head Neck Surg* 1986;94(2): 143–147
5. Wigand ME, Steiner W, Jaumann MP. Endonasal sinus surgery with endoscopic control: from radical operation to rehabilitation of the mucosa. *Endoscopy* 1978;10(4):255–260
6. Zojaji R, Mirzadeh M, Naghibi S (2008) Comparative evaluation of preoperative CT scan and intraoperative endoscopic sinus surgery findings in patients with chronic rhinosinusitis. *Iran J Radiol* 5: 77-82.
7. Sheetal D, Devan PP, Manjunath P, Martin P, Satish Kumar K, et al. (2011) CT pns - Do we really require before fess? *J Clin Diagn Res* 5: 179-181.
8. Srivastava, Mohit, Sushant Tyagi, and Lalit Kumar. "Comparative Evaluation of Chronic Rhinosinusitis Patients by Conventional Radiography, Computed Tomography and Diagnostic Nasal Endoscopy (DNE)." *Indian Journal of Otolaryngology and Head & Neck Surgery* 68.2 (2016): 173–178. PMC. Web. 4 Aug. 2018.
9. Sancheti P, Velankar HK, Setty YK, Mathew MS, Dabholkar YG (2017) Diagnostic Nasal Endoscopy or CT Scan of Paranasal Sinuses: Which One First? *Res J Ear Nose Throat Vol.1 No.1*:7
10. Maru YK, Gupta Y (2000) Concha bullosa: frequency and appearance on sinonasal CT. *Indian J Otolaryngol Head Neck Surg* 52:40–44.