



Journal Homepage: -www.journalijar.com

INTERNATIONAL JOURNAL OF ADVANCED RESEARCH (IJAR)

Article DOI:10.21474/IJAR01/13858
DOI URL: <http://dx.doi.org/10.21474/IJAR01/13858>



RESEARCH ARTICLE

MULTIPLE SYNCHRONOUS SMALL BOWEL ADENOCARCINOMAS IN A CASE OF BOWEL OBSTRUCTION DUE TO FAECALOMAS SECONDARY TO MULTIPLE STRICTURES – A DIAGNOSTIC SURPRISE

Dr. Umesh O. Paprunia¹, Dr. Girija A. Patil² and Dr. Bhushan H. Mahamulkar³

1. Dr. Umesh O. Paprunia, Senior Consultant & Head of Department, Department of General Surgery, Noble Hospital, Pune.
2. Dr. Girija A. Patil, Senior Consultant, Department of General Surgery, Noble Hospital, Pune.
3. Dr. Bhushan H. Mahamulkar, Senior Resident, Department of General Surgery, Noble Hospital, Pune.

Manuscript Info

Manuscript History

Received: 30 September 2021
Final Accepted: 31 October 2021
Published: November 2021

Keywords:

Multiple Synchronous SBA, Faecaloma, Intestinal Obstruction, Tuberculosis

Abstract

Small bowel adenocarcinoma (SBA) is a rare neoplasm presenting usually in elderly patients as a single tumour. Multiple synchronous SBA is unique and difficult to diagnose due to non-specific presentations. Faecalomas have been described in association with Hirschsprung's disease, psychiatric patients, Chagas disease, both inflammatory and neoplastic conditions, and in patients suffering with chronic constipation. We herein report a case of multiple faecalomas secondary to multiple small bowel strictures leading to small bowel obstruction in a patient with previous history of pulmonary tuberculosis. The patient was successfully treated surgically. The strictures on histopathology turned out to be low grade adenocarcinoma. Multiple synchronous SBA as well as multiple faecalomas are individually rare entities, and their combined occurrence is even rarer.

Copy Right, IJAR, 2021,. All rights reserved.

Introduction:-

Small bowel cancer is a rare malignancy that comprises less than 5% of all gastrointestinal malignancies.^[1] The most common histologic subtype of small bowel malignancy is adenocarcinoma, seen in approximately 40% of all small bowel malignancies.^[2,3,4]

Small bowel adenocarcinoma (SBA) is most commonly located in the duodenum (57%), 29% of cases are located in the jejunum, and 10% of cases are in the ileum.^[5] The clinical presentation of SBA is nonspecific abdominal discomfort, including abdominal pain, nausea, vomiting, gastrointestinal bleeding and intestinal obstruction. This leads to an average delay of 6–10 months in diagnosis.^[3] Most cases have a single lesion in the small bowel.^[6] Due to its rarity, multiple synchronous SBA is frequently misdiagnosed.

Faecaloma is defined as a mass of hardened faeces most commonly accumulated in the colon or rectum.^[7,8,9] The consistency of the faecaloma is more than faecal impaction due to coprostasis.^[10] Faecalomas have been described in association with Hirschsprung's disease^[11], psychiatric patients, Chagas disease, both inflammatory and neoplastic conditions, and in patients suffering with chronic constipation.^[12]

Corresponding Author:- Dr. Umesh O. Paprunia

Address:- Dr. Umesh O. Paprunia, Senior Consultant & Head of Department, Department of General Surgery, Noble Hospital, Pune.

We hereby present a case of an elderly lady who presented with recurrent small bowel obstruction due to multiple faecalomas secondary to multiple small bowel strictures which later turned out to be small bowel adenocarcinomas on histopathology.

Case Report:

A 55-year-old, diabetic and hypertensive lady presented to the emergency department with complaints of abdominal pain, distension, and vomiting on and off from 5 days. It was associated with constipation from past 3 days. She had been having similar complaints from the past 15 years for which she had been seeking medical advice from various sources and had temporary relief from her symptoms. The patient had also undergone a prior abdominal surgery 10 years back, details of which were not available. She was diagnosed to have Pulmonary tuberculosis in the past for which she completed a full course of antitubercular therapy. A history of significant weight loss was also given by the patient and her relatives.

On physical examination, the patient was afebrile, had a pulse rate of 80/minute, blood pressure of 130/70 mmHg and normal respiration. Abdominal examination revealed distension with no visible veins or sinuses and diffuse tenderness over whole abdomen. Previous midline vertical laparotomy scar was noted. On auscultation hyperperistaltic bowel sounds were present. A digital rectal exam revealed no positive findings.

Plain standing abdominal radiography showed multiple air-fluid levels and were suggestive of a small bowel obstruction. Meanwhile, the patient was resuscitated, a nasogastric tube was inserted for decompression and routine blood investigations were sent. Previously available colonoscopy reports were suggestive of age-related chronic constipation. After the initial assessment, a CECT abdomen was ordered which showed dilated ileal loops with intraluminal obstruction due to faecaloma and bowel wall thickening at multiple places.

The patient was taken up for a diagnostic laparoscopy and adhesiolysis was performed. Multiple faecal balls within multiple ileal strictures were found on laparoscopy. A laparoscopic assisted resection and anastomosis of the involved ileal segment with faecalomas and strictures was performed. A solitary distal ileal stricturoplasty was performed. (Fig.1-4)

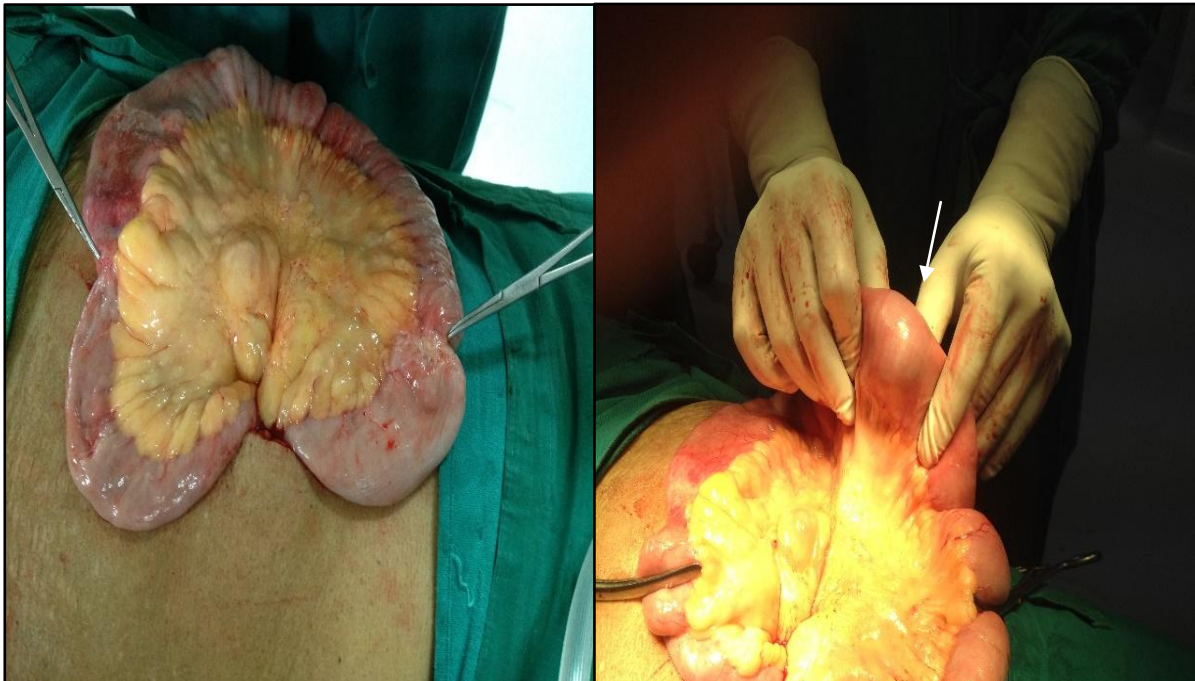


Fig.1: -Multiple ileal strictures **Fig. 2:** -Faecaloma within the strictures (White arrow)
(Haemostats pointing at the strictures)

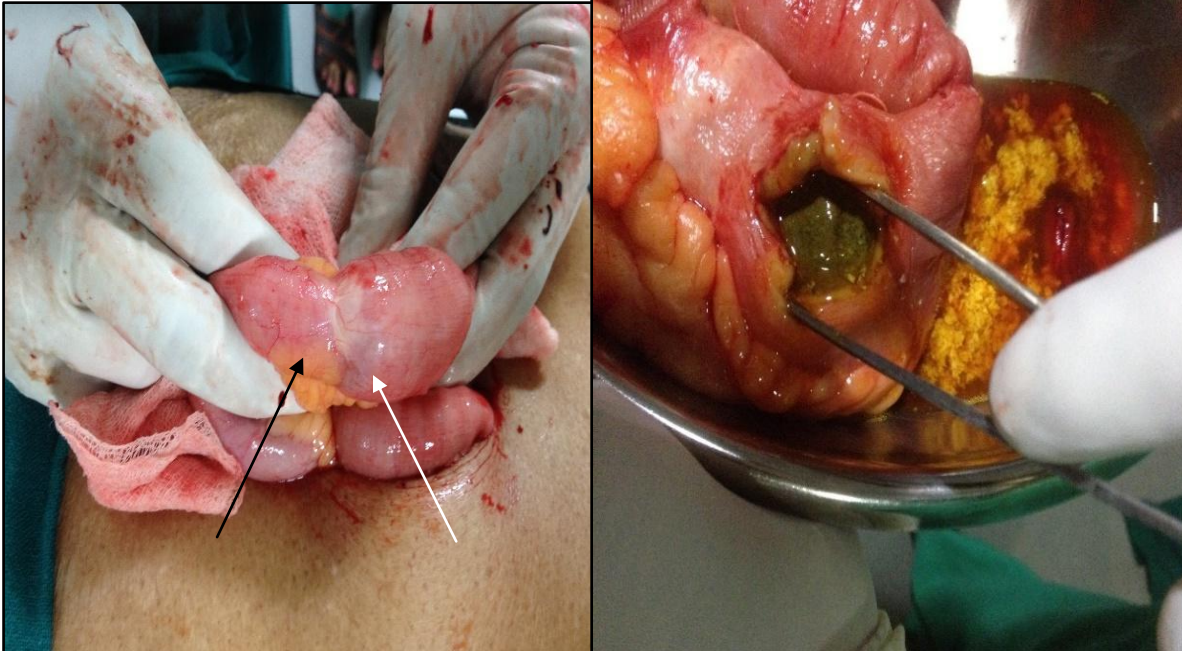


Fig. 3:- Distal ileal stricture (Black arrow)**Fig. 4:-** Faecaloma within the resected specimen Faecaloma (White arrow).

The patient was discharged after a favourable postoperative course in the ICU and wards. The histopathology report of the resected segment was suggestive of an underlying low-grade adenocarcinoma and was a diagnostic surprise. The resected margins were free of tumour cells. The specimen was also analysed to rule out any nidus of bezoar over which the faecalomas had formed, but there was no such evidence and only faecal matter was found to be present. The patient was then lost to follow up.

Discussion:-

SBA is rare and most tumours are single and commonly located in the duodenum. SBA often develops with vague and nonspecific gastrointestinal symptoms, including obscure bleeding, abdominal pain, nausea and vomiting, weight loss, diarrhoea, and intestinal obstruction. Multiple synchronous SBA is a rare and unique and very few studies on these tumours have been found in literature. These studies show that it is a difficult condition to diagnose.^[13] Chronic inflammation is associated with the formation of several malignant tumours, with Crohn's disease for example increasing the risk of SBA.^[14] Patients with familial adenomatous polyposis (FAP), hereditary non-polyposis colorectal cancer (HNPCC), Peutz-Jeghers syndrome, and celiac disease also show an increased risk of SBA development.^[15,16]

Faecaloma is an extremely rare form of faecal impaction and is defined as the accumulation of hard faecal matter within the bowel lumen that is separable from rest of bowel contents^[17, 18]. It is most commonly seen on the left side of the colon (rectum & sigmoid) because stool becomes firmer, and diameter of the left colon is smaller. It has been seen in association with Chagas disease, Hirschsprung's disease, inflammatory disease, neoplasm, chronic constipation, psychiatric patients, and elderly institutionalized population.^[7,9] Patients with faecaloma usually present with nonspecific complaints such as constipation, weight loss, vague abdominal discomfort after meals and "overflow type" of diarrhoea.^[9] In very rare cases small bowel involvement has been described in literature.^[7,8,19] Previously it has been reported that, none of the patients in a large series of 411 patients with bowel obstruction were found to have faecaloma.^[20]

In our case, Multiple SBA were thought to be secondary to a previous history of pulmonary tuberculosis causing chronic inflammation of the bowel and strictures as a part of its other systemic effects. Out of all the above-mentioned causes for faecaloma formation like chronic constipation, underlying inflammatory disease and adenocarcinoma seem relevant in our case. Peri-operatively, the strictures were suspected to be secondary to tuberculous pathology as our patient had history of pulmonary tuberculosis. However, the final histopathology report

of a low-grade adenocarcinoma came as a diagnostic surprise. Protocols to identify multiple synchronous SBA at an early stage are currently lacking and are urgently required. The complex presentation and rare occurrence of multiple SBA condition makes it easy to be misdiagnosed.

We would like to emphasize that, we should not ignore multiple synchronous SBA when diagnosing intestinal diseases and intestinal tuberculosis may represent risk factor for multiple SBA, although the pathology does not provide sufficient evidence. Since no specific methods exist for the diagnosis of multiple synchronous SBA, several diagnostic techniques used, including radiologic (CT, MRI, PET-CT) and endoscopic approaches (enteroscopy, video capsule) are usually combined for a more accurate evaluation and diagnosis. Doctors should strive to obtain pathological diagnosis to avoid diagnostic treatments and treatment delays. To-date, surgical resection remains the treatment of choice for patients with SBA. The 5-year survival is poor and dependent on tumor stage: 50–60% for stage I, 39–55% for stage II, 10–40% for stage III and 3–5% for stage IV.^[21] Majority of the diagnosis of SBA occurs at stage IV because the disease is easily misdiagnosed, and surgery is delayed. No dedicated TNM staging for multiple synchronous SBA exists. A higher number of adjuvant therapies are used for SBA treatment due to its poor prognosis and high risk of relapse.^[22,23] The most used chemotherapy regimen in the past was based in fluorouracil with modest results. Drugs like oxaliplatin and capecitabine are showing better outcome and a prospective international randomized trial (BALLAD) is being carried to assess its efficacy.^[6]

The management of faecalomas is controversial. Most of the faecal impactions are successfully managed conservatively with bowel rest, laxative, enema, and digital evacuation.^[24] Endoscopic removal of the faecaloma has also been reported in the literature.^[18] Surgical procedure generally involves either exploratory laparotomy or laparoscopy followed by removal of faecaloma and/or resection of the involved segment.^[7,9] In patients who are successfully treated, it is important to keep a close follow up and prescribe stool softeners. Emphasis on proper dietary habits which include high fiber diet, adequate water intake is also needed along with regular toilet training sessions.^[9] The outcome is mostly favourable after both conservative and surgical management. However, in elderly and those with intestinal rupture the outcome is poor.^[12,25]

Conclusion:-

Multiple synchronous small bowel adenocarcinoma (SBA) is a rare cancer. This coupled with multiple faecalomas causing small bowel obstruction makes it an extremely rare occurrence. To the best of our knowledge this case is one of the first few reported cases in literature. The diagnosis requires a high index of suspicion. Small bowel resection with negative margins is the treatment of choice. Options for adjuvant treatment include fluoropyrimidine or oxaliplatin-based regimens and are under trial.

References:-

1. Frost DB, Mercado PD, Tyrell JS. Small bowel cancer: a 30-year review. *Ann Surg Oncol.* 1994;1(4):290–5.
2. Bauer RL, Palmer ML, Bauer AM, et al Adenocarcinoma of the small intestine: 21-year review of diagnosis, treatment, and prognosis. *Ann Surg Oncol* 1994;1:183-8.
3. Dabaja BS, Suki D, Pro B, et al. Adenocarcinoma of the small bowel: presentation, prognostic factors, and outcome of 217 patients. *Cancer* 2004;101:518-26.
4. Delaunoy T, Neczyporenko F, Limburg PJ, Erlichman C. Small bowel adenocarcinoma: a rare but aggressive disease. *Clin Colorectal Cancer* 2004;4:241-8.
5. Halfdanarson TR, McWilliams RR, Donohue JH, Quevedo JF. A single institution experience with 491 cases of small bowel adenocarcinoma. *Am J Surg.* 2010;199(6):797–803.
6. Ren PT, Fu H. Primary segmental and multiple adenocarcinomas of the small bowel. *Intern Med* 2012;51:877-80.
7. Mushtaq M, Shah MA, Malik AA, Wani KA, Thakur N, Paray FQ. Giant fecaloma causing small bowel obstruction: case report and review of the literature. *Bull Emerg Trauma.* 2015; 3: 70-72.
8. Yoo HY, Park HW, Chang SH, Bae SH. Ileal fecaloma presenting with small bowel obstruction. *Pediatr Gastroenterol Hepatol Nutr.* 2015; 18: 193-196.
9. Gupta M, Aggarwal P, Singh R, Lehl SS. A case of giant fecaloma in a 32-year-old woman. *Austin J Clin Case Rep.* 2014; 1: 1017.
10. Zimmers T. Giant calcified fecaloma. *Ann Emerg Med.* 1984;13(9 Pt 1):749.
11. Campbell JB, Robinson AE. Hirschsprung's disease presenting as calcified fecaloma. *Pediatr Radiol.* 1973;1(3):161-3.

12. Caiazzo P, De Martino C, Del Vecchio G, Di Lascio P, Marasco M, Laviani F, et al. Megacolon for a giant faecaloma with unlucky outcome: case report and review of the literature. *Ann Ital Chir.* 2013;84(3):319-22.
13. Cavalla C, Oppliger F, Schiappacasse G, Valderrama R, Castiblanco A, Margarit S. Multiple synchronous adenocarcinomas of the small bowel in a young patient: a case report. *Int J Surg Case Rep.* 2018;42:250-3.
14. Gardiner KR, Dasari BV. Operative management of small bowel Crohn's disease. *Surg Clin North Am.* 2007;87(3):587-610.
15. Bennett CM, Coleman HG, Veal PG, Cantwell MM, Lau CC, Murray LJ. Lifestyle factors and small intestine adenocarcinoma risk: a systematic review and meta-analysis. *Cancer Epidemiol.* 2015;39(3):265-73.
16. Cahill C, Gordon PH, Petrucci A, Boutros M. Small bowel adenocarcinoma and Crohn's disease: any further ahead than 50 years ago? *World J Gastroenterol.* 2014;20(33):11486-95.
17. Garisto JD, Campillo L, Edwards E, Harbour M, Ermocilla R. Giant fecaloma in a 12-year-old-boy: a case report. *Cases J.* 2009; 2: 127.
18. Kim SM, Ryu KH, Kim YS, Lee TH, Im EH, Huh KC, et al. Cecal fecaloma due to intestinal tuberculosis: endoscopic treatment. *Clin Endosc.* 2012;45(2):174-6.
19. Sakai E, Inokuchi Y, Inamori M, Uchiyama T, Iida H, Takahashi H, et al. Rectal fecaloma: successful treatment using endoscopic removal. *Digestion* 2007; 75: 198.
20. Akrami M, Hesaroeh AG, Barfei M, Zangouri V, Alborzi Z. Clinical Characteristics of Bowel Obstruction in Southern Iran; Results of a Single Center Experience. *Bull Emerg Trauma.* 2015;3(1):22-6.
21. Aparicio T, Zaanani A, Mary F, Afchain P, Manfredi S, Evans TR. Small Bowel Adenocarcinoma. *Gastroenterol Clin N Am.* 2016;45(3):447-57.
22. Shenoy S. Primary small-bowel malignancy: update in tumor biology, markers, and management strategies. *J Gastrointest Cancer.* 2014;45(4):421-30.
23. Han SL, Cheng J, Zhou HZ, Guo SC, Jia ZR, Wang PF. Surgically treated primary malignant tumor of small bowel: a clinical analysis. *World J Gastroenterol.* 2010;16(12):1527-32.
24. Kim KH, Kim YS, Seo GS, Choi CS, Choi SC. A case of fecaloma resulting in the rectosigmoid megacolon. *Korean Journal of Neurogastroenterology and Motility.* 2007;13(1):81-5.
25. Ouaisi M, Sielezneff I, Benoist S, Pirro N, Cretel E, Chaix JB, et al. Lethal fecaloma. *J Am Geriatr Soc.* 2007;55(6):965-7.