



ISSN NO. 2320-5407

Journal Homepage: [-www.journalijar.com](http://www.journalijar.com)

INTERNATIONAL JOURNAL OF ADVANCED RESEARCH (IJAR)

Article DOI:10.21474/IJAR01/13711
DOI URL: <http://dx.doi.org/10.21474/IJAR01/13711>



INTERNATIONAL JOURNAL OF
ADVANCED RESEARCH (IJAR)
ISSN 2320-5407
Journal Homepage: <http://www.journalijar.com>
Journal DOI:10.21474/IJAR01

RESEARCH ARTICLE

EVALUATION OF MINERALIZED PLASMATIC MATRIX DURING SINUS LIFT WITH THE SIMULTANEOUS PLACEMENT OF DENTAL IMPLANTS

Hisham M.S. El Eryani¹, Sally S.Abdelsameaa², Hamdy A.M. Marzook³ and Abdel Monem T. Gad Allah⁴

1. M.S.C, Degree of Oral and Maxillofacial Surgery, Faculty of Dentistry, Mansoura University, Egypt.
2. Lecturer of Oral and Maxillofacial Surgery Faculty of Dentistry Mansoura University, Egypt.
3. Professor Emeritus of Oral and Maxillofacial Surgery Faculty of Dentistry Mansoura University, Egypt.
4. Professor of Oral and Maxillofacial Surgery Faculty of Dentistry Mansoura University, Egypt.

Manuscript Info

Manuscript History

Received: 05 September 2021
Final Accepted: 10 October 2021
Published: November 2021

Key words:-

Mineralized Plasmatic Matrix, Dental Implants, Xenograft, Osstell, Piezotome, Sinus Lift, Centrifuge

Abstract

Objectives: Mineralized plasmatic matrix is reported to improve the quality of the bone/fibrin mixture, creating a stable and easy to handle homogeneous material. However, few studies evaluate the use of the mineralized plasmatic matrix during sinus lift with the simultaneous placement of dental implants.

Purpose: This study evaluated the efficiency or not of MPM compared to the xenograft bone grafting in the maxillary sinus lift.

Patients and methods: This study was conducted randomly on patients selected for treatment with a total of sixteen lateral windows sinus lift with simultaneous implant placement. Their ages ranged between 20 and 60 years old. Participating patients were divided into two groups equally and randomly; The control group: eight sinus floor elevation was performed using simultaneous implant placement. As a grafting material, Xenograft was used. The study group: eight Sinus floor elevation was achieved with simultaneous implant placement. Xenograft has been used in the form of MPM as a grafting material. CBCT taken before and after sinus augmentation to measure bone volume and height after 1 week of baseline (T0), after 6 months (T1), and after 12 months of baseline (T0) (T2). The Osstell(PT) was used for assessment implant stability at implant insertion (PT0) as well as for loading visit (PT1).

Result: A significant difference was observed between the two groups in bone volume ($p=0.049$). No significant difference was observed between the two groups ($p=0.129$) in height of graft.

Conclusion: MPM eliminated the need for barrier membranes when a guided bone regeneration procedure is considered. The use of MPM as a grafting bone offered greater graft stability and handling.

Copy Right, IJAR, 2021,. All rights reserved.

Introduction:-

The augmentation of sinus floor has lately become an extensively accepted surgical procedure before implantation for improving the amount of bone volume before implant placement. Though the use of bone autogenously appear to be

Corresponding Author:- Hisham M. S. El Eryani

Address:- M.S.C, Degree of Oral and Maxillofacial Surgery, Faculty of Dentistry, Mansoura University, Egypt.

standard gold, greatly consideration has been compensated to the using substitutes for bone to incredulous site donor morbidity.⁽¹⁾

Nowadays, to facilitate dental implant insertion, sinus floor elevation is considered the standard gold procedure in the atrophic maxilla. However, the process of leftovers high prognostic, chronic sinus infection due to perforation of the membrane (Schneiderian) compromise in implant success and the stability of the augmented bone.⁽²⁾

Manysinus floor elevation techniques had been presented. Conservatively, sinus augmentation procedure is achieved either via transcresal approach (technique Summers') or by lateral method (a modified approach of Caldwell-Luc).⁽³⁾ To reduce complications and intra-operative time their technique minimally invasive antral membrane balloon elevation was established to reach improved outcomes with minimal trauma to the patient.⁽⁴⁾

The concentration (labeled matrix plasmatic mineralized [M.P.M]) improves the fibrin mixture/quality of the bone, creating easy and a stable handling material homogeneous. In addition, it activates expression of material biological compounds through the repair of tissue machinery of remodeling, chemotaxis, angiogenesis, osteogenesis, and cell proliferation.⁽⁵⁾

Graft materials have wide variety in both the stability of reconstruction and in the stability of the implants due to they are used of bone grafts in the maxillary sinus lift, revealed rates similar of success.⁽⁶⁾ The use of bone graft substitute during sinus augmentations, cause bone resorption, and repneumatization of the maxillary sinuses, which ultimately affect the long-term success of the implant.⁽⁷⁾

The stability of the graft is an important conditions for the success of the bone grafting. This stability is offered by the MPM compared to the bone substitute alone.⁽⁸⁾

This study can be used as a base to demonstrate the efficiency or not of the MPM compared to the classical bone grafting in sinus lift. Regarding definition of the MPM, the use of the particulate bone graft in implant dentistry has its limits.

Patients and Methods:-

Patients:-

This study was conducted randomly on patients selected for treatment with a total of sixteen lateral windows sinus lift with simultaneous implant placement. Their ages ranged between 20 and 60 years old. All patients received detailed oral and written information about the study, type of procedure, including the risks, benefits and alternative therapies and signed an informed consent form before any study procedures.

Patient grouping:

Participating patients were divided into two equal and random groups; control group and study group.

The control group:

Sinus floor elevation with simultaneous implant placement was achieved. As a grafting material, Xenograft was used.

The study group:

Sinus floor elevation with simultaneous implant placement was achieved. Xenograft was used as a grafting material in the form of MPM.

Methods:-

Surgical procedure:

Surgery was performed under local anesthesia (lidocaine 1:80,000 epinephrine). The modified approach of Caldwell-Luc was used to achieve admission to the cavity of sinus. The lateral wall of the maxilla was exposed with a full-thickness mucoperiosteal flap made with crestal incision was made using a no. 15 blade and two vertical incisions on the buccal side of the residual alveolar ridge mesially and distally. The lateral window size was determined by how many implant to be inserted with attention to diminish the size of the lateral window as possible. A bony window was then traced using a Piezo-surgical unit.

Firstly, bone was marked using tip end B S 5. This was followed by deepening of mark using SL1 tip. Cutting of bone was made until a very thin plate of buccal bone remained above the lining of the sinus. A dental handle mirror was then used to break the buccal plate remaining. The section fractured of bone was detached from the antral lining and effort ended to detach it from the lining of sinus membrane. The tip of SL2 was used to improve the bony window, This was followed by the SL3 tip to raise the lining in the vicinity of the bony window. The partially raised lining was then lifted to a greater extent using the BS4 and BS5 tips.⁽⁹⁾

MPM Preparation:

A total number of 10 ml of venous blood was drawn into two 9 ml vacutest tubes and immediately centrifuged at 2500 rpm for 12 min.⁽¹⁰⁾ Upon completion, a liquid yellow plasma on the top of the tube was seen separated from the erythrocyte at the bottom of the tube. The yellow part was then collected using a syringe, and added to a cup that contains the bone graft material. The whole material was then mixed for a few seconds to obtain the MPM. The obtained biphasic matrix was then cut into pieces, and introduced into sub-antral space as in the control group.

Suturing:

Non-resorbable suture material was used to accomplish a water tight, primary closure of the flap by using of mattress horizontal sutures occupied 5 mm far from the line of incision. In addition, another row of interrupted sutures was done 3 mm from the incision line to ensure hermetic seal.

Implant Stability:

Implant stability quotient (ISQ): numerical value (0–100) recorded immediately after implant insertion and expressing resonance frequency analysis (RFA). The Osstell® (PT) was used to evaluate the implant stability at the insertion of implant (PT0) as well as loading visit (PT1).

Radiographic Assessment :

Cone Beam Computed Tomography scans were conducted at the preoperative visit (T X), 1 week subsequent to sinus lift surgery (first line, T0), at six months after loading (T1), and six months after implant loading (T2). Scans for all patients were reserved by a Planmeca ProMax® three D unit* used imaging fixed parameter at each scanning. Altogether data of DICOM were formerly investigated used Planmeca Romexis® software®.

Results:-

This study was conducted on sixteen patients; fourteen females and two males, who met the inclusion criteria. Patients' age ranged from 20 to 60 years with a mean age of 44.63 ± 8.55 years of control group and 42.50 ± 11.35 in the study group. A total number of 16 sinus floor elevations were performed. Twenty-six dental implants were inserted simultaneously to replace sixteen missing first molars and eight missing second molars and two premolars. The control group included five sinus lift procedures made in four patients, with a mean age of 46.6 ± 10.8 years. In the study group, also five sinus lift procedures were performed for four patients with a mean age of 35.8 ± 9 years.

The control group included eight sinus lift procedures made in eight patients. In the study group, also sinus lift procedures were made in eight patients. The implant lengths used in all cases were 10, 11.5, and 13. The implant diameters were 3.5 mm (50%, five implants), 4 mm (40%, four implants), and 4.5 mm (10%, one implant).

Clinical Evaluation:

All implants were successfully Osseo-integrated indicating an overall survival rate of 100% throughout the entire follow-up period.

Implant Stability at T0:

For the control group, the ISQ values at T₀ ranged from 40 to 65 N/cm, with a mean value of 53.88 ± 7.55 . For the study group, the ISQ values at T₀ ranged from 51 to 68 N/cm with a mean value of 61.63 ± 7.37 N/cm. There was no statistically significant difference between the two groups.

Implant Stability at T1:

Implant stability was assessed after 6 months of implant insertion (T₆). For the control group: the ISQ values at T₆ ranged from 82 to 95, with a mean of 89.25 ± 4.65 . For the study group; the ISQ values at T₆ ranged from 82 to 95, with a mean of 87.75 ± 5.70 . There was no statistically significant difference between the two groups at T₆.

Discussion:-

This study hypothesized that the use of growth concentrated factors collective with a graft material of bone produce improved outcomes in terms of implant stability and the stability of graft volume when associated to the usage graft bone alone.

This study assessed the MPM efficacy used in augmentation of maxillary sinus for encouraging the formation of new bone. We similarly related MPM and xenograft bone in relations of changes in volume at different time-points, subsequently augmentation of sinus by CBCT scan. The study null hypothesis was that attendance would be an alteration in the formation of new bone among two groups.

The stability of implant maintaining and achieving are requisites for successful of a dental implants. The stability of implant can be defined as absence of the clinical mobility, which is also the definition suggests of osseointegration. Implant primary stability at assignment is a mechanical phenomenon that is associated with the quantity and quality of local bone, the type of implant placement and used technique. Implant secondary stability is the instability increase quality able to form bone and remodeling at the tissue interface/implant and the bone in the surrounding tissue.^(11,12)

Many studies have recognized that the ridge width and residual bone height appear to be the factor that mostly influence the survival rate of implant with sinus floor elevation by lateral techniques. In our study, all implants successfully displayed Osseo integrated; they were introduced into the maxilla in the posterior area with bone height ranging from 3-7 mm in the sub antral residual ridge.⁽¹³⁾

In this study stabilization of implant was achieved with the micro-threads of the implant neck and tapered profile. The design of implant appeared a relevant parameter as the implant stability is a parameter key for bone regeneration and osseointegration. Thus, the use of micro-threaded and tapered implant's is a simple choice and more secure than the use of implant that cylinder-type. In agreement with other research conducted by Pommer et al.¹⁴ and Degidi et al.¹⁵ Though, different profiles lead to the same outcomes, if used surgical procedure with the adequate careful.^(16,17)

All implants in both groups, in our study had ISQ ranging values ranging from 40 to 65 for the control group. In the study group, values ranged from 51 to 68 representing stability primary, which is essential for dental implant success.

Regarding the implant stability observed there was no statistically significant difference between the study and control groups at T0 & T1 ($P=0.057$, 0.573). There is statistically significant decrease in mean osstel from T0 to T1 among control and study groups

This finding is in contradiction with other studies reported in the literature. Stability is the most determining factor of implant success. Implant stability occurs as a result of the process of osseointegration, which depends on the healing potential of the patient as well as on the implant design and surface characteristics.^{18,19,20} This significant difference in implant stability was observed within the 6 months' period in both groups, which can be attributed to two factors; an increased degree of osseointegration of implants or increased maturation of the surrounding grafted bone. Both of these factors occur naturally with time.

MPM contains a considerable number of concentrated growth factors. Examples include EGF (Endothelial Growth Factor), TGF- β 1 (Transforming Growth Factor Beta 1) and PDGF (platelet-derived growth factor). These factors, among others, enhance the differentiation of osteogenic cells and to significantly induce a greater amount of newly formed bone.^{21,22}

Choukroun et al.²³ reported that when the graft material is used along with PRF, there was 30% decrease in the healing time needed before dental implant placement in sinus floor augmentation. The writers recognized this healing accelerated to the platelets growth factors and fibrin network. This describes the graft volume stability after loading in the control group compared to the study group.

The added bone above implant protrusion to the ridge residual was measured by adding IP to RBH ($BG = IP - RBH$) at T0. In the control group, it measures from 3.5 mm to 6.2, with a mean of 3.12 ± 0.94 mm. In the study group, it ranged from 3.3 to 5.8 mm with a mean of 4.26 ± 0.97 mm. It was observed a significant difference between the control and study groups ($P=0.031$).

Both height and volume were used to assess the stability of the bone graft material. It was because the volume be a misleading parameter as the relationship between the implant apex and the level of the sinus floor is obscure. In our study, stability of the bone gained in terms of height and volume was significantly impacted by time since all cases have demonstrated a significant reduction in bone volume by the end of the follow-up period. It was in accordance with other studies reported in the literature.^{24,25,26}

In our study when comparing the two groups, A significant difference was found at either T1 or T2 (P=0.02 and 0.007) in bone resorption, in agreement with other research conducted by Chanavaz²⁷ reported that maxillary sinus pneumatization is encouraged by the positive pressure formation within the sinus of maxillary due to breathing.

The xenograft and MPM in the current study, regarding the graft volume was calculated at T0. In the control group, it ranged from 2.01 to 4.89 cm³ with a mean of 4.91 ± 0.85 cm³. For the study group, it ranged from 2.34 to 5.21 cm³ with an average of 3.98 ± 0.87 cm³. It was observed a significant difference between the control and study groups (p=0.049), correspondingly. El Moheeb et al. reported that the possibility of raising that MPM induce the formation of new bone in procedures of sinus lifting when using as a grafted bone.²⁸

The xenograft granules display susceptible to growth factors, also tissue regeneration satisfactory effects on growth factor. Growth factors are unaffinitive to xenografts and xenogeneic bone graft materials resorb gradually.²⁹

The study by Umanjec-Korac et al.³⁰ report that maxillary sinus lifting with xenograft material showed 21% volume reduction when follow-up for 2-year in 29 patients. In another study by Sbordone et al.³¹ reported 39.2% volume reduction at 6-year follow-up when used autogenous bone as a graft material in augmentation of maxillary sinus. All these studies exhibiting higher resorption rates compared to our study however, observation/reentry periods longer compared to our flow up 1 year. The graft materials show resorption slowly over time that positioned in the sinus.

The study reported by Smolka et al.³¹ at 6 months follow up the percent average of autogenous bone volume reduction was 16% and at 1 year follow-up in the maxillary sinus lift show 19%. In the study reported by Johansson et al.³² Maxillary sinus augmentation shows 49.5% volume reduction with autogenous bone graft. Unpredictable resorption rate of xenograft bone in hard tissue augmentation as bone graft.

The study by Lee et al.³³ reported that the use of fibrin-enriched platelet glue, a comparable preparation to MPM, results in amount of bone gain statistically significant. An outcome that is in conflict with the results of this study. The reason is unclear but is the use of autogenous bone in Lee et al.'s study, which has osteogenic and osteoconductive potential.

For successful guided bone regeneration, The use of a barrier membrane to cover the bone window of the lateral approach of the sinus lift procedure has been traditionally used to aid in the prevention of graft displacement as well as to prevent soft tissue invasion into the graft material.³⁴ This situation is not the same when MPM is used. The fibrin content of the MPM appears to enclose the graft particles, prevents the invasion of soft tissues, and at the same time prevents the displacement of the graft particles.

MPM reduced dispersion of the bone graft particles, which may act as an aid in reducing the amount of the needed bone graft. The absence of collagen membrane reduce the cost of the grafting procedures.

Figures Tription:

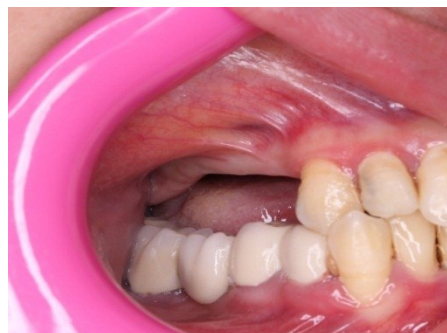

Fig.1:-

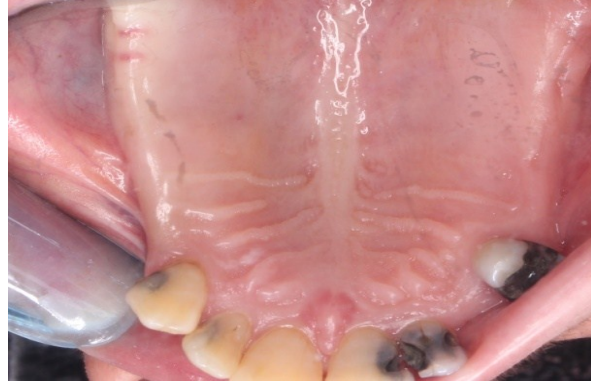

Fig. 2:-

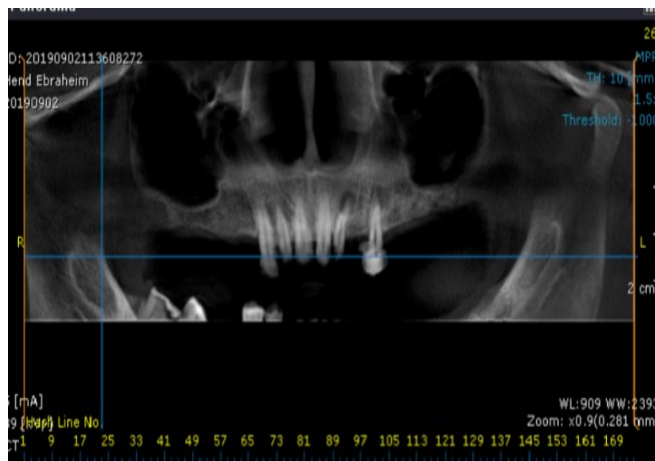


Fig.3:-

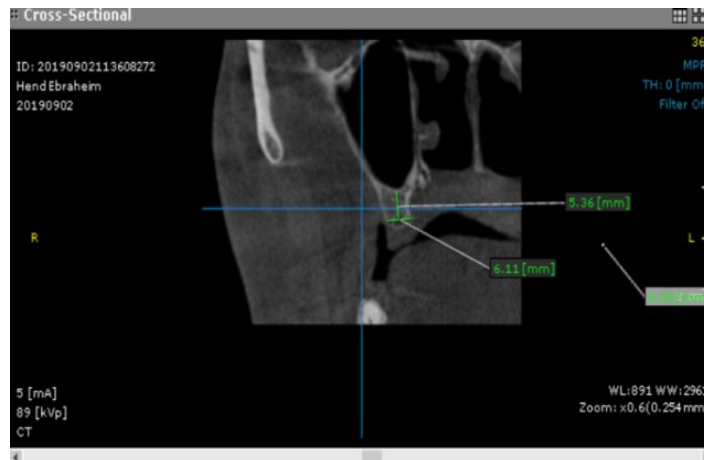


Fig.4:-

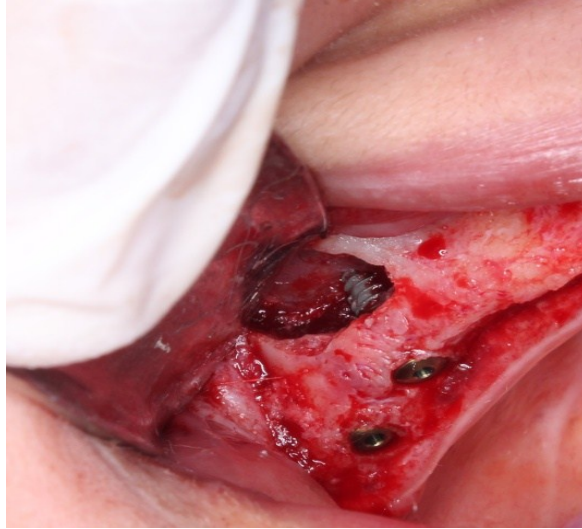


Fig.5:-

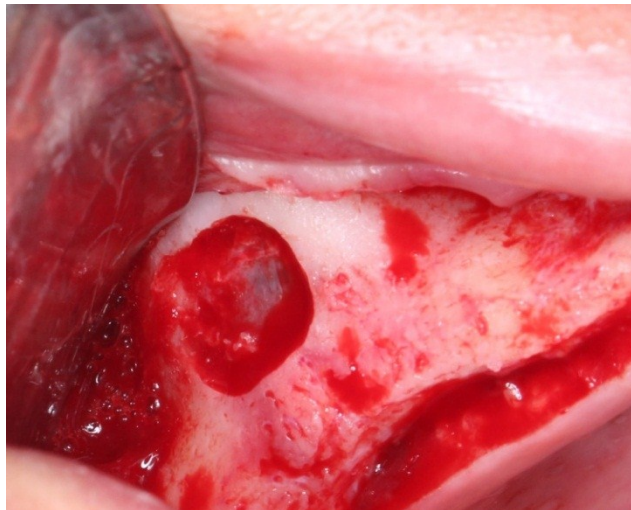


Fig.6:-

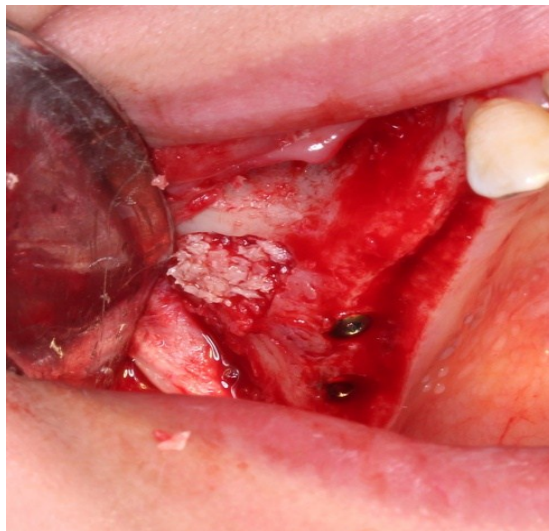


Fig.7:-

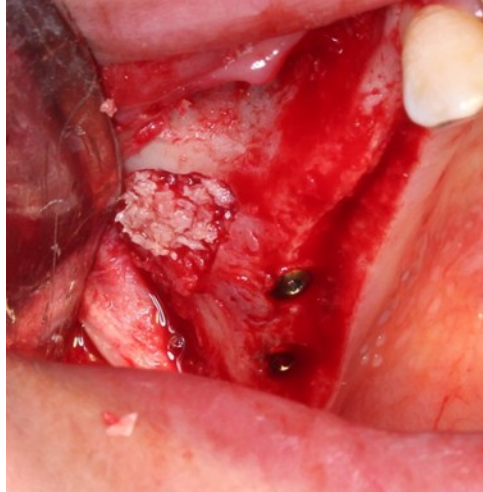


Fig.8:-

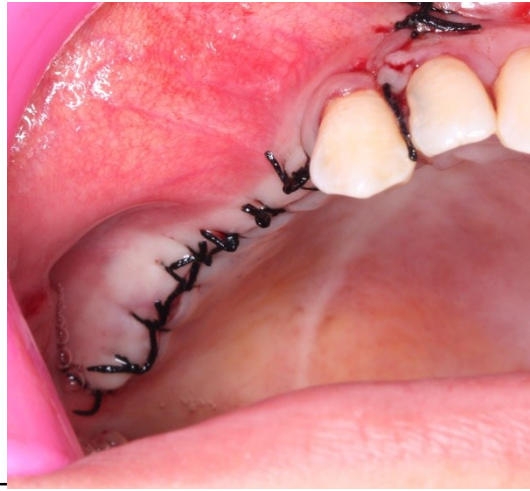

Fig.9:-

Figure (1) Preoperative a Photograph showing the missing 6,**Figure (2)** A Photograph showing during occlusion,**Figure (3)** Preoperative radiograph showing the missing 6,**Figure (4)** Preoperative radiograph showing the missing 6,**Figure (5)** A Photograph showing schneiderian membrane,**Figure (6)** A Photograph showing implant inside sinus,**Figure(7)** A Photograph showing implant in place,**Figure (8)** A Photograph showing completely filled with graft, and **Figure (9)** A Photograph showing free tension flap closure

Conclusion:-

MPM use as a grafting bone offer greater graft stability, handling, cost-effective source of growth factors and is easy to prepare and simultaneous implant placement in cases with a reduced residual bone height of 3mm can be successfully performed without significant impact on the implant survival rate.

Recommendation:-

A larger sample and a longer follow up period.

Reference:-

1. Canullo L. Sinus lift surgery in severely resorbed maxillae : One-year follow-up. J Oral Science Rehabilitation 2018;4(1):08–14.
2. Nolan PJ., Freeman K., Kraut RA. Correlation between schneiderian membrane perforation and sinus lift graft outcome: A retrospective evaluation of 359 augmented sinus. Journal of Oral and Maxillofacial Surgery 2014;72(1):47–52.
3. Sakkas A., Konstantinidis I., Winter K., Schramm A., Wilde F. Effect of Schneiderian membrane perforation on

- sinus lift graft outcome using two different donor sites: a retrospective study of 105 maxillary sinus elevation procedures. *GMS Interdisciplinary Plastic and Reconstructive Surgery DGPW* 2016;5(2):1-9.
4. Asmael HM. Is antral membrane balloon elevation truly minimally invasive technique in sinus floor elevation surgery? A systematic review. *International Journal of Implant Dentistry* 2018;4(1):12.
 5. González-Sánchez JG., Jiménez-Barragán K. [Closure of recurrent cleft palate fistulas with plasma rich in growth factors]. *Acta Otorrinolaringologica Espanola* 2011;62(6):448-53.
 6. Xavier S., Silva E., Kahn A., Chaushu L., Chaushu G. Maxillary Sinus Grafting with Autograft Versus Fresh-Frozen Allograft: A Split-Mouth Evaluation of Bone Volume Dynamics. *The International Journal of Oral & Maxillofacial Implants* 2015;30(5):1137-42.
 7. Salem D., Alshihri A., Arguello E., Jung R., Mohamed H., Friedland B. Volumetric Analysis of Allogenic and Xenogenic Bone Substitutes Used in Maxillary Sinus Augmentations Utilizing Cone Beam CT: A Prospective Randomized Pilot Study. *The International Journal of Oral & Maxillofacial Implants* 2019;21:67-78.
 8. Siada, Abeer, Mohammad Khursheed, Moheb, Mohamad EL, Patil S., Sghaireen MG., Brad B., Mizohata A., Alam., Osuga N., et al. Mineralized Plasmatic Matrix to Enhance the Bone Grafting Technique. *Journal of Hard Tissue Biology* 2017;26(3):289-92.
 9. Purushotham S., Raveendran AM., Kripalani BK., D'Souza ML. Direct Sinus Lift and Immediate Implant Placement Using Piezosurgical Approach- A Case Report. *Journal of Clinical and Diagnostic Research : JCDR* 2016;10:20-2.
 10. Dhurat R., Suresh M. Principles and methods of preparation of platelet-rich plasma: A review and author's perspective. *Journal of Cutaneous and Aesthetic Surgery* 2014;7(4):189.
 11. Rodrigo D., Aracil L., Martin C., Sanz M. Diagnosis of implant stability and its impact on implant survival: A prospective case series study. *Clinical Oral Implants Research* 2010;21(3):255-61.
 12. Han CH., Mangano F., Mortellaro C., Park KB. Immediate loading of tapered implants placed in postextraction sockets and healed sites. *Journal of Craniofacial Surgery* 2016;27(5):1220-7.
 13. Fuerst G., Tangl S., Gruber R., Gahleitner A., Sanroman F., Watzek G. Bone formation following sinus grafting with autogenous bone-derived cells and bovine bone mineral in minipigs: Preliminary findings. *Clinical Oral Implants Research* 2004;15(6):733-40.
 14. Pommer B., Hof M., Fädler A., Gahleitner A., Watzek G., Watzak G. Primary implant stability in the atrophic sinus floor of human cadaver maxillae: Impact of residual ridge height, bone density, and implant diameter. *Clinical Oral Implants Research* 2014;25(2).
 15. Degidi M., Daprile G., Piattelli A. Primary Stability Determination of Implants Inserted in Sinus Augmented Sites: 1-Step Versus 2-Step Procedure. *Implant Dentistry* 2013;22(5):530-3.
 16. Turkyilmaz I., Tumer C., Ozbek EN., Tözüm TF. Relations between the bone density values from computerized tomography, and implant stability parameters: a clinical study of 230 regular platform implants. *Journal of Clinical Periodontology* 2007;34(8):716-22.
 17. Youssef M., Shaaban AM., Eldibany R. the Correlation Between Bone Density and Implant Stability. *Alexandria Dental Journal* 2015;40(1):15-21.
 18. Sivan-Gildor A., Machtei EE., Gabay E., Frankenthal S., Levin L., Suzuki M., et al. Novel Implant Design Improves Implant Survival in Multitrooted Extraction Sites: A Preclinical Pilot Study. *Journal of Periodontology* 2014;85(10):1458-63.
 19. Freitas GP., Lopes HB., Martins-Neto EC., De Oliveira PT., Beloti MM., Rosa AL. Effect of surface nanotopography on bone response to titanium implant. *Journal of Oral Implantology* 2016;42(3):240-7.
 20. Degidi M., Daprile G., Piattelli A. Primary Stability Determination of Implants Inserted in Sinus Augmented Sites: 1-Step Versus 2-Step Procedure. *Implant Dentistry* 2013;22(5):530-3.
 21. Vahabi S., Vaziri S., Torshabi M., Rezaei Esfahrood Z. Effects of Plasma Rich in Growth Factors and Platelet-Rich Fibrin on Proliferation and Viability of Human Gingival Fibroblasts. *Journal of Dentistry (Tehran, Iran)* 2015;12(7):504-12.
 22. Garcia R V., Gabrielli MAC., Hochuli-Vieira E., Spolidorio LC., Filho JGP., Neto FAD., et al. Effect of platelet-rich plasma on peri-implant bone repair: a histologic study in dogs. *The Journal of Oral Implantology* 2010;36(4):281-90.
 23. Choukroun J., Diss A., Simonpieri A., Girard MO., Schoeffler C., Dohan SL., et al. Platelet-rich fibrin (PRF): A second-generation platelet concentrate. Part V: Histologic evaluations of PRF effects on bone allograft maturation in sinus lift. *Oral Surgery, Oral Medicine, Oral Pathology, Oral Radiology and Endodontology* 2006;101(3):299-303.
 24. Mardinger O., Chaushu G., Sigalov S., Herzberg R., Shlomi B., Schwartz-Arad D. Factors affecting changes in sinus graft height between and above the placed implants. *Oral Surgery, Oral Medicine, Oral Pathology, Oral Radiology and Endodontology* 2011;111(1):6-11.

25. Cha JK., Kim C., Pae HC., Lee JS., Jung UW., Choi SH. Maxillary sinus augmentation using biphasic calcium phosphate: Dimensional stability results after 3-6 years. *Journal of Periodontal and Implant Science* 2019;49(1):47–57.
26. Cinar IC., Gultekin BA., Saglanmak A., Yalcin S., Olgac V., Mijiritsky E. Histologic, Histomorphometric, and Clinical Analysis of the Effects of Growth Factors in a Fibrin Network Used in Maxillary Sinus Augmentation. *International Journal of Environmental Research and Public Health* 2020;17(6):1918.
27. Chanavaz M. Maxillary sinus: anatomy, physiology, surgery, and bone grafting related to implantology--eleven years of surgical experience (1979-1990). *J Oral Implantol.*
28. Cinar IC., Gultekin BA., Saglanmak A., Yalcin S., Olgac V., Mijiritsky E. Histologic, Histomorphometric, and Clinical Analysis of the Effects of Growth Factors in a Fibrin Network Used in Maxillary Sinus Augmentation. *Int J Environ Res Public Health* 2020;17(6):1918.
29. Luvizuto ER., Tangl S., Dobsak T., Reich K., Gruber R., Sonoda CK., et al. Effect of recombinant PDGF-BB on bone formation in the presence of β -tricalcium phosphate and bovine bone mineral matrix: A pilot study in rat calvarial defects. *BMC Oral Health* 2016;16(1):1–7.
30. Umanjec-Korac S., Wu G., Hassan B., Liu Y., Wismeijer D. A retrospective analysis of the resorption rate of deproteinized bovine bone as maxillary sinus graft material on cone beam computed tomography. *Clinical Oral Implants Research* 2014;25(7):781–5.
31. Smolka W., Eggensperger N., Carollo V., Ozdoba C., Iizuka T. Changes in the volume and density of calvarial split bone grafts after alveolar ridge augmentation. *Clinical Oral Implants Research* 2006;17(2):149–55.
32. Johansson B., Grepe A., Wannfors K., Hirsch JM. A clinical study of changes in the volume of bone grafts in the atrophic maxilla. *Dentomaxillofacial Radiology* 2001;30(3):157–61.
33. Sohn DS., Lee JS., Ahn MR., Shin HI. New bone formation in the maxillary sinus without bone grafts. *Implant Dentistry* 2008;17(3):321–31.
34. Rivara F., Negri M., Lumetti S., Parisi L., Toffoli A., Calciolari E., et al. Maxillary sinus floor augmentation using an equine-derived graft material: Preliminary results in 17 patients. *BioMed Research International* 2017;2017:9164156.