



Journal Homepage: - [www.journalijar.com](http://www.journalijar.com)

## INTERNATIONAL JOURNAL OF ADVANCED RESEARCH (IJAR)

Article DOI: 10.21474/IJAR01/14159

DOI URL: <http://dx.doi.org/10.21474/IJAR01/14159>



### RESEARCH ARTICLE

#### TRAUMATIC OPTIC NEUROPATHY

**Kamelia Rifai, Ennejjar Amine, Salma Moutamani and Lalla Ouafa Cherkaoui**  
Department A of Ophthalmology, Mohammed V University Souissi, Rabat, Morocco.

#### Manuscript Info

##### Manuscript History

Received: 30 November 2021

Final Accepted: 31 December 2021

Published: January 2022

##### Key words:-

Optic Nerve, Injury, Atrophy

#### Abstract

Copy Right, IJAR, 2022,. All rights reserved.

#### Introduction:-

Visual disturbances in head trauma patients are often a source of complaint expressed by patients; about 5% of them have an identified lesion on the visual pathways [1] and 0.5 to 2% suffer from posttraumatic optic neuropathy [2]. This incidence is higher in facial trauma, ranging from 2.5 to 10%, especially in cases associated with fracture of the facial bone [3].

Optic atrophy is a pathological term referring to optic nerve shrinkage caused by the degeneration of retinal ganglion cell axons.

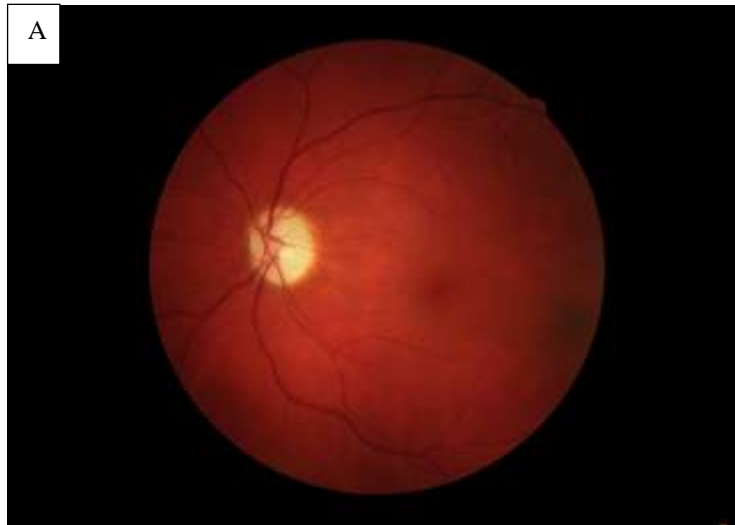
We report the case of a 17-year-old child, translated in emergency after having been the victim of an indirect contusion by a wooden stick on his right eye. This child had no particular history. Ophthalmological examination five hours from the injury revealed negative light perception in his right eye with areflexic mydriasis. The fundus was unremarkable with a normal appearance of the papilla. Complementary examinations carried out in emergency included a CT scan which showed thickening of the optic nerve without fracture of the orbital frame or of the optic canal, without retrobulbar hemorrhage, or foreign body. He will quickly provide a bolus of solumedrol at a dose of 30mg/kg for three days. We did not obtain visual improvement despite corticosteroids. An MRI was performed eight days after the trauma and revealed a continuous optic nerve with an overall increased volume. The visual evoked potentials (VEPs) were flat on the right, and the optic nerve became pale at one month (A).

The forces of the shock can create compression and contusion of the optic nerve causing edema and ischemia in this inextensible sheath, moreover the optic nerve can be subject to micro-shearing at its entry into the optic canal. Blindness in indirect TON is due to ischemia and necrosis of the terminal intracranial portion and the intracanal portion of the optic nerve following trauma. Typically optic nerve atrophy will develop within 4 to 6 weeks. [4,5]

Post-traumatic optic neuropathy can be the origin of a profound loss of visual acuity, which especially since it was initially important. Any treatment of traumatic optic neuropathies has not been the subject of a consensus. Whatever the treatment achieved, when the initial visual acuity has collapsed, visual recovery is often very poor, which can have important consequences on the professional life or personal of patients.

**Corresponding Author:- Kamelia Rifai**

Address:- Department A of Ophthalmology, Mohammed V University Souissi, Rabat, Morocco.



**Figure 1:-** A) Optic disc atrophy.

**References:-**

1. Sabates NR, Gonce MA, Farris BK. Neuro-ophthalmological findings in closed head trauma. *J Clin Neuroophthalmol* 1991;11:273—7.
2. Steinsapir KD, Goldberg RA. Traumatic optic neuropathy. *Surv Ophthalmol* 1994;38:487—518.
3. Anderson RL, Panje WR, Gross CE. Optic nerve blindness following blunt forehead trauma. *Ophthalmology* 1982;89: 445—55.
4. Anderson RL, Panje WR, Gross CE. Optic nerve blindness following blunt forehead trauma. *Ophthalmology* 1982; 89: 445—455.
5. Steinsapir KD, Goldberg RA. Traumatic optic neuropathy. *Surv Ophthalmol.* 1994;38:487—518.