



Journal Homepage: - www.journalijar.com

INTERNATIONAL JOURNAL OF ADVANCED RESEARCH (IJAR)

Article DOI: 10.21474/IJAR01/14421

DOI URL: <http://dx.doi.org/10.21474/IJAR01/14421>



RESEARCH ARTICLE

ROLE OF FIBEROPTIC BRONCHOSCOPY IN SPUTUM NEGATIVE PATIENTS

Rachit Sharma, Rajendra Prasad, Rishabh Kacker, Tasleem Raza and Amit Srivastava

Manuscript Info

Manuscript History

Received: 18 January 2022

Final Accepted: 20 February 2022

Published: March 2022

Abstract

Background: Tuberculosis continues to be the one of the most common global health problems for more than a century. Fiberoptic bronchoscopy may be very useful in diagnosing cases who have no sputum or whose sputum smear is negative for Acid-Fast bacilli. The current study aims to assess the role of fiberoptic bronchoscopy in sputum smear negative under NTEP and radiologically suspected cases of pulmonary tuberculosis.

Methods: This study was conducted in our institution in clinico-radiological suspected cases of pulmonary tuberculosis patients in whom two sputum smear for acid fast bacilli by Zeihl-Neelsen stain under NTEP was negative. Fiberoptic bronchoscopy was performed in all these patients and samples taken were sent for investigations.

Result: Fiberoptic bronchoscopy was performed in a total of 110 patients of presumptive pulmonary tuberculosis whose sputum for AFB smear was negative. Out of 110 patients, 65.45% were male and 35.55% were female. Fever was the most common presenting symptom and was found in 93.64% patients. Radiographically, pulmonary consolidation was bilateral in 63.34% cases while was unilateral in 36.36% cases. The total yield of FOB came out to be 59.1% in which BAL for AFB smear was positive in 43.63% cases, BAL for Mtb culture was positive in 54.54% cases while, BAL for PCR was found to be positive in 59.09% cases.

Conclusion: Fiberoptic bronchoscopy may be useful in rapid diagnosis and early treatment initiation thereby, reducing the risk of transmission of the disease. The findings of the study indicated that fiberoptic bronchoscopy is a useful method to diagnose the cases of sputum negative radiologically suspected symptomatic patients of tuberculosis.

Copy Right, IJAR, 2022,. All rights reserved.

Introduction:-

Tuberculosis continues to be the one of the most common global health problems for more than a century. It remains one of the world's leading causes of adult morbidity and mortality resulting in an estimated 10 million incident cases and 1.5 million deaths from the disease in the year 2020, thus showing an incremental trend despite systemic efforts to curb and control the disease.¹In 2020, thirty high burden countries accounted for 86% of new TB cases, with India leading the count.¹TB remains a major health problem in India, with the country accounting for nearly 26% of all TB cases reported globally. In 2021, out of the estimated global incidence of 10 million cases 2.64 million cases were estimated to have occurred in India.¹Early detection, proper treatment and controlling the drug-compliance are the key to success for controlling tuberculosis.²Unfortunately, most of the high burden countries are have poor

infrastructure for the diagnosis of infectious diseases owing to inadequacy of resources. The only diagnostic technique for TB, suitable to peripheral levels of health services, is serial sputum smear microscopy with ZiehlNeelsen (ZN) staining³. Sputum smear microscopy is not only time consuming but has also shown a high false negative rate ranging from 16 to 50% despite the clinical profile and radiological lesions being consistent with diagnosis of pulmonary tuberculosis⁴. Attempts to improve the quality of sputum smear examination have been made from time to time but did not reveal any significant improvement in false positivity as well as false negativity rate despite increasing the complexity of investigational procedures.⁵⁻⁷ In the event of negative-sputum in presence of symptoms, it is essential that the diagnostic tool is sensitive enough to provide an accurate diagnosis within a reasonable time. There are alternative approaches like culture sensitivity, however, AFB culture takes around 4-6 weeks, and during this time a false negative patient remains without treatment and thus increases the chance of spread of disease in the community. Anti-tuberculosis treatment (ATT) is frequently started empirically, leading many a time to avoidable risk of drug toxicity, and infructuous expenditure. Diseases like bronchogenic carcinoma and diffuse lung diseases are sometimes missed because cases are put within the grey area of "presumptive tuberculosis". On the other hand, if not treated, 64% of sputum negative suspects could need chemotherapy within 12 months⁸.

Various methods have been employed to ascertain active TB disease in patients with presumptive sputum negative tuberculosis which includes sputum induction with hypertonic saline, gastric lavage, bronchoscopic procedures such as bronchial aspirate/bronchoalveolar lavage (BAL)/brushing/biopsy and post bronchoscopy sputum. Among various alternative methods, use of fiber-optic bronchoscope (FOB) is one of the most widely studied alternative diagnostic approach among sputum negative patients.⁹⁻¹² The FOB facilitates rapid diagnosis and offers the additional advantage of the diagnosis of several conditions that may mimic PTB. However, FOB is an invasive procedure, and is associated with the risk of transmission of tuberculosis (TB) and other infections. It is costly, and is not widely available in the developing countries. In developed countries with no limitations on resources, early FOB seems to be the best course of action in a patient with suspected SSN-PTB. With the changing economic scenario and availability of fiber-optic bronchoscope facilities in developing countries, the picture is changing fast, hence it is essential that its utility in smear negative situations must be evaluated in our settings. The present study is an attempt in that direction.

Methods:-

This prospective observational study was conducted in Era's Lucknow Medical College and Hospital, Lucknow, Uttar Pradesh from June 2015 to December 2016. All presumptive cases of Pulmonary tuberculosis attending the pulmonary OPD and those admitted in the chest ward with following inclusion and exclusion criteria were included in the study.

Patients aged 18 years or more, with clinic-radiological suspicion of pulmonary TB and in whom sputum was negative for acid fast bacilli on two samples under NTEP or in whom sputum was either not produced or was inadequate for examination were included in the study. Patients younger than 18 years of age, with bleeding diathesis, history of myocardial infarction or arrhythmias, history of anti-tubercular treatment for more than one month and patients who were hemodynamically unstable were excluded from the study.

Procedure:-

All patients who gave an informed written consent and fulfilled the inclusion criteria, were subjected to bronchoscopy. Patients were kept nil orally for 8 hours prior to bronchoscopy, which was carried out under local anesthesia and a thorough examination of the bronchial tree was done. BAL was obtained from the radiographically suspected areas/segments in all the patients. BAL obtained was sent for AFB smear by ZN stain method, MTB culture (LJ Medium) and PCR.

Patient was kept under observation for 2 hours after the procedure to watch for any complications and was asked to keep nil orally for 2 hours post procedure.

Results:-

Fiberoptic bronchoscopy was performed in a total of 110 patients of presumptive pulmonary tuberculosis whose sputum for AFB smear was negative. Out of 110 patients, 72(65.45%) were male and 38(35.55%) were females (Table 1). The mean age of the patients was 39.78±16.31 years. Most common age group was 21-30 years (22.73%)

followed by 41-50 years (20.91%), while the least common age group were 61-70 years and >70 years (4.55%) each (Table 2). Out of 110 patients included in the study, only 24 (21.82%) had positive contact history while rest 86 (78.18%) had no contact history (Table 3). Fever was the most common presenting symptom and was found in 103 (93.64%) patients followed by cough which was present in 88 (80%) patients (Table 4). Radiographically pulmonary consolidation was bilateral in 70 (63.64%) cases while in rest it was unilateral 40 (36.36%) cases (Table 5). Congestion and hyperaemia (38%) were the most common bronchoscopic findings followed by mucopurulent/mucoid secretions (34%). Out of a total of 110 sputum negative patients enrolled in the study, a total of 65 (59.1%) turned out to be positive after fiberoptic bronchoscopy. BAL for AFB smear was positive in 43.63% cases, BAL for MTB culture was positive in 54.54% cases while BAL for PCR was found to be positive in 59.09% cases (Table 6). The sensitivity of different measures ranged from 73.8% (AFB) to 100% (PCR). All the measures had 100% specificity and 100% positive predictive value. The negative predictive value of different measures ranged from 72.6% (AFB) to 100% (PCR) (Table 7).

Table 1:- Gender of Study Population.

Gender	Number of patients	Percentage
Female	38	35.55
Male	72	65.45

Table 2:- Age Profile of Study Population.

Age Group	Number of patients	Percentage
Upto 20	16	14.55
21-30	25	22.73
31-40	19	17.27
41-50	23	20.91
51-60	17	15.45
61-70	5	4.55
>70	5	4.55
	110	100.00

Table 3:- Contact History in Study Population.

History of Contact	Number of patients	Percentage
No contact history	86	78.18
Positive contact history	24	21.82

Table 4:- Presenting Symptoms in Study Population.

Presenting Symptoms	Number of patients	Percentage
Fever	103	93.64
Cough	88	80.00

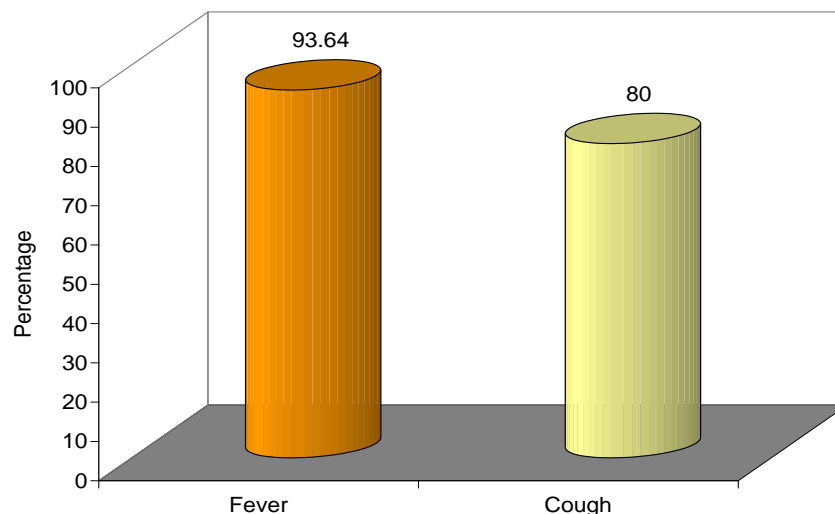


Table 5:- Pulmonary Consolidation in Study Population.

Consolidation	Number of patients	Percentage
Bilateral	70	63.64
Unilateral	40	36.36

Table 6:- BAL Fluid Analysis of Study Population.

	Negative		Positive	
	No.	%	No.	%
AFB	62	56.36	48	43.64
Culture sensitivity for MTB	50	45.45	60	54.55
PCR	45	40.91	65	59.09

Table 9:- Diagnostic Efficacy of different post-bronchoscopy diagnostic measures for diagnosis of tuberculosis.

Measure	Total Positive	Total Negative	Sensitivity	Specificity	PPV	NPV
BAL AFB	48	62	73.8	100	100	72.6
BAL C/S	60	50	92.3	100.0	100.0	90.0
BAL PCR	65	45	100	100	100	100

Discussion:-

Tuberculosis is one of the unresolved diseases that has remained untamed despite concerted efforts by health professionals throughout the world. Primary treatment of tuberculosis is sometimes started on symptomatic manifestation itself. Sputum smear positivity is the criteria for screening; however, it is often marred with false negativity^{4,13}. On the other hand there are a number of conditions including malignancy that often have clinical manifestations similar to tuberculosis and are clinically misdiagnosed as pulmonary tuberculosis¹⁴⁻¹⁶. In such a situation, a clinically suspected sputum negative tuberculosis patient needs further exploration for the underlying disease responsible for the clinical manifestation. In such a scenario advanced and confirmatory diagnostic methods like PCR and fiberoptic bronchoscopy play an instrumental role.

Hence the present study was planned to evaluate the role of fiberoptic bronchoscopy in sputum negative pulmonary tuberculosis cases.

The age profile of patients in present study matched to the previous studies that have conducted FOB for sputum negativity. In a study by Caymmiet al. (2004)¹⁷ the median age of patients was observed to be 39 years (range 19-77 years). The present study had maximum number of patients in 21-30 years age group (22.73%) whereas Jain et al. (2015)¹⁸ found maximum number of their cases to be aged 40-49 years (41.7%). These differences in age profile of patient might be incidental and as such except for role of intermediate reactors old age, no other association with age was seen. Majority of the cases enrolled in the study were males (65.45%), thus showing a male preponderance with a male to female ratio of 1.9:1. One of the reasons for this high male preponderance could be the gender-biased health services utilization pattern in a country like India where women most often fail to avail the services of formal healthcare system. The findings of present study seem to endorse the observations of Rhines (2013)¹⁹ who while commenting on the epidemiology of tuberculosis found that in some regions, cases among men exceed those found in women by a ratio of 2:1 and attributed this to underreporting and latent variables undoubtedly bias the observed differences in prevalence between males and females to some degree while at the same time also found that there is also strong evidence that sex-based differences in TB prevalence represent real epidemiological differences. In present study, a total of 21.82% patients had a positive contact history. Contact history is a high risk for tuberculosis positivity with a prevalence ranging from 4.7%-26.8% among smear-negative patients²⁰. The findings in present study were consistent with this observation. The symptomatic profile of the patients was dominated by presence of fever (93.64%) and cough (80%) – two of the primary symptomatic conditions of tuberculosis. In consonance with the inclusion criteria, chest X-ray findings indicated consolidation in all the cases of which majority (63.64%) had bilateral consolidation. These findings are suggestive of active tuberculosis as suggested by Joshi et al. (2012)²¹, however, in yet another study; Joshi et al. (2007)²² expressed doubts regarding the specificity of chest X-ray and were of the view that chest radiography for TB lacks specificity. Radiologic lesions suggestive of TB are also noticed in conditions such as histoplasmosis, tropical eosinophilia, pneumoconiosis, siderosis, sarcoidosis, ABPA, hypersensitivity pneumonitis and vasculitis. Hence, although the radiological picture corroborated the clinical diagnosis yet they cannot be considered confirmatory.

In present study too, we carried out BAL AFB assessment and found that 36 (43.64%) cases were positive whereas L-J medium confirmed the diagnosis of pulmonary tuberculosis in 54.55% cases. BAL AFB assessment is one of the useful modalities for confirming sputum negative tuberculosis as pulmonary tuberculosis as indicated in previous studies^{9,10,12,17,23,24,25,26} and findings of present study confirmed that. In present study, BAL fluid PCR assessment was most sensitive and provided a positivity rate of 59.09%. BAL PCR is a highly sensitive tool for assessment of sputum negative tuberculosis. In a study by Wong et al. (1998)²⁷ it was found to be 97.2% sensitive. However, specificity of PCR is often questioned. In present study, specificity of all the techniques could not be assessed as there was no definitive false positive criteria and the focus of evaluation was only on sensitivity of the technique.

In present study, in a total of 45 (40.91%) cases tuberculosis could not be confirmed even after fiberoptic bronchoscopy. There are many other conditions that mimic pulmonary tuberculosis. Sometimes conditions like, lung cancer can mimic the pulmonary tuberculosis which can also be diagnosed in fiberoptic bronchoscopy^{14,15,16} however, present study did not reveal malignancy in any of the cases. The presence of malignancy in sputum negative cases is rare, Quaiseret al. (2012)²⁸ found only 5% of their sputum smear negative pulmonary tuberculosis patients to have metastatic neoplasms. Jain et al. (2015)¹⁸ also found only 3.3% of their sputum negative PTB cases to be positive for lung cancer. A relatively higher rate of malignancy has only been reported by Wong et al. (1998)²⁷ who observed 8.95% of their sputum negative PTB cases to have lung cancer. In present study, remaining 45 cases were considered to be having pyogenic etiologies other than MTB. Other infectious etiologies mimicking tuberculosis are often seen in clinically suspected pulmonary tuberculosis cases. Infectious etiologies other than Mycobacterium tuberculosis have also been detected following bronchoscopy by Wong et al. (1998)²⁷, Caymmiet al. (2004)¹⁷ and Jain et al. (2015)¹⁸. A treatment response to antibiotic regimen in these cases confirmed this etiology.

In present study, through the help of fiberoptic bronchoscopy, confirmed diagnosis could be established in 65 out of 110 (59.09%). Thus, showing that bronchoscopy is useful modality for diagnosis in suspect cases. In present study, all the cases were radiologically positive. As already stated, radiological findings are often confusing and most of the time have a high rate of false positivity. The clinical suspicion in these cases was based on chest radiography findings and has been the reason for positive findings in all the cases. Owing to radiological consolidation being the inclusion criteria its assessment was based only on laterality but did not yield a significant association with the outcome. Also, in present study, the resistance pattern studied showed that 17.46% of patients diagnosed to be tuberculosis had resistance to one or more tubercular drugs. It is an issue of concern and shows that sputum negativity can deteriorate the condition of patient and can result in acquired resistance.

The findings in present study highlighted the usefulness of fiberoptic bronchoscopy in sputum negative pulmonary tuberculosis cases. However, we focused on the diagnosis of pulmonary tuberculosis only and ruled out diagnosis and confirmation of other conditions.

Conclusion:-

The diagnostic yield of fiberoptic bronchoscopy is determined by not only the indication of its use but also by the skills of the bronchoscopist as well as pathologist. In cases of clinical suspicion where expectoration is negligible or sputum is negative, fiberoptic bronchoscopy may be useful in rapid diagnosis and early treatment initiation thereby, reducing the risk of transmission of the disease. The findings of the study indicated that fiberoptic bronchoscopy is a useful method to diagnose the cases of sputum negative radiologically suspected symptomatic patients of tuberculosis. Among different measures used for diagnosing bronchoalveolar lavage, PCR was most sensitive. Keeping in view the high post-FOB positivity, it is recommended as a preferred diagnostic modality.

1. World Health Organization (WHO). Global tuberculosis report 2021. World Health Organization, Geneva, Switzerland, 2021.
2. Corbet EL, Watt CJ, Walker N, Maher D, Williams BG, et al. The growing burden of tuberculosis: global trends and interactions with the HIV epidemic. Archives of Internal Medicine 2003;163:1009–21.
3. Chandra TJ. Same day sputum smear microscopy approach for the diagnosis of pulmonary tuberculosis in a microscopy centre at Rajahmundry. Indian J Tuberc 2012; 59:141-44.
4. Kulpati DD, Heera HS. Diagnosis of smear negative pulmonary tuberculosis by flexible fibreoptic bronchoscopy. Indian J Tuberc. 1986;33:179–82.
5. Aber VR, Allen BW, Mutchison DA, Ayuma P, Edwards EA, Keyes AB. Quality control in tuberculosis bacteriology: I, laboratory studies on isolated positive cultures and the efficiency of direct smear examination. Tubercle. 1980;61:123–33

6. Fujiki A, Giango C, Endo S. Quality control of sputum smear examination in Cebu Province. *Int J Tuberc Lung Dis.* 2002;6:39-46.
7. Selvakumar N, Murthy BN, Prabhakaran E, Sivagamasundari S, Vasanthan S, et al. Lot Quality Assurance Sampling of Sputum Acid-Fast Bacillus Smears for Assessing Sputum Smear Microscopy Centers. *J. Clin. Microbiol.* 2005;43:913-15.
8. Jayaswal R., Panda B.N. and Debnatb J. Three short course chemotherapy regimens in Armed Forces - A comparison. *Lung India*, 1991;9:104.
9. Panda BN, Rajan KE, Jena J, Nema SK, Murali M, Patil AP. Diagnostic yield from flexible fiberoptic bronchoscopy in sputum negative pulmonary tuberculosis cases. *Ind. J. Tub.* 1995;42: 207-9.
10. Yüksekol I, Bal S, Ozkan M, Balkan A, Bedirhan I, Tozkoparan E, Demirci N, Seber O. The value of fiberoptic bronchoscopy in diagnosis of smear negative pulmonary tuberculosis. *TuberkToraks.* 2003;51:405-9.
11. Mohan A, Sharma SK. Fiberoptic Bronchoscopy in the Diagnosis of Sputum Smear-negative Pulmonary Tuberculosis: Current Status. *Indian J Chest Dis Allied Sci* 2008;50:67-78.
12. Kumar A, Gupta AK, Khan MH. Role of flexible fiberoptic bronchoscopy in suspected sputum smear negative pulmonary tuberculosis cases at microscopy centre under RNTCP. *Int J Med Sci Public Health.* 2014;3: 31-4.
13. Aderemi OK, Dada-Adegbola H. Epidemiology of Smear - Negative Tuberculosis in Ibadan, Nigeria. *Afr J Infect Dis.* 2013;7:14-7.
14. Bhatt MLB, Kant S, Bhaskar R. Pulmonary tuberculosis as differential diagnosis of lung cancer. *South Asian J Cancer.* 2012;1: 36-42.
15. Harikrishna J, Sukaveni V, Kumar DP, Mohan A. Cancer and tuberculosis. *JIACM* 2012;13:142-44.
16. Chen C-Y, Wang J-Y, Chien Y-C, Chen K-Y, Yu C-J, Yang P-C. Lung cancer mimicking pulmonary tuberculosis in a TB-endemic country: the role of early invasive diagnostic procedures. *Lung Cancer Management* 2015;4: 9-16.
17. Caymmi ALS, Silveira MAS, Montal G, Lemos ACM. The diagnostic role of fiberoptic bronchoscopy in cases of suspected pulmonary tuberculosis. *J. Bras. Pneum.* 2004;30:1-7.
18. Jain RK, Arun B, Paramjyothi G. Role of fiberoptic bronchoscopy in patients with sputum smear negative for acid fast bacilli and chest x-ray suggestive of pulmonary tuberculosis. *Journal of Evidence Based Medicine and Healthcare* 2015;2:155-64.
19. Rhines AS. The role of sex differences in the prevalence and transmission of tuberculosis. *Tuberculosis (Edinb).* 2013;93:104-7.
20. Rouillon A, Perdriet S, Parrot R. Transmission of tubercle bacilli: the effects of chemotherapy. *Tubercle* 1976; 57: 275-99.
21. Joshi A, Jajoo U, Taksande A, Pandit A. Efficacy of x-ray chest in the diagnosis of parenchymal pulmonary tuberculosis in symptomatic medical care seeking individuals. *J MGIMS* 2012;17: 23-36.
22. Joshi R, Patil S, Kalantri S, Schwartzman K, Menzies D, Pai M. Prevalence of Abnormal Radiological Findings in Health Care Workers with Latent Tuberculosis Infection and Correlations with T Cell Immune Response. *PLoS ONE.* 2007;2:e805.
23. Sohrabpour H, Masjedi M. The role of fiberoptic bronchoscopy in the diagnosis of pulmonary tuberculosis. *Medical Journal of The Islamic Republic of Iran* 1988;2:25-7.
24. Chan H.S., Sun H.M.A, Hoheisel G.B. Bronchoscopic aspiration and bronchoalveolar lavage in the diagnosis of sputum smear negative pulmonary tuberculosis. *Lung* 1990;168: 215-20.
25. Charoenratanakul S, Dejsomritrutai W, Chaiprasert A. Diagnostic role of fiberoptic bronchoscopy in suspected smear negative pulmonary tuberculosis. *Respiratory Medicine* 1995;89: 621-23.
26. Vijayan VK, Paramasivan CN, Sankaran K. Comparison of bronchoalveolar lavage fluid with sputum culture in the diagnosis of sputum smear negative pulmonary tuberculosis. *Ind. J. Tub.* 1996;43:179-82.
27. Wong CF, Yew WW, Chan CY, Au LY, Cheung SW, Cheng AF. Rapid diagnosis of smear-negative pulmonary tuberculosis via fiberoptic bronchoscopy: utility of polymerase chain reaction in bronchial aspirates as an adjunct to transbronchial biopsies. *Respiratory Medicine* 1998; 92:815-9.
28. Quaiser S, Agarwal A, Khan R, Haque SF. Fiberoptic bronchoscopy, as a valuable diagnostic option in sputum negative pulmonary tuberculosis: A prospective study. *Int J Appl Basic Med Res.* 2012;2:123-7.