



Journal Homepage: - www.journalijar.com

INTERNATIONAL JOURNAL OF ADVANCED RESEARCH (IJAR)

Article DOI: 10.21474/IJAR01/14592
DOI URL: <http://dx.doi.org/10.21474/IJAR01/14592>



RESEARCH ARTICLE

A COMPLETE LBBB REVEALING NON SPECIFIC VENOUS METASTASIS INTO THE RIGHT ATRIUM : A CASE REPORT AND REVIEW OF LITERATURE

EL Belidi Abir, Regragui Hind, Derquaoui Sabrine, Chahdi Hafsa and Mouine Najat

Manuscript Info

Manuscript History

Received: 25 February 2022

Final Accepted: 27 March 2022

Published: April 2022

Abstract

The primary heart tumors are rare, whereas metastatic heart tumors occur more frequently. We present a case of an asymptomatic 71-year-old man diagnosed with isolated right atrium metastasis of a poorly differentiated hepatic carcinoma by direct inferior vena cava invasion; the patient opted out of any intervention and was discharged under VKA. The prevalence of secondary cardiac tumors has been reported as 10 to 12% in autopsy studies. Clinically, cardiac metastasis usually remains asymptomatic and detected incidentally. The techniques mainly used in assessment of cardiac lesions include transthoracic and transoesophageal echocardiogram, CT scans and MRI. Treatment of metastatic cardiac tumor is usually palliative, because the overall prognosis is poor. A multidisciplinary approach involving cardiologists, oncologists, and cardiothoracic surgeons is crucial for deciding the best therapeutic regimen for such patients.

Copy Right, IJAR, 2022,. All rights reserved.

Introduction:-

The prevalence of secondary cardiac tumors has been reported as 10 to 12% in autopsy studies. (1) In general, metastatic heart tumors are asymptomatic. Although these metastases rarely grow in the heart cavity, they often lead to lethal complications, such as pulmonary embolism arrhythmias and obstruction of heart cavity inflow. The techniques mainly used in assessment of cardiac lesions include transthoracic and transoesophageal echocardiogram, CT scans and MRI. Treatment of metastatic cardiac tumor is usually palliative, because the overall prognosis is poor. The present report describes an unusual case of isolated metastasis of Hepatic carcinoma in the right atrium. In similar cases, treatment should be individualized to the patient, and a multidisciplinary approach, including surgery, radiotherapy, and chemotherapy, should be used.

Case report:

A 71 year-old man, smoker treated for type II diabetes, was referred to our university hospital by anesthesiology for cardiac exploration after discovering an unknown complete left bundle block in his EKG that was performed before cataract surgery.

The patient was haemodynamically stable and did not exhibit any signs of dyspnoea or pectoral angina. Cardiovascular examination revealed no irregularities regarding blood pressure (110/60mmHg), heart rate (56b.p.m.), respiratory rate (16 b.p.m.), oxygen saturation (SpO2 100%), heart sounds, and lung auscultation. There were no signs of peripheral oedema. There was no hepatomegaly.

Corresponding Author:- EL Belidi Abir

His electrocardiogram (EKG) at admission showed a complete left bundle branch block with a sinus rhythm and the chest X ray was normal.

A transthoracic echocardiography showed a 51 × 34mm fixed and hyperechoic mass filling nearly the entire right atrium, slightly calcified, and adhered to the lateral wall of RA, without extension into the outflow tract. Both left and right ventricular functions were preserved. The RV outflow tract was not compromised and the main pulmonary arteries including branches were mass free, and the pressure gradient over the tricuspid valve was not elevated. PAPs 27mmHg.

The transesophageal echocardiography showed, a large mass in the RA attached to the myocardium occupying almost the entire RA cavity with 2 other masses (thrombi) attached to the tumor, mobile with no invasion into tricuspid valve, otherwise the TTE didn't find any abnormalities in the left cavities or in the valves.

Laboratory tests conducted on venous blood sample showed a normal renal function. Liver function tests revealed elevated values: aspartate transaminase, 2415 U/l (normal range 0-50); alanine transaminase, 998 U/l (normal range 0-50); alkaline phosphatase 276 U/l (normal range 30-120); total bilirubin and direct bilirubin levels were slightly elevated.

The hemogram was unremarkable; the prothrombin time was normal. Cardiac markers were also slightly elevated: troponin I, 0.45 ng/ml (normal range 0-0.001); a-fetoprotein level was elevated 3025 ng/mL (normal range, <13.2 ng/ml).

CT scan of the thorax and abdomen revealed similar findings as the TTE, it showed a large mass within the right atrium with heterogeneous contrast enhancement. And an irregular hypodense hepatic mass interesting the segment VIII with invasion of the inferior vena cava. Thrombosis of the right kidney vein and inferior vena cava was also noted.

The case was discussed in our multidisciplinary tumor board and it was decided to administer palliative chemotherapy. However, the patient refused any treatment and was discharged under AVK, he expired due to cardiorespiratory failure after two months.

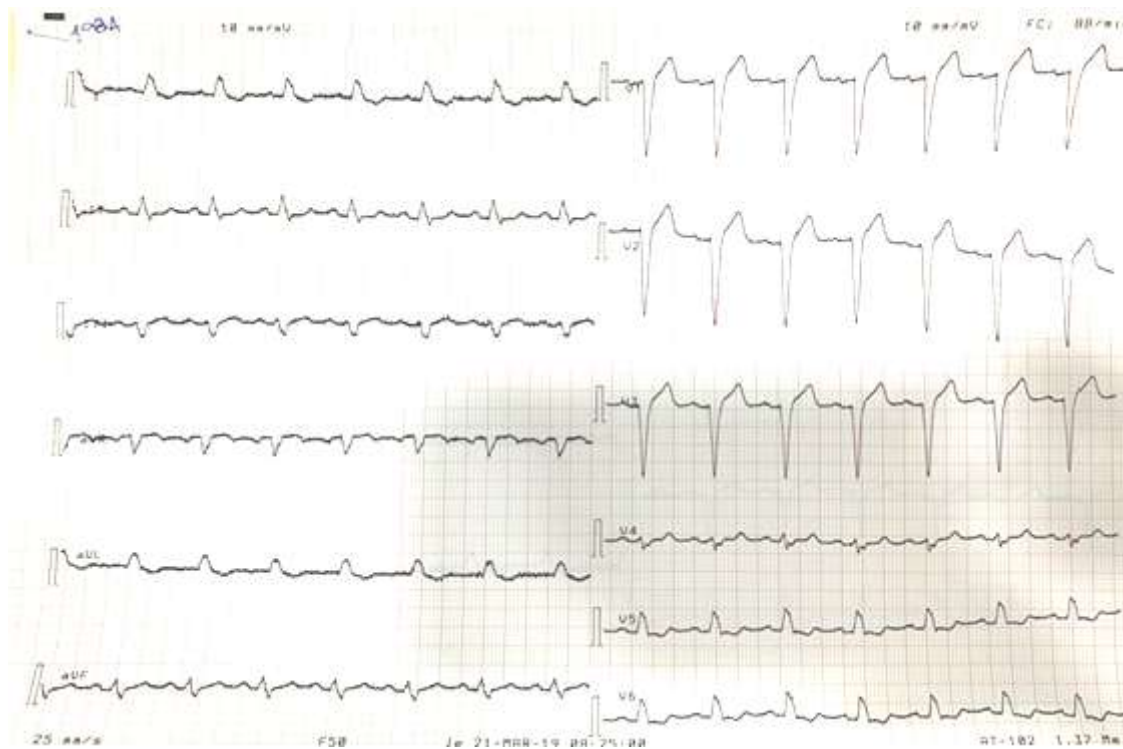


Figure 1:- Electrocardiogram showing a complet LBBB.

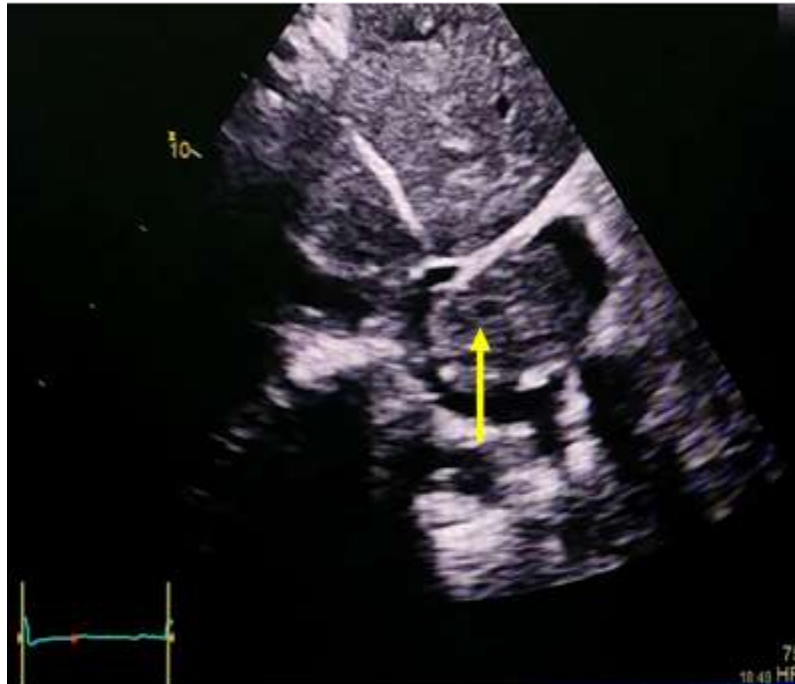

Figure 2:- Two-dimensional transthoracic echocardiography (subcostal view) showed an echodense mass in the right atrium (arrow).

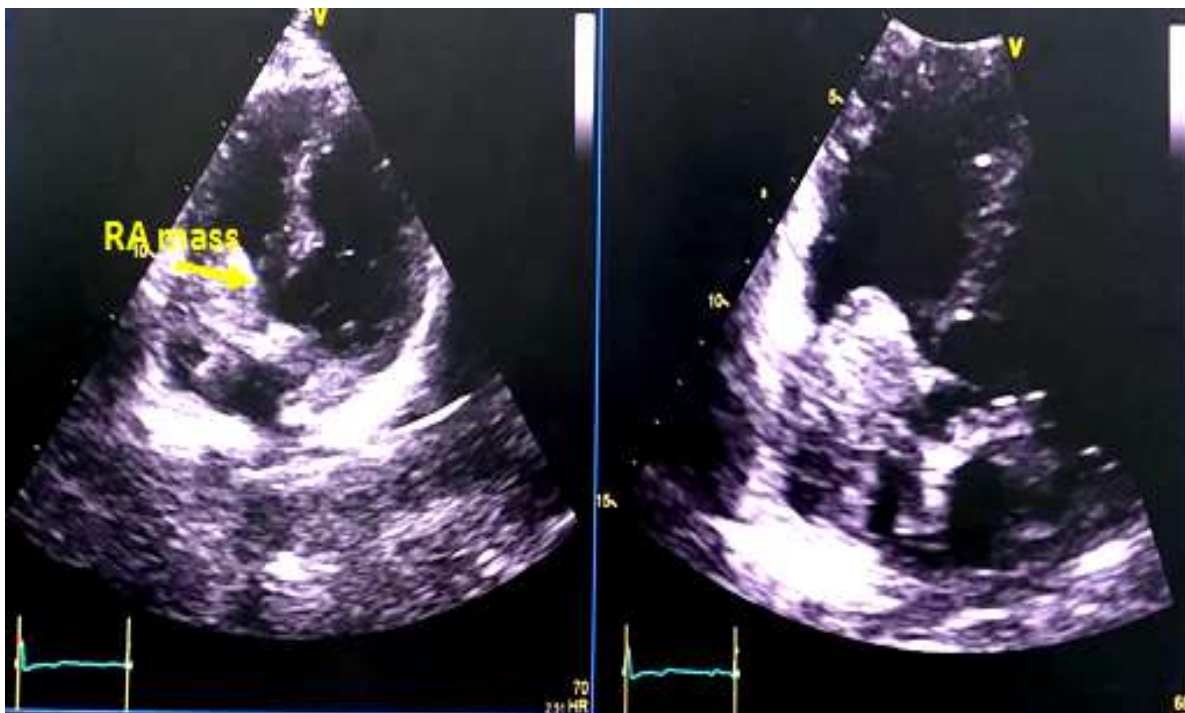


Figure 3:- Two-dimensional transthoracic echocardiography (apical 4-chamber view) showed an echodense mass in the right atrium (RA).

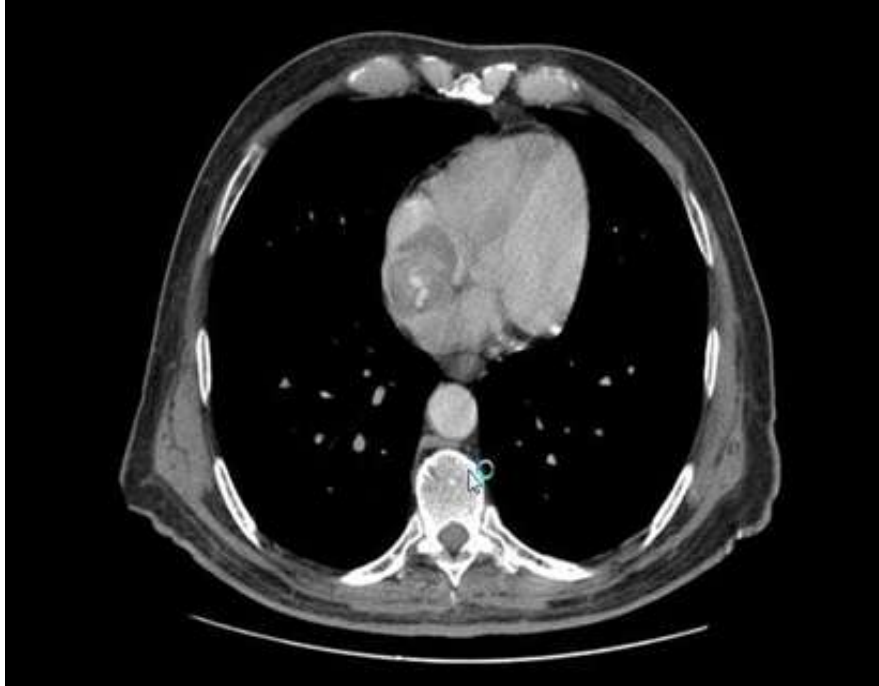

Figure 4:- Cardiac CT oblique five-chamber view in transverse section with horizontal long axis on Iode contrast demonstrating a large right atrial mass.

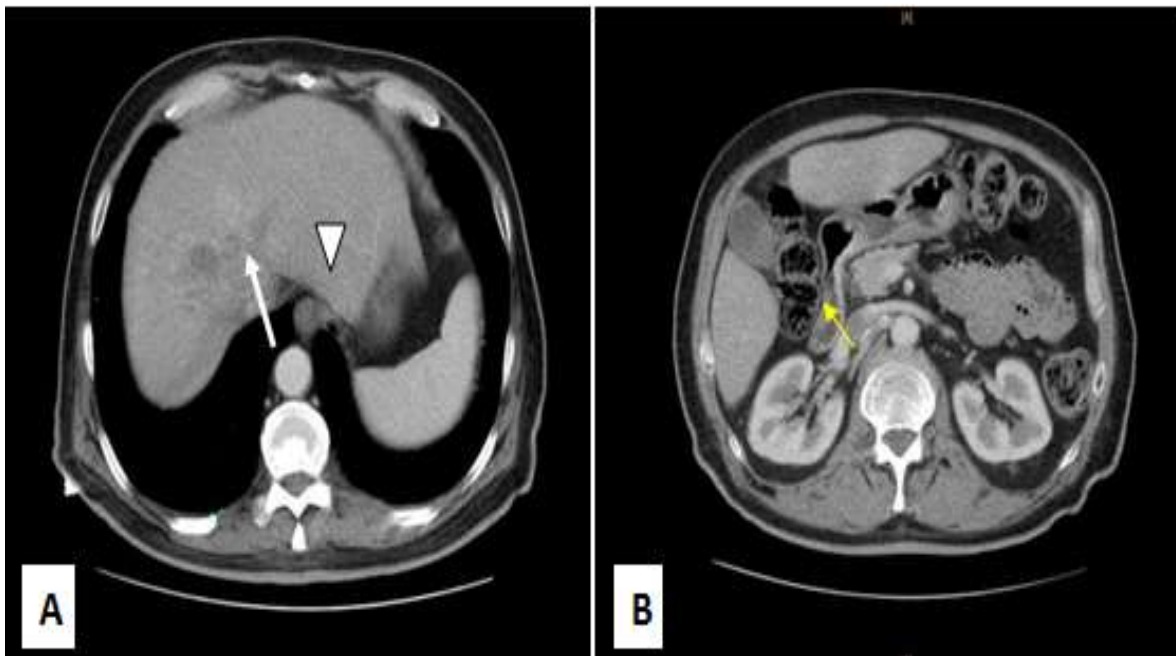


Figure 5:- CT scan of abdomen. Axial view. A: The arrow indicates an irregular hypodense hepatic mass with invasion of the inferior vena cava (arrowhead). B: Thrombosis of the right kidney vein was also noted.

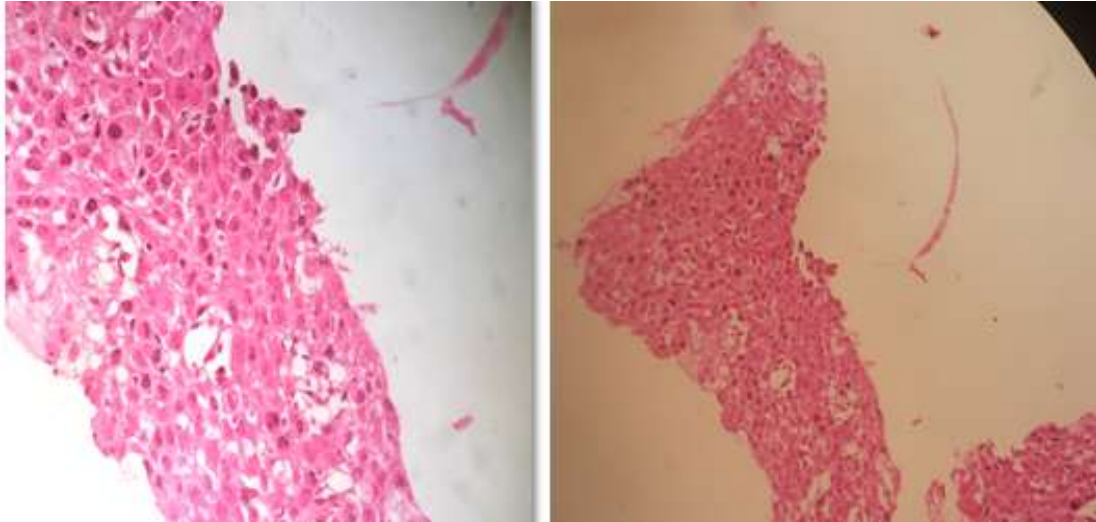


Figure 6:- Histopathology showed a poorly differentiated carcinomatous hepatic process.

Discussion:-

Secondary cardiac tumors occur in 10 to 12% of patients with malignant neoplasms in autopsy studies. [1]

However, Metastatic cells can reach the heart by four different pathways: lymphatic spread (lymphomas, leukemias and bronchogenic and breast carcinoma) hematogenous spread (malignant melanoma, sarcoma, bronchogenic tumor); contiguous extension usually from mediastinal tumors; (bronchogenic and breast carcinoma), or intracavitary extension from the inferior vena cava (carcinoma of the liver, kidney, leiomyoma. Sometimes, tumors also spread through the pulmonary veins. [2]

Metastatic lesions are preferentially located in the pericardium, In fact, pericardial or myocardial involvement depends on the preferential metastatic pathway, lymphatic or hematogenous, of the primary tumor. [3]

The more compatible mechanism involved of metastasis with the present case is a venous hematogenous pathway through the vena cava the right heart because of infiltration of the IVC.

The most common metastatic cardiac malignancy descending order of frequency is the bronchogenic cancers (up to 36% in some autopsy studies) lymphomas, leukemias, breast and esophagus cancer [4]

Clinically, cardiac metastasis usually remains asymptomatic and are usually detected incidentally as it was represented by our patient. And they can cause symptoms that reflect the site, the extension of the mass and the local complications. There can be arrhythmias, conduction abnormalities by invasion of the cardiac conduction system, pericardial effusion or myocardial infarction occasioned by coronary invasion, embolism or compression from tumor masses, intracavitary metastases of the right ventricle may lead also to pulmonary embolism. [5]

The techniques mainly used in assessment of cardiac lesions include transthoracic and transoesophageal echocardiogram, CT scans and MRI.

Transthoracic echocardiography represents the primary imaging modality for the assessment of intracardiac masses that can precise the anatomic location and the characteristics of the tumor (size, mobility, attachment) [6] and can screen for additional tumors and evaluate the physiologic consequences by dynamic assessment. transesophageal echocardiography shows them better, especially if the mass is located posteriorly.

In CT scanner, secondary cardiac masses are represented as a cardiac mass with heterogeneous contrast enhancement; the CT scan also provides high-quality images with superior spatial resolution for evaluation of the mass characteristics as calcifications (osteosarcoma metastasis) and for evaluation of relationship between the tumor and coronary arteries for surgical planning for the mass resection.

Differential diagnosis is broad and includes thrombus, vegetation, or primary tumors such as myxoma.

Magnetic resonance imaging is the preferred imaging modality because of overall better soft tissue contrast and the ability to characterize tumor infiltration and tumor type. [7] Secondary mass characteristics in MRA are hypointense T1 and hyperintense T2. In our case cardiac MR was not done.

Molecular imaging methods such as 18F-FDG-PET/CT can assess metabolic activity, and hereby depict tumor metabolism. In the past, with help of 18F-FDG-PET/CT, a differentiation of malignant and benign cardiac masses was feasible with a sensitivity of more than 90%.

Treatment of metastatic cardiac tumor is usually palliative, because the overall prognosis is poor, with more than 50% of patients dying within 1 year.

Surgical or non surgical approaches, including transcatheter arterial embolization, transcatheter arterial infusion chemotherapy and radiotherapy, have been undertaken to treat IVC/RA metastases. [8] Surgical resection is indicated in cases of solitary intracavitary heart metastases, which lead to the obliteration of cardiac chambers or valve obstruction; however, the outcomes are unclear.

Some reports have described cases of sudden death due to malignant cardiac metastases [9]

However, there is no consensus regarding surgical treatment for such disease. Palliative radiotherapy and chemotherapy in chemosensitive tumors is recommended.

The management of a malignant pericardial effusion is typically individualized to a local center's experience and close collaboration between cardiologists, and oncologists is necessary to insure an optimal plan. [10] [11]

Conclusion:-

Right atrium metastatic tumors are relatively rarer than other types. Transthoracic echocardiography appears to be the most easily available, noninvasive, cost-effective and useful technique in making the differential diagnosis.

A multidisciplinary approach involving cardiologists, oncologists, and cardiothoracic surgeons is crucial for deciding the best therapeutic regimen for such patients.

References:-

- [1] Butany J, Leong SW, Carmichael K, Komeda M. A 30-year analysis of cardiac neoplasms at autopsy. *Can J Cardiol*. 2005 Jun;21(8):675-80. PMID: 16003450.
- [2] Moskovitch G, Ghabbert V, Escourrou G, Desloques L, Potal P, Glock Y, et al. [cardiac tumors : CT and MR imaging futures] ; *JRadiol* 2010 ; 91 : 857-77
- [3] Reynen K, Kockeritz U, Strasser RH. Metastases to the heart. *Ann Oncol* 2004;15:375–381.
- [4] Chiles C, Woodar PK, Gutierrez FR, Link KM. Metastatic involvement of the heart and pericardium : CT and MR imaging . *Radiographics* 2001 ; 21 : 439-49.
- [5] Neragi-Miandoab S, Kim J, Vlahakesy GJ. Malignant tumours of the heart: a review of tumour type, diagnosis and therapy. *Clin Oncol* 2007;19:748–756.
- [6] Bhan A, Mehrotra R, Choudhary SK, et al. Surgical experience with intracardiac myxomas: long-term follow-up. *Ann Thorac Surg* 1998;
- [7] Dodd JD, Aquino SL, Holmvang G, et al. Cardiac septal aneurysm mimicking pseudomass: appearance on ECG-gated cardiac MRI and MDCT. *AJR Am J Roentgenol* 2007;188:W550–W553.
- [8] Dodd JD, Aquino SL, Holmvang G, et al. Cardiac septal aneurysm mimicking pseudomass: appearance on ECG-gated cardiac MRI and MDCT. *AJR Am J Roentgenol* 2007;188:W550–W553.
- [9] Yoshidome H, Takeuchi D, Kimura F, et al: Treatment strategy for hepatocellular carcinoma with major portal vein or inferior vena cava invasion: a single institution experience. *J Am Coll Surg* 212: 796-803, 2011.
- [10] Terauchi F, Washino S, Matsuzaki A, et al. Sudden death in a case of cardiac metastasis of renal cell carcinoma. *Nishinon J Urol*. 2006;68:270–3.
- [11] Zamorano JL, Lancellotti P, Rodriguez Muñoz D, Aboyans V, Asteggiano R, Galderisi M, Habib G, Lenihan DJ, Lip GYH, Lyon AR, Lopez Fernandez T, Mohty D, Piepoli MF, Tamargo J, Torbicki A, Suter TM. 2016 ESC

position paper on cancer treatments and cardiovascular toxicity developed under the auspices of the ESC Committee for Practice Guidelines: the Task Force for cancer treatments and cardiovascular toxicity of the European Society of Cardiology. EuroHeart J 2016;37:2768–2801.