



Journal Homepage: - [www.journalijar.com](http://www.journalijar.com)

## INTERNATIONAL JOURNAL OF ADVANCED RESEARCH (IJAR)

Article DOI: 10.21474/IJAR01/15438

DOI URL: <http://dx.doi.org/10.21474/IJAR01/15438>



### RESEARCH ARTICLE

#### A RARE CASE OF SECONDARY AMENORRHOEA WITH SWEYER'S SYNDROME: A CASE REPORT

Prameela Menon<sup>1</sup> and Pooja Viswaraj<sup>2</sup>

1. Professor, Department of Obstetrics and Gynaecology, Amala Institute of Medical Sciences, Thrissur, Kerala, India.
2. Postgraduate Resident, Department of Obstetrics and Gynaecology, Amala Institute of Medical Sciences Thrissur, Kerala, India.

#### Manuscript Info

##### Manuscript History

Received: 25 July 2022

Final Accepted: 28 August 2022

Published: September 2022

##### Key words:-

Sweyer's Syndrome, Secondary Amenorrhoea, Gonadoblastoma

#### Abstract

Sweyer's syndrome or pure gonadal dysgenesis is characterised by primary amenorrhoea, presence of female phenotype, female external genitalia and female internal genitalia with hypoplastic uterus and streak gonads. A 16 year old girl presented with secondary amenorrhoea, she attained menarche at 11 years and was followed by 4 months of regular cycles thereafter developed two years of amenorrhoea. On examination she is phenotypically female with no secondary sexual characteristics, external genitalia is female. Laboratory investigations showed a high level of serum follicle stimulating hormone, Luteinising hormone which were consistent with hyper gonadotropic hypogonadism, pelvic ultrasound showed a hypoplastic uterus and hypoplastic ovaries, chromosomal analysis revealed XY Karyotype. Further she underwent laparoscopic prophylactic gonadectomy and the histopathology confirmed hypoplastic ovaries. In conclusion we emphasise that Sweyer's syndrome can present with secondary amenorrhoea with a functioning uterus with lining endometrium. The importance of timely diagnosis and gonadectomy forseeing a gonadoblastoma cannot be over emphasised.

Copy Right, IJAR, 2022.. All rights reserved.

#### Introduction:-

Sweyer's syndrome is a rare disorder characterised by the failure of gonadal development: testis or ovaries. Sweyer's syndrome was first identified in 1955 by Doctor Sweyer<sup>1</sup>. This disorder is classified as Disorder of sexual development (DSD) which encompasses any disorder in which gonadal, chromosomal or anatomical sex is abnormal<sup>2</sup>. Sweyer's has female phenotype. Patients usually present with primary amenorrhoea or delayed menses due to the absence of functional gonads and XY karyotype<sup>3</sup>. We present the case of a 16 year old girl who presented with secondary amenorrhoea and had a normal female phenotype and XY karyotype with hypoplastic gonads on histopathology.

#### Case Report

Ms'Z 'a 16 year old female presented with secondary amenorrhoea since past two years. She gave us a history of attaining menarche at 11 years which was succeeded by four regular cycles with 3 – 4 days of bleeding and cycle

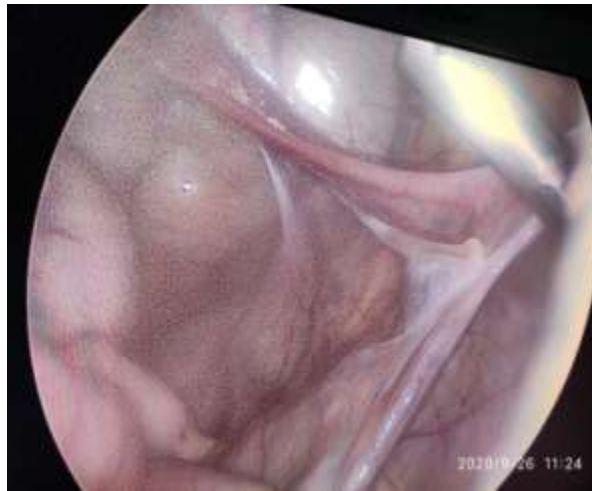
**Corresponding Author:- Prameela Menon**

Address:- Professor, Department of Obstetrics and Gynaecology, Amala Institute of Medical Sciences, Thrissur, Kerala, India.

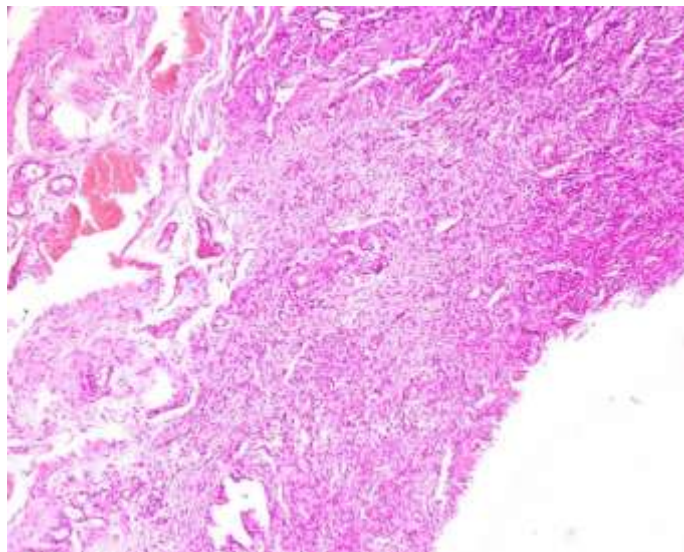
length of 30 days after which she remained amenorrheic for 7 months. Then she had a single cycle with bleeding for 3-4 days. Thereafter she became amenorrheic for two years for which she came to us for evaluation.

On examination we found that she had female phenotype, absent secondary sexual characteristics, height 153 cm, weight- 34 kg, Breast and pubic hair-Tanner- 1, absent axillary hair.

Her external genitalia was female with normal sized clitoris. Hymen was intact, vagina admitted a probe of 4 cm length. Abdomen was normal without any evidence of undescended gonads. On per rectal examination an infantile uterus was felt. Pelvic ultrasound showed a small hypoplastic uterus 0.6x0.5 cm in cross-section, both ovaries appeared hypoplastic. Hormone profile showed luteinising hormone 45.63 mIU/l, FSH – 160.6 mIU/ml, TSH - 3.3 mIU/l, testosterone -0.35 ng/ml, serum prolactin 19.99 ng/ml. Her karyotyping came as XY, establishing a diagnosis of Swyers syndrome. After proper counselling to the patient and the family members regarding the diagnosis and the immediate need for gonadectomy, she underwent a laparoscopic pelvic exploration and bilateral prophylactic gonadectomy. Intraoperatively we could identify a hypoplastic (infantile) uterus about 2x3x1 cm with normal fallopian tubes approximately 3 cm in length on each side of the uterus. Bilateral hypoplastic/ streak ovaries were located behind the fallopian tube on either sides (figure 1). We proceeded with bilateral salpingoopherectomy and left the hypoplastic uterus in place. Histopathology came as bilateral hypoplastic ovaries with fallopian tubes of normal histology. (Figure 2)



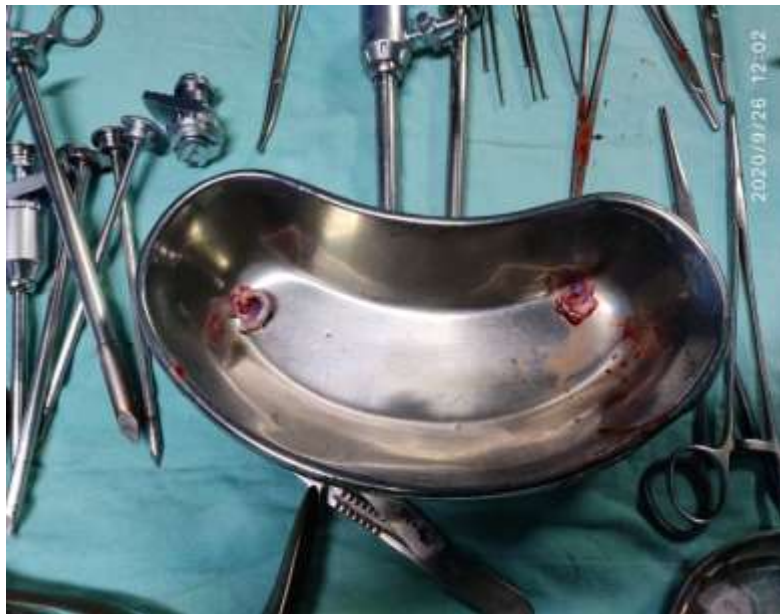**Fig 1:-** Laparoscopic Image Showing Fallopian Tube With Streak Gonad.



**Fig 2:-** Histopathology Report Of The Patient Showed Streak Gonads- Ovary.



**Fig 3:-** Karyotype Of The Patient Revealing Male Genotype - 46XY.



**Fig 4:-** Specimen Showig Sreak Gonads Which Were Removed.

### **Discussion:-**

Sweyers syndrome is a rare cause of primary amenorrhea. Patients with this disorder are phenotypically female and have 46 XY karyotype on chromosome analysis<sup>3</sup>. In our case the patient presented with secondary amenorrhoea which points to the presence of a uterus with an endometrial lining. Usually diagnosis and gonadectomy in many cases can be delayed as the patient is having an atypical presentation .

Deletion of SRY- sex determining region on chromosome y is seen in 20 % cases . however the remaining 80 % do not harbour an SRY gene mutation. Since the karyotype of the patient is XY ( figure 3 ) , the main differential diagnosis for this condition can be Androgen Insensitivity syndrome and true hermaphroditism. In this patient there is absence of secondary sexual characteristics with the presence of a hypoplastic uterus and hypergonadotrophic hypogonadism which differentiates it from androgen insensitivity. The external genitalia is purely female this feature differentiates her from a true hermaphrodite. In a true hermaphrodite either a unilateral or bilateral ovo- testis

will be observed which is absent here. There is a risk of developing dysgerminoma in the occult testicular elements of about 25 %<sup>4</sup>, thus there is an immediate need for gonadectomy soon after diagnosis.

Further management of the patient includes Estrogen and progesterone for the development of secondary sexual characteristics. Future prospects of management in anticipation of pregnancy includes offering IVF using donor ovum and partner's sperm.

**Conclusion:-**

Sweyers syndrome is a rare form of sexual development which requires clinical, laboratory and radiological evaluation. Although most cases present with primary amenorrhoea the possibility of having hypoplastic uterus with a lining functional endometrium must be considered, pointing towards early evaluation of cases with secondary amenorrhoea too which can facilitate early gonadectomy.

**References:-**

1. Sweyer GI : Male Psuedohermaphroditism : a hitherto undescribed form : Br Med J . 1955, 2 (4941) : 709-712.
2. A.R. Rey , N . Josso Diagnosis and treatment of disorders of sexual development, (7 th ) edition, L.J. De Groot, J.L Jameson ( Eds ) , Endocrinology adult and pediatric , vol .2 ElsevierSaunde, Philadelphia ( 2010 ) , pp . 2086-2118
3. Michala L. Goswami D, Creighton S M , Conway GS . Sweryerssyndrome : Presentation and outcomes . BJOJ, 2008, 115 : 737-41. [Pubmed]
4. Hoepffner W. Horn LC , Simon E et al, Gonadoblastomas in 5 patients with 46, XY, gonadal dysgenesis. ExpClinEndocrinolDiabetis . 2005 ; 113: 231-235 [ Pub Med ].