



Journal Homepage: -www.journalijar.com

INTERNATIONAL JOURNAL OF ADVANCED RESEARCH (IJAR)

Article DOI:10.21474/IJAR01/15457
DOI URL: <http://dx.doi.org/10.21474/IJAR01/15457>



RESEARCH ARTICLE

UNUSUAL METASTASIS IN THE CERVIX: ABOUT A CASE

K. Raissouni, M. Khmou, Y. Mahdi, S. Ech-Chrif, I. Boujida, Y. Laraqui and B. El Khanoussi

Department of Pathological Anatomy, National institute of oncology "Sidi Mohamed Ben Abdellah", Faculty of Medicine and Pharmacy, Mohammed V University, Rabat, Morocco.

Manuscript Info

Manuscript History

Received: 05 August 2022

Final Accepted: 09 September 2022

Published: October 2022

Key words:-

Gallbladder, Cervix, Adenocarcinoma, Metastases

Abstract

Metastases to the cervix from a non-gynecological neoplasm are extremely rare. Only four cases of primary carcinoma of gallbladder with metastasis to the cervix have been reported [1]. We reported a case of a 52-year-old woman operated on 2 years earlier for a primary gallbladder adenocarcinoma, the evolution was marked by the appearance of left lumbar pain radiating towards the left flank with vaginal bleeding. A biopsy with immunohistochemical complement confirmed the diagnosis of secondary location of gallbladder adenocarcinoma. Pelvic MRI shows a lesion in the cervix and a left ureteral compression with left hydronephrosis. A placement of a double J probe, with radiotherapy and radiological control was decided for this patient at first.

Copy Right, IJAR, 2022,. All rights reserved.

Introduction:-

The uterine cervix is rarely involved by metastatic tumors [2,3]. It was reported that the incidence of metastasis to the cervix is about 0.3% [4,5]. When metastatic involvement of the uterine cervix does occur, it poses a diagnostic dilemma for both the clinician and the pathologist as secondary tumors may be overlooked. Regarding malignant non-gynecological tumors that metastasize to the cervix; a few cases have been reported; most of them related to gastric and mammary neoplasm [6]. Due to the scarcity of the reports, there is no real consensus for the management of this uncommon presentation; however, the distinction between primary and non-primary cervical carcinomas is of great importance, as it not only dictates prognosis, but also allows for selection of the appropriate treatment.

Case Report

A 52-year-old woman presented a 3-month history of a pain in her left lumbar area radiating to left flank with vaginal discharges and bleeding. Her medical history was significant; she underwent 2 years ago a cholecystectomy with liver bi-segmentectomy IVb and V for gallbladder adenocarcinoma. The pelvic exam revealed the presence of a 4 cm, firm budding cervical tumor. There was no perimetrium or pelvic sidewall involvement. Her abdomen was non-tender, without evidence of hepatosplenomegaly. A cervical biopsy was performed; Microscopically, the tumor was largely necrosed on the surface, it consisted of well-differentiated glands anastomosed into cribriform masses consisting of large cells with mucin secreting features (Fig A, B).

Immunohistochemistry showed positivity of the adenocarcinoma for MUC1 and CK19 confirming metastasis from biliary primary (Fig C, D). PAX8 and hormone receptors (RE, RP) were negative.

Corresponding Author:- K. Raissouni

Address:- Department of Pathological Anatomy, National institute of oncology "Sidi Mohamed Ben Abdellah", Faculty of Medicine and Pharmacy, Mohammed V University, Rabat, Morocco.

Abdominal and pelvic MRI had shown a cervix lesion and a left ureteral compression with left hydronephrosis, No evidence of extension into the liver and no signs of biliary obstruction were noted. There was moderate right-sided hydronephrosis and hydroureter, the patient had a Double J stent placement and starts radiotherapy. A radiological control was decided for this patient at first.

Discussion:-

The annual incidence of primary carcinoma of the gallbladder is about 2.5 cases per 100,000 people in the United States [7]. It is typically a disease of the elderly, with a peak in the sixth or seventh decade of life, and it is more frequently diagnosed in women. The most common type of gallbladder cancer, is adenocarcinoma; accounting for 69% of the cases [8]. Despite improvements in diagnostic and therapeutic modalities, patients with gallbladder carcinoma continue to have an extremely poor prognosis, mainly because of the typically late diagnosis due to the non-specificity of the clinical symptoms. In most series, over 80% of the cases were diagnosed as stage IV disease (liver involvement, distant metastasis, or both) [8]. It has reported that 81% of metastases were found in the liver (66% of patients) and lungs (15%).

The lower female genital tract is rarely involved by metastatic tumors; The ovaries and the vagina were the most frequent sites of metastasis, regardless of the location of the primary tumor. The potential routes for metastasis of non-gynecologic carcinomas to the cervix include hematogenous spread, retrograde lymphatic spread, and transperitoneal seeding with either transtubal spread or penetration from the cul-de-sac [2,3].

There were a few cases of metastasis to the cervix; Mazur and al [3] have reported five case in their largest series.

Contrary to ovaries, which provide a right environment for metastatic cells, the uterine cervix is believed to be an unfavorable medium for metastatic growth; this is due to the high fibromuscular tissue content of the cervix, small size, and relatively limited blood supply of the cervix [2–6].

Most cases with metastasis to the uterine cervix manifest with abnormal vaginal bleeding (62–75%) [5, 11]

The anatomopathological examination is the definitive tool to determine the metastatic disease's true origin [10].

Adenocarcinoma histology type represents 0.42 to 11.7% of all cervix carcinomas [12]. However, metastatic adenocarcinoma incidence was 21.6 to 56.9% of cervical Adenocarcinoma [12, 13]. In these cases, it is indispensable to differentiate a genital from the extragenital origin of the uterine cervix tumor. The presence of a papillary serous pattern, a prominent signet-ring cell component, or an 'indian-file' arrangement of the tumor cells suggests the possibility of an ovarian, gastrointestinal, or breast origin, respectively [2].

However, our pathology review showed an adenocarcinoma with features not typical for a cervical primary. Morphologic findings that should raise suspicion for a metastatic lesion include a permeative growth pattern that surrounds normal endocervical glands, multifocal involvement, unusually prominent involvement of cervical lymphatics or blood vessels, and a lack of an associated in situ carcinoma [2,14]

In this case, there was histologically involvement of the cervix by a well-differentiated adenocarcinoma that was composed of glandular distended tubes. The adenocarcinoma infiltrated between normal endocervical glands (Fig A,B), and there was no associated adenocarcinoma in situ.

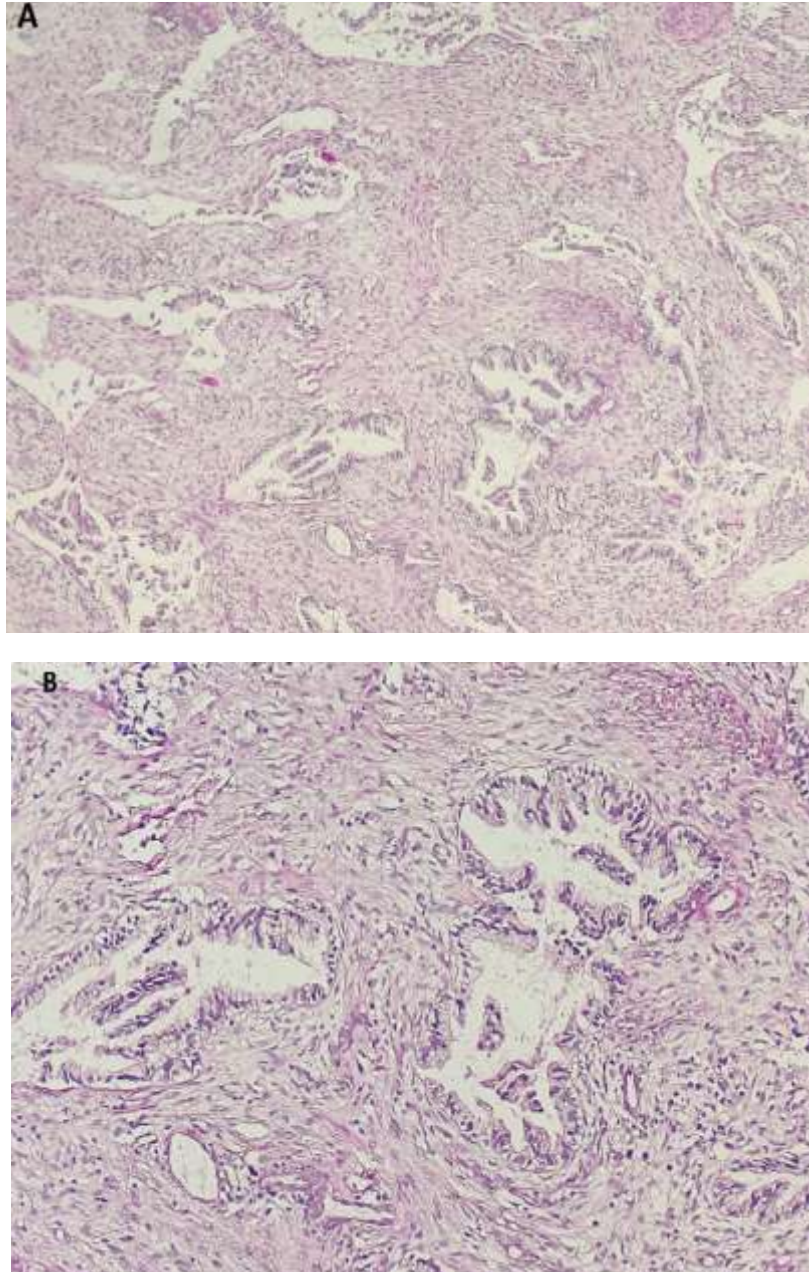


Fig. A, B:- Metastatic adenocarcinoma of the gallbladder involving the cervix. The metastasis infiltrates around normal glands and produces a desmoplastic response.

Immunohistochemical staining is indispensable for distinguishing primary cervical carcinomas from metastatic carcinomas [15].

P16, PAX8, CEA, and CK7 are usually expressed in primary cervical adenocarcinomas [15, 16] and more cases are negatives for, ER and RP.

IHC profile reveals negativity of P16, PAX8 and hormonal receptors (ER, RP), and positivity of MUC1 and CK19 (Fig C, D); this result would be unusual for an endocervical adenocarcinoma but are compatible with adenocarcinomas of other sites including the gallbladder.

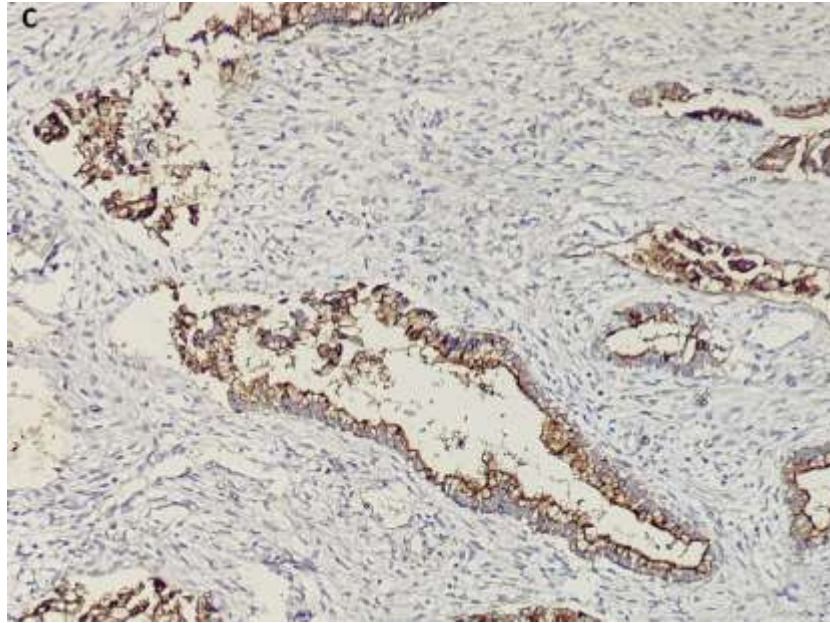


Fig.C:- Histological slide showing MUC1 positivity.

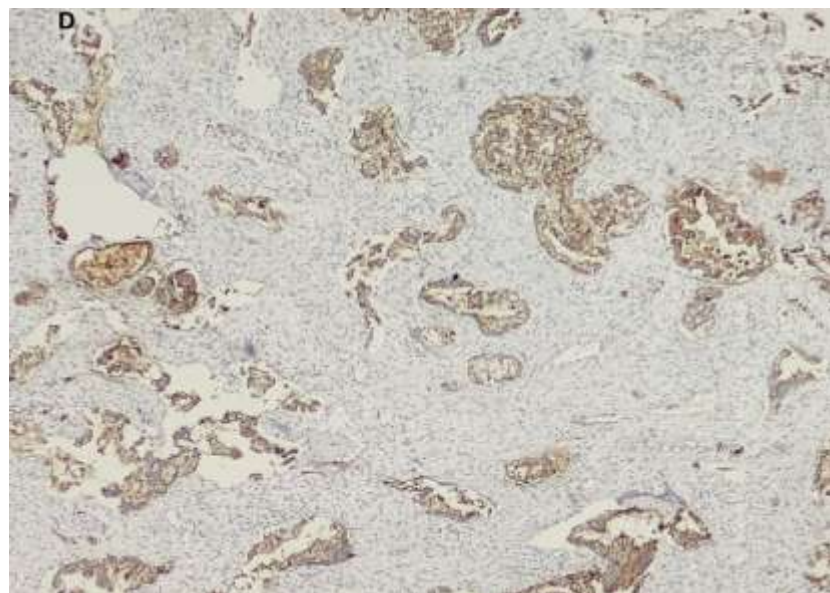


Fig.D:- Histological slide showing CK19 positivity.

Pelvic MRI with contrast should be considered to determine soft tissue and parametrial involvement like it has been recommended for all cervical tumors. In our case, it did not show any other metastatic sites; they have opted to start with decompressive and hemostatic radiotherapy for this patient.

Conclusion:-

Metastatic disease to the uterine cervix is rare and often hard to diagnose. These metastases should be discarded when patients with a history of extra-genital primary carcinoma present abnormal vaginal bleeding or discharge. For an accurate diagnosis of the origin of uterine cervical adenocarcinoma cancer, immunohistochemistry should be performed.

This case highlights the importance of performing a thorough work-up for metastatic disease before initiating therapy in patients with an atypical presentation for cervical adenocarcinoma.

References:-

1. Sergio MR, Michael F, Michael TD, Pedro TR. Metastatic carcinoma of the gallbladder mimicking an advanced cervical carcinoma. *Gynecologic Oncology* 97(2005)942-945.
2. Clement PB. Miscellaneous primary tumors and metastatic tumors of the uterine cervix. *Semin Diagn Pathol* 1990;7:228 – 48.
3. Mazur MT, Hsueh S, Gersell DJ. Metastases to the female genital tract. Analysis of 325 cases. *Cancer* 1984;53:1978 – 84.
4. Abrams HL, Spiro R, Goldstein N. Metastases in carcinoma. Analysis of 1000 autopsied cases. *Cancer* 1950; 3: 74–85.
5. Ng AB, Teeple D, Linder EA et al. The cellular manifestations of extrauterine cancer. *Acta Cytol* 1974; 18: 108–117.
6. Mulvany NJ, Nirenberg A, Oster A. Non-primary cervical adenocarcinomas. *Pathology* 1996;28:293 – 7.
7. Jemal A, Tiwari RC, Murray T, Ghafoor A, Samels A, Ward E, et al. Cancer statistics, 2004. *CA Cancer J Clin* 2004;54:8 – 29
8. Chao TC, Greager JA. Primary carcinoma of the gallbladder. *J Surg Oncol* 1991;46:215 – 21
9. Ohlsson EG, Aronsen KF. Carcinoma of the gallbladder. A study of 181 cases. *Acta Chir Scand* 1974;140:475 – 80.
10. Mulvany NJ, Nirenberg A, Oster AG. Non-primary cervical adenocarcinomas. *Pathology*. 1996;28:293–7.
11. Yazigi R, Sandstad J, Munoz AK. Breast cancer metastasizing to the uterine cervix. *Cancer*. 1988;61:2558–60
12. William P, Abraham M. Adenocarcinoma of the cervix. *Am J Obstet Gynecol*. 1962;84:367–74.
13. Korhonen M, Stenback F. Adenocarcinoma metastatic to the uterine cervix. *Gynecol Obstet Invest*. 1984;17:57–65.
14. Esposito JM, Zarou DM, Zarou GS. Extragenital adenocarcinoma metastatic to the cervix uteri. *Am J Obstet Gynecol* 1965;15: 792 – 5.
15. Raspollini MR, Baroni G, Taddei A, Taddei GL. Primary cervical adenocarcinoma with intestinal differentiation and colonic carcinoma metastatic to cervix: an investigation using Cdx-2 and a limited immunohistochemical panel. *Arch Pathol Lab Med* 2003; 127:1586 – 90.
16. Negri G, Egarter-Vigl E, Kasal A, Romano F, Haitel A, Mian C. p16ink4A is a useful marker for the diagnosis of adenocarcinoma of the cervix uteri and its precursors. An immunohistochemical study with immunocytochemical correlations. *Am J Surg Pathol* 2003;27: 187 – 93
17. Tot T. Adenocarcinomas metastatic to the liver. The value of cytokeratins 20 and 7 in the search for unknown primary tumors. *Cancer* 1999;85:171 – 7
18. Parwani AV, Geradts J, Caspers E, Offerhaus GJ, Yeo CJ, Cameron JL, et al. *Mod Pathol* 2003;16:299 – 308.