



Journal Homepage: -[www.journalijar.com](http://www.journalijar.com)

## INTERNATIONAL JOURNAL OF ADVANCED RESEARCH (IJAR)

Article DOI:10.21474/IJAR01/15485  
DOI URL: <http://dx.doi.org/10.21474/IJAR01/15485>



### RESEARCH ARTICLE

#### DERMOSCOPY OF DISORDERS OF HYPOPIGMENTATION

Dr. Bindhu R. and Dr. Ashok S. Hogade

#### Manuscript Info

##### Manuscript History

Received: 10 August 2022

Final Accepted: 14 September 2022

Published: October 2022

#### Abstract

**Background:-** Hypopigmentary disorders constitute a large and heterogenous group of diseases that are clinically characterised by hypopigmented macules. Dermoscopy is a non invasive imaging technique that allows for appreciation of subtle, distinctive features visible to the naked eye aid in differential diagnosis of hypopigmentary disorders.

**Aims & Objective:-** To investigate the utility of dermoscopy In common hypopigmentary diseases.

**Materials & Method:-** A series of 50 cases of hypopigmentary disorders was included in this case series. Detailed and informed consent was taken from the patients. The following skin diseases were included in the research : vitiligo, Pityriasis versicolor, idiopathic guttate hypomelanosis, nevus depigmentosus, pityriasis alba. All of the cases which were on treatment were excluded from study. A detailed history and dermatological examination was done along with Wood's light examination and potassium hydroxide (KOH). The following parameters were taken into consideration while doing dermoscopy in these diseases i) Presence of altered pigmentation , ii) edge of macule , iii) presence of scales , iv) Presence of perifollicular pigmentation, reticulation or telangiectasia.

**Results:-** In this study , 50 patients with following diseases were enrolled in the study : vitiligo (15 cases), pityriasis versicolor (12 cases) , idiopathic guttate hypomelanosis (10 cases) , nevus depigmentosus ( 6 cases ) , pityriasis alba (6 cases) . On dermoscopy , vitiligo lesions showed white glow . Pityriasis versicolor was whitish brown with double edged scales. Idiopathic guttate hypomelanosis was white with well defined and angulated margins. Nevus depigmentosus showed Pseudopods. Different patterns like trichrome pattern, Polka dot pattern, petaloid patterns were seen.

**Conclusion:-** This study showed that these hypopigmented diseases might display specific and characteristic dermoscopic features. Dermoscopic findings should always be interpreted with the overall clinical context of the patient history and macroscopic examination.

Copy Right, IJAR, 2022., All rights reserved.

#### Introduction:-

Hypopigmentary disorders constitute a large and heterogenous group of diseases that are clinically characterised by hypopigmented macules. Dermoscopy is a non invasive imaging technique that allows for appreciation of subtle,

distinctive features visible to the naked eye aid in differential diagnosis of hypopigmentary disorders. Hypopigmented lesions are considered as important dermatoses in daily practice. Their accurate diagnosis is very much crucial because of the social stigma attached to these diseases in the Indian subcontinent. Dermoscopy in hypopigmented lesions is limited to case reports and case series. As in inflammatory conditions, there are no defined dermoscopic criteria in hypopigmented lesions.

### Aims & Objective:-

To investigate the utility of dermoscopy in common hypopigmentary diseases

### Materials & Method:-

A series of 50 cases of hypopigmentary disorders was included in this case series. Detailed and informed consent was taken from the patients. The following skin diseases were included in the research : vitiligo, Pityriasis versicolor, idiopathic guttate hypomelanosis, nevus depigmentosus, pityriasis alba. All of the cases which were on treatment were excluded from study. A detailed history and dermatological examination was done along with Wood's light examination and potassium hydroxide (KOH). The following parameters were taken into consideration while doing dermoscopy in these diseases i) Presence of altered pigmentation , ii) edge of macule , iii) presence of scales , iv) Presence of perifollicular pigmentation, reticulation or telangiectasia.

### Results:-

In this study , 50 patients with following diseases were enrolled in the study : vitiligo (15 cases), pityriasis versicolor (12 cases) , idiopathic guttate hypomelanosis (10 cases) , nevus depigmentosus ( 6 cases) , pityriasis alba (6 cases) . On dermoscopy , vitiligo lesions showed white glow . Pityriasis versicolor was whitish brown with double edged scales. Idiopathic guttate hypomelanosis was white with well defined and angulated margins. Nevus depigmentosus showed Pseudopods. Different patterns like trichrome pattern, Polka dot pattern, petaloid patterns were seen.

### Discussion:-

**1:-VITILIGO** :- Dermoscopic patterns in vitiligo include a diffuse white structureless area, which is seen as “white glow”<sup>1</sup>[figure-1a] due to absent pigment network because of the absence of melanocytes in the lesions. Reduced, residual, perifollicular, and perilesional pigmentation are noted based on the evolving, stability, and treatment of the lesions. “Reverse pigment network”<sup>2</sup>[figure-1b] which is a feature of melanoma and melanocytic nevus, can be observed in evolving vitiligo. It describes the reverse of normal reticular pigment network, wherein white lines segregate hyperpigmentary areas in net-like fashion. This is exactly opposite to the normal network, and it is noted in evolving lesions of vitiligo and can obviate the need for biopsy in doubtful lesions of vitiligo.

According to the basic guidelines, milky white is the background color, scales are absent in the lesion, different shades of pigmentation are the pigment pattern, no vascular structures are noted[figure-1c], and white hairs, if present in leukotrichia in vitiligo patch, are the follicular changes<sup>2</sup>. ”White glow” forms a special clue in vitiligo as it is not seen in other depigmentary lesions except in idiopathic guttate hypomelanosis (IGH).

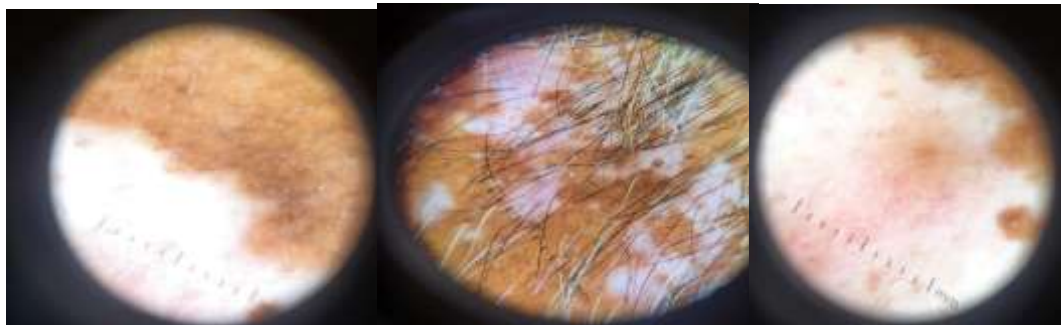

Figure:- 1 a

Figure :- 1b

Figure :-1c

## 2:- Pityriasis Versicolor :-

It shows diffuse white structureless areas with faint pigment network in the background . Borders of the lesion are indistinct. Fine white scales cover the entire lesions. However, scaling can be present as focal or in perifollicular or perilesional areas and in the skin cleavage lines. Scales in the skin furrows detach from the skin and breaks into two parts when the lesions are stretchedreferred as “double-edged” scales<sup>3</sup> .[figure-2b]

Hence, in accordance with basic guidelines, brownish-white in the background color,[figure-2a] faint brownish pigment network is the pigment network and scales are fine and white<sup>4</sup>. No follicular and vascular structures are involved in PV. We consider “double edged” scales are the special clue in PV as this pattern is not observed in other hypopigmentary lesions.

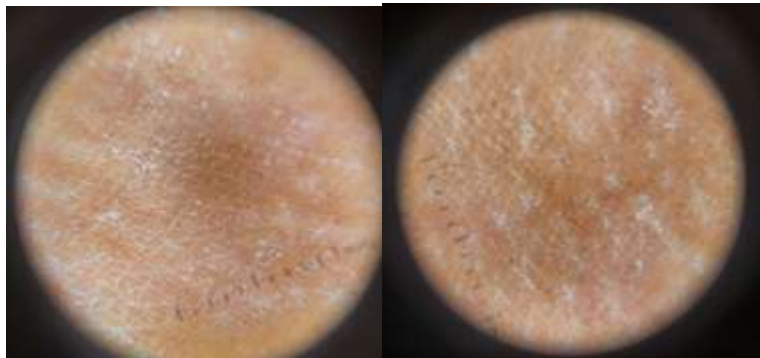


Figure -2a

Figure- 2b

## 3:- Idiopathic Guttate Hypomelanosis:-

Four different dermoscopic patterns have been described in IGH and that includes amoeboid, feathery, petaloid, and nebuloid patterns based on the different angulations<sup>5</sup> of white areas at the periphery. In the amoeboid pattern, diffuse structureless white areas extend like pseudopods appearing as as amoeba[figure-3a]. Feather-like spreading of margins, is referred to as feathery pattern[figure-3b]. The petaloid pattern is characterized by well-defined borders resembling petals of a flower[figure-3c]. Nebuloid pattern is distinctive of all with ill-defined borders. It should be noted that the last pattern closely resembles guttate vitiligo. It should be noted that in all types, margins are well demarcated.

Perifollicular, perilesional pigmentation, and diffuse pigmentation with linear and branching vessels are infrequently observed<sup>6</sup>. Pigmentation is more conspicuous in the skin of color.No changes are seen in terms of scaling or follicular structures.

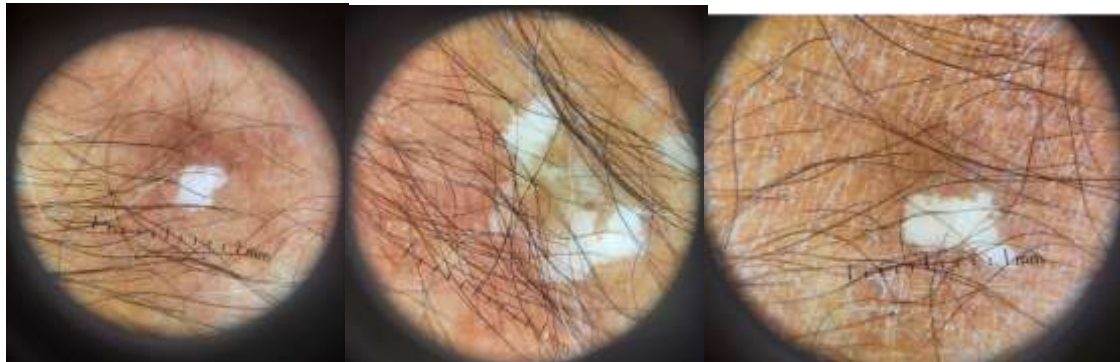


Figure-3a

Figure-3b

Figure-3c

## 4:- Nevus Depigmentosus:-

Dermoscopy of ND shows white structureless areas, faint uniform reticular pigment[figure-4a] network throughout the lesion with perifollicular pigmentation<sup>7</sup>. White structureless area extends peripherally as pseudopods<sup>8</sup>[figure-4b]. These correspond to the serrated borders of ND. In general, white areas under dermoscopy suggest decreased melanin in the epidermis. Here, the presence of faint or subtle uniform reticular pigmentation suggests that melanin is definitely present in the epidermis.

Hence, in the view of basic guidelines, brownish-white is the background color, reticular pigment network, and perifollicular pigment are the pigment pattern without scales<sup>9</sup>. [figure-4c] Follicular and vascular changes are not seen in ND. Pseudopod like extensions of the central white structureless area is the special clue in ND.

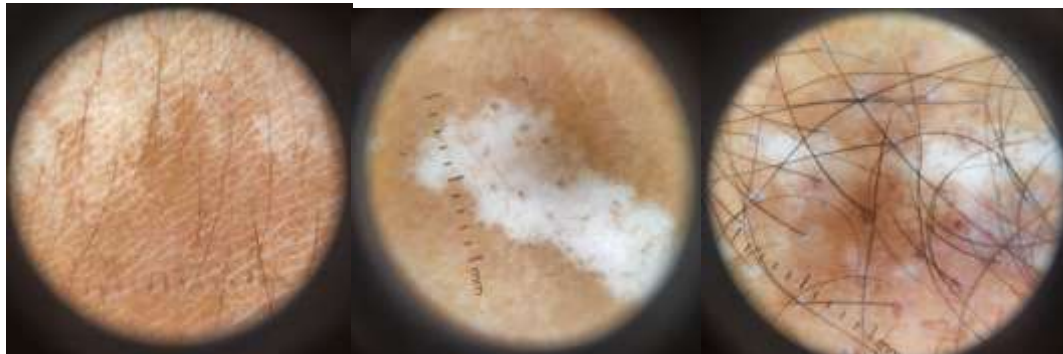

Figure-4a

Figure-4b

Figure-4c

### 5:- PITYRIASIS ALBA :-

Dermoscopy in pityriasis alba is white structureless areas with ill-defined margins [figure-5a]. Fine scales are noted at the center of the lesion. Areas of faint brownish pigment network are present within whitish areas [figure-5b]. It is essential to note that scales are white and focally distributed<sup>10</sup> and are not prominent in skin cleavage lines. This particular dermoscopic feature differentiates PA from pityriasis versicolor (PV).

Thus, in the view of basic guidelines, brownish-white is background color, scales are white and focal, light brown pigment network forms the pigment pattern<sup>11</sup>. No follicular and vascular changes are noted in PA without any special clue.

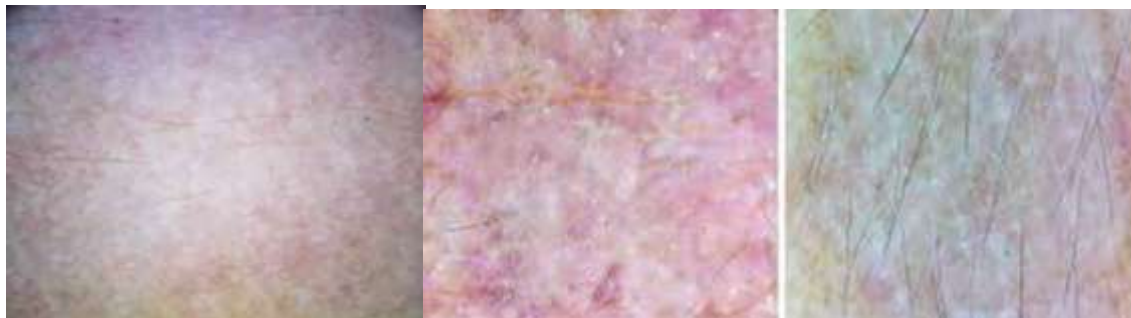

Figure-5a

Figure :- 5b

### Conclusion:-

This study showed that these hypopigmented diseases might display specific and characteristic dermoscopic features. Dermoscopic findings should always be interpreted with the overall clinical context of the patient history and macroscopic examination.

### Declarations :-

#### Conflict of interest :-

All authors declare they have no conflict of interest.

### Limitations:-

Cases who have acute skin infections and those on treatment.

### References:-

1. Kumar Jha A, Sonthalia S, Lallas A, Chaudhary RK. Dermoscopy in vitiligo: Diagnosis and beyond. Int J Dermatol 2018;57:50-4.

2. Ankad BS. Hypopigmented disorders (Disorders of pigmentation). In: Lallas A, Errichetti E, Ioannides D, editors. *Dermoscopy in General Dermatology*. London: CRC Press; 2019. p. 257-69.
3. Mathur M, Prakash Acharya P, Karki A, Kc N, Shah J. Dermoscopic pattern of pityriasis versicolor. *Clin CosmetInvestig Dermatol* 2019;12:303-9.
4. Thomas N, Malakar S. Dermoscopy: An easy way to solve the diagnostic puzzle in pityriasis versicolor. *Indian J Dermatol Venereol Leprol* 2019;85:664-5.
5. Ankad BS, Beergouder SL. Dermoscopic evaluation of idiopathic guttate hypomelanosis: A preliminary observation. *Indian Dermatol Online J* 2015;6:164-7.
6. Errichetti E, Stinco G. Dermoscopy of idiopathic guttate hypomelanosis. *J Dermatol* 2015;42:1118-9.
7. Errichetti E, Stinco G. Dermoscopy in general dermatology: A practical overview. *Dermatol Ther (Heidelb)* 2016;6:471-507.
8. Ankad BS, Shah S. Dermoscopy of nevus depigmentosus. *Pigment Int* 2017;4:121-3.
9. Malakar S, Mukherjee SS, Malakar S. Uniform faint reticulate pigment network – A dermoscopic hallmark of nevus depigmentosus. *Our Dermatol Online* 2018;9:225-6
10. Rubegni P, Burroni M, Andreassi A, Fimiani M. The role of dermoscopy and digital dermoscopy analysis in the diagnosis of pigmented skin lesions. *Arch Dermatol*. 2005;141:1444-1446
11. Paganelli G, Soyer HP, Argenziano G et al. Diagnosis of pigmented skin lesions by dermoscopy: web-based training improves diagnostic performance of non-experts. *Br J Dermatol* 2003; 148: 698–702.