



### RESEARCH ARTICLE

## EVALUATION OF THE EFFECT OF *CRASSOCEPHALUM CREPIDIOIDES* ON THE WOUND HEALING IN ALBINO RATS

Ananya Das

Post Graduate Trainee, Department of Pharmacology, Regional Institute of Medical Sciences, Imphal, Manipur.

#### Manuscript Info

##### Manuscript History

Received: 15 August 2022

Final Accepted: 18 September 2022

Published: October 2022

##### Key words:-

Crassocephalumcrepidioides, Wound Healing, Albino Rats

#### Abstract

*Crassocephalumcrepidioides* has been widely used in many parts of the world. The succus of the plant has also been used since many years by the local people of Manipur to treat fresh wounds. However, there has been no scientific studies till date to prove its role in wound healing. The present study is an attempt to evaluate the effects of the methanol extract of the leaves of this plant on the wound healing activity in albino rats using different wound models.

Copy Right, IJAR, 2022,. All rights reserved.

#### Introduction:-

The use of medicinal plants for treating diseases is probably the oldest existing method that humanity has ever tried to use to cope with various ailments. Ancient Chinese and Egyptian records indicate that herbs were used on a regular basis in their healing rituals. But with the advent of western medicine over the past century, herbal medicine has been challenged by clinical practitioners all over the world because of the lack of scientific evidence in the context of contemporary medicine. However, in recent years there has been an increase in the popularity of the use of herbs due to the side effects of chemical drugs, lack of curative modern therapies for several chronic diseases, drug resistance and tremendous investment in pharmaceutical research and development. About 1,200 new drugs have been approved by the United States Food and Drug Administration since 1950. As a result, the use of herbal products for health purposes has increased worldwide over the last 40 years in both the developing and the developed countries. Moreover, global pharmaceutical companies armed with modern science and technology have begun to rediscover herbs as a potential source of new drug candidates. This has helped to renew the strategies in favour of natural product drug development and discovery (1). A survey reports that more than 80% of the world population still depends on herbal medicines for their primary health care (2). According to WHO 21,000 species of plants have the potential of being used as medicinal plants. India is the largest producer of medicinal herbs and is called as botanical garden of the world (3). Approximately one third of all the traditional medicines in use are for the treatment of wounds and skin disorders (4). About 163 species are used as wound healing plants in the Indian system of medicine (5).

*Crassocephalumcrepidioides* (*C. crepidioides*) (Family: Asteraceae, Order: Asterales) commonly known as Thickhead is an erect, annual and slightly succulent herb growing up to 180 cm tall. The leaves which are fleshy and mucilaginous with a nutty flavour are heated and the succus is used to treat sores and fresh wounds topically by the people in the Mt. Hagen area of the highlands (6). It was observed that a similar kind of treatment was also used by the tribal people of Manipur, India since many years to treat fresh wounds. However, there is no scientific study available till date regarding the evaluation of the effect of the plant in wound healing. Hence, considering its use in treating wounds by the local people in different parts of the world, an attempt has been made to evaluate the role of *C. crepidioides* in wound healing in experimental animal models.

**Corresponding Author:- Ananya Das**

Address:- Post Graduate Trainee, Department of Pharmacology, Regional Institute of Medical Sciences, Imphal, Manipur.

## Materials And Methods:-

### Collection and preparation of the plant extract:

The leaves of *C. crepidioides* were collected from the Imphal valley during the months of June-July. It was identified and authenticated by the Manipur University.

The shade dried leaves were ground well in a mixer grinder and made into a coarse powder form of weight 50 g. It was then put in a Soxhlet apparatus and defatting was done up to 4 h with petroleum ether at 60-80°C. It was then extracted with methanol for another 4 h. The extract was filtered and the solvent was then removed and air dried and stored in a freezer for use in the study (7). The yield at the end of the extraction was found to be 15%.

### Acute toxicity study:

Acute toxicity test was carried out as per the OECD guidelines 423 in female albino rats (8). It was found that the plant extract was safe up to a dose of 2000 mg/kg of body weight. Thereafter two doses of 100 mg/kg and 200 mg/kg were chosen for the study.

### Phytochemical screening:

The preliminary phytochemical analysis of the methanol extract of the plant that was carried out using standard procedures to identify the various constituents revealed the presence of steroids, flavonoids and tannins (9-12).

### Animals:

Healthy adult Wistar albino rats of either sex (120-150g) was selected and obtained from Central Animal House RIMS, Imphal after getting approval from the Institutional Animal Ethics Committee. The animals were kept in polypropylene cages under conditions of controlled temperature (21-23°C) under 12 h light and 12 h dark cycle for 1 week in the animal room of the Dept of Pharmacology, RIMS for acclimatization. All the animal cares and procedures were according to the guidelines of the Committee for the Purpose of Control and Supervision of Experiments on Animals (CPCSEA), India.

### Study design:

In each wound model, three groups of six rats each were randomly selected. Group I was the control while Group II and III served as the treated groups. The plant extract was given in 2% gum acacia suspension at the dose of 1 ml/100g p.o. All the treatments were administered orally once a day by a feeding tube from the first day of surgical wound infliction till epithelialization in an excised wound model and for 10 days in incision and dead space wound models. Mupirocin ointment 2% was applied topically on all the inflicted wounds till complete healing. The animals were kept individually in separate cages till the experiment was over. The treatment given to the animals were as follows:

Groups	Drugs given
I	2% gum acacia suspension – 1 ml/100 g p.o.
II	Methanol extract of <i>C. crepidioides</i> – 100 mg/kg p.o.
III	Methanol extract of <i>C. crepidioides</i> – 200 mg/kg p.o.

### Excision wound model to assess the wound contracture and period of epithelialisation:

The rats of all the groups were inflicted with excision wounds as described by Das K with slight modification (13). After anaesthetization of the rats with diethyl ether, hair on the nape of the dorsal neck was shaved with a hair clipper. Under aseptic precautions, a circular wound of 2 cm in diameter was excised from the shaved area using a circular stamp moistened with methylene blue, sterile scissors and forceps. Incision of the muscle layer was avoided during the procedure so that the tension of the skin is not affected.

The wound closure rate was assessed by tracing it on days 0, 5 and 10 after creating the wound. The wound margin was marked on a tracing paper with marker by placing over the wound. The marked portion on the paper was subsequently placed on a 1 mm<sup>2</sup> graph sheet and counting of the number of small squares inside the marked area was done and the area of the wound recorded. The wound closure rate in the different groups of treatment were expressed as the percentage and compared with the wound size on day 0 in the respective groups. The number of days required for falling of the scab without any residual raw area was determined as the period of epithelialization.

**Incision wound model to assess tensile strength of the wound:**

The incision wound model of Ehrlich HP and Hunt TK was followed with slight modifications (14). After anaesthesia with diethyl ether, the hair over the area to be operated was removed with a hair clipper. An incision wound of 4 cm in length was made through the entire thickness of the skin on one side and 1 cm away from the vertebral column under aseptic precautions. The wound edges were approximated by interrupted silk sutures (3-0) at 1 cm intervals. The sutures were removed on day 7.

On day 10, the breaking strength of the wound was measured by the principle of continuous water flow technique of Lee KH (15). After anaesthesia, each rat was secured on the operating table in its normal position and the lines were drawn on either side of the wound 3 mm away from the wound margin on the normal skin. Two allis tissue forceps were applied on the lines facing each other. One of the forceps was fixed firmly on the operating table while the other was connected to a freely suspended light polythene container below the level of the animal through a string passed over a pulley. Water was made to flow inside the container at a constant rate through a regulator from a reservoir to build up enough force to disrupt the wound. As soon as the gaping appeared in the wound, the water flow was cut off and the volume of the water in the container was converted to its corresponding weight. The weight obtained represented the pulling force to disrupt the wound. The weight of the amount of water to cause wound gaping in the different groups of animals were compared. At the end of the experiment, the disrupted wound margins were sutured and allowed to heal.

**Dead space wound model to assess the granulation tissues:**

After anaesthetizing the rats with diethyl ether, the hair over the operating area was removed with a hair clipper. The method adopted by Khan MA et al was followed with slight modification (16). The subcutaneous dead space wounds were inflicted on one side of the axilla on each animal by making a pouch through a small nick in the skin under aseptic conditions. The pre weighed sterile cotton pellets (10 mg) were introduced and then stitched. The inflicted wounds were opened on the 10<sup>th</sup> post operative day under anaesthesia and the cotton pellets were removed. The granulation tissues surrounding the cotton pellets were excised carefully and kept in the fixative for histological examination.

**Statistical analysis:**

All the values obtained in the study were expressed as mean  $\pm$  SEM. The data was subjected to one way of analysis of variance (ANOVA) followed by Dunnett's 't' test. P values <0.05 were considered significant.

**Tissue staining techniques:**

The histological techniques in the study were followed as described by Drury RAB and Wallington EA (17).

**Results And Observations:-****Effect of methanol extract of *C. crepidioides* on % wound contraction in excision wound model:**

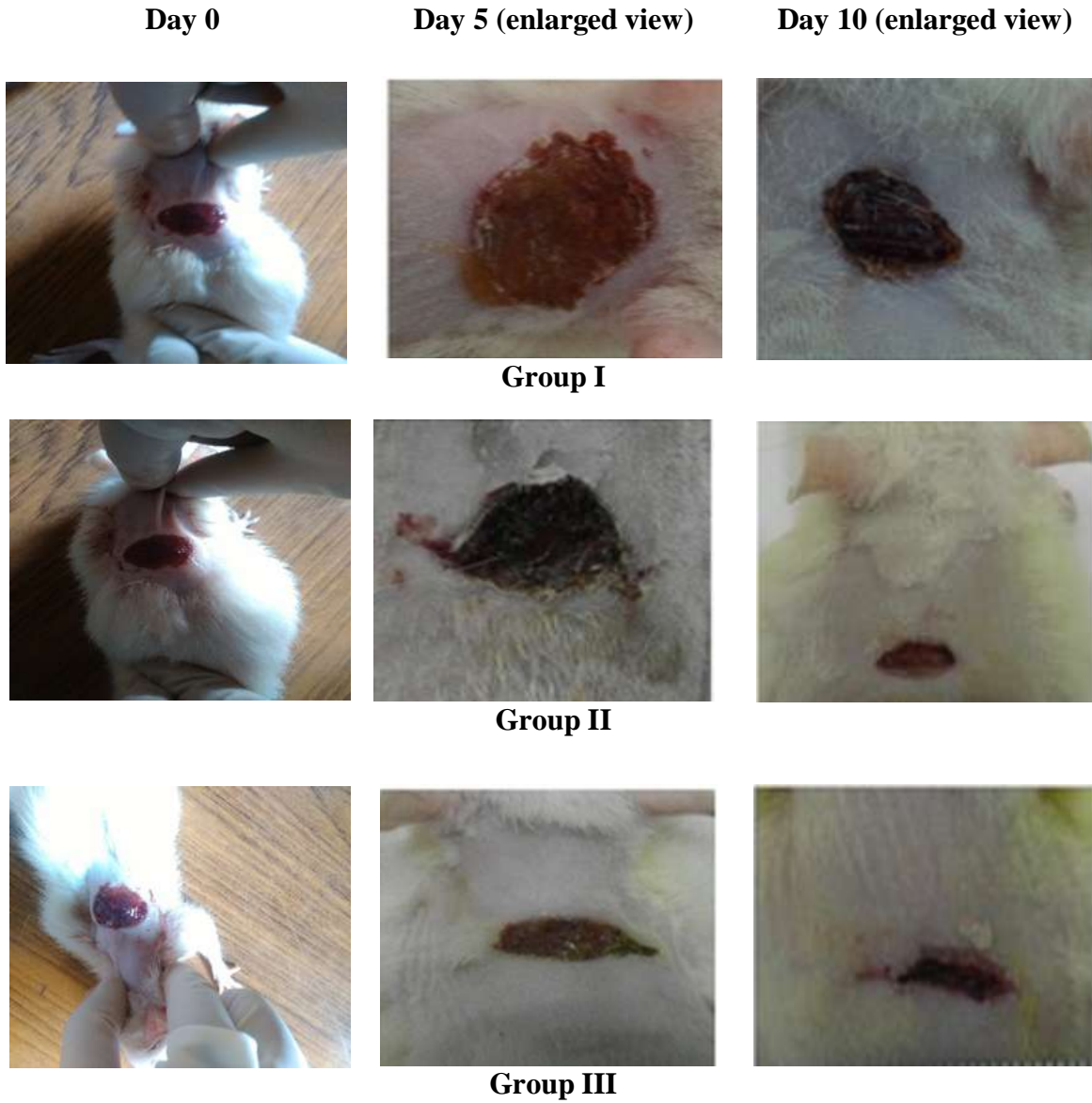
In the excision wound model, the percentage of wound area contraction was calculated on the 5<sup>th</sup> and 10<sup>th</sup> post-wound days as shown in Table 1. When compared to group I, there were significant differences in the percentage wound contraction in groups II (P<0.01) and III (P<0.001) for both the 5<sup>th</sup> and 10<sup>th</sup> day. Similarly, the decrease in the number of days required for epithelialization in the treated groups were found to be significant (P<0.001) when compared to group I.

**Table 1:-** Effect of methanol extract of on % wound contraction in excision wound model.

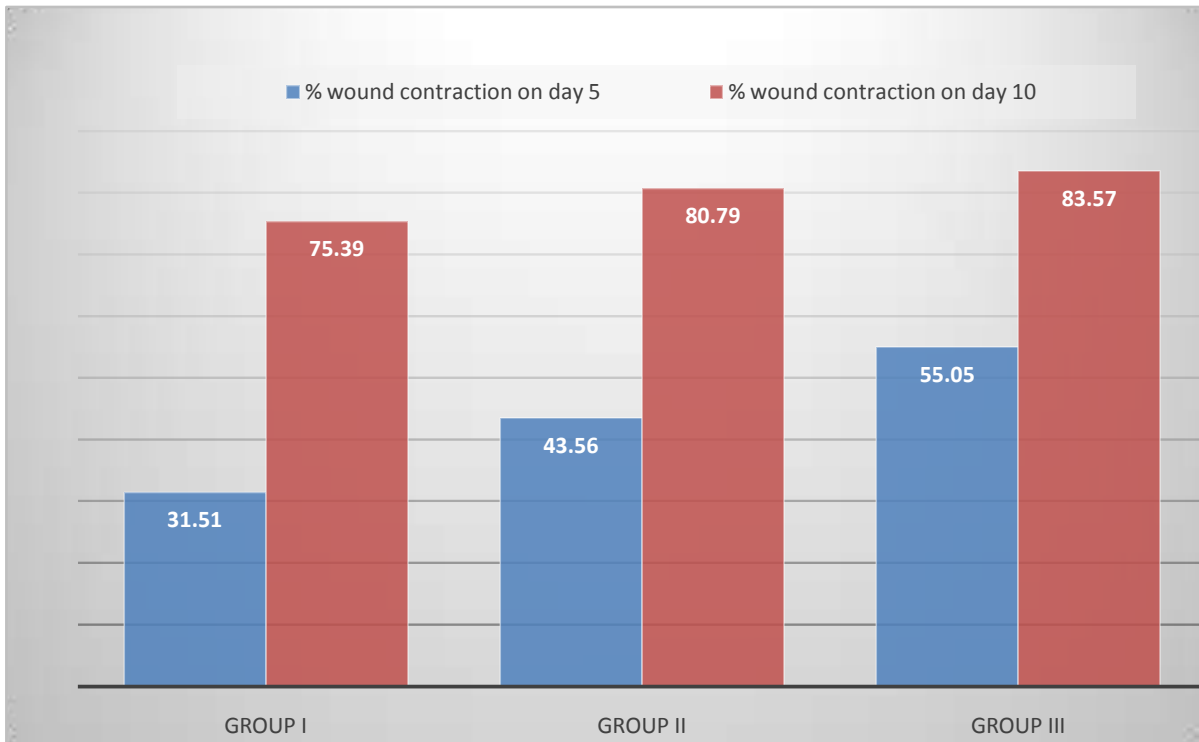
Groups	% Wound contraction on day 5 compared to day 0	% Wound contraction on day 10 compared to day 0	Epithelialization (days)
I	31.51 $\pm$ 2.24	75.39 $\pm$ 1.35	24.83 $\pm$ 0.31
II	43.56 $\pm$ 1.55*	80.79 $\pm$ 0.43**	21.33 $\pm$ 0.33**
III	55.05 $\pm$ 1.74*	83.57 $\pm$ 0.46***#	18 $\pm$ 0.37***#
One way ANOVA			
F	39.832	23.366	103.361
All values are in mean $\pm$ SEM (n = 6), *P value < 0.01 when compared to group I **P value < 0.001 when compared to group I, #P value < 0.001 when compared to group II, Group I: 2% gum acacia suspension p.o.			

Group II: Methanol extract of *C. crepidioides* 100 mg/kg p.o.  
Group III: Methanol extract of *C. crepidioides* 200 mg/kg p.o.  
(One way ANOVA followed by Dunnett's test)

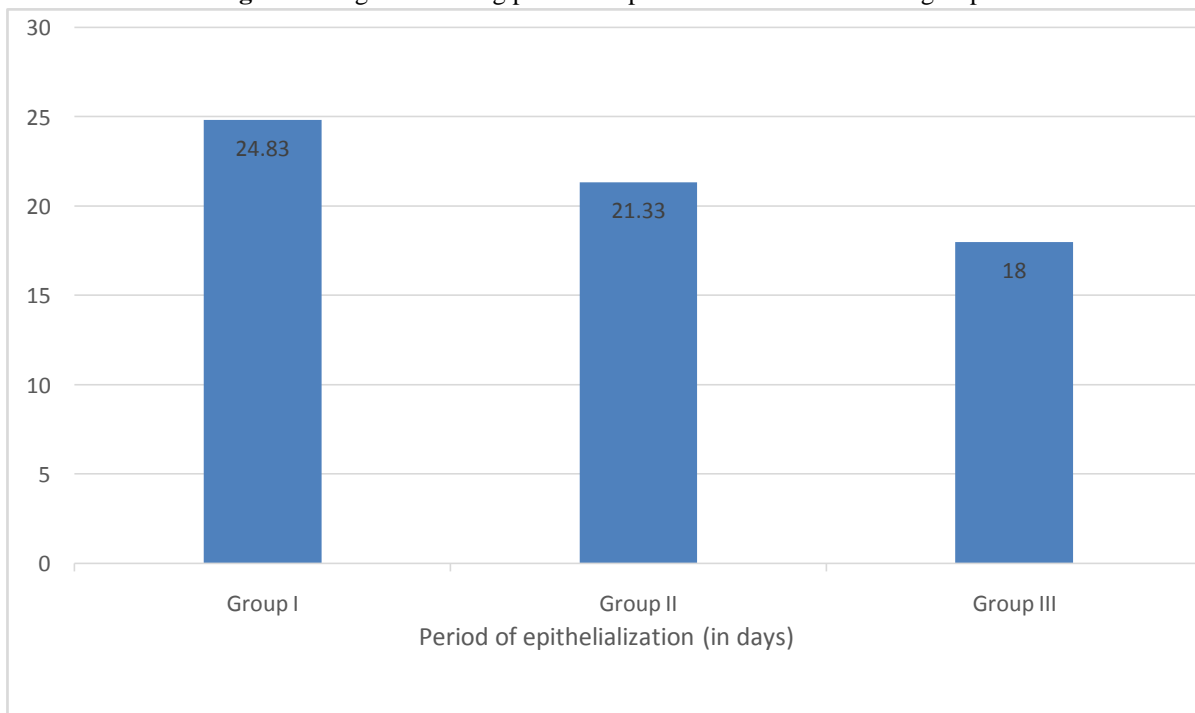
**Fig 1:-** Macroscopic view of the stages of wound healing in different groups on days 0, 5 and 10.



**Fig 2:-** Histogram showing percentage of wound contraction in different groups on days 5 and 10.



**Fig 3:-** Histogram showing period of epithelialization in different groups.



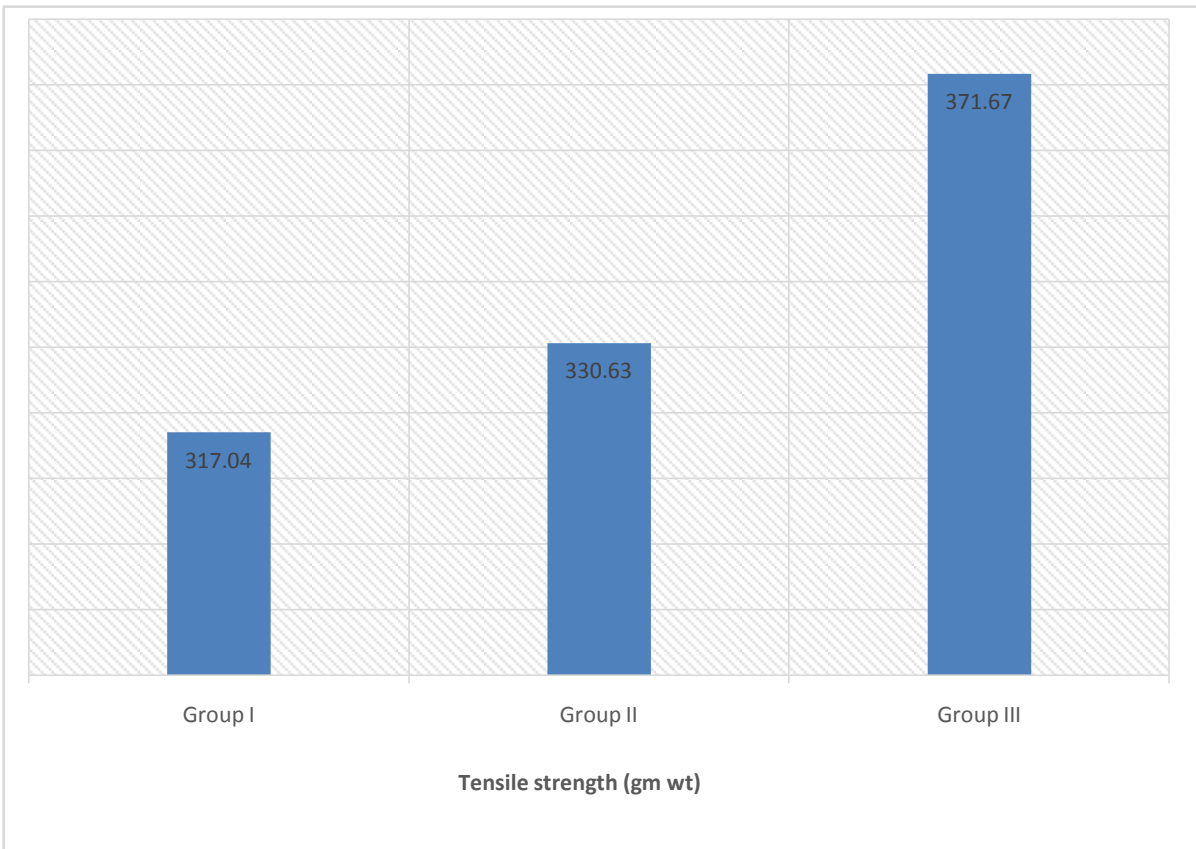
**Effect of methanol extract of *C. crepidioides* on the tensile strength in incision wound model:**

In the incision wound model, the tensile strength (gmwt) was measured on the 10<sup>th</sup> day as shown in Table 2. When compared to group I, the tensile strength was found to increase significantly in groups II (P<0.01) and III (P<0.001).

**Table 2:-** Effect of methanol extract of *C. crepidioides* on tensile strength in incision wound model.

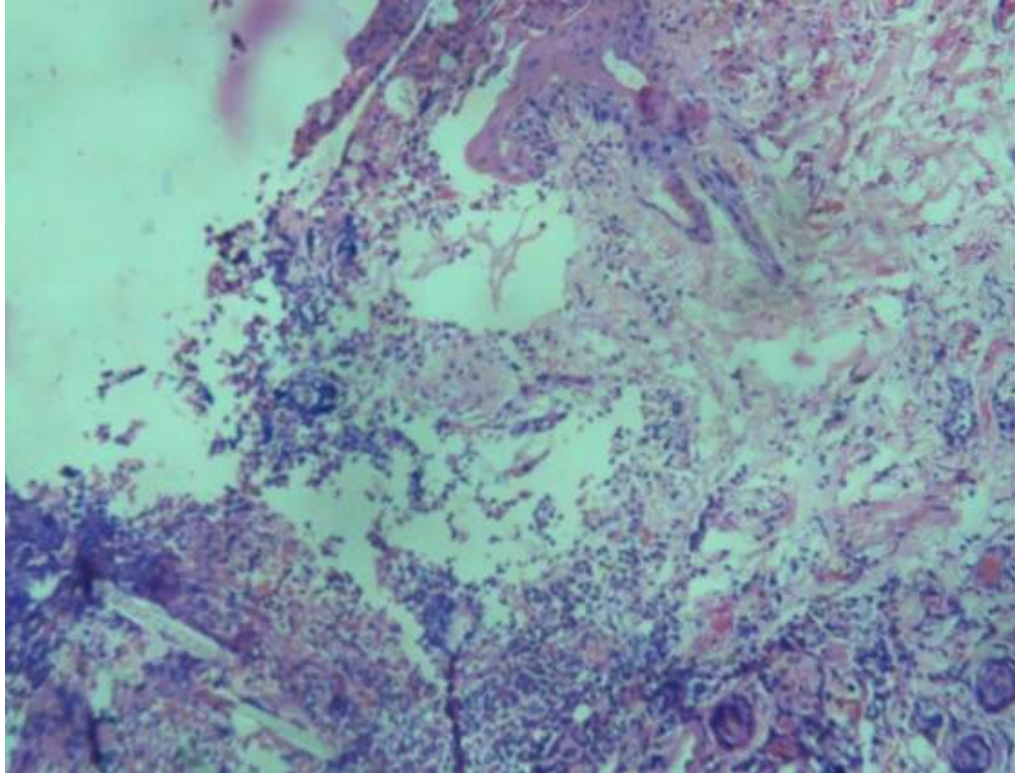
Groups	Tensile strength (g)
I	317.04±2.35
II	330.63±2.57*
III	371.67±4.77**#
One way ANOVA	
F	69.471
Df	2,15

All values are in mean ± SEM (n = 6), \*P value < 0.01 when compared to group I  
 \*\*P value < 0.001 when compared to group I, #P value < 0.001 when compared to group II,  
 Group I: 2% gum acacia suspension p.o.  
 Group II: Methanol extract of *C. crepidioides* 100 mg/kg p.o.  
 Group III: Methanol extract of *C. crepidioides* 200 mg/kg p.o.  
 (One way ANOVA followed by Dunnett's test)

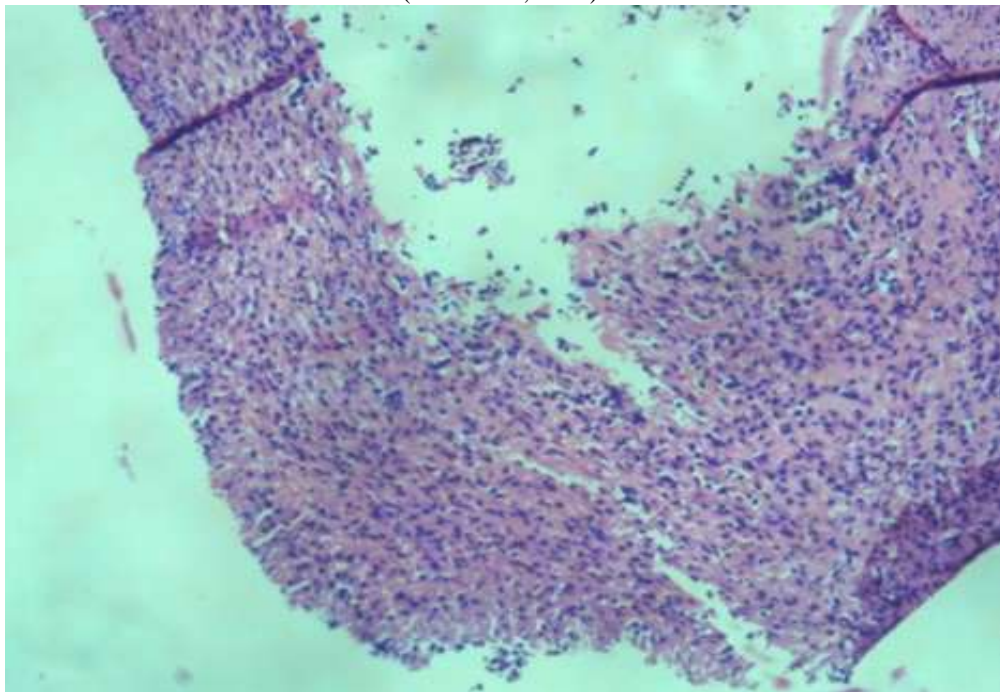
**Fig 4:-** Histogram showing comparison of tensile strength (gm wt) on 10<sup>th</sup> day in different groups.**Effect of methanol extract of *C. crepidioides* on granulation tissues in dead space wound model:**

The granulation tissues surrounding the cotton pellets were examined histologically. It was observed that there was an enhancement in the healing process in the treated groups as evidenced by increased neovascularization, abundant eosinophilic collagenous stroma along with numerous fibroblasts (Figs. 5a, 5b, 5c).

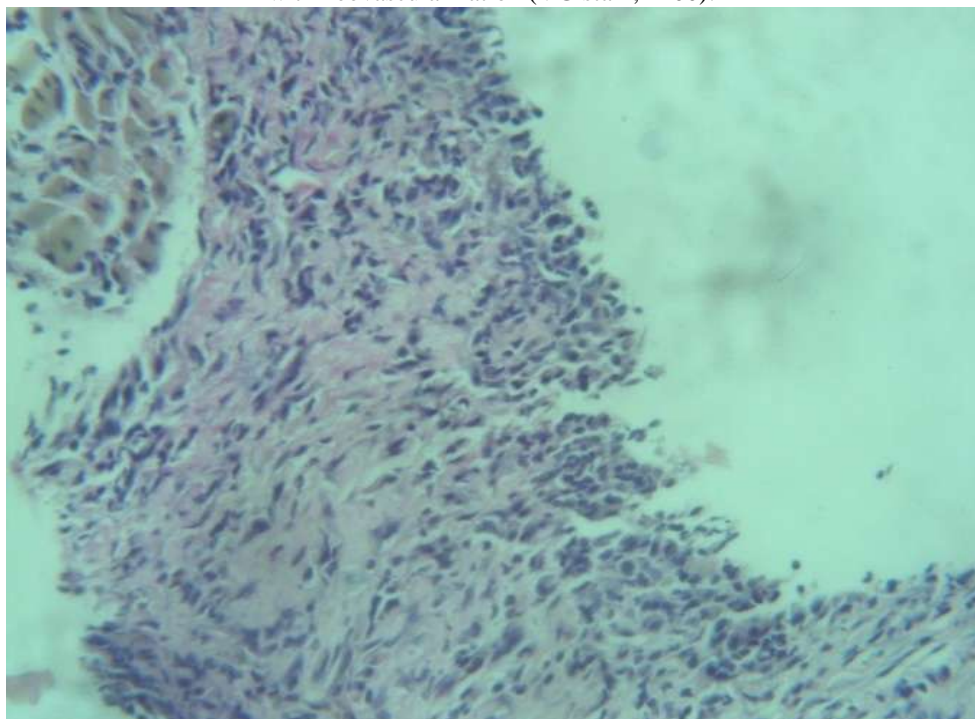
**Fig 5a:-** Mixed inflammatory cells composed of lymphocytes and PMN cells and newly formed blood vessels with myxoid collagen and plump fibroblasts (H&E stain, x200).



**Fig 5b:-** Mixed inflammatory cells with abundant eosinophilic collagenous stroma and scattered plump fibroblasts (H&E stain, x200).



**Fig 5c:-** Dense eosinophilic collagen with many plump fibroblasts in fascicles scattered mixed inflammatory cells with neovascularization (VG stain, x400).



### **Discussion:-**

There is an increasing interest in finding herbal extracts with wound healing activity although its use for treating cuts and wounds is a common practice in traditional medicine in many parts of the world. The wound healing process consists of four phases: haemostasis, inflammation, proliferation and remodelling. The initial step assists in the protection of the vascular system to maintain the functionality of the organ. The clot formed as a result of coagulation provides a matrix for the cells involved in subsequent steps of haemostasis and inflammation (18). Various pro-inflammatory cytokines and growth factors are released by the clot and wound tissue. Inflammatory cells then migrate to the wound site by the process of chemotaxis and promote the inflammatory phase (19-21). The inflammation helps to fight potential bacterial contamination of the wound and activates cytokine secretion (18,22). The proliferation phase overlaps with the preceding inflammatory phase. It represents a proliferation of both epithelial and dermal elements which results in re-epithelialization of the wound and laying down of the primary extracellular matrix (23). Angiogenesis occurs secondary to endothelial progenitor cells, a derivative of hematopoietic stem cells (24,25). Wound remodelling leading to scar formation. This phase marks the final step in tissue remodelling and differentiation leading to recovery of the skin and its aesthetic restoration (26,27).

The enhanced wound healing potency may be attributed to free radical-scavenging action and the antimicrobial property of the phytoconstituents present in the extract, and the quicker process of wound healing could be a function of either the individual or the synergistic effects of the bioactive molecules. These active constituents promote the process of wound healing by increasing the viability of collagen fibrils, by increasing the strength of collagen fibres either by increasing the circulation, preventing the cell damage or by promoting DNA synthesis (28).

In the present study, we studied wound healing properties of *C. crepidioides* using the widely accepted models-excision, incision and dead space wound models. We assessed the wound contracture and epithelialization in the excision wound model and tensile strength of the wound in the incision wound model. The granulation tissues collected from the dead space wound model in the different groups were assessed for the histological changes as done by other workers. The percentages of wound contraction on 5<sup>th</sup> and 10<sup>th</sup> day of treatment were found to increase significantly along with the decrease in the period of epithelialization. The tensile strength of the healed wounds was also increased significantly in the test drug treated groups when compared with the control group. The enhancement in the healing process by the methanol extract of *C. crepidioides* treated groups were supported by the histological

findings such as increased neovascularisation, abundant eosinophilic collagenous stroma along with numerous fibroblasts.

Preliminary phytochemical analysis of the methanol extract of *C. crepidioides* revealed the presence of steroids, flavonoids and tannins. Flavonoids are known to decrease lipid peroxidation by preventing the onset of cell necrosis and by improving vascularity (29). The inhibition of lipid peroxidation is believed to increase the viability of collagen fibrils by increasing the strength of collagen fibres, increasing the circulation, preventing the cell damage and by promoting the DNA synthesis. It also has potent antioxidant and free radical-scavenging effect thus enhancing the level of antioxidant enzymes in granuloma tissue (30). Tannins promote wound healing through various cellular mechanisms such as chelation of free radicals and reactive oxygen species, promoting contraction of the area of the wound and increasing the formation of blood vessels and fibroblasts including proliferation of the keratinocytes. Moreover, tannins are also known to help in wound healing for wound due to their astringent and antimicrobial property (30).

The results of the various parameters observed from the standard wound healing models show that the methanol extract of *C. crepidioides* enhanced the healing of wounds which may be attributed to the phytoconstituents present in the plant such as flavonoids and tannins.

### Conclusion:-

The methanol extract of *C. crepidioides* was studied for the wound healing property using the standard wound healing models in albino rats. The presence of significant wound contraction, decreased period of epithelialization and increased tensile strength shows that the plant has healing property. This property was supported by the presence of histological findings such as increased neovascularisation, abundant eosinophilic collagenous stroma along with numerous fibroblasts. The enhancement in the healing of wounds may be due to the presence of flavonoids and tannins.

### References:-

1. Pan SY, Litscher G, Gao SH, Zhou SF, Yu ZL, Chen HQ et al. Historical Perspective of Traditional Indigenous Medical Practices: The Current Renaissance and Conservation of Herbal Resources. *Evid Based Complement Alternat Med.* 2014 Apr 27. doi: 10.1155/2014/525340
2. Alam G, Singh MP, Singh A. Wound healing potential of some medicinal plants. *International Journal of Pharmaceutical Sciences Review and Research.* 2011 July-Aug;9(1).
3. Seth SD, Sharma B. Medicinal plants of India. *Indian J. Med. Res.* 2004;120(1):9-11.
4. Logeeswari K, Sripathi SK. Wound healing medicinal plants: A Review. *International Journal of Chemical, Environmental and Pharmaceutical Research* 2012;3(3):199-218.
5. Biswas TK, Mukherjee B. Plant medicines of Indian origin for wound healing activity: A Review. *Int J of Low Extrem Wounds.* 2003 March;2(1):25-39. doi: 10.1177/1534734603002001006
6. Jorim RY, Korape S, Legu W, Koch M, Barrows LR, Matainaho TK et al. An ethnobotanical survey of medicinal plants used in the eastern highlands of Papua New Guinea. *Journal of Ethnobiology and Ethnomedicine* 2012 Dec 18;8:47. <https://doi.org/10.1186/1746-4269-8-47>.
7. Dhiman A, Nanda A, Ahmad S, Narasimhan B. In vitro antimicrobial activity of methanolic leaf extract of *Psidium guajava* L. *J Pharm Bioallied Sci* 2011;3(2):226.
8. OECDiLibrary. OECD guidelines for the testing of chemicals, Section 4. Test no. 423: Acute Oral toxicity-Acute toxic class method. Available at: [http://www.oecd-ilibrary.org/environment/test-no-423-acute-oral-toxicity-acute-toxic-class-method\\_9789264071001-en](http://www.oecd-ilibrary.org/environment/test-no-423-acute-oral-toxicity-acute-toxic-class-method_9789264071001-en).
9. Kumar U, Kumar B, Bhandari A, Kumar Y. Phytochemical investigation and comparison of antimicrobial screening of clove and cardamom. *Int J Pharm Sci Res* 2010 Dec 1;1(12):138-47. doi: <http://dx.doi.org/10.13040/IJPSR.0975-8232>
10. Shah B, Seth AK. *Textbook of pharmacognosy and phytochemistry.* 2nd ed. New Delhi: Elsevier; 2014.
11. Dhanasekaran M, Abraham GC, Mohan S. Preliminary phytochemical and histochemical investigation on *Kigelia pinnata* DC. *International Journal of Pharma Sciences and Research* 2014 July;5(7):413-9.
12. Bargah RK. Preliminary test of phytochemical screening of crude ethanolic and aqueous extract of *Moringa pterygosperma*. *J Pharmacogn Phytochem* 2015;4(1):7-9.
13. Das K. Wound healing potential of aqueous crude extract of *Stevia rebaudiana* in mice. *Brazilian Journal of Pharmacognosy* 2013 Mar-April;23(2):351-7. <https://doi.org/10.1590/S0102-695X2013005000011>

14. Ehrlich HP, Hunt TK. Effects of cortisone and anabolic steroids on the tensile strength of healing wounds. *Ann Surg* 1969 Aug;170(2):203-6. doi: 10.1097/00000658-196908000-00007
15. Lee KH. Studies on mechanism of action of salicylates II. Retardation of wound healing by aspirin. *J Pharm Sci* 1968;57:1042-3.
16. Khan MA, Saxena A, Fatima FT, Sharma G, Goud V, Hussain A. Study of wound healing activity of *Delonix regia* in experimental animal models. *American Journal of Pharmtech Research* 2012;2(2):380-90.
17. Drury RAB, Wallington EA, Cameron R. *Carleton's Histological Techniques: 4th ed.* USA: Oxford University Press NY; 1967. 279-280 p.
18. Velnar T, Bailey T, Smrkolj V. The wound healing process: an overview of the cellular and molecular mechanisms. *J Int Med Res* 2009 Sep-Oct;37(5):1528-42. doi: 10.1177/147323000903700531.
19. Gosain A, DiPietro LA. Aging and wound healing. *World J Surg* 2004 Mar;28(3):321-6. doi: 10.1007/s00268-003-7397-6.
20. Broughton G, Janis JE, Attinger CE. The basic science of wound healing. *Plast Reconstr Surg* 2006 June;117(Suppl 7):12S-34S. doi: 10.1097/01.prs.0000225430.42531.c2.
21. Campos ACL, Groth AK, Branco AB. Assessment and nutritional aspects of wound healing. *Curr Opin Clin Nutr Metab Care* 2008 May;11(3):281-8. doi: 10.1097/MCO.0b013e3282fbd35a.
22. Wiksman LB, Solomonik I, Spira R, Tennenbaum T. Novel insights into wound healing sequence of events. *Toxicol Pathol* 2007 Oct;35(6):767-79. doi: 10.1080/01926230701584189.
23. Guo S, DiPietro LA. Factors affecting wound healing. *J Dent Res* 2010 Mar;89(3):219-29. doi: 10.1177/0022034509359125
24. Wu Y, Wang J, Scott PG, Tredget EE. Bone marrow-derived stem cells in wound healing: a review. *Wound Repair Regen* 2007 Sep-Oct;15(Suppl 1):18S-26S. doi: 10.1111/j.1524-475X.2007.00221.x.
25. Rea S, Giles NL, Webb S, Adcroft KF, Evill LM, Strickland DH, et al. Bone marrow-derived cells in the healing burn wound-more than just inflammation. *Burns* 2009 May;35(3):356-64. doi: 10.1016/j.burns.2008.07.011.
26. Diegelmann RF, Evans MC. Wound healing: an overview of acute, fibrotic and delayed healing. *Front Biosci* 2004 Jan 1;9:283-9. doi: 10.2741/1184.
27. Hackam DJ, Ford HR. Cellular, biochemical, and clinical aspects of wound healing. *Surg Infect (Larchmt)* 2002;3(Suppl 1):23S-35S. doi: 10.1089/sur.2002.3.s1-23.
28. Majumdar M, Nayeem N, Kamath JV, Asad M. Evaluation of *Tectona grandis* leaves for wound healing activity. *Pak J Pharm Sci* 2007;20(2):120-4.
29. Baravkar AA, Kale RN, Patil RN, Sawant SD. Pharmaceutical and biological evaluation of formulated cream of methanolic extract of *Acacia nilotica* leaves. *Res J Pharm Technol* 2008;1(4):481-3.
30. Shenoy C, Patil MB, Kumar R, Patil S. Preliminary phytochemical investigation and wound healing activity of *Allium cepa* Linn (Liliaceae). *Int J Pharm Pharm Sci* 2009;2(2):167-75.