



Journal Homepage: - www.journalijar.com

INTERNATIONAL JOURNAL OF ADVANCED RESEARCH (IJAR)

Article DOI: 10.21474/IJAR01/15894

DOI URL: <http://dx.doi.org/10.21474/IJAR01/15894>



RESEARCH ARTICLE

CONSERVATIVE MANAGEMENT OF CESAREAN SCAR ECTOPIC PREGNANCY

Dr. Jolapuramrajeswari and Dr. K. Sugunasree
Postgraduate OBGYNCOAUTHOR: kurnoolmedicalcollege.

Manuscript Info

Manuscript History

Received: 19 October 2022

Final Accepted: 24 November 2022

Published: December 2022

Abstract

Introduction:

Cesarean scar ectopic pregnancies are a complication of pregnancy, it may also follow previous hysterotomy for any cause, uterine manipulation and in vitro fertilization. Immediate prognosis depends on early diagnosis and management. Now presenting 2 cases which are successfully managed by medical management.

Aims and objectives:

To study the outcome of medical management in cesarean scar pregnancy.

Materials and methods: A case study was conducted at government general hospital, Kurnool, which were managed successfully with medical management.

Copy Right, IJAR, 2022.. All rights reserved.

Introduction:-

In cesarean scar pregnancy the gestational sac is implanted in the myometrium at the site of previous cesarean section.

Among all the ectopic pregnancies, cesarean scar pregnancy is a rare type of ectopic pregnancy associated with severe complications such as uterine rupture, massive hemorrhage.

Its incidence is rising in parallel with the increase in primary and repeat cesarean sections, currently about 1/1800 to 1/2200 normal pregnancies accounts for 6% of ectopic pregnancies.

We describe 2 cases of cesarean scar pregnancy treated by methotrexate injection.

Casei:

A 30 years old woman G5P3L2D1A1 with previous history of 2 cesarean sections, was referred from private hospital in view of cesarean scar ectopic pregnancy diagnosed in routine transabdominal first trimester scan.

Scan suggestive of a single gestational sac corresponding to 6 weeks 6 days with endometrial mantle sign with fetal cardiac activity with evidence of scar ectopic pregnancy.

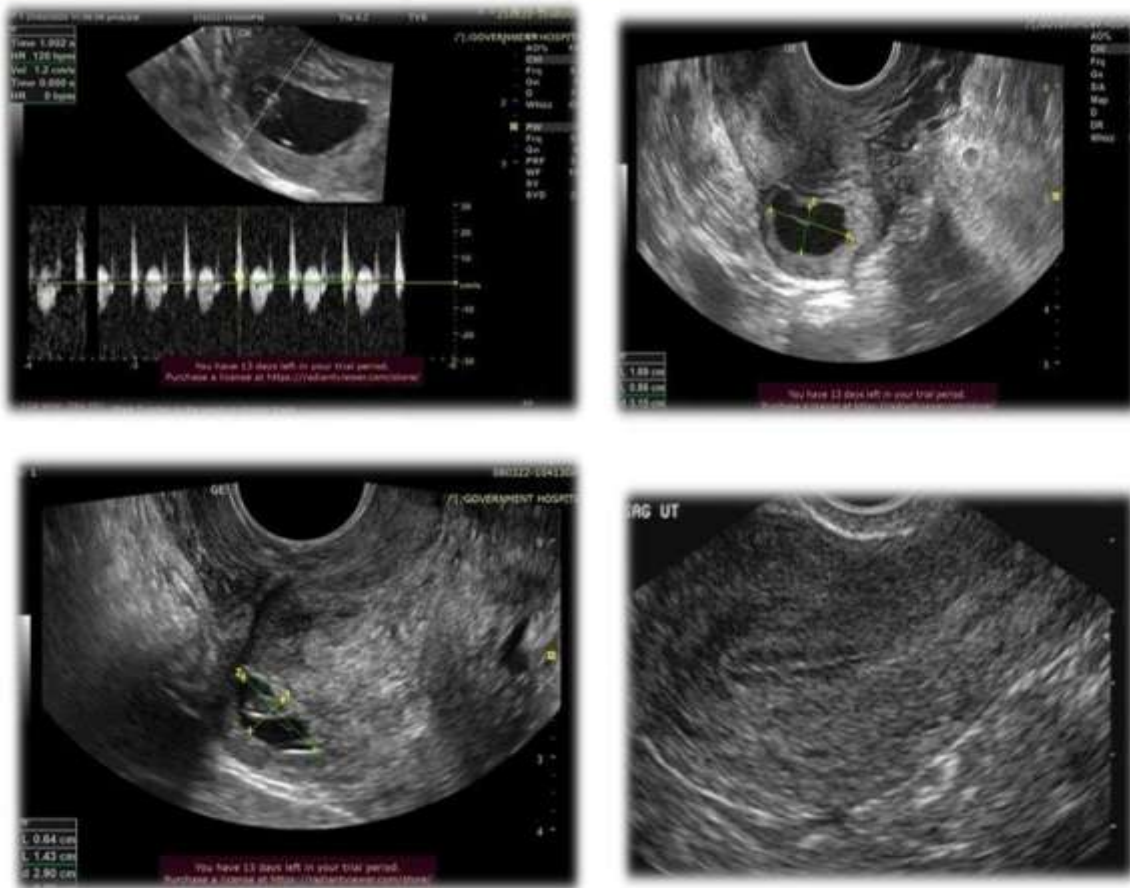
- Patient was asymptomatic at the time of admission.
- On examination patient vitals were stable.
- Uterine size could not be made out due to obese abdominal wall. Uterus appears anteverted with neither forniceal fullness nor forniceal tenderness. Cervical motion tenderness noted.

Corresponding Author:- Dr. Jolapuramrajeswari

Address:- Postgraduate OBGYNCOAUTHOR: kurnoolmedicalcollege.

Case-I

Day	Dose	al cardiac activity	Gestational sac	β -HCG
1	20mg intragestational sac induction	+	6wks	28450IU/ml
4	50mg IM	-	5×4mm subchorionic collection with insac	50030IU/ml
7			1.7×1cm gestational sac with fetal pole 1.1cm subchorionic collection	1326IU/ml
11			1.3×1.1cm ET-7mm	1097IU/ml
16			1.38×0.6cm ET-5.3	851IU/ml

**CaseII:**

- A 21 yr's old G2P1L1 with previous C/S delivery with complaints of 2 months amenorrhoea and bleeding PV for one day.
- Patient was admitted and on evaluation her Hb was 7.5gms and USG pelvis revealed 1.9×1.3cm's heterogenous lesion in lower part of anterior wall of uterus with thinning of myometrium
- Doppler study revealed increased peripheral vascularity around the lesions suggestive of scar ectopic pregnancy.
- Patient had 2 units of blood transfusion and was planned for medical management of scar ectopic pregnancy in view of low parity

Case-II

Day	Dose	β -HCG
1	50mgIM	12880IU/ml
4	-	5440IU/ml
7	-	650IU/ml

Discussion:-

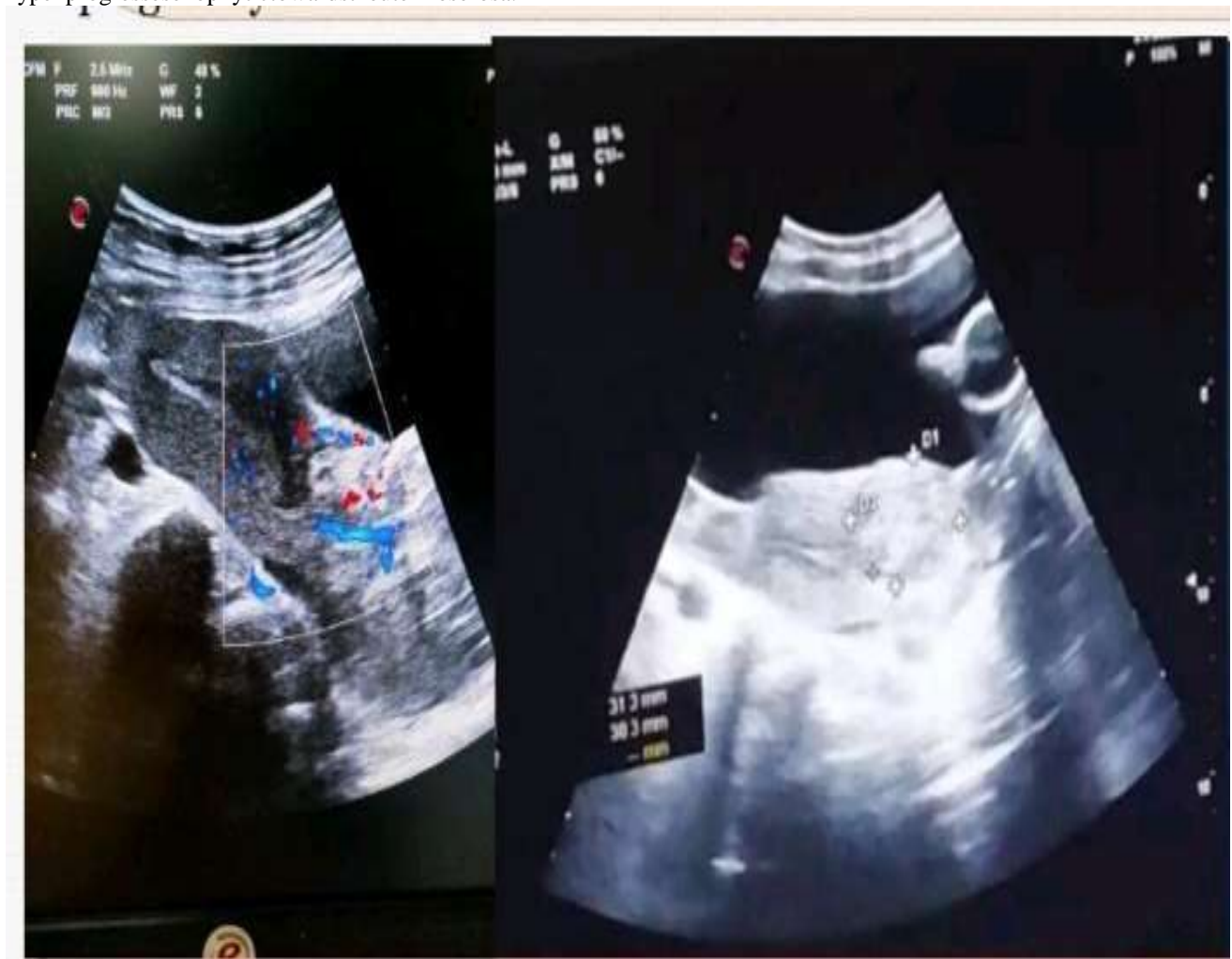Cesarean scar ectopic is defined as a gestation completely surrounded by myometrium and fibrous tissues of the cesarean section scar and separated from endometrial cavity and endocervical canal.

The first case was reported in 1978 (Larsen and Solomon) as a postabortal haemorrhage due to what the authors called a uterine scar sacculus.

There are two recognized types of scar ectopic pregnancies.

Type 1 develops in the myometrium and grows toward the uterine cavity

Type 2 progresses exophytic toward the uterine serosa.

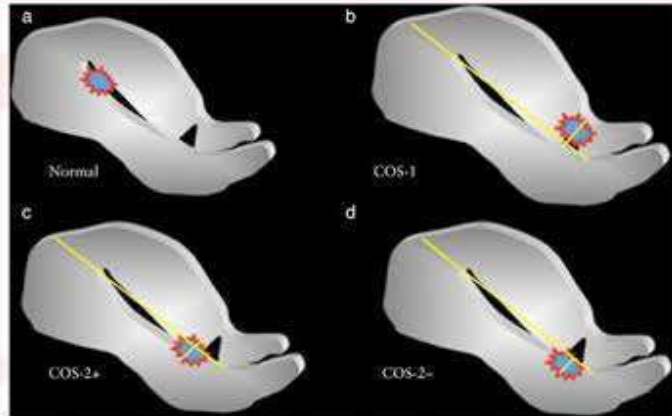


First-trimester prediction of surgical outcome in abnormally invasive placenta using the cross-over sign

Call et al., UOG 2018

The cross-over sign (COS)

In a sagittal view of the uterus, a straight longitudinal line is drawn connecting the internal cervical os and the uterine fundus through the endometrium, the gestational sac is identified and its superior-inferior (S-I) diameter perpendicular to the endometrial line is traced.



- **COS-1** – the gestational sac is implanted within the Cesarean scar (CS) and at least two-thirds of the S-I diameter of the gestational sac is above the endometrial line towards the anterior uterine wall.
- **COS-2** – the gestational sac is implanted within the CS and less than two-thirds of the S-I diameter of the gestational sac is above the endometrial line.
 - Cases in the latter group are further divided into the presence (**COS-2+**) or absence (**COS-2-**) of an intersection between the S-I diameter of the ectopic gestational sac and the endometrial line.

The pathophysiology of cesarean scar pregnancy it is possible that the conceptus penetrates the myometrium through a microscopic dehiscence tract of the cesarean scar or the gestational sac implantation occurs in a prior healed cesarean section scar.

It may also result from a defect in the endometrium caused by trauma created by procedures in assisted reproductive techniques.

Complications of cesarean scar pregnancy:

Catastrophic haemorrhage
 Increased risk of placenta accreta
 Rupture uterus
 Secondary abdominal pregnancy

Side effects of methotrexate:

Nausea and vomiting's
 Anemia and granulocytopenia
 Pain abdomen
 End stage liver disease
 Skin allergic reactions
 Increased risk of lymphoma

Treatment other modalities:

Expectant management
 Medical management
 Medical treatment combined with surgical aspiration of sac
 Surgical treatment:

uterine curettage e) hysterectomy
 hysteroscopic evaluation f) high intensity focussed USG ablation) laparoscopic excision
 g) HIFU + Hysteroscopic suction
 d) sacral resection
 Differential diagnosis:

- Spontaneous abortion
- Cervicoisthmic pregnancy
- Trophoblastic tumor
- Very low implanted intrauterine pregnancy

- It may result in a pregnancy that loses its vascular connections while growing, thus causing a spontaneous abortion, or it may continue to grow gaining new stronger vascular connections ending in a low lying adherent placenta with or without invasion of surrounding organs.

- Early diagnosis is thus important to avoid serious complications.

Conclusion:-

- Delayed diagnosis of caesarean scar ectopic may result in maternal mortality or may affect the obstetric future of the patient
- Therefore it is worth presenting an early diagnosis and effective management with medical treatment in a tertiary care center to preserve her future fertility

References:-

- [1] Herman A, Weinraub Z, Avrech O, Maymon R, Ron-El R, Bukovsky Y. Follow up and outcome of isthmic pregnancy located in a previous caesarean section scar. *British Journal of Obstetrics and Gynaecology*. 1995;102(10):839–41. [PubMed] [Google Scholar]
- [2] Seow KM, Hwang JL, Tsai YL, Huang LW, Lin YH, Hsieh BC. Subsequent pregnancy outcome after conservative treatment of a previous Caesarean scar pregnancy. *Acta Obstetrica et Gynecologica Scandinavica*. 2004;83(12):1167–72. [PubMed] [Google Scholar]
- [3] Cignini P, Giorlandino M, Caserta L, Dominici L, Giorlandino C. The importance of early diagnosis in Caesarean scar pregnancy. *J Prenat Med*. 2007;1(2):29–31. [PMC free article] [PubMed] [Google Scholar]
- [4] Aich R, Solanki N, Kakadiya K, Bansal A, Joshi M, Nawale A. Ectopic Pregnancy in caesarean section scar: A case report. *Radiology Case Reports*. 2015;10 (4):68–71. [PMC free article] [PubMed] [Google Scholar].