Journal Homepage: -www.journalijar.com

INTERNATIONAL JOURNAL OF ADVANCED RESEARCH (IJAR)

ISSN NO. 2320-5407

Article DOI:10.21474/IJAR01/16182
DOI URL: http://dx.doi.org/10.21474/IJAR01/16182

RESEARCH ARTICLE

BIOMECHANICAL EVALUATION FOR COMPARISON OF 3D TITANIUM MINIPLATES WITH CONVENTIONAL TITANIUM MINIPLATES IN THE MANAGEMENT OF MANDIBULAR FRACTURES

Dr. Neel Kamal[1], Dr. Vaz Ashwin Alwyn[2], Dr. Amit Sharma[3], Dr. Alfisha Sheikh[4] and Dr. Alankrita Sisodia[5]

1. Professor, Department of Oral and Maxillofacial Surgery, Rajasthan Dental College and Hospital, Jaipur.
2. Postgraduate, Department of Oral and Maxillofacial Surgery, Rajasthan Dental College and Hospital, Jaipur.
3. Professor and Head, Department of Oral and Maxillofacial Surgery, Rajasthan Dental College and Hospital, Jaipur.
4. Postgraduate, Department of Oral and Maxillofacial Surgery, Rajasthan Dental College and Hospital, Jaipur.
5. Assistant Professor, Department of Oral and Maxillofacial Surgery, Rajasthan Dental College and Hospital, Jaipur.

Manuscript Info

Manuscript History
Received: 29 November 2022
Final Accepted: 30 December 2022
Published: January 2023

Key words:-
Mandibular Fracture, Bite Force, 3D Titanium Miniplate, Conventional Titanium Miniplate

Abstract

Aim of the Study: The aim of the study was to evaluate and compare the efficacy of the 3-dimensional titanium miniplates against conventional titanium miniplates in the management of mandibular fractures.

Materials and Method: This study included 20 cases of either trauma, reconstructive or orthognathic surgery in which internal fixation is indicated. Patients were assigned to any one of the two equal groups randomly. Group A consisted of 10 patients treated by 3-dimensional titanium miniplates and group B consisted of 10 patients treated by conventional titanium miniplates. Intra-operative parameter included operating time of both the groups. Postoperative clinical examination was carried out on the 1st, 2nd, 3rd, 4th, 6th weeks and the 3rd postoperative month. Postoperative clinical evaluation included assessment of pain, stability, infection, bite force, wound dehiscence. The results of two groups were compared statistically.

Results:A statistically significant difference was found in the operating time which was less in group A as compared to group B ($p = 0.001$). The bite forces recorded on 1st postoperative week were more in group A as compared to group B and were found to be statistically significant at incisor region ($p=0.012$), right canine region ($p=0.014$), left canine region ($p=0.001$), right premolar region ($p=0.013$) and left premolar region ($p=0.046$). No significant difference was found in other clinical parameters.

Conclusion: Due to simultaneous stabilization at superior and inferior borders, operating time was relatively less. It provides three-dimensional stability at the fracture site. 3-dimensional miniplate seems to be an easy alternative to conventional miniplates.

Copy Right, IJAR, 2023,. All rights reserved.

Corresponding Author:- Dr. Neel Kamal
Address**:-** Professor, Department of Oral and Maxillofacial Surgery, Rajasthan Dental College and Hospital, Jaipur.

Introduction:-

Mandible, as a part of face is one of the commonest sites to be involved in maxillofacial trauma.[1] The frequency of symphysis fracture is more after traumatic events involving the mandible with a frequency of 9% to 57%.[2]

Fractures of facial skeleton result in discontinuity of bone. The aim of mandibular fracture treatment is restoration of anatomical form and function for which the fractured bone fragments need to be held in stable close apposition to promote uneventful healing.[3] The fracture of the mandible can be managed by closed reduction and intermaxillary fixation (IMF) but, displaced and unfavorable fractures require open reduction and internal fixation (ORIF) and also, conditions wherein IMF is contraindicated or undesirable, ORIF is preferred.[4] Internal fixation produces three dimensional stability of the fracture site which promotes primary healing.[5] Since its initial development in 1970s, methods of open reduction and internal fixation have changed and diversified enormously in past few years.[6] Two fundamentally different philosophies have evolved. Spiessel and AO/ASIF group advocated use of rigid plates with bicortical screws whereas; Champy advocated miniplate osteosynthesis using monocortical screws.[7] The rigid systems have been replaced by more functionally oriented systems and the term semi-rigid has gained importance.[5]

Miniplate osteosynthesis affords a reliable method of providing internal fixation of mandibular fractures without the need for intermaxillary fixation. The technique has advantage of allowing intraoral plate fixation while simultaneously adjusting the occlusion.[8] The 3-dimensional (3D) plating system for mandibular fracture treatment is relatively new. The 3-dimensional titanium miniplates and screws were developed and reported by Farmand and Dupoirieux. The plates are adapted to the bone according to Champy's principles and are secured with monocortical screws. The fundamental idea of three dimensional miniplate is based on the principle of the quadrangle as a geometrically stable configuration for support. Increased stability is achieved by the geometric shape that forms a cuboid rather than by its thickness or length.[9]

Due to the unique biomechanical behaviour of anterior mandibular fractures where there is high negative bending and high torsion moments, an optimal plate design in this region should be such that it counteracts these forces and provides stability in all dimensions.[10] Management of mandibular fractures in the intermental foramina region using standard miniplate by conventional technique preferably requires 2 miniplates with 2 holes on either side of fracture line to overcome the torsional forces whereas a 3D plate provides greater resistance against torque and a single plate allows simultaneous stabilization at both superior and inferior borders.[6]

Aim and Objectives:-

The aim of the study was to evaluate and compare the efficacy of the 3-dimensional titanium miniplates against conventional titanium miniplates in the management of mandibular fractures.

The objectives of the study included:

1. Operating time associated with 3D miniplates and conventional miniplates.
2. To evaluate the pain, postoperative infection and wound dehiscence.
3. To compare the postoperative stability and bite efficiency at the fracture site.

Materials and Method:-

Fig. 1:- Armamentarium.



Fig. 2:- 2.0 mm three-dimensional titanium miniplates (4 hole, 6 hole) and titanium screws.

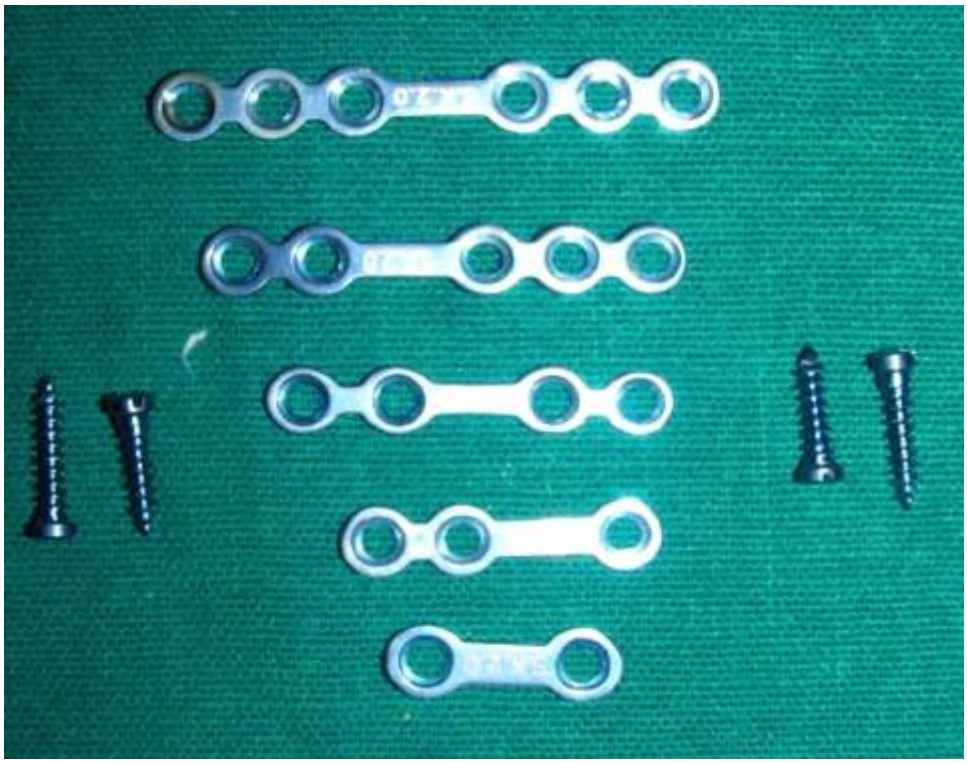

Fig. 3:- 2.0 mm standard titanium miniplates (6 hole, 5 hole, 4 hole, 3 hole, 2 hole) and titanium screws.

Fig. 4:- Digital bite force device.

Fig. 5:- Measurement of bite force.

The present study was carried out on 20 patients who underwent open reduction with internal fixation for mandibular fractures in the Department of Oral and Maxillofacial Surgery. The patients were enrolled for the study consecutively as and when they reported to the hospital. A detailed case history was recorded for every patient. Informed written consent was taken from each patient after explaining the nature of the study. Patients were randomly divided into group A & B. Group A consisted of 10 patients treated by 3D titanium miniplates and group B consisted of 10 patients treated by conventional titanium miniplates. Postoperative clinical examination was carried out on the 1st, 2nd, 3rd, 4th, 6th weeks and the 3rd postoperative month.

Inclusion Criteria:
1) Age of the patient 18 to 50 years with mandibular fractures.
2) Fracture of mandible without gross-comminution of the fracture segments.
3) Osteotomized bone segments for orthognathic surgery.

Exclusion Criteria:
1) Patients with comminuted fractures of mandible.
2) Severely infected fractures with large hematoma.
3) Patients with immunocompromised status.
4) Patients with multiple trauma requiring admission to the intensive care unit.

Preoperative evaluation of the patient:
The sample for study was chosen based on the above-mentioned criteria. A thorough history was noted including the time and date of accident, time of reporting to the department, mechanism of injury and history of bleeding from ear, nose and oral cavity. The patient was also questioned about the history of unconsciousness, vomiting and convulsions as well as the history of amnesia. This was followed by a detailed clinical examination. Stabilization was done using Erich's arch bar or interdental wiring. The face and the oral cavity were examined for signs of soft tissue injuries. All wounds were debrided and lacerated wounds were sutured with 3-0 Vicryl. Inj TT 0.5 ml IM was administered and patient were started on antibiotics and analgesics. Consent for the surgical procedure was taken.

Radiological Assessment:
The radiographic evaluation consisted of OPG, mandibular occlusal radiograph/PA view. CT scan was done in cases when deemed necessary. Radiographs were taken preoperatively and postoperatively followed up at regular intervals up to 3 months.

Operative Technique:
The method of surgical exposure of the fracture site and reduction of the fracture was similar to both groups of patients. All the plates and screws were placed through an intraoral approach under local anesthesia. All the patients were kept under appropriate antibiotic cover preoperatively and up to 7 days postoperatively. Intermaxillary fixation was achieved to settle the occlusion before surgery. Regional anesthesia was achieved with Lignocaine 2% and adrenaline 1:100000 by an Inferior Alveolar nerve block and infiltration anaesthesia.

Surgical Exposure:
Intra-orally, local infiltration was performed with Lignocaine 2%, after irrigating the oral cavity with betadine. An incision was made on oral mucosa 5 mm below the level of attached gingiva. It was extended parallel to the alveolar process. The incision was made so as to provide adequate exposure of fracture site. Mucoperiosteal flap was raised.

Reduction:
Fracture site was identified, and curetted with the help of curette to remove any trapped muscle, granulation tissue and blood clots. The fracture site was flushed with 5% povidone iodine followed by normal saline. The fragments were reduced manually in correct anatomical position. Occlusion was checked and temporary intermaxillary fixation done, in such a way so as to achieve the maximum apposition of the fracture fragments.

Results:-
Among 20 patients enrolled in the study, 15 were males and 5 were females with 10 patients in group A (3D titanium) and 10 in group B (conventional titanium).

Average age of subjects in group A was 31.3±8.68 years and that in group B was 30.1±8.33 years.

Table 1:- Distribution of study subjects based on gender.

	Male	Female
Group A	6	4
	60.0%	40.0%
Group B	9	1
	90.0%	10.0%

There were 6 (60%) male subjects and 4 (40%) female subjects in group A, and there were 9 (90%) male subjects and 1 (10%) female subjects in group B (**Table 1**).

Table 2:- Distribution of study subjects based on fracture site.

	Symphysis	Parasymphysis
Group A	03	07
	30.0%	70.0%
Group B	04	06
	40.0%	60.0%

Out of 10 patients in group A, there were three patients (30%) with fracture of symphysis site and seven patients (70%) with fracture of parasymphysis site. Out of 10 patients in group B, four patients (40%) were fracture of symphysis site and six patients (60%) were fracture of parasymphysis site (**Table 2**).

Table 3:- Intergroup comparison of mean time taken for surgery in different groups.

	Mean (Min)	SD	Std Error	P value	Significance
Group A	94.900	5.709	1.805	0.001	Significant
Group B	108.012	7.546	2.386		

The mean duration of surgery in group A was 94.9±5.709 min and that in group B was 108.0±7.546 min. There was a statistical significant difference in duration of surgery between both groups (p=0.001) (**Table 3**).

Table 4:- Intergroup comparison of pain scores.

		No Pain	Mild Pain	Moderate Pain	Chi Square	P value
1st Week	Group A	1	4	5	2.397	0.309 (Non-Sig)
		10.0%	40.0%	50.0%		
	Group B	3	5	2		

		30.0%	50.0%	20.0%		
2nd Week	Group A	6	4	0	2.301	0.302 (Non-Sig)
		60.0%	40.0%	0%		
	Group B	9	1	0		
		90.0%	10.0%	0%		
3rd Week	Group A	10	0	0	0.000	1.000 (Non-Sig)
		100.0%	0.0%	0%		
	Group B	10	0	0		
		100.0%	0.0%	0%		
4th Week	Group A	10	0	0	0.000	1.000 (Non-Sig)
		100.0%	0.0%	0%		
	Group B	10	0	0		
		100.0%	0.0%	0%		

During the 1st postoperative week, four patients reported mild pain and five reported moderate pain in group A and five patients reported mild pain and two reported moderate pain in group B. There was no statistical significant difference in both the groups (p=0.309). During the 2nd postoperative week, four patients reported mild pain in group A and one patient reported mild pain in group B. There was no statistical significant difference in both the groups (p=0.302). In both the groups, patients did not report with pain on 3rd and 4th week (p=1.000) (**Table 4**).

Table 5:- Intergroup comparison of infection among study subjects.

		No	Yes	Chi Square	P value
1st Week	Group A	08	02	0.647	0.832 (Non-Sig)
		80%	20%		
	Group B	07	03		
		70%	30%		
2nd Week	Group A	10	00	0.000	1.000 (Non-Sig)
		100%	00%		
	Group B	10	00		
		100%	00%		
3rd Week	Group A	10	00	0.000	1.000 (Non-Sig)
		100%	00%		
	Group B	10	00		
		100%	00%		
4th Week	Group A	10	00	0.000	1.000 (Non-Sig)
		100%	00%		
	Group B	10	00		

During the 1st postoperative week, infection was seen in two cases of group A and three cases of group B. Later, there were no cases of infection reported in both the groups. It was statistically insignificant by chi -square test (**Table 5**).

Table 6:- Intergroup comparison of wound dehiscence among study subjects.

		No	Yes	Chi Square	P value
1st Week	Group A	10	00	0.000	1.000 (Non-Sig)
		100%	00%		
	Group B	10	00		
		100%	00%		
2nd Week	Group A	10	00	0.000	1.000 (Non-Sig)
		100%	00%		
	Group B	10	00		
		100%	00%		
3rd Week	Group A	10	00	0.000	1.000 (Non-Sig)
		100%	00%		
	Group B	10	00		
		100%	00%		

4th Week	Group A	10	00	0.000	1.000 (Non-Sig)
		100%	00%		
	Group B	10	00		
		100%	00%		

In both the groups, patients did not develop wound dehiscence on all postoperative assessment days. There was no statistical significant difference among the groups with constant P value of 1 (**Table 6**).

Table 7:- Intergroup comparison of stability among study subjects.

		Yes	No	Chi Square	P value
1st Week	Group A	10	00	0.000	1.000 (Non-Sig)
		100%	00%		
	Group B	10	00		
		100%	00%		
2nd Week	Group A	10	00	0.000	1.000 (Non-Sig)
		100%	00%		
	Group B	10	00		
		100%	00%		
3rd Week	Group A	10	00	0.000	1.000 (Non-Sig)
		100%	00%		
	Group B	10	00		
		100%	00%		
4th Week	Group A	10	00	0.000	1.000 (Non-Sig)
		100%	00%		
	Group B	10	00		
		100%	00%		

In both the groups, fracture segments were stable for all the patients on all postoperative assessment days. There was no statistical significant difference among the groups with constant P value of 1 (**Table 7**).

According to present study, the bite forces recorded during preoperative period were more in group A than group B and were found to be statistically significant at incisor region (p=0.042), right canine region (p=0.018), left canine region (p=0.017), right premolar region (p=0.002) and left premolar region (p=0.015). The bite forces recorded on 1st postoperative week were more in group A than group B and were found to be statistically significant at incisor region (p=0.012), right canine region (p=0.014), left canine region (p=0.001), right premolar region (p=0.013) and left premolar region (p=0.046). The bite forces recorded on 2nd, 3rd, 4th, 6th postoperative weeks and 3rd postoperative month were not found to be statistically significant at incisor region, right and left canine regions, right and left premolar regions.

Discussion:-

In the current study, totally 20 mandibular fracture patients were selected and divided into two groups. First group included ten patients in whom fracture fixation was done by 3D titanium plate and second group included ten patients in whom fracture fixation was done by conventional titanium miniplates.

The age of the patients in this study was in the range of 18 to 50 years. This was in accordance with Norhan et al. (2016)[11] who reported mean value of age group as 33.15 years and Kumar et al. (2012)[12] who reported mean value of 33.9 years.

In this current study, incidence of mandibular fractures in males compared with that of females was in the ratio of 3: 1. This was in agreement with Yadav. S et al. (2015)[13] who reported occurrence of mandibular fractures in male population as 90% and in female population as 10 %.

In the present study, anterior mandibular fractures were selected and the case selection was done on the basis of studies conducted by Andrew J.L Gear et al. (2005)[14]. According to them, 3D plates were typically used in symphyseal/parasymphyseal fractures, which are under a great degree of torsional strain than other areas of mandible. These unique plates may theoretically provide increased torsional stability.

In the present study, operating time for group A patients ranged from 85 min to 101 min with mean value of 94.90 min. For group B patients, the value ranged from 97 min to 119 min with the mean value of 108.01 min. The comparison showed statistically significant difference with p value of 0.001. The result of this study was in agreement with Manoj Kumar Jain et al. (2010)[9]. The current study was also supported by the results from Zix et al. (2007)[15] and Maninder et al. (2017)[16]. 3D plate brings about easy adaptation of plate in achieving simultaneous stabilization of fracture site both at superior and inferior border of the mandible at a time in single plate usage itself. Whereas for conventional miniplates there is a need of two plates to bring about stabilization of fracture site. Thus, 3D plate fixation saves operation time in comparison with conventional miniplates.

In the present study, on the 1st postoperative week, moderate pain was noted in 5 patients and mild pain was noted in 4 patients of group A. In group B, moderate pain was noted in 2 patients, and mild pain was noted in 5 patients. Thereafter, pain decreased in the subsequent visits with report of no pain in the 3rd postoperative week in both groups. There was no statistical significant difference among the groups in 1st, 2nd, 3rd and 4th postoperative weeks. The results were in agreement with the study conducted by Yogesh Mittal et al. (2016)[17]. The results were also in agreement with Jitender et al. (2019)[18] and Deepak et al. (2019)[19].

In the present study, infection was present in 2 patients in group A and 3 patients in group B during 1 week postoperatively. From 2nd week, patient did not report infection in both the groups. There was no statistical significant difference for infection in both the groups. This study was in accordance with Farmand et al. (1992)[20] who did a study on 95 mandibular body fractures fixed with 3D (4 holed) square plates. He reported presence of 1 late infection in 1 patient. Guimond et al. (2005)[21] also reported infection rate of 5.4% (2 out of 37 patients) with usage of 3D plates.

In the present study, no patients reported with wound dehiscence postoperatively in both the groups. There was no statistical significant difference among the groups. This study was in accordance with Niranjan et al. (2019)[22].In their study on 40 patients of mandibular fractures equally divided into 2 groups (one group treated with 2D and the other with 3D miniplates) reported no case of wound dehiscence postoperatively in any group. The results were also in agreement with Manoj Kumar Jain et al. (2010)[9] and Deepak et al. (2019)[19].

In the present study, all patients in both groups of 3D plates and conventional miniplates showed no postoperative mobility of fracture segments. The comparison showed no statistical significant difference with constant p value 1. This was in agreement with Gabrielli et al. (2003)[23], Mittal and Dubbudu et al. (2012)[5], Bipin et al. (2013)[24], who all reported no postoperative mobility of fractured segments in both groups of 3D plates and conventional miniplates.

The bite force is related to a number of factors, including tactile impulses, pain and pressure reception in the periodontal ligament, the number of residual teeth and patient age, because a reduction in bite force can occur with age owing to the age-dependent deterioration of the dentition. It has long been known that a neuromuscular protective mechanism occurs throughout the body. For instance, one of the first protective mechanisms called into play when a fracture occurs is “muscle splinting” in which selective components of the neuromuscular system are activated or deactivated to remove the force from the damaged bone. In 1994, Tate et al stated that sufficient internal fixation hardware should be applied to resist the maximal force of mastication. Thus, they hypothesized that the stability of fracture segment would be ensured even under the full function of the masticatory system. The amount of force generated by the patients with untreated as well as treated fractures is much less. Furthermore, one must remember that the data reported concerned the maximal voluntary bite force (i.e., the maximum bite force an individual can voluntarily generate) the amount of force used during functional activities would probably be much less. Hence, the fixation requirements, determined from the maximal voluntarily bite force of noninjured subjects, might be inflated, and this fixation requirement is perhaps a semirigid form of fixation such as monocortical fixation.[25] In 2002, Gerlach and Schwarz in their study bite force of treated mandibular angle fractures concluded that the maximal bite force in patients with mandibular fractures treated with miniplate osteosynthesis had reached only 31% at 1 week postoperatively compared with a healthy control group. These values had increased to 58% at 6 weeks postoperatively.[26] Similarly in the present study, a positive co relation was found between postoperative anterior and posterior bite force in both the groups. There was a progressive increase in the bite force readings from the pre operative to 3 months postoperatively in both the groups. The mean difference between the 2 groups is statistically significant during 1st postoperative week at incisors, canines and premolars with $p<0.05$. The mean difference between the 2 groups is not statistically significant from 2nd postoperative week to 3rd month at incisors, canines and premolars. Hence there is no statistically significant difference in the stability of 3D miniplates and

conventional miniplate systems. Limitations of the present study include the shorter follow up period and a smaller sample size. To show significant improvements of 3D plates/screws, further studies with a larger sample size with longer follow up is required.

Conclusion:-

The following conclusions were drawn from the study:

1. 3D plates were indeed easy and simple to use. Significant reduction in operating time could be achieved with the use of 3D plates which makes it a time-saving.
2. Patients treated with 3D plates showed a less incidence of postoperative infection.
3. Other complications were found to be extremely rare.
4. This 3D plating system can be used with satisfactory results, especially in anterior mandibular fractures.
5. This technique does not require expensive armamentarium.
6. These plates ensure three-dimensional stability and the period of immobilization was not necessary as in other systems. Thereby, the morbidity associated with prolonged immobilization is reduced.
7. This system requires lesser area of exposure.

The probable limitations of 3D plates may be excessive implant material due to the extra vertical bars incorporated for countering the torque forces, cases where the fracture line passes through the mental foramina region and angle of the mandible where 3D plates cannot be adapted. The results of the present study were put to comparison with previous studies on fracture mandible and were found to be in accordance with them where 3D plates cannot be adapted.

All patients in present study appreciated early recovery of normal jaw function, primary healing and good union at fracture.

To conclude, 3D plate seems to be an easy alternative to conventional miniplates. The small sample size and limited follow up could be considered as the limitations of our study. It is hence recommended to have a multicentre study with large number of patients, with larger period of follow-up and correlation among these studies to authenticate our claims.

Declaration:
Funding:
Nil

Conflict of interest:
There are no conflicts of interest

Ethical approval:
Approved

References:-

1. Kruger GO. Oral and Maxillofacial Surgery. 6th ed. Jaypee Brothers;1990pg.364.
2. Ji B, Wang C, Liu L, Long J, Tian W, Wang H. A Biomechanical analysis of titanium miniplates used for treatment of mandibular symphyseal fractures with finite element method. Oral Surg Oral Med Oral Path Oral Radio Endo 2010;109:e21-e27.
3. Hayter JP, Cawood JI. The functional case for miniplates in maxillofacial surgery. Int J Oral Maxillofac Surg 1993;22:91-96.
4. Kuriakose MA, Fardy M, Sirikumara M, Patton DW, Sugar AW. A comparative review of 266 mandibular fractures with internal fixation using rigid (AO/ASIF) plates or mini-plates. British Journal of Oral and Maxillofacial Surgery 1996;34: 315-321.
5. Mittal G, Dubbudu RR, Cariappa KM. Three Dimensional titanium miniplates in oral and maxillofacial surgery: A prospective clinical trial. J Maxillofac Oral Surg 2012;11(2):152-159.
6. Jain MK, Sankar K, Ramesh C, Bhatta R. Management of mandibular interforaminal fractures using 3 dimensional locking and standard titanium miniplates–A comparative preliminary report of 10 cases. Journal of Craniomaxillofacial Surgery 2012;1-4.

7. Goyal M, Marya K, Chawla S, Pandey R. Mandibular osteosynthesis: A comparative evaluation of two different fixation systems using 2mm titanium miniplates and 3D locking plates. J Maxillofac Oral Surg 2011;10(1):32-37.
8. Marentette L. Miniplate osteosynthesis of mandible fractures. Operative techniques in Otolaryngology-Head and Neck surgery 1995;6(2):86-88.
9. Jain MK, Manjunath KS, Bhagwan BK, Shah DK. Comparison of 3-dimensional and standard miniplate fixation in management of mandibular fractures. J Oral Maxillofac Surg 2010;68:1568-1572.
10. Tams Van Loon JP, Rozema FR, Otten E, Bos RM. A three dimensional study of loads across the fracture for different sites of mandible. British Journal of Oral and Maxillofacial Surgery 1996;34:400-405.
11. Norhan A. El Nakeeb 1, Mostafa M. El Dibany, Mohamed M. Shokry. A comparative study between 3 -d plates and conventional miniplates for internal fixation of anterior mandibular fractures . Alexandria Dental Journal; Vol.41, Pages:253 -260, 2016.
12. B.Pavan Kumar, Jeevan Kumar, A.P. Mohan, V. Venkatesh & H.Rahul Kumar; A Comparative Study Of Three Dimensional Stainless Steel Plate Versus Stainless Steel Miniplate In The Management Of Mandibular Parasymphysis Fracture: J. Bio. Innov 1(2), Pp: 19 -32 , 2012.
13. Yadav S, Agarwal A, Singh S, Kumar S, Anand KR, Chhabra V. 3 -D locking titanium miniplates in management of mandibular fracture: A prospective clinical study. J Dent Specialit ; 3 (1) : 64 - 67, 2015.
14. Andrew J. L. Gear, Elena Apasova, John P. Schmitz and Warren chubert; Treatment Modalities for Mandibular Angle Fractures: J Oral Maxillofac Surg 63:655 -663, 2005.
15. J.Zix, Olivier Lieger, and T. Lizuka; Use of straight and curved 3-dimensional titanium miniplates for fracture fixation at the mandibular angle: J Oral Maxillofac Surg 65: 1758 - 1763, 2007.
16. Maninder Jambhulkar, Sumit Gupta, Hemant Gupta, S Mohammad, "Study of Comparison of Bite Force between Conventional and 3D Miniplate in Mandibular Fractures", International Journal of Science and Research (IJSR), Volume 6 Issue 10, October 2017, pp. 153-158.
17. Mittal Y, Varghese KG, Mohan S, Jayakumar N, Chhag S. A Comparative Study of 3-dimensional Titanium Versus 2-Dimensional Titanium Miniplates for Open Reduction and Fixation of Mandibular Parasymphysis Fracture. J Maxillofac Oral Surg. 2016 Mar;15(1):93-8. doi: 10.1007/s12663-015-0780-7.
18. Aurora JK, Tiwari S, Dubey KN, et al. Conventional Versus 3D Plates for Mandibular Anterior Region Fractures: A Comparative Study. The Traumaxilla. 2019;1(2-3):49-56.
19. Deepak Yadav, Ravish Mishra, Shashank T, et al. (2019) 3 - Dimensional versus Conventional Titanium Miniplate osteosynthesis in mandibular fracture – A Comparative study. Advanced Research in Dentistry and Oral Hygiene 1(1): 1-11.
20. Farmand. M, Dupoinrieux L; The value of 3 - dimensional plates in maxillofacial surgery. Rev Stomatol chir Maxillofac 1992; 93 (6):353 -357.
21. Claude Guimond, James V. Johnson, and J.M.Marchena ; Fixation of mandibular angle fractures with a 2.0 -mm 3 -Dimensional curved angle strut plate: J Oral Maxillofac Surg 63: 209 - 214, 2005.
22. Mishra N, Thakkar N, Kar I, Baig SA, Sharma G, Kar R, Sahu GR, Birmiwal KG. 3D Miniplates Versus Conventional Miniplates in Treatment of Mandible Fractures. J Maxillofac Oral Surg. 2019 Mar;18(1):65-72. doi: 10.1007/s12663-017-1068-x.
23. Marisa Aparecida Cabrini Gabrielli, Mario Francisco Real Gabrielli, Elcio Marcantonio, and Eduardo Hoch uli-Vieira; Fixation of Mandibular Fractures With 2.0 -mm Miniplates: Review of 191 Cases: J Oral Maxillofac Surg 61: 430 -436, 2003.
24. Bipin S Sadhwani, Sonal Anchlia . Conventional 2.0 mm miniplates versus 3 -D plates in mandibular fractures. Ann Maxillofac Surg.; 3 (2) : 154 –159, 2013.
25. Aggarwal M, Mohammed S, Singh RK, Singh V. Prospective randomized clinical trial comparing bite force in 2.0mm locking plate versus 2.0mm standard plates in treatment of mandibular fractures. J Oral MaxillofacSurg 2011;69:1995-2000.
26. Gerlach KL, Schwarz A. Bite forces in patients after treatment of Mandibular angle fractures with miniplateosteosynthesis according to Champy. Int J Oral MaxillofacSurg 2002;31:345–348.