



Journal Homepage: - [www.journalijar.com](http://www.journalijar.com)

## INTERNATIONAL JOURNAL OF ADVANCED RESEARCH (IJAR)

Article DOI: 10.21474/IJAR01/16547

DOI URL: <http://dx.doi.org/10.21474/IJAR01/16547>



### RESEARCH ARTICLE

#### STUDY ON ETIOLOGICAL PROFILE OF PATIENTS WITH PAPILLOEDEMA

Akhila Ravipati<sup>1</sup>, P. Viswabharathi<sup>2</sup> and Channa Bhaskar Sai<sup>3</sup>

1. Postgraduate, Department of Ophthalmology, Government Regional Eye Hospital, Visakhapatnam, Andhra Pradesh, India.
2. Assistant Professor, Department of Ophthalmology, Government Regional Eye Hospital, Visakhapatnam, Andhra Pradesh, India.
3. Postgraduate, Department of Ophthalmology, Government Regional Eye Hospital, Visakhapatnam, Andhra Pradesh, India.

#### Manuscript Info

##### Manuscript History

Received: 30 January 2023

Final Accepted: 28 February 2023

Published: March 2023

##### Key words:-

Papilledema

#### Abstract

**Aims and objectives :** To study the aetiological pattern in Papilledema, To study the involvement of 6th cranial Nerve in Papilledema, To study the visual acuity pattern in papilledema, To study the visual field pattern in papilledema.

**Materials and Methods:** This observational study was conducted at andhra Medical College ,vizag for a period of 4 months from feb 2022 to may 2022 .After taking informed consent of 15 Patients with papilledema who were referred from various departments in KGH were examined thoroughly as per proforma. We included patients with papilledema on ophthalmoscopic examination admitted in department of medicine . We excluded patients with optic disc swelling due to other cause that do not involve raised intracranial pressure, and Patient with head injury.All subjects were subjected to routine and special investigation to ascertain the Etiological Proportion of papilledema.In this study patients included on the basis of fundus examination done by slit lamp examination with 78D, and graded according to frisen scale of papilledema . Patients who had papilledema undergoes to evaluation of history, general examination and investigational work up. Then all patient had neuroimaging to detect intracranial pathology and lumbar puncture done in those patient who have no contraindication.

**Results:** Among 15 cases majority were Females(60%),majorly are of 3rd & 4th decade,vision improving to 6/6 with correction (90%),mri showed space occupying lesions(53.3%),associated with 6th nerve palsy in (44.4%),visual fields showed enlarged blind spot in most of the cases(47%).

**Conclusion:** in our study most common etiological factor is space occupying lesion.not all papilledema are associated with 6th nerve palsy.not all papilledemas have visual field defects.

Copy Right, IJAR, 2023,. All rights reserved.

#### Introduction:-

- Papilledema is one of the true neuro ophthalmic emergencies .

**Corresponding Author:- Akhila Ravipati**

Address:- Postgraduate, Department of Ophthalmology, Government Regional Eye Hospital, Visakhapatnam, Andhra Pradesh, India.

- “Papilledema is defined as a passive, non inflammatory edema of the optic nerve head due to raised intracranial pressure, which is almost always bilateral and without visual deficit”.
- Optic disc is the watershed zone between retina and optic nerve. It is the exit site of all ganglion cell axons of the retina, which converge at the optic disc to leave the eye and form the optic nerve.
- The optic disc is located in the nasal retina 3-4 mm from fovea. It is 1.88mm in vertical diameter and 1.76 mm in horizontal diameter. Since there are no photoreceptors over the disc, it is projected in visual space as an absolute scotoma, “The Blind spot of mariotte”.
- The blind spot is centered 15 deg from fixation and slightly below the horizontal meridian in the temporal visual field. It represents 7 deg /5 deg in the visual space [1].

#### **Blood supply of optic nerve:**

Surface area is supplied by retinal capillaries. Pre laminar region is supplied by peripapillary choroidal vessels. Laminal portion of optic nerve head (ONH) receives its blood supply from circle of Zinn, formed by short ciliary vessels. Post laminar area is supplied by branches of pial plexus from central retinal artery (CRA).

- The optic nerves are surrounded by meningeal sheaths, dura, arachnoid & pia mater upto lamina cribrosa.
- There is extension of the Intracranial subarachnoid space forward around the optic nerve to the back of the eyeball.

#### **Theories Of Papilledema:**

##### **Non mechanical theory :**

1).Gowers theory of inflammation,2). Jackson’s theory of vasomotor instability.

##### **Mechanical theory**

##### **Axoplasmic Flow:**

Normally there is a continuous flow of axoplasm along the axons of optic nerve. This axoplasmic transport consists of mucopolysaccharides, proteins, glycolipids, gangliosides, phospholipids, cholesterol, smooth endoplasmic reticulum and associated elements.

There are two types of axoplasmic transport 1). Anterograde flow or orthograde transport ,2). Retrograde flow  
**HAYREH’S THEORY OF PAPILLEDEMA** • Hayreh has demonstrated the increase intracranial pressure (ICP) in the subarachnoid space(SAS) is easily transmitted to the perineural space[6]

#### **Materials And Methods:-**

Cases studied were 15 patients with Papilledema who presented to department of neuro ophthalmology at the Government Regional eye hospital,vizag from feb 2022 to may 2022 . All the age groups and both sexes were included. A complete ophthalmological workup was done.Proper history was taken ,complaints were asked,General vital data like pulse, blood pressure, peripheral pulses are noted. Higher mental function status also noted.

##### **Ocular examination:**

Head posture, facial symmetry are noted. • Any deviation of eyeball is recorded. Under slit lamp, details of the anterior segment were seen. • Pupil size, reaction, any anisocoria is noted. • Extraocular movements are noted down-both ductions and versions in all cardinal positions • A dilated fundus examination and refraction is done. • Diplopia charting . • A forced duction test( if necessary).

##### **Neurologic Examination:**

Examination of other cranial nerves, Motor, sensory, cerebellar symptoms and signs are noted.

##### **Investigations:**

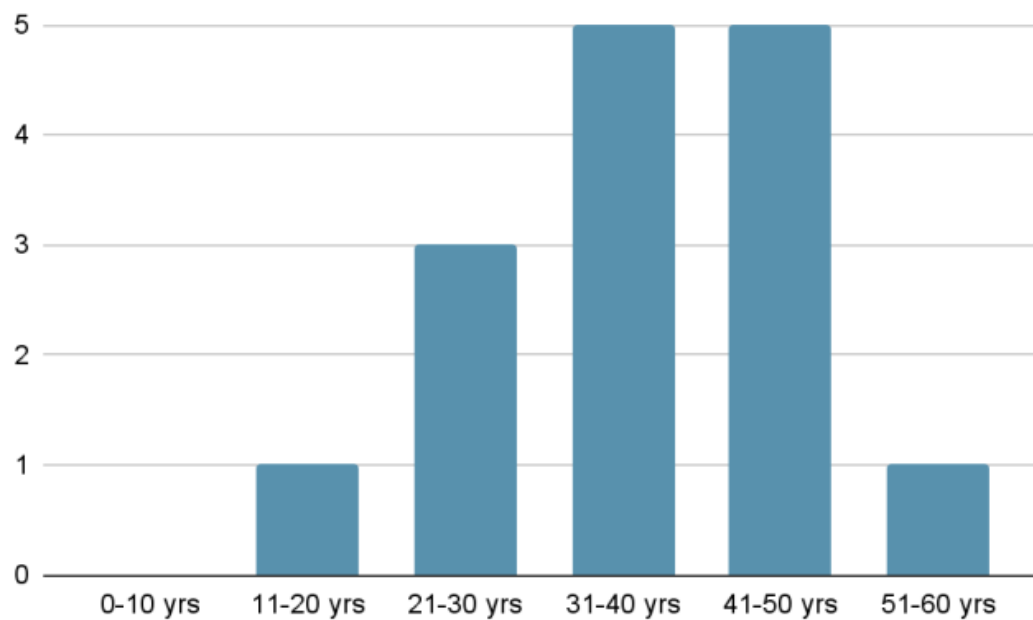
1. Visual field examination.
2. Blood investigations(if necessary).
3. NEUROIMAGING: CT or MRI , MRA/MRV(if necessary)
4. Specialist opinion: Neuro physician / Neurosurgeon.

**Results:-**

Majority where in age group of 31-50 yrs among the total 15 patients.

AGE (IN YEARS)	NO. OF PATIENTS	%
0-10 yrs	0	0
11-20 yrs	1	6
21-30 yrs	3	20
31-40 yrs	5	33
41-50 yrs	5	33
51-60 yrs	1	6
<b>TOTAL</b>	<b>15</b>	<b>100</b>

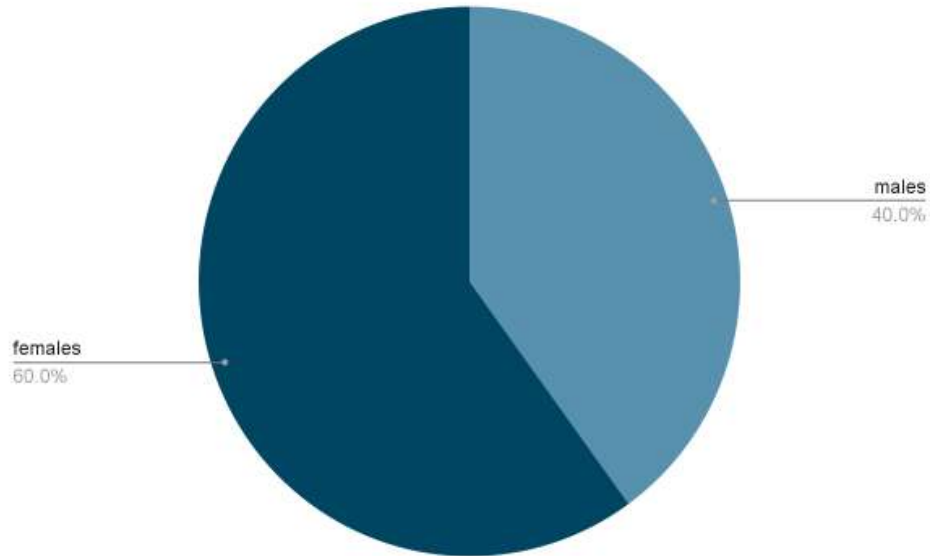
**Table 1:-** Age Distribution Of Papilledema.



**Figure 1:-** Depicting Age Distribution.

**Table 2:-** Gender Distribution.

GENDER	CASES	%
Males	6	40
Female	9	60
Total	15	100



**Figure 2:-** Gender Distribution.

**Table 3:-** Distribution Of Cases According To Etiology.

<b>Aetiology</b>	<b>No.of cases</b>	<b>%</b>
Space occupying lesion(SOL)	8	<b>53</b>
Meningitis	2	<b>13</b>
Thrombosis	0	<b>0</b>
Trauma	1	<b>6</b>
Post surgical/medication use	1	<b>6</b>
Systemic condition	1	<b>6</b>
idiopathic	2	<b>13</b>
<b>TOTAL</b>	<b>15</b>	<b>100</b>

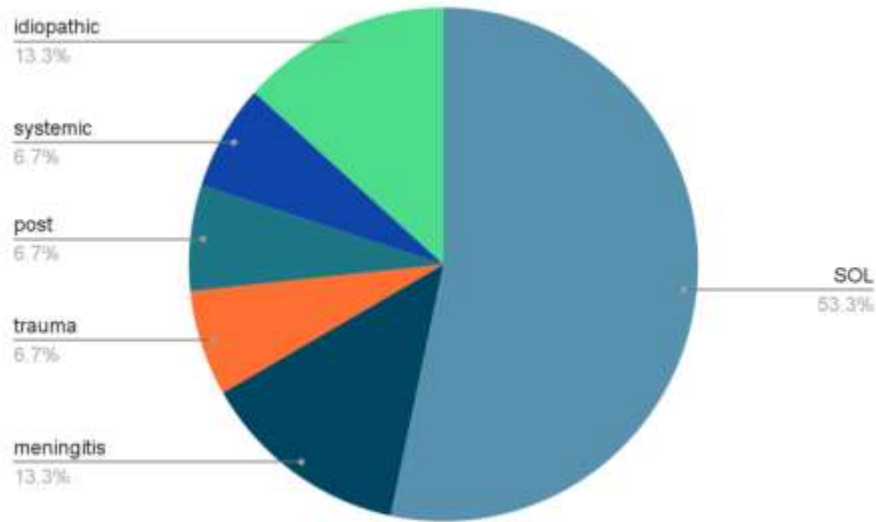


Figure 3:- Etiological Pattern.

Table 4:- Distribution Of Cases According To Sixth Nerve Involvement.

	NO. OF CASES	%
SIXTH NERVE PALSY	2	13.3
SIXTH NERVE NORMAL	13	86.7
<b>TOTAL</b>	<b>15</b>	<b>100</b>

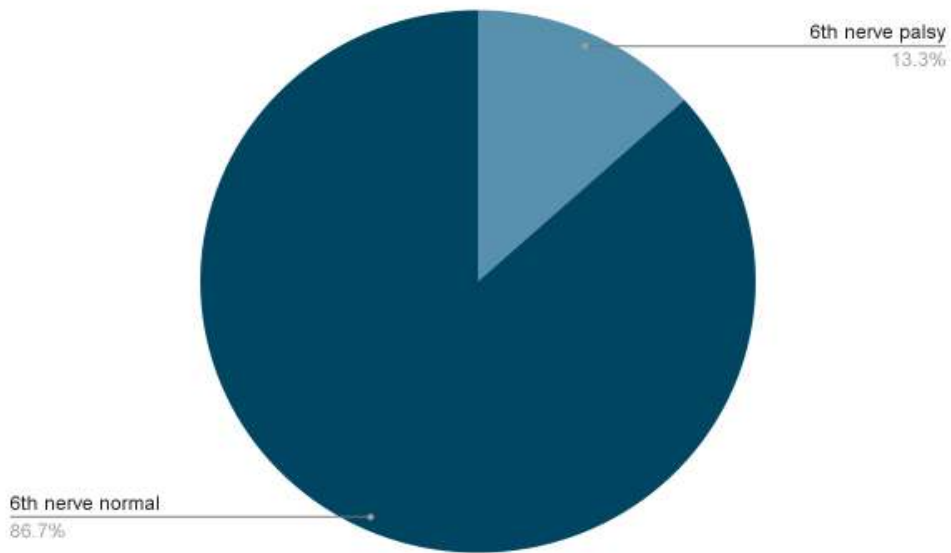


Figure 4:- Sixth Nerve Involvement Distribution.

Table 5:- Distribution Of Cases According To Visual Acuity.

	NO. OF CASES	%
VISION 6/6	3	20
WITH CORRECTION 6/6	9	60
NIG	3	20
<b>TOTAL</b>	<b>15</b>	<b>100</b>

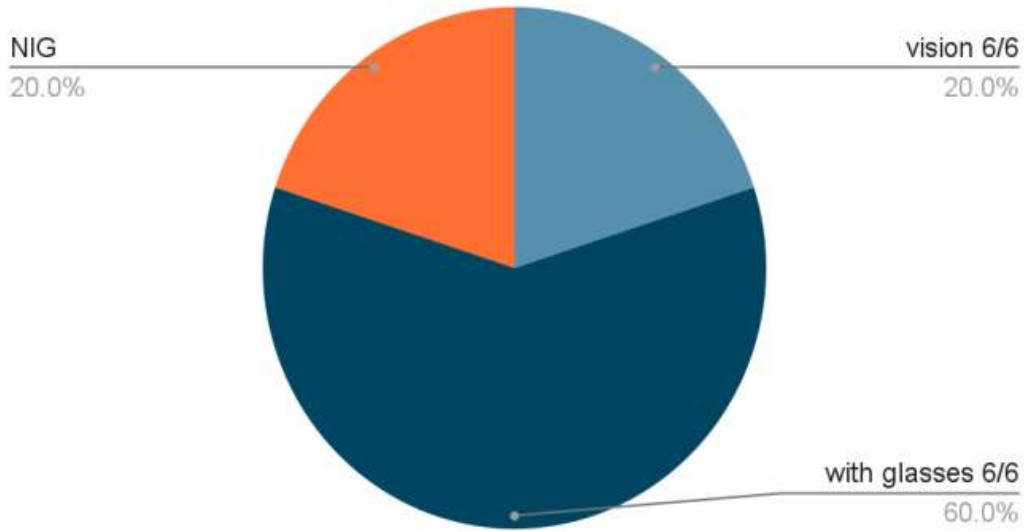
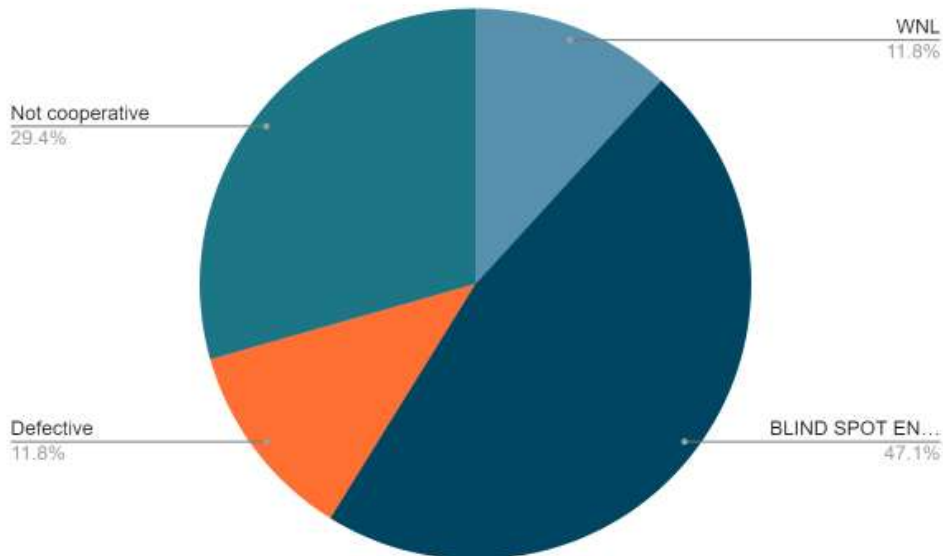


Figure 5:- Distribution Of Cases According To Visual Acuity.

Table 6:- Visual Fields In Papilledema.

	No Of Cases	PERCENTAGE
WNL	2	13
BLIND SPOT ENLARGEMENT	8	53
DEFECTIVE	2	13
NOT COOPERATIVE	3	20
TOTAL	15	100



**Discussion:-**

Among 15 cases majority were Females(60%),majorly are of 3rd & 4th decade,bilateral(100%),mri showed space occupying lesions(53.3%),vision improving to 6/6 with correction (60%),associated with 6th nerve palsy in (13.3%),visual fields showed enlarged blind spot in most of the cases(53%)[11]

NAMITHA et.al conducted Among 45 cases majority were Females(66.7%),majorly are of 2nd decade,bilateral(96%),mri showed space occupying lesions(60%),vision 6/6 improving to 6/6 with correction

(75%), associated with 6th nerve palsy in (44.4%), visual fields showed enlarged blind spot in most of the cases (28.9%).

### Conclusion:-

1. Papilledema occur in a wide range of age but are more common in the age group of 31-50 years.
2. Overall, females were affected more than males.
3. Bilateral papilledema was most common than unilateral papilledema like Foster Kennedy syndrome.
4. The common aetiological factor for papilledema was space occupying lesion.
5. 13.3% of the patients had sixth cranial nerve paresis in papilledema, 0.15% Patients had 7th nerve involvement. Not all papilledema are associated with 6th nerve palsy, 6th nerve palsy might not be present in all cases of papilledema.
6. More than three fourth (80%) of patients had normal visual acuity in papilledema.
7. (53%) of the patients had visual field involvement in papilledema.

### References:-

1. Ophthalmology, Myron Yanoff and Jay. S. Duker, 3<sup>rd</sup> edition, chapter 5.16, page 497.
2. Wolff's anatomy of the eye and orbit.
3. Adler's physiology of eye.
4. Parson's disease of the eye 20th edition
5. Clinical ophthalmology 4th edition – J.J.Kanski.
6. Glaser Neuro ophthalmology
7. Modern ophthalmology L.C.Dutla 3rd edition.
8. The foundation of the American Academy of ophthalmology 2000 – 2001 Neuro ophthalmology, Sir Stewart Duke – elder. Vol X, Vol.12.
9. Rigi M, Almarzouqi SJ, Morgan ML, Lee AG. Papilledema: epidemiology, etiology, and clinical management. *Eye Brain*. 2015 Aug 17;7:47-57. doi: 10.2147/EB.S69174. PMID: 28539794; PMCID: PMC5398730.
10. Kulhari A, He M, Fourcand F, Singh A, Zacharatos H, Mehta S, Kirmani JF. Safety and Clinical Outcomes after Transverse Venous Sinus Stenting for Treatment of Refractory Idiopathic Intracranial Hypertension: Single Center Experience. *J Vasc Interv Neurol*. 2020 Jan;11(1):6-12. PMID: 32071666; PMCID: PMC6998806.
11. Crum OM, Kilgore KP, Sharma R, Lee MS, Spiegel MR, McClelland CM, Bhatti MT, Chen JJ. Etiology of Papilledema in Patients in the Eye Clinic Setting. *JAMA Netw Open*. 2020 Jun 1;3(6):e206625. doi: 10.1001/jamanetworkopen.2020.6625. PMID: 32484553; PMCID: PMC7267843.
12. Xie JS, Donaldson L, Margolin E. Papilledema: A review of etiology, pathophysiology, diagnosis, and management. *Surv Ophthalmol*. 2022 Jul-Aug;67(4):1135-1159. doi: 10.1016/j.survophthal.2021.11.007. Epub 2021 Nov 20. PMID: 34813854.