



ISSN NO. 2320-5407

Journal Homepage: [-www.journalijar.com](http://www.journalijar.com)

**INTERNATIONAL JOURNAL OF
ADVANCED RESEARCH (IJAR)**

Article DOI: 10.21474/IJAR01/17088
DOI URL: <http://dx.doi.org/10.21474/IJAR01/17088>



INTERNATIONAL JOURNAL OF
ADVANCED RESEARCH (IJAR)
ISSN 2320-5407
Journal Homepage: <http://www.journalijar.com>
Journal DOI: 10.21474/IJAR01

RESEARCH ARTICLE

BULBO-MEDULLARY EPENDYMOMA IN AN ADULT: CASE REPORT

Tarik Chekrine¹, Meriem Ait Alla¹, Mouna Bourhafour¹, Zineb Bouchbika¹, Nadia Benchakroun¹, Hassan Jouhadi¹, Nezha Tawfiq¹, Mehdi Karkouri², Abdelhakim Lakhdar³ and Souha Sahraoui¹

1. Radiation Oncology Department, Mohamed VI Center for Cancer Treatment, UHC Ibn Rochd, Faculty of Medicine and Pharmacy, Hassan II University, Casablanca, Morocco.
2. Laboratory of Anatomopathology, UHC Ibn Rochd, Faculty of Medicine and Pharmacy, Hassan II University, Casablanca, Morocco.
3. Neurosurgery Department, UHC Ibn Rochd, Faculty of Medicine and Pharmacy, Casablanca, Morocco.

Manuscript Info

Manuscript History

Received: 15 April 2023
Final Accepted: 19 May 2023
Published: June 2023

Key words: -

Spinal Ependymoma, Bulbo-Medullar Junction, Surgery, Radiotherapy

Abstract

Spinal ependymoma, the most common intramedullary tumour in adults, is generally located intradurally and intramedullarily. The presence of this tumor in the bulbo-medullary region is rarely documented in the medical literature. We present the case of a 33-year-old man with persistent torticollis and severe neck pain. Spinal cord magnetic resonance imaging revealed a lesion in the bulbo-medullary region. Subtotal resection of this lesion was performed, and anatomopathological and immunohistochemical analysis confirmed the diagnosis of ependymoma. Following surgery, the patient underwent post-operative radiotherapy. The standard therapeutic management of ependymoma is total tumor resection. However, the role of post-operative radiotherapy remains to be determined, although it is recommended in cases of subtotal resection.

Copy Right, IJAR, 2023, All rights reserved.

Introduction: -

Ependymomas are malignant neuroepithelial tumours that occur in children and adults and can develop along the neuraxis [1]. It has recently been acknowledged that these tumours originate from radial glial stem cells [2]. They constitute 3-6% of all central nervous system tumours and are the most common intramedullary tumour of the adult spinal cord, representing approximately 60% of all cases [3]. The occurrence of these tumour in the bulbo-medullary region is rarely described in the literature, thus, we present a novel observation in a 33-year-old adult.

Observation: -

A 33-year-old man with no previous history of the condition had been enduring severe neck pain and torticollis since April 2020. No motor or sensory disorders of the cranial nerves were observed. A standard X-ray of the cervical spine did not indicate any specific lesions. The patient underwent a rehabilitation regimen consisting of physiotherapy sessions and muscle strengthening techniques. However, when the torticollis and neck pain persisted, a spinal magnetic resonance imaging was performed. This revealed a bulbo-medullary tissue lesion with cystic areas 47 mm height and 25 mm in width, presenting with heterogeneous isosignal in T1 sequence and heterogeneous hypersignal in T2 sequence (Figure 1a;1b). A subtotal resection of the tumour was executed via a posterior approach to the occiput at C3 without any intra- or post-operative complications. The histopathological study showed tumour proliferation in the form of perivascular rosettes and palisading arrangements of columnar cells, exhibiting an ependymal phenotype without significant atypia or necrosis

Corresponding Author: -Tarik Chekrine

Address: -Radiation Oncology. Department, Mohamed VI Center for Cancer Treatment, UHC Ibn Rochd, Faculty of Medicine and Pharmacy, Hassan II University, Casablanca, Morocco.

or endotheliocapillary hyperplasia suggestive of ependymoma. Additional immunohistochemistry confirmed the diagnosis of WHO grade II classical ependymoma (Figure 2a). The tumour cells tested positive for GFAP (Figure 2b) but did not express Olig 2 (Figure 2c). The patient underwent adjuvant radiotherapy on the residual tumour at a dose of 50.4 Gy in conventional mode (Figure 3). Clinical and radiological follow-up demonstrated a substantial improvement in symptoms and no progression of the tumour after 18 months.

Discussion: -

Spinal ependymoma is the most common intramedullary tumour in adults, making up over 60% of all such lesions [3]. They can manifest in any region of the spinal cord but are the most frequently found in the cervical and cervicothoracic segments [4]. Bulbo-medullary localisation is particularly rare and of specific interest in this case.

Ependymomas were long presumed to derive from the ependymal cells lining the central canal of the spinal cord. However, more recent research suggests that they actually originate from radial glial progenitor or stem cells [2].

The 2021 revision of the WHO classification of central nervous system tumours introduced a significant change by classifying ependymomas into ten types based on their anatomical location (supratentorial, infratentorial and spinal) and molecular characteristics (ZFTA fusion or YAP1 fusion for supratentorial, and posterior fossa A "PFA" type or posterior fossa B "PFB" type for infratentorial) [5].

However, spinal ependymomas comprise four distinct types: spinal ependymoma (SP-EPN), spinal ependymoma with MYCN amplification (SP-MYCN), myxopapillary ependymoma (MPE) and subependymoma (SE).

The SP-EPN and SP-MYCN types necessitate a spinal location for diagnosis, whereas MPE and SE can also occur in other anatomical regions [5]. The molecular classification of ependymomas is based on novel diagnostic technologies, such as DNA methylome profiling and DNA sequencing [4].

Spinal ependymomas are also linked with neurofibromatosis type 2, and sporadic cases exhibit an increased frequency of NF2 gene mutation [6].

The peak incidence of spinal ependymomas occurs in the fourth decade of life, with a median age of presentation of 41 years [5]. Men are more frequently affected than women [7]. In this case, the patient was a 33-year-old adult.

Due to their slow growth and tendency to compress rather than infiltrate the surrounding tissue, spinal ependymomas often present with insidious clinical symptoms. Consequently, diagnosis is often made up to 3 years after the onset of symptoms [8]. Symptoms are usually attributable to compression of the brain stem or upper cervical cord. In the case of the patient presented here, he had been complaining of neck pain for over a year.

Pathological examination reveals uniform, moderately hyperchromatic nuclei and perivascular pseudorosettes, which are classic features of ependymomas [4].

On immunohistochemistry, tumour cells characteristically express GFAP, S100 and vimentin and show focal intracytoplasmic dot or ring EMA expression. Contrary to spinal astrocytomas, spinal ependymomas are markedly negative for OLIG 2. Additionally, they do not express SOX 10, a feature present in schwannomas, pilocytic astrocytomas and most diffuse gliomas [2].

The majority of spinal ependymomas are grade 2 according to the WHO classification, with grade 3 tumours being rare [2].

In a small subgroup of patients, MYCN amplification has been identified [4]. These tumours are high-grade and aggressive but have not yet been officially graded in the 5th edition (2021) of the WHO classification of tumours of the central nervous system [2].

Radiologically, magnetic resonance imaging (MRI) is the examination of choice for investigating intramedullary tumours. Spinal ependymomas generally present with a heterogeneous signal, with low intensity in T1 and high intensity in T2. Heterogeneous gadolinium enhancement is often seen, with a clear boundary at the periphery of the tumour. Spinal ependymomas tend to be located more centrally in the spinal cord than astrocytomas, and the main differential diagnosis

to consider is astrocytoma. In about 20% of cases, haemorrhage has occurred, forming a low-intensity T2 bulge, usually at the periphery of the tumour [9].

Complete tumour resection (GTR) is the primary therapeutic approach, offering a better prognosis [10]. However, it is not achievable in around a quarter of cases [11]. GTR should be considered at an early stage of the disease, as functional outcome is linked to small tumour size and good neurological status at the time of surgery [12]. Typically, a clear surgical interface is usually present between the tumour and the spinal cord tissue.

The role of postoperative adjuvant radiotherapy remains unclear, although it is favoured in cases of subtotal resection (STR). Adjuvant radiotherapy prolongs progression-free survival and recurrence-free interval when the resection is incomplete.

In a review of 348 patients with medullary ependymomas who underwent surgery, GTR was achieved in 77% and STR in 23% of patients. Adjuvant radiotherapy was administered to 58.8% of patients with STR and 3.7% of patients after GTR. PFS was significantly prolonged by adjuvant radiotherapy following STR ($p < 0.001$) [13].

The prognosis for spinal ependymomas is generally better than for cranial ependymomas. Total resection is the most significant prognostic factor for spinal ependymomas. Recurrence rates can range from a few months to a few years [14]. Spinal ependymomas with MYCN amplification are considered to be aggressive tumours with a poor prognosis, with frequent early dissemination throughout the central nervous system and recurrence despite resection [5]. Strategies to inhibit MYCN are under investigation, including vaccination [15]. Other types of spinal tumour have a more favourable outcome [5].

Recurrences are not necessarily accompanied by neurological deficits. Therefore, MRI monitoring can detect recurrences in asymptomatic patients to propose secondary treatments, including surgery or radiotherapy, resulting in better progression-free survival at 3 years. However, the impact on overall survival remains limited [16].

Figures:

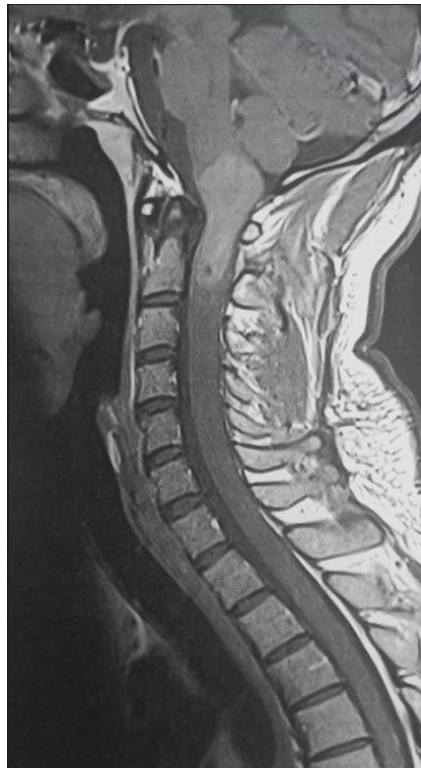

Figure 1a: - Preoperative Spinal MRI showing the bulbo-medullary lesion in sagittal T1 isosignal.

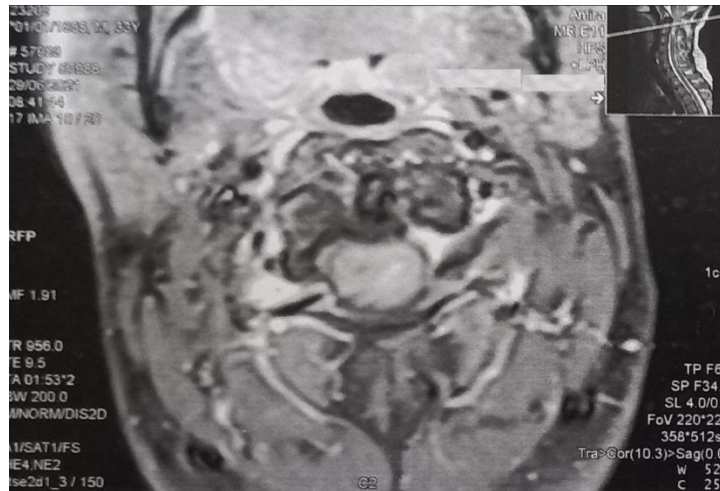


Figure 1b: - Preoperative Spinal MRI showing bulbo-medullary lesion in axial T2 hypersignal.

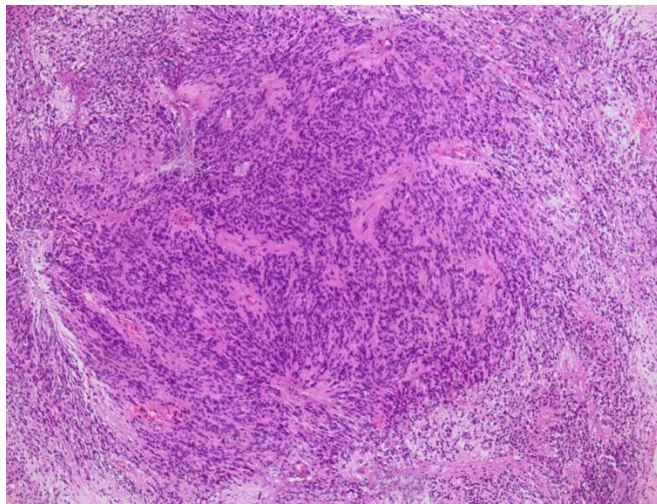


Figure 2a: - Typical perivascular pseudorosettes (Hematoxylin and eosin, $\times 20$).

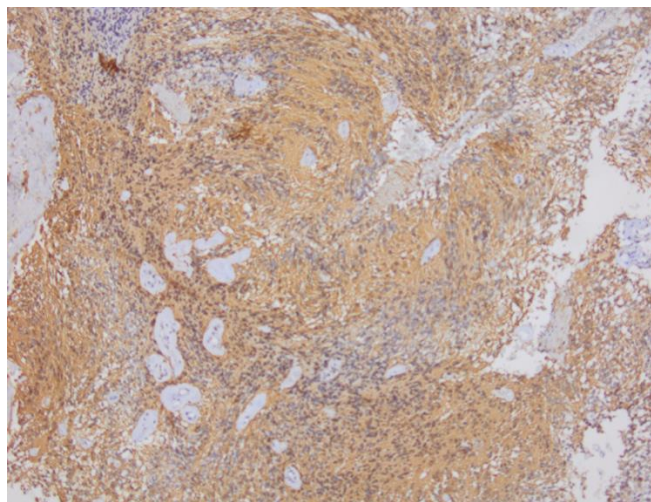


Figure 2b: - Glial fibrillary acidic protein (GFAP) highlights cell processes in perivascular pseudorosettes.

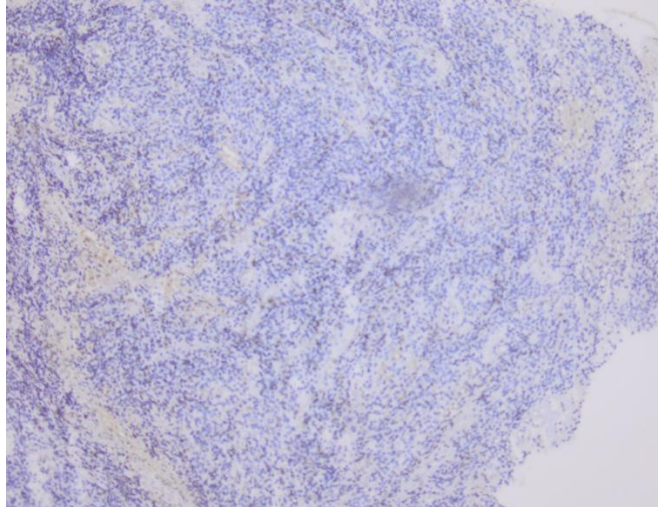


Figure 2c: Oligodendrocyte lineage transcription factor 2 (OLIG2) not expressed by tumor cells.

Conclusion: -

Bulbo-medullary ependymomas are rare. Despite these being benign, slow-growing, indolent tumours with favourable long-term survival, it is essential to achieve complete resection while preserving vital functions. The role of postoperative radiotherapy remains undefined, although it is recommended when resection is subtotal.

References: -

- 1- Louis DN, Ohgaki H, Wiestler OD, Cavenee WK, Burger PC, Jouvet A, et al. The 2007 WHO classification of tumours of the central nervous system. *Acta Neuropathol* 2007 ;114 :97–109.
- 2- Pietsch T, Aldape KD, Korshunov A, Pajtler KW, Taylor MD, Venneti S, Spinal ependymoma. In: WHO Classification of Tumours Editorial Board. Central nervous system tumours. Lyon (France): International Agency for Research on Cancer; 2021. (WHO classification of tumours series, 5th ed.; vol. 6). <https://publications.iarc.fr/601>.
- 3- Reni M, Gatta G, Mazza E, Vecht C. Ependymoma. *Crit Rev Oncol Hematol* 2007 ;63(1) :81-89.
- 4- Gupta RK, Sharma A, Sharma MC. Overview of recent advances in the classification of ependymomas in WHO CNS5 classification: Simplified approach to their integrated diagnosis. *Indian J Pathol Microbiol* [serial online] 2022 [cited 2023 Jun 8] ;65, Suppl S1 :68-72.
- 5- Kresbach C, Neyazi S, Schüller U. Updates in the classification of ependymal neoplasms: The 2021 WHO Classification and beyond. *Brain Pathol.* 2022 Jul;32(4): e13068. doi: 10.1111/bpa.13068. Epub 2022 Mar 21. PMID: 35307892; PMCID: PMC9245931.
- 6- Ebert C, von Haken M, Meyer-Puttlitz B, Wiestler OD, Reifenberger G, Pietsch T, et al. Molecular genetic analysis of ependymal tumors. NF2 mutations and chromosome 22q loss occur preferentially in intramedullary spinal ependymomas. *Am J Pathol* 1999 ;155 :627-32.
- 7- Rudà R, Bruno F, Pellerino A, Soffiotti R. Ependymoma: Evaluation and Management Updates. *Curr Oncol Rep.* 2022 Aug ;24(8):985-993. doi: 10.1007/s11912-022-01260-w. Epub 2022 Apr 6. PMID: 35384591; PMCID: PMC9249684.
- 8- García-Garrido CD; Ramos-Rubio DA, Rivas-Cabello SF; Rincón-Velazco ME; Arditi-Zambrano LM, Puente-García JA. Ependimoma primary o bulbo medular en adulto. A propósito de un caso. *Avances en Biomedicina.* 2018 Abril; Volumen 7(1), p 53-57.
- 9- Yuh EL, Barkovich AJ, Gupta N. Imaging of ependymomas: MRI and CT. *Childs Nerv Syst* 2009;25(10):1203-1213.
- 10- Deng Y, Chen H, Wang C, Zhang Y. Risk factors for the recurrence of world health organization grade II ependymomas of spinal cord in adults after microsurgical resections: a retrospective study of 118 patients in a single center. *Clin Neurol Neurosurg.* 2020; 195:105856.
- 11- Clover LL, Hazuka MB, Kinzie JJ. Spinal cord ependymomas treated with surgery and radiation therapy. A review of 11 cases. *Am J Clin Oncol.* 1993 Aug;16(4):350-3.
- 12- Eroes CA, Zausinger S, Kreth FW, Goldbrunner R, Tonn JC. Intramedullary low-grade astrocytoma and ependymoma. Surgical results and predicting factors for clinical outcome. *Acta Neurochir (Wien).* 2010;152(4):611–618.

- 13- Oh MC, Ivan ME, Sun MZ, Kaur G, Safaee M, Kim JM, Sayegh ET, Aranda D, Parsa AT. Adjuvant radiotherapy delays recurrence following subtotal resection of spinal cord ependymomas. *Neuro Oncol.* 2013(2) Feb;15(2):208-15.
- 14- Ge X, Wu Z, Zhang J, Zhang L. Surgical strategies, and functional outcome of intramedullary cervicomedullary ependymoma. *Turk Neurosurg* 2017; 27:563-72.
- 15- Stermann A, Huebener N, Seidel D, et al. Targeting of MYCN by means of DNA vaccination is effective against neuroblastoma in mice. *Cancer Immunol Immunother.* 2015;64(10):1215–27.
- 16- Klawinski D, Indelicato DJ, Hossain J, Sandler E. Surveillance imaging in pediatric ependymoma. *Pediatr Blood Cancer* 2020;67(11): e28622.