



### RESEARCH ARTICLE

## PENETRATING KERATOPLASTY: CASABLANCA EXPERIENCE – FIVE-YEAR REVIEW

H.Zaydi, K.Sbai, Z.Boubekri, Bentouhami, Y.Hidan, A.Mchachi, L.Benhmidoune and R.Rachid.

#### Manuscript Info

##### Manuscript History

Received: 20 February 2025

Final Accepted: 23 March 2025

Published: April 2025

##### Key words:-

Penetrating keratoplasty – Rejection – Cornea – Keratoconus – Bullous keratopathy.

#### Abstract

Penetrating keratoplasty (PK) is a surgical procedure aimed at replacing the entire thickness of the patient's cornea with that of a donor. This technique is the oldest and most common for corneal transplantation. The aim of our study is to report the experience of the adult ophthalmology services at the 20 August 1953 Hospital in Casablanca, and the ophthalmology department of the Cheikh Khalifa International University Hospital in Casablanca (CKIUH) regarding penetrating keratoplasty.

**Materials and Methods:** This was a descriptive cross-sectional study conducted within the adult ophthalmology services of the 20 August 1953 Hospital in Casablanca, and the ophthalmology department of CKIUH, including patients who underwent penetrating keratoplasty between March 2017 and January 2022.

**Results and Discussion:** We collected data from 189 patients, with a mean age of 42.87 years and slight male predominance. The main indication was advanced keratoconus (46%) followed by bullous keratopathy (27%). The initial visual acuity was less than 1/10 in almost all cases (88.8%). Graft rejection was observed in 14.2% of cases, and ocular hypertension and infectious complications in 4.7% of cases. Final visual acuity was greater than 3/10 (logMAR=0.52) in 65% of cases with a mean astigmatism of 4.75 diopters. Graft rejection is more frequent in cases of corneal neovascularization, in men, and less frequent in cases of keratoconus. Our study results are comparable to those in the literature, particularly regarding the indications and postoperative complications of corneal transplantation.

Regular monitoring is necessary to detect and treat complications, especially neovascularization, which often precedes graft rejection.

**Conclusion:** The results of penetrating keratoplasty remain satisfactory, provided that a precise evaluation of the surgical indication is performed, accompanied by attentive and regular postoperative monitoring aimed at optimizing visual prognosis. Currently, the challenge is to explore new avenues for lamellar keratoplasty and promote organ donation to meet the growing demand for corneal grafts.

"© 2025 by the Author(s). Published by IJAR under CC BY 4.0. Unrestricted use allowed with credit to the author."

---

**Introduction:-**

Corneal blindness accounts for 10% of all cases of blindness worldwide. It includes various eye conditions that alter corneal transparency and lead to blindness(1,2). Penetrating keratoplasty (PK) is a surgical procedure that aims to replace the entire thickness of a patient's cornea with that of a donor cornea. This technique is the oldest and most common for corneal transplantation, and it continues to hold its place because of specific indications when the condition affects the entire thickness of the cornea, such as in cases of hydrops, bullous keratopathy, and post-traumatic and post-infectious opacities(3–5). In Morocco, corneal transplantation faces many obstacles, particularly the scarcity of donations, which leaves our country lagging in terms of corneal donation and transplantation(6,7).

The **objective** of our work was to report the experience of the adult ophthalmology departments of the 20 August Hospital in Casablanca and the Cheikh Khalifa International University Hospital in Casablanca (HUICK) regarding penetrating keratoplasty, while emphasizing the indications, anatomical and functional outcomes, as well as the various complications.

**Materials and Methods:**

This descriptive cross-sectional study was conducted in the adult ophthalmology departments of 20 August Hospital and HUICK.

Between March 2017 and January 2022.

Our study included all patients who underwent penetrating keratoplasty in the two departments during this period, except for those lost to follow-up and incomplete records.

Data were collected from patient records using a pre-established data collection form, entered into Excel, and analyzed using Jamovi.

Quantitative variables were expressed as means and standard deviations, while qualitative variables were expressed as frequencies and percentages.

Associations were analyzed using the chi-square test, Fisher's exact test, and Yates' correction.

**Results:**

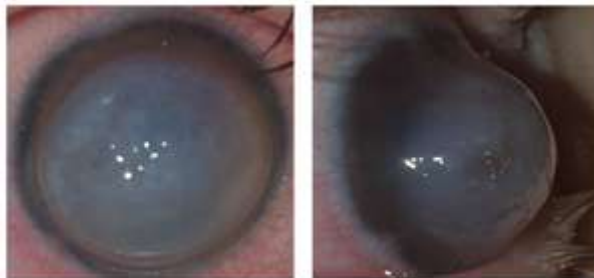We included 202 transplanted eyes of 189 patients, with a mean age of  $42.8 \pm 21$  years and extremes ranging from 10 to 87 years. There was also a slight male predominance with a male-to-female ratio of 1.17.

The main reasons for consultation were visual disturbances in all patients, followed by ocular pain and tearing in 26% and 24.8% of patients, respectively.

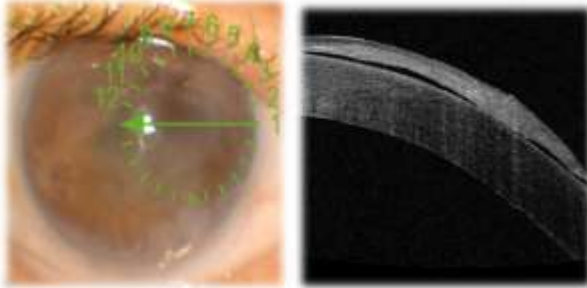
Regarding ophthalmological history, 44% of the patients were followed up for keratoconus, 31.7% had previously undergone cataract surgery, 11.6% had a history of ocular trauma, and 11% had a history of atopy.

Best-corrected visual acuity (BCVA) was limited to less than 1/10 in 88.8% of cases and to 1/10 in 11% of cases. Regarding laterality of the condition, 56.6% of the patients had bilateral corneal involvement.

The main indication was keratoconus (Fig1) with a percentage of 46%, followed by bullous keratopathy( (Fig2) at 27%, post-traumatic corneal scars, corneal dystrophies, and corneal opacities post-keratitis.



**Fig 1 Stage IV keratoconus complicated by hydrops.**



**Fig2** Optical coherence tomography showing subepithelial bubbles in pseudophakic bullous keratopathy. The other indications were as follows (Table 1).

**Table 1: Distribution by Indication.**

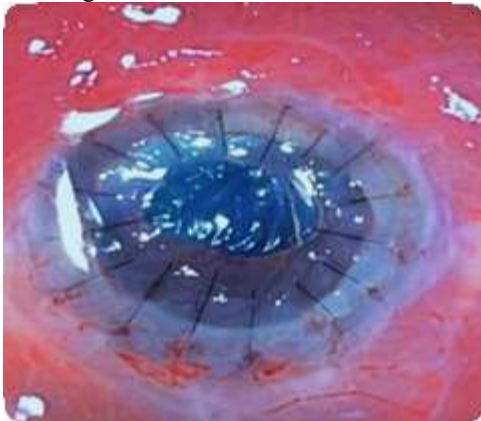
Indication	Count	Percentage
Keratoconus	87	46 %
Bullous keratopathy	51	27 %
Post-traumatic corneal scar	22	11,6 %
Corneal dystrophy	19	10 %
Corneal opacity post-keratitis	9	4,7 %
Keratoplasty failure	1	0,05 %
<b>Total</b>	<b>189</b>	<b>100 %</b>

Regarding the origin of the graft, almost all were imported from American eye banks, with only four grafts from deceased donors in a state of brain death, harvested in the central operating room of CHU Ibn Rochd in Casablanca. The average donor age was 34 years.

The average endothelial cell density of the grafts was 2803 cells/mm<sup>2</sup>. All procedures were performed under general anesthesia.

The procedure was straightforward in 184 cases, while five patients underwent a combined procedure: penetrating keratoplasty with extracapsular cataract extraction (ECCE) and implantation. On average, the diameter of the graft trephination was 7.56 millimeters, while that of the recipient cornea was 7.31 millimeters.

The most common diameter was 7.25 millimeters in 80.4% of the patients who received oversized grafts of 0.25 mm. The majority of grafts (86.2%) were sutured to the recipient cornea with 16 interrupted sutures spaced at approximately 360° using a 10/0 nylon monofilament (Fig3). We noted only one intraoperative complication, bleeding from an adherent leukoma, which was well-controlled.



**Fig 3** Corneal graft sutured with 16 interrupted sutures of 10/0 nylon monofilament.

Early postoperative outcomes were uncomplicated in 89.4% of the patients. The early postoperative complications (Table 2) observed included 12% of cases with ocular hypertension, 3.7%, suture loosening, and delayed re-epithelialization (2.6%) (Fig 4).

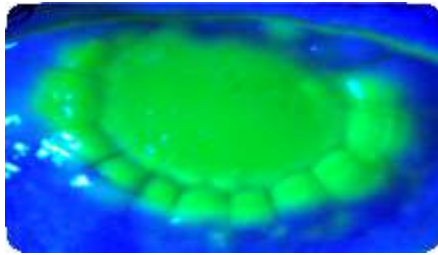
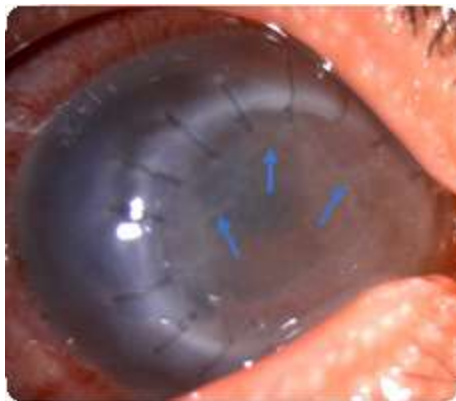

Fig 4 Delayed corneal re-epithelialization (10 days after PK)

Table 2: Distribution of Early Postoperative Complications.

Early Postoperative Complications	Count	Percentage
Ocular hypertension	23	12,17 %
Suture loosening	7	3,7 %
Corneal edema	5	2,6 %
Delayed re-epithelialization	5	2,6 %
Iris herniation	1	0,5 %



The medium- and long-term postoperative outcomes were uncomplicated in 75% of the cases. Graft rejection (Fig 5) was observed in 14.2% of patients, and ocular hypertension and infectious complications were noted in 4.7% of patients. Corneal neovascularization was detected in 1.5% of the patients (Fig 6).

Fig 5: Endothelial graft rejection in the process of formation with Khodadoust lines (arrows).

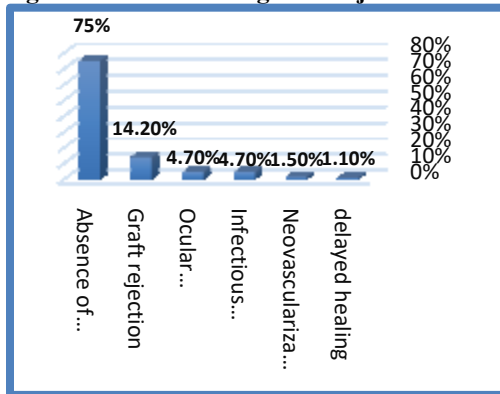


Fig 6 : Distribution of Medium- and Long-Term Postoperative Outcomes.

The final BCVA after suture removal was less than 1/10 in 10.4% of cases and greater than 3/10 in 65.0% of cases (Fig 7).

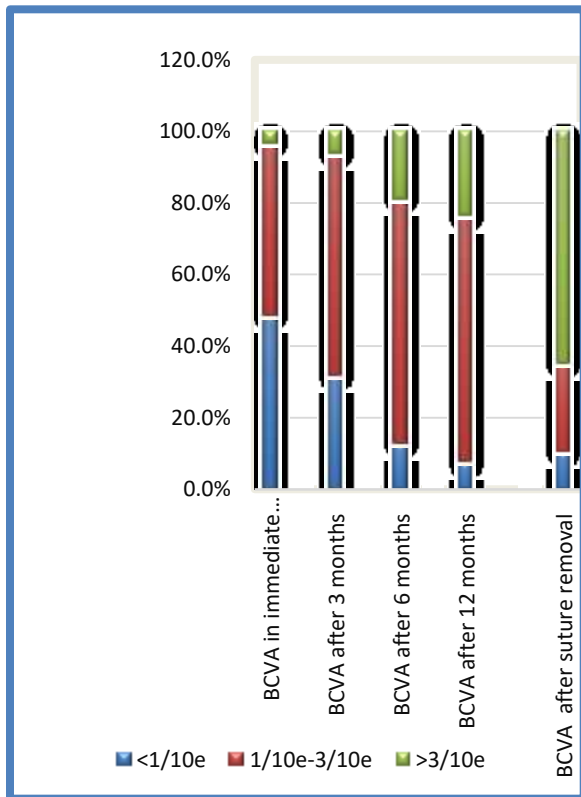
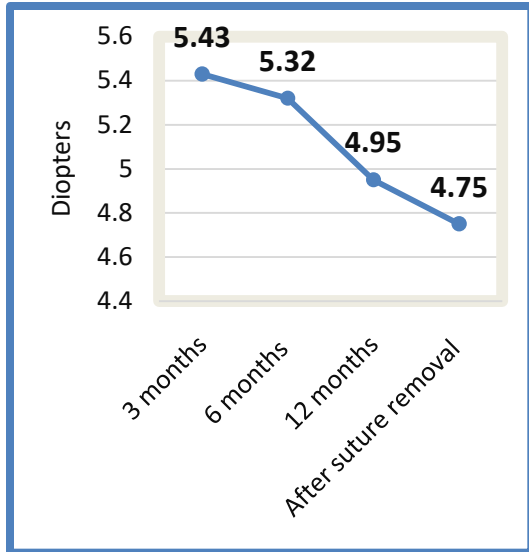


Fig 7: BCVA after PK surgery.

The average astigmatism after suture removal was 4.75 diopters (Fig 8).



**Fig 8: Postoperative astigmatism evolution.**

Complete suture removal was performed in 74% of our patients, whereas it was still ongoing in 26% of our cohort. The average time for suture removal was 12.5 +/- 2.36 months, carried out progressively. Through our analysis of the factors influencing corneal graft rejection, we identified several significant associations with a p-value less than 0.005 (Table 3).

**Table 3: Association analysis between several factors and the occurrence of rejection.**

	Absence of rejection	Occurrence of rejection	P value
<b>Age range</b>			
< 15	100,0 %	0,0 %	<b>&lt; 0,001</b>
15-30	97,9 %	2,1 %	
30-45	96,8 %	3,2 %	
45-60	87,1%	12,9 %	
> 60	64,0 %	36,0 %	
<b>Sex</b>			
Female	95,8 %	4,2 %	<b>0,001</b>
Male	78,4 %	21,6 %	
<b>Indication</b>			
Corneal opacity post-keratitis	44,4 %	55,6 %	<b>0,004</b>
Corneal dystrophy	93,8 %	6,3 %	
Keratoconus	93,1 %	6,9 %	

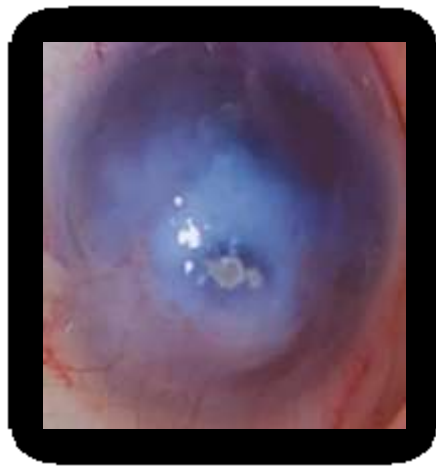Bullous keratopathy	78,4 %	21,6 %	
Post-traumatic corneal scar	90,0%	10,0%	
<b>Neovascularization</b>			
Absent	93,4 %	6,6 %	<b>&lt; 0,001</b>
Present	53,1 %	46,9 %	

First, age played a crucial role: older patients were found to have a higher risk of rejection.

Additionally, sex was another important factor, with men exhibiting a significantly higher risk than women, showing rejection rates of 21.6% for men versus 4.2% for women.

The type of indication also influenced the outcomes ; patients with corneal dystrophy, keratoconus, or corneal opacification had high success rates. In contrast, those with corneal opacities resulting from keratitis or bullous keratopathy had lower success rates.

Finally, we noted that rejection was significantly more frequent in patients with corneal neovascularization (Fig 9).



**Fig 9: Centrally located corneal opacity with descemetocoele and corneal neovascularization.**

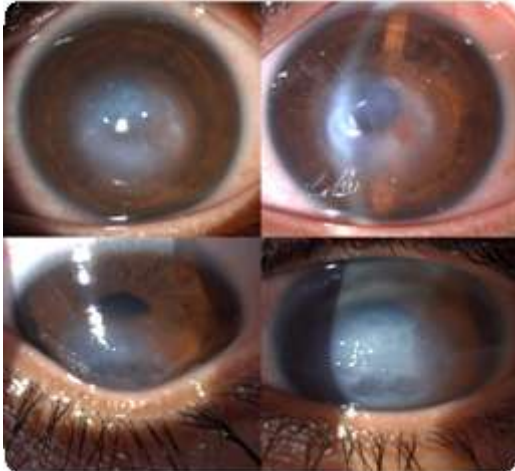### Discussion

The mean age in our series was 42.8 years, which aligns with the findings of the Chinese study by Qing Pan et al.(8), where the mean age was 41.5 years, and the study conducted by Belghmaidi et al.(9), which reported a mean age of 34 years. These similarities are significant given that the corneal allocation score tends to favor younger individuals.

In contrast, the mean ages reported in a study conducted in Singapore by Donald et al.(10) and in Philadelphia by Faris et al.(11) were higher. These discrepancies can be explained by the predominance of bullous keratopathy, which results in an older patient population.

Consistent with our series, a slight male predominance was observed in most studies, which may be related to the trend noted in numerous studies regarding male predominance in cases of keratoconus(12).

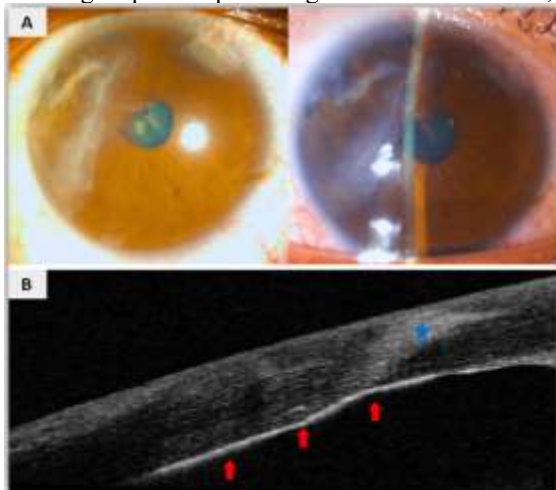
In our series, keratoconus (Fig10) stands out was the predominant indication for penetrating keratoplasty, representing a prevalence of 46%. These results are consistent with findings from several studies, such as those of Zouhair et al.(13) in the pediatric ophthalmology department of Casablanca and the study from the CHU of Marrakech(9), which reported frequencies of 40% and 33.8%, respectively.



**Fig 10: Keratoconus stage IV complicated by hydrops.**

Bullous keratopathy emerged as the second indication for penetrating keratoplasty in our series as well as in a study conducted at the CHU of Marrakech by Belghmaidi(9), with respective percentages of 27% and 19.5%. Interestingly, this condition is the primary indication in the series by Donald(10) in Singapore and Faris (11) in Philadelphia.

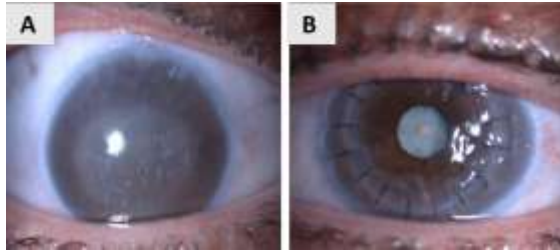
Traumatic corneal scars (Fig 11) are a significant indication for corneal grafting, particularly when they affect the visual axis. In our series, this indication had a frequency of 11.6%, consistent with findings from a study at the CHU of Marrakech (9) and a study conducted in Canada by Benson et al.(14), which reported percentages of 10.7% and 16% among all indications. This indication is more prevalent in the study by Zouhair et al.(13) and Qing et al.(8), showing respective percentages of 23% and 21.2%, likely related to the younger age of the patients.



**Figure 11: Corneal scars following blunt trauma.**

**A: Para-axial corneal scars with irido-lenticular synechiae and iris pigments on the anterior lens;**  
**B: Optical coherence imaging showing sequelae of stromal opacity with endothelial thickening .**

Corneal dystrophy (Fig 12) of all types had a similar prevalence across most studies, with a percentage of 10% in our series. This finding is consistent with the results reported in other surveys, such as 10% by Benson et al.(14) and 9% by the pediatricophthalmology department of Casablanca(13).



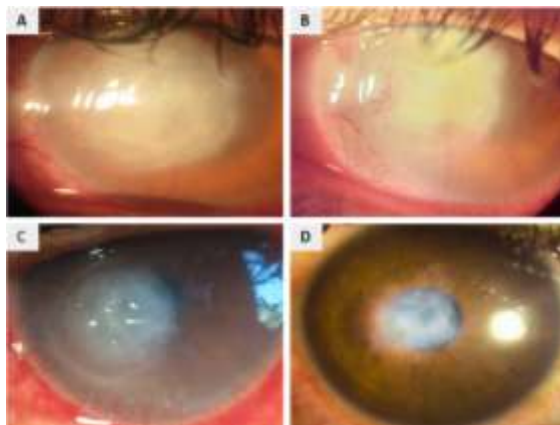
**Fig 12: Groenouw's Dystrophy.**

**A. Appearance before corneal transplantation;**

**B. Appearance after penetrating keratoplasty.**

In our series, only 4.7% of the patients underwent penetrating keratoplasty due to sequelae of corneal opacity from an infection (Fig 13), and none of the patients received a graft for infectious or inflammatory keratitis.

In our context, penetrating keratoplasties are often performed on sequelae of opacities resulting from infectious keratitis. This approach is motivated by the scarcity of corneal grafts and the high risk of graft rejection during active infectious or inflammatory episodes.



**Fig 13: Bacterial Corneal Ulcer on Contact Lenses.**

**A. Initial appearance upon admission;**

**B. Appearance after 5 days of fortified antibiotic drops;**

**C. Appearance after 2 weeks;**

**D. Sequela opacity with reduced corneal neovascularization after subconjunctival anti-VEGF injections.**

This observation differs from the findings in the literature. For example, in a study conducted in Tunisia by Limaiem et al.(15), which focused on therapeutic keratoplasties, 60% of patients underwent penetrating keratoplasty due to infectious keratitis.

Table 4 illustrates the differences in the frequency of various indications according to several studies (Table 4).

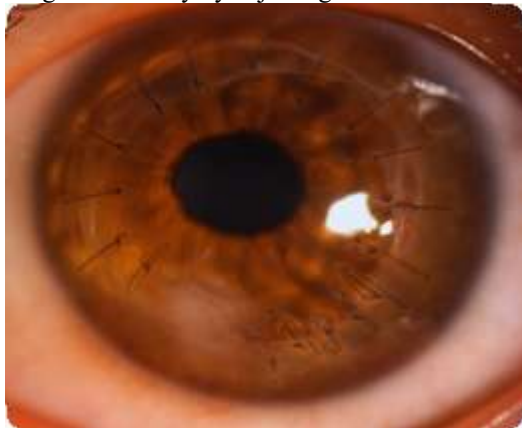	Keratoconus	Bullous keratopathy	Traumatic corneal scars	Corneal dystrophy	Corneal opacity post-keratitis
<b>Benson et al</b>	23%	11%	16%	10%	9%
<b>Zouhair et al</b>	40%	16%	23%	9%	20%
<b>Belghmaidis et al</b>	33,8%	19,5%	10,7%	10,7%	15,6%

<b>Qing Pan et al</b>	13,8%	10,8%	21,2%	8,9%	35,9%
<b>Limaie m R et al</b>	--	--	2,8%	--	60%
<b>Rahman I et al</b>	24%	21%	--	14%	9%
<b>Donald T et al</b>	9,7%	23,4%	7,3%	7,1%	12,9%
<b>Faris R et al</b>	16%	30,6%	6%	11,8%	6,7%
<b>Our Study</b>	46%	27%	11,6%	10%	4,7%

**Table 4: Comparison of indications for PK among different series.**

Regarding surgical intervention, general anesthesia is preferred in keratoplasty because it is an open surgery that carries the risk of expulsive hemorrhage(5,16). In our survey, almost all grafts (97,8%) were imported from American eye banks. In contrast, a Tunisian study by Liamiam(15) reported that all grafts came from the eye bank in Tunis. In an investigation conducted at CHU Mohammed VI in Marrakech, 20% of grafts were harvested locally(9). In our study, the disparity between the graft trephination diameter and cornea was established at 0.25 mm. These results align with those of Zouhair et al.(13) and Donald et al.(10), demonstrating a 0.25 mm oversizing of the graft trephination diameter compared with the cornea. In contrast, studies by Nurözler et al. in Turkey(17) and Qing Pan in China(8) indicated larger graft diameters, with average sizes of 8 mm and 7.77 mm, respectively.

In our series, the graft was sutured using 14 to 16 separate radial sutures with a nylon monofilament 10/0 (Fig14), which was observed in 87.8% of our patients. This approach was adopted in accordance with several studies in the literature because of the lower risk of suture loosening compared with continuous suturing and the ability to manage astigmatism early by adjusting individual sutures(9,13,18).



**Fig 14: Postoperative appearance at 6 months of a graft sutured with separate sutures using a 10/0 monofilament. Visual acuity: 5/10.**

In our study, 65% of the patients had a corrected visual acuity greater than 3/10. Consistent with the literature, functional outcomes were generally favorable in cases of keratoconus associated with Fuchs' dystrophy, whereas less positive results were observed in cases of bullous keratopathy, infectious sequelae, and post-traumatic corneal scars. The visual gain achieved is closely dependent on the correction of the sphere and postoperative astigmatism(19,20).

Overall, the results following penetrating keratoplasty are encouraging, with a visual acuity exceeding 1/10 observed in 89.6% of the cases in our series. These results are comparable to those reported by Zouhair Y(13), Belghmaidi S(9), and Qing Pan(8), who recorded percentages of 80%, 90%, and 69.5%, respectively (Table 5). In contrast, the study by Limaïem R(15), which primarily focused on hot keratoplasties, recorded a percentage of 25.7% for visual acuity greater than 1/10, indicating more favorable results in the absence of corneal perforation.

**Table 5: Comparison of best-corrected visual acuity.**

Studies	BCVA		
	1/10	1/10-3/10	3/10
Zouhair Y et al 2018 Pediatric ophthalmology Casablanca	1/10	1/10-3/10	3/10
	20%	22%	58%
Belghmaidi S et al 2016 Marrakech	1/10	1/10-5/10	5/10
	10%	19%	71%
Qing Pan et al 2012 China	1/10	1/10-5/10	5/10
	30,50%	34,50%	35%
Limaïem R et al 2009 Tunisia	1/10	1/10	
	74,30%	25,70%	
Rahman I et al 2009 United Kingdom	5/10	5/10	
	52%	48%	
Our Study	1/10	1/10-3/10	3/10
	10,4%	24,6 %	65,0 %

The average astigmatism after suture removal in our series was 4.75 diopters, a value similar to that reported in the literature, specifically 4.05, 4.25, and 5 in the studies by Alvarez in Spain(21), Belghmaidi S in Marrakech(9), and Deshmukh in India(22), respectively (Table 6).

**Table 6 : Comparison of postoperative astigmatism.**

Authors	Year of study	Country/City	Average astigmatism after suture removal (Diopters)
Deshmukh R et al	2022	India	5
Zouhair Y et al	2018	Casablanca Pediatric Ophtalmology	5 ± 2,01
Belghmaidi S	2016	Marrakech	4,25
Alvarez J et al	2003	Spain	4,05 ± 2.29
Our study	2022	Casablanca	4,75 ± 0,9

The early postoperative period allows for the early adjustment of sutures using a slit lamp, followed by the possibility of adjusting separate sutures after six months of healing by removing those in the most curved axes according to topography. Complete suture removal may be considered from the 12th month postoperatively, with earlier options for children (6 months) and young children (3 months)(5).

In line with the literature, the average time for suture removal in our series was  $12.5 \pm 2.36$  months, consistent with the study by Belghmaidi S in Marrakech(9), where complete suture removal was performed at an average of 13 months postoperative.

In cases of keratoconus or abnormal healing, delayed suture removal beyond 18 months is recommended. Well-tolerated sutures may be entirely or partially preserved. Visual rehabilitation involves addressing sutures beforehand and may be extended to other interventions depending on the context, such as fitting rigid contact lenses or scleral glasses, refractive compressive sutures, relaxing incisions, or even refractive surgery of the graft through photorefractive keratectomy or LASIK(5).

The decision to maintain long-term sutures or to completely remove them after a corneal graft can be delicate. Sometimes, even several years post-graft, the removal of all sutures can lead to a significant increase in postoperative astigmatism, especially if it is initially moderate. Conversely, when the scar shows well-established neovascularization, it is generally stable and astigmatism is less likely to change after suture removal. In such cases, it is imperative to remove the sutures regardless of the postoperative timeframe to prevent potential complications such as graft rejection(23).

Regarding postoperative complications, in our series, graft rejection was observed in 14.2% of the cases, which aligns with the percentage of 13.81% found in the study by Zouhair et al. These percentages remain relatively modest compared with the prevalence reported by Qing Pan (32.5%) and Donald (29.15%) (Table 7).

**Table 7: Prevalence of graft rejection occurrence (%).**

Authors	Year of study	Country/City	Prevalence of graft rejection occurrence (%)
Zouhair Y et al	2018	Pediatric Ophthalmology Casablanca	13,81
Belghmaidi S et al	2016	Marrakech	9,74
Qing Pan et al	2012	China	32,5
Limaïem R et al	2009	Tunisia	20
Rahman I et al	2009	United Kingdom	21
Donald T et al	2008	Singapore	29,15
Our study	2022	Casablanca	14,2

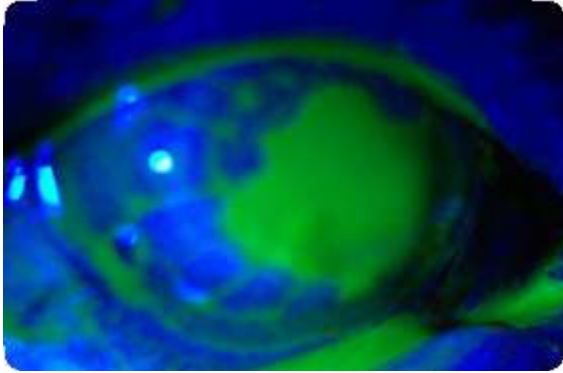
Ocular hypertension, observed in 12.17% of our patients, represents the second leading cause of failure in penetrating keratoplasties. Karadag et al.(24) demonstrated that the incidence of ocular hypertension after keratoplasty is significantly higher in glaucomatous patients.

Infectious complications in our study were relatively limited at 4.7%, which is comparable to that reported in the study by Khattak et al.(25) in Saudi Arabia (3%) and the study by Qing Pan(8) (3.5%). This low frequency was attributed to good patient management, awareness, and follow-up.

These infections may originate from the pathogens transmitted by the graft. It is crucial to note that the risk of endophthalmitis increases approximately 20-fold when the graft is not sterile. Currently, only organ culture provides assurance of graft sterility with a reliability of approximately 99%. Additionally, the pathogen may be transmitted by the implant or originate from the conjunctival and palpebral flora of the patient (23).

Endophthalmitis is a rare complication of penetrating keratoplasty with an incidence of approximately 0.5%. It most frequently occurs within 72 h following the procedure, and donor contamination is identified in 50% of cases.

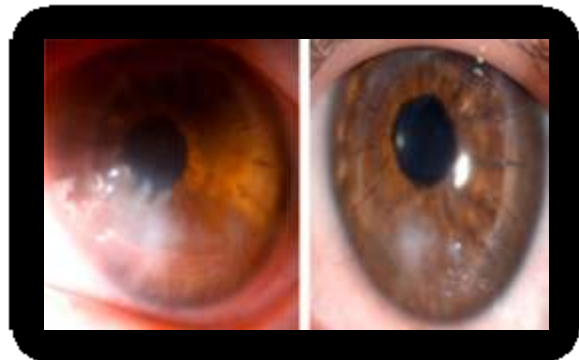
Herpetic keratitis on the graft often corresponds to recurrence of the initial pathology; however, it can also occur in patients who have never had herpetic keratitis and were grafted for another condition (Fig 15) (26,27).



**Fig 15: Herpetic keratitis presenting as geographic map-like patterns on a penetrating keratoplasty.**

Secondary endothelial decompensation presented as chronic edema in 2.6% of our patients, which aligns with the results of the study by Limaïem et al.(15), who reported 2.8%. However, this complication was more frequent in the series by Khattak et al., with a rate of 8.1% compared with 5.6% for Deep Anterior Lamellar Keratoplasty (DALK). These results highlight the more satisfactory performance of DALK compared to PK(25).

Neovascularization of the graft (Fig 16) is a significant cause of corneal graft rejection. In our study, this complication was observed in 18.9% of our patients, with percentages ranging from 14.1% to 31%, according to literature data(10,13,25). The management of corneal neovascularization in our facility relies on the administration of anti-VEGF agents via subconjunctival injection.



**Fig 16: Corneal graft neovascularization.**

	Ocular hypertension	Infectious complications	Endothelial decompensation	Neo vascularization
<b>Zouhair Y et al</b>	13,81%	7,89%	-	21,7%
<b>Khattak A et al</b>	8,1%	3%	8,1%	14,1%
<b>Belghmaidi S et al</b>	16,9%	0%	-	-
<b>Qing Pan et al</b>	17,7%	3,5%	-	-
<b>Limaïem R et al</b>	11,4%	14,3%	2,8%	--
<b>Rahman I et al</b>	18%	8%	-	-
<b>Donald T et al</b>	11,53%	11,86%	-	31%
<b>Our study</b>	12,17%	4,7%	2,6%	18,9%

The following table summarizes the various complications compared with different studies.

**Table 8: Comparison of postoperative complications of PK with the literature.**

### Conclusion

In summary, penetrating keratoplasty is a commonly used technique for corneal grafts in Morocco, yielding favorable results when surgical indications are carefully evaluated, therapeutic precautions against rejection are implemented, and regular follow-up is conducted to promptly address complications. Despite its low cost, the number of grafts remains inadequate, highlighting the urgent need for public awareness regarding organ donation, especially for corneal transplants.

The Moroccan Ministry of Health's initiative to promote corneal grafts aims to create a tissue bank, import grafts, and establish best practices with a goal of 1,000 grafts per year. This holistic approach considers various medical, legislative, and ethical aspects, and relies on active public collaboration for success.

Additionally, while penetrating keratoplasty is crucial, other lamellar techniques are available, each with unique benefits and challenges. The choice of the graft method should be tailored to individual cases, emphasizing the need for a personalized approach in corneal transplantation.

### Références

1. Lamm V, Hara H, Mammen A, Dhaliwal D, Cooper DKC. CORNEAL BLINDNESS AND XENOTRANSPLANTATION. *Xenotransplantation*. 2014 Mar;21(2):99–114.
2. Organisation Mondiale de la Santé. Projet de plan d'action pour la prévention de la cécité et des déficiences visuelles évitables 2014-2019 [Internet]. 2013 Mar [cited Feb 22, 2023]. Available from: [https://apps.who.int/iris/bitstream/handle/10665/150276/A66\\_11-fr.pdf](https://apps.who.int/iris/bitstream/handle/10665/150276/A66_11-fr.pdf)
3. Cabinet d'ophtalmologie des Flandres. Différents types de greffes de cornée [Internet]. 2022 [cited Oct 4, 2022]. Available from: <https://www.cof.fr/cornee-et-greffes/differents-types-de-greffes-de-cornee>
4. Singh R, Gupta N, Vanathi M, et al.. Corneal transplantation in the modern era. *Indian J Med Res*. 2019 Jul;150(1):7–22.
5. Boucenna W, Bourges JL. Kératoplastie transfixiante. *Journal Français d'Ophtalmologie*. 2022 May 1;45(5):543–58.

6. Hajji I, Bouslous N, Amine M, Baha T, Benhaddou R, Moutaouakil A. Acceptabilité du don de cornée : sondage auprès de la population de Marrakech. *Journal de la Société Marocaine d’Ophtalmologie* [Internet]. 2015 May 15 [cited 2023 Feb 22];(24). Available from: <https://revues.imist.ma/index.php/JSMO/article/view/8834>
7. Ramdani B. Etat des lieux du prélèvement et de la greffe d’organes, de tissus et de cellules MAROC. Conseil consultatif de transplantation d’organes et de tissus humains. 2017 Apr 7;
8. Pan Q, Li X, Gu Y. Indications and outcomes of penetrating keratoplasty in a tertiary hospital in the developing world: penetrating keratoplasty in China. *Clinical and Experimental Ophthalmology*. 2012 Apr;40(3):232–8.
9. Belghmaidi S, Hajji I, Soummane H, Ennassiri W, Essafi H, Moutaouakil A. Greffe de cornée: expérience du service d’ophtalmologie au CHU Mohammed VI de Marrakech, Maroc. *Pan Afr Med J*. 2016 Apr 6;23:158.
10. Tan DTH, Janardhanan P, Zhou H, Chan YH, Htoon HM, Ang LPK, et al. Penetrating Keratoplasty in Asian Eyes. *Ophthalmology*. 2008 Jun;115(6):975-982.e1.
11. Ghosheh FR, Cremona F, Ayres BD, Hammersmith KM, Cohen EJ, Raber IM, et al. Indications for Penetrating Keratoplasty and Associated Procedures, 2001–2005. *Eye and Contact Lens: Science & Clinical Practice*. 2008 Jul;34(4):211–4.
12. Maadane A, Boutahar H, Jomaa R, Bourakba S, Chariba S, Sekhsoukh R. KERATOCONE: ETUDE EPEDEMIOLOGIQUE PROSPECTIVE KERATOCONE: PROSPECTIVE EPEDEMIOLOGICAL STUDY. *Journal de la Société Marocaine d’Ophtalmologie*. 2019 Jun 10;(28):66–72.
13. Dr Y.Zouhair, Pr. B. Allali, Dr I.Morsli, Dr A. Idrissi, Dr S. Belaaroussi, Pr L. El Maaloum, Pr A. El Kettani, Pr K. Zaghoul. Keratoplastie Transfixiante : Résultats Anatomiques Et Fonctionnels. 2018 Oct [cited 2022 Dec 20]; Available from: [https://d1wqtxts1xzle7.cloudfront.net/57383951/E1305012330-libre.pdf?1536994536=&response-content-disposition=inline%3B+filename%3DKeratoplastie\\_Transfixiante\\_Resultats\\_An.pdf&Expires=1671565307&Signature=UZTD7u8BL0uFySAb3GFS7C1xmQFpHL8nriGV5XXQJpjjv1DTTDnX4qELIUGx6A0-Cel6gIjk2gyVZAVRISapX1jCbgJYEyD~BK98BSDGBsfG4yhAsZlZDrXrIJCMPcxlwC8fwbajyQj3Yygbg~dfUPvs76GCvHfR7R2pW7cAoOieS18GLIDr1IGQ1y2fiGq7GCGhKXf6inPjMXPCTGb9tGflk4myOOJKFSJ0YXVCNHX45qaCceeAtLpFdBe812baqfi2GYliP4qvI0bghAmqQnRkgEdpIwVWF2WKKWbdUBg89Z9U2dg-bE3cHYnsEvU3MIUvgaoFMNGJwxz734Dgw\\_\\_&Key-Pair-Id=APKAJLOHF5GGSLRBV4ZA](https://d1wqtxts1xzle7.cloudfront.net/57383951/E1305012330-libre.pdf?1536994536=&response-content-disposition=inline%3B+filename%3DKeratoplastie_Transfixiante_Resultats_An.pdf&Expires=1671565307&Signature=UZTD7u8BL0uFySAb3GFS7C1xmQFpHL8nriGV5XXQJpjjv1DTTDnX4qELIUGx6A0-Cel6gIjk2gyVZAVRISapX1jCbgJYEyD~BK98BSDGBsfG4yhAsZlZDrXrIJCMPcxlwC8fwbajyQj3Yygbg~dfUPvs76GCvHfR7R2pW7cAoOieS18GLIDr1IGQ1y2fiGq7GCGhKXf6inPjMXPCTGb9tGflk4myOOJKFSJ0YXVCNHX45qaCceeAtLpFdBe812baqfi2GYliP4qvI0bghAmqQnRkgEdpIwVWF2WKKWbdUBg89Z9U2dg-bE3cHYnsEvU3MIUvgaoFMNGJwxz734Dgw__&Key-Pair-Id=APKAJLOHF5GGSLRBV4ZA)
14. Benson MD, Kurji K, Tseng C, Bao B, Mah D. Analysis of penetrating keratoplasty in Northern Alberta, Canada, from 2000 to 2015. *Canadian Journal of Ophthalmology*. 2018 Dec;53(6):568–73.
15. Limaiem R, Mnasri H, Maazi AE, Mghaieth F, Chaabouni A, Matri LE. Kératoplastie transfixiante à visée thérapeutique : indications et résultats en Tunisie. *Journal Français d’Ophtalmologie*. 2009 Oct 1;32(8):551–7.
16. Wang X, Dang GF, Li YM, Li WF, Wu XY. General anesthesia versus local anesthesia for penetrating keratoplasty: a prospective study. *Int J Ophthalmol*. 2014 Apr 18;7(2):278–82.
17. Nurözler AB, Salvarli S, Budak K, Onat M, Duman S. Results of Therapeutic Penetrating Keratoplasty. *Jpn J Ophthalmol*. 2004 Jul;48(4):368–71.
18. Rahman I, Carley F, Hillarby C, Brahma A, Tullo AB. Penetrating keratoplasty: indications, outcomes, and complications. *Eye*. 2009 Jun;23(6):1288–94.
19. Sagnières H, Doat M, Girard A, Legeais JM, Renard G, Bourges JL. Acuité visuelle un et deux ans après kératoplastie transfixiante pour kératocône. *Journal Français d’Ophtalmologie*. 2007 Apr 1;30(5, Part 1):465–73.
20. Aneeq Ansari MS, Zulfiqar N, Nafees K, Shaheen M. Improvement In Visual Acuity Six Months After Penetrating Keratoplasty In Patients Of Keratoconus. *J Ayub Med Coll Abbottabad*. 2021;33(2):289–92.
21. de Toledo JA, de la Paz MF, Barraquer RI, Barraquer J. Long-Term Progression of Astigmatism After Penetrating Keratoplasty for Keratoconus: Evidence of Late Recurrence. *Cornea*. 2003 May;22(4):317.
22. Deshmukh R, Nair S, Vaddavalli PK, Agrawal T, Rapuano CJ, Beltz J, et al. Post-penetrating keratoplasty astigmatism. *Survey of Ophthalmology*. 2022 Jul 1;67(4):1200–28.
23. Borderie V, Guilbert E, Touzeau O, Laroche L. Kératoplastie transfixiante. *EMC - Ophtalmologie*. 2011 Jan;8(3):1–12.

24. Karadag O, Kugu S, Erdogan G, Kandemir B, Eraslan Ozdil S, Dogan OK. Incidence of and Risk Factors for Increased Intraocular Pressure After Penetrating Keratoplasty. *Cornea*. 2010 Mar;29(3):278–82.
25. Khattak A, Nakhli FR, Al-Arfaj KM, Cheema AA. Comparison of outcomes and complications of deep anterior lamellar keratoplasty and penetrating keratoplasty performed in a large group of patients with keratoconus. *Int Ophthalmol*. 2018 Jun;38(3):985–92.
26. Davila JR, Mian SI. Infectious keratitis after keratoplasty. *Current Opinion in Ophthalmology*. 2016 Jul;27(4):358–66.
27. Simpson SH. Creating a Data Analysis Plan: What to Consider When Choosing Statistics for a Study. *Can J Hosp Pharm*. 2015;68(4):311–7.