



Journal Homepage: [-www.journalijar.com](http://www.journalijar.com)

INTERNATIONAL JOURNAL OF ADVANCED RESEARCH (IJAR)

Article DOI:10.21474/IJAR01/21455

DOI URL: <http://dx.doi.org/10.21474/IJAR01/21455>



RESEARCH ARTICLE

DIAGNOSTIC PERFORMANCE AND SAFETY OF ULTRASOUND-GUIDED PERCUTANEOUS LIVER BIOPSY

Rachid El Jim^{1,2}, Hajar.Ellouzy^{1,2}, Asmae Lamine^{1,2}, Maria Lahlali^{1,2}, Nada Lahmidani^{1,2}, Amine El Mekkaoui^{1,2}, Mounia El Yousfi^{1,2}, Dafr-Allah Benajah^{1,2}, Mohammed El Abkari^{1,2}, Sidi Adil Ibrahimi^{1,2} and Hakima Abid^{1,2}

1. Hepato-gastroenterology department, hassan ii university medical center, fez, morocco.

2. Faculty of medicine, dentistry and pharmacy, sidi mohammed ben abdellah university, fez, morocco.

Manuscript Info

Manuscript History

Received: 21 May 2025

Final Accepted: 23 June 2025

Published: July 2025

Key words:-

Ultrasound-Guided Percutaneous Liver
Biopsy, indications, sensitivity, safety

Abstract

Introduction:-The role of liver biopsy in the management of patients with liver disease has changed significantly. The indications for liver biopsy (LB) have changed in recent years due to the development of sensitive and specific non-invasive tests; however, liver biopsy is still sometimes unavoidable.

The objective of our study is to analyze the indications for LB and evaluate its sensitivity and yield in the diagnosis of liver diseases.

Materials and methods:-This is a retrospective, descriptive study of patients who underwent ultrasound-guided PBH in the hepatology and gastroenterology department over a period of five years (from January 1, 2019, to January 1, 2024). Patient data was collected and analyzed using a data sheet (patients with incomplete files were excluded). Several parameters were analyzed, including age, sex, indications, biopsy fragment size, number of cores, complications, and comparison of pre-biopsy diagnoses with histological reports.

Results:-We collected 233 cases. The average age of our patients was 52.6 years (range: 17-90 years), with the majority being women (52.7%, n=123). An average of 46.6 LB procedures are performed per year. Our patients' indications were diverse, with tumor pathology being the most common: secondary liver cancer 34.76% (n=81), nonspecific liver mass 15.4% (n=36), and viral hepatitis, which has become less and less common over the years: hepatitis B 3.86% (n=9), hepatitis C 1.29% (n=3). The objective anatomopathological results were conclusive in 74.24% (n=173) of cases, allowing a definitive diagnosis to be made, and inconclusive in 25.75% (n=60). 6.87% of the latter underwent a second PBH, the results of which were conclusive in 68% (n=11) of cases. The ultrasound-guided PBH procedure was performed without incident in 89.70% (n=209) of cases, with post-procedure pain relieved by analgesics in 9.87% (n=23) and a single case of hemorrhage.

Conclusion:-Despite its invasive nature, PBH remains essential in the diagnosis and assessment of liver damage. When performed with strict adherence to contraindications and good ultrasound guidance, it is a safe procedure. Severe complications are rare. Obtaining an efficient yield requires the collection of a significant sample and a detailed pathological report allowing the clinician to analyze and critique the results.

"© 2025 by the Author(s). Published by IJAR under CC BY 4.0. Unrestricted use allowed with credit to the author."

Corresponding Author:-Rachid El Jim

Address:-1. Hepato-gastroenterology department, hassan ii university medical center, fez, morocco. 2. Faculty of medicine, dentistry and pharmacy, sidi mohammed ben abdellah university, fez, morocco.

Introduction:-

Ultrasound-guided percutaneous liver biopsy (UG PLB) has been a mainstay of diagnosis and management of liver diseases for several decades. It not only checks the type of lesions but also aids in selecting the most effective treatment plans, particularly in challenging situations like liver metastases, indeterminate masses, and specific hepatitis.[1], [2].The UG PLB was initially thought to be a simple procedure, but with the introduction of multimodal ultrasounds and contrast agents, it has undergone significant development, becoming more accurate in viral sample collection and easier to see lesions.[3]

Its widespread use is based on its ability to detect malignant tumors and assess the stage of liver fibrosis, while maintaining a relatively low complication rate, despite the increasing complexity of indications.[4]

Globally, primary or secondary liver cancer remains one of the leading causes of mortality, and a reliable histopathological diagnosis is sometimes essential to ensure optimal treatment planning.[5]Despite technological advances, many ambiguities remain regarding the clinical indications and diagnostic efficacy of ultrasound-guided percutaneous liver biopsy, particularly in the areas of secondary malignant liver tumors, indeterminate liver lesions, and chronic viral hepatitis.[6], These gray areas concern both the actual frequency of these indications and their impact on the reliability of histological results and, consequently, on therapeutic decisions.

At the same time, the choice of biopsy techniques and needle gauge remains a subject of debate, as does the role of advanced imaging modalities such as contrast-enhanced ultrasound (CEUS) or fusion imaging, whose contribution to the success rate of the procedure remains to be clarified[7]. Another crucial issue is striking a balance between diagnostic adequacy and procedural safety, especially in patients who have hepatic comorbidities that could raise their risk of complications. A sample that is too small or difficult to interpret can postpone diagnosis, postpone treatment, and jeopardize prognosis. [6].

This serves as the background for the study's conceptual framework. It seeks to establish a connection between the primary clinical indications for PLB and the technical factors that could affect the procedure's safety and diagnostic yield.

Methods:-

We conducted a retrospective, descriptive study of all patients who underwent ultrasound-guided percutaneous liver biopsy (UG-PLB) in the hepatology and gastroenterology department of our hospital over a five-year period, from January 1, 2019, to January 1, 2024, .

A standardized data collection form created specifically for this study was used to gather information from medical records that had been archived. Patients who lacked necessary information or had incomplete medical records were not included in the analysis. The variables studied included: age, sex, indications for biopsy, size of the fragment obtained, number of cores taken, complications observed, and concordance between the initial presumed diagnosis (before biopsy) and the final pathological results.

All biopsies were performed by experienced practitioners using a standardized technique under real-time ultrasound guidance. The type of needle, puncture site, number of passes, and post-procedure management were tailored to each patient based on the indication, clinical context, and potential contraindications.

The data collected were subjected to descriptive analysis. Diagnostic performance was assessed based on whether or not the histological results obtained were conclusive. The safety of the procedure was assessed by recording immediate or delayed adverse effects, whether minor (post-procedure pain, localized hematoma) or major (hemorrhage, perforation).

The Declaration of Helsinki's ethical guidelines were followed in the conduct of this study. All data were anonymized before processing. In accordance with national regulations,

Results:-**1. Demographic characteristics of patients**

A total of 233 patients were included in the study. The mean age at the time of biopsy was 52.6 years, ranging from 17 to 90 years. The gender distribution showed a slight female predominance, with 52.7% women (n = 123) versus 47.3% men (n = 110). The majority of patients (68.2%, n = 159) had at least one comorbidity, mainly a metabolic disorder (diabetes or metabolic syndrome).

2. Frequency of biopsies and clinical indications

Over the five-year period, an average of 46.6 liver biopsies per year were performed. Tumor pathologies clearly predominate in the distribution of clinical indications that resulted in liver biopsies guided by percutaneous ultrasound. Secondary liver cancer was the leading indication, with 81 cases (34.76%), followed by indeterminate liver masses in 36 cases (15.8%) and hepatocellular carcinoma in 18 cases (7.72%).

Inflammatory and autoimmune disorders were also common: autoimmune hepatitis (6.87%), isolated cholestasis (4.29%), and overlap syndromes including primary biliary cirrhosis (3.86%).

Unexplained biological disorders accounted for a significant proportion: cytolysis and/or cholestasis without clear etiology justified biopsy in a cumulative 27 cases (11.58%). Chronic viral liver diseases were rarer: hepatitis B in 9 cases (3.8%), hepatitis C in 3 cases (1.29%). Other indications included suspected metabolic steatopathy (MASH) (6.02%), cryptogenic cirrhosis (1.72%), cholangiocarcinoma (1.72%), and, to a lesser extent, a discrepancy between ultrasound and fibroscan (0.86%).

The distribution of clinical indications for percutaneous ultrasound-guided liver biopsies is shown in Figure 1, with a focus on the prevalence of tumor pathologies

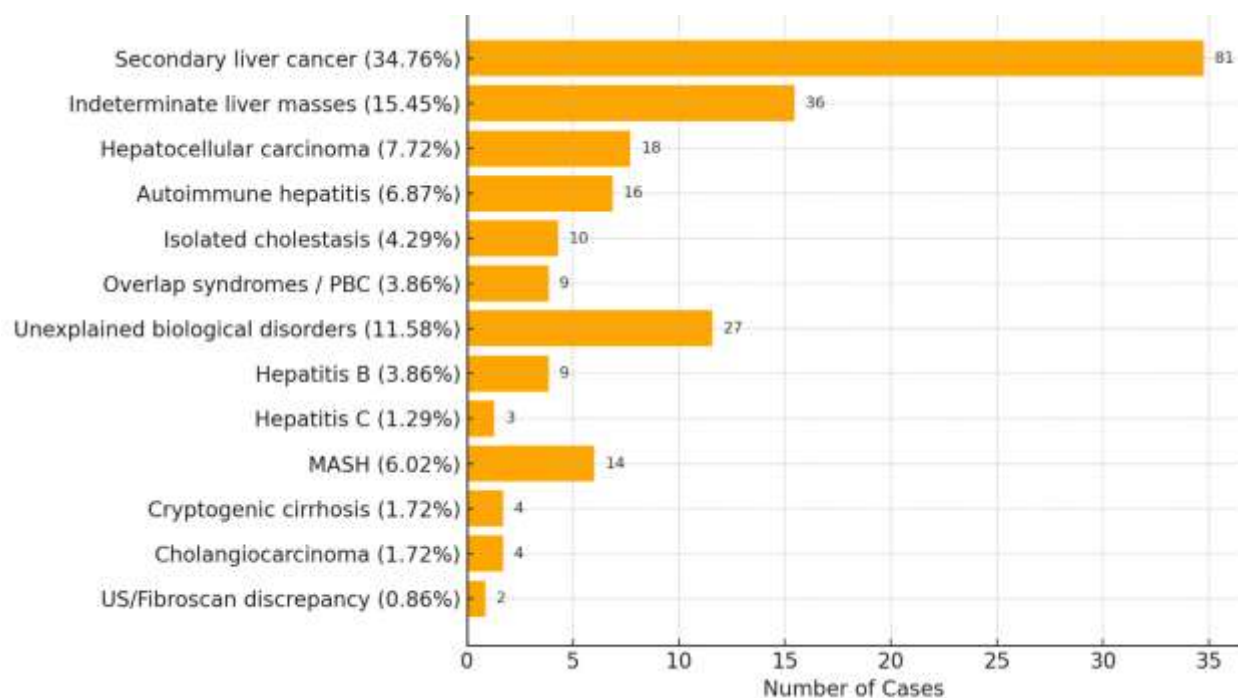


Figure 1: The distribution of clinical indications for percutaneous ultrasound-guided liver biopsies.

3. Technical details of the procedure

Every biopsy was carried out under strict aseptic conditions and with real-time ultrasound guidance. With an average of 1.8 cores per procedure, the needle gauge used was either 16G or 18G, depending on the situation.

The average length of the fragments obtained was 21.3 mm, with a median of 8 to 12 analyzable portal tracts.

No sampling failures were reported. Loss of material during handling « unanalyzable fragment » occurred in 2.1% of cases (n = 5).

Regarding the number of needle passes, the majority of procedures (n = 191-81.97%) were completed with a single pass. Two passes were required in 39 cases (16.71%), while three passes were performed in only 3 cases (1%).

4. Diagnostic performance of biopsy

In 74.25 percent of cases (n = 173), the anatomopathological results were considered conclusive, allowing for the establishment of a final diagnostic that clinicians could use. However, 25.75% of the biopsies (n = 60) were deemed insufficient or non-contributive, either due to incomplete tissue representation or fragmented materials.

Out of these 60 non-conclusive cases, 6.6% of patients (n = 4) received a second biopsy, with conclusive results in 75% of cases (n = 3), thereby improving the overall diagnostic performance.

In parallel, 44 patients whose initial biopsy was considered Inconclusive received an anatomopathological relecture via a second senior pathologist in order to prevent an invasive repeat of the procedure. This reassessment, which was carried out with a double lecture in college, has enabled a final diagnosis in a significant number of cases (n=37,84%) improving overall diagnostic performance without the need for a second opinion.

The underlying indication had a significant impact on the diagnostic yield of ultrasound-guided percutaneous liver biopsy. With high conclusive rates for secondary liver cancer (85.2%), hepatocellular carcinoma (83.3%), and indeterminate liver masses (77.8%), tumor-related indications continuously performed the best. These tumor-related yields did not differ significantly, according to statistical analysis ($p > 0.05$).

However, compared to secondary liver cancer, biopsies conducted for unexplained cytotoxicity/cholestasis (55.6%) and metabolic steatopathy (MASH) (58.3%) produced noticeably lower diagnostic rates ($p = 0.0033$ and $p = 0.0355$, respectively). The intermediate yields for overlap syndromes, autoimmune hepatitis, and isolated cholestasis ranged from 60% to 68.7%; however, these differences were not statistically significant ($p > 0.05$).

Despite being less common, chronic viral hepatitis produced moderate yields (66.7% for HBV and 60% for HCV), with no statistically significant differences from tumor indications. With 100% conclusive results for imaging discrepancies, rare indications like cryptogenic cirrhosis, cholangiocarcinoma, and discordance between ultrasound and Fibroscan showed varying but generally favorable yields.

Table 1 lists the number of conclusive cases and associated p-values for the diagnostic yield of percutaneous liver biopsy based on the underlying clinical indication, using secondary liver cancer as the reference group.

Indication	Cases (n)	Conclusive (n)	Yield (%)	p-value vs. Secondary Cancer
Secondary liver cancer	81	69	85.2	1.0000
Indeterminate liver mass	36	28	77.8	0.4738
Hepatocellular carcinoma	18	15	83.3	1.0000
Autoimmune hepatitis	16	11	68.7	0.2223
Isolated cholestasis	10	6	60.0	0.1251
Overlap syndromes (incl. PBC)	9	6	66.7	0.3458
Unexplained cytotoxicity/cholestasis	27	15	55.6	0.0033
Hepatitis B	9	6	66.7	0.3458
Hepatitis C	3	2	66.6	0.4002
Metabolic steatopathy (MASH)	14	8	57.14	0.0355
Cryptogenic cirrhosis	4	3	75.0	0.4919
Cholangiocarcinoma	4	3	75%	0.4919
US-Fibroscan discrepancy	2	2	100.0	1.0000

Table 1: Diagnostic Yield of Ultrasound-Guided Percutaneous Liver Biopsy by Clinical Indication

5. Tolerance and safety of the procedure

The overall tolerance of the procedure was satisfactory. No incidents were reported in 89.70% of cases (n = 209). Moderate post-procedure pain, effectively controlled by simple analgesics, was noted in 9.87% of patients (n = 23). Only one case of major complication was reported: intra-abdominal hemorrhage requiring close monitoring, without surgical or radiological intervention.

No procedure-related mortality was observed.

Discussion:-

Demographic results:

In our study, the mean age of patients undergoing ultrasound-guided percutaneous liver biopsy was 52.6 years, with a slight female predominance (52.7%). 68.2% of patients had at least one comorbidity at presentation, primarily metabolic conditions like diabetes or metabolic syndrome.

This mean age reflects the time when liver-related comorbidities become more common and is in line with findings from the literature that report similar age ranges for patients undergoing liver biopsy [8]. Additionally, the slight female predominance is consistent with earlier research that frequently shows a higher prevalence of metabolic syndrome and autoimmune disease in women, which is one of the common reasons for liver biopsy.[9]

The majority of patients (68.2%) had at least one comorbidity when they first arrived, with metabolic disorders being the most common. This result is in line with the established link between liver diseases and metabolic syndrome, which frequently necessitate biopsy for proper diagnosis and treatment.[9]

clinical indications:

The indications have changed from viral hepatitis to metabolic liver disease, which is in line with changing clinical practice and larger epidemiological trends.

The most common reason for a percutaneous liver biopsy in our group was secondary liver cancer, which accounted for 34.76% of the yearly procedures. noted that metastatic liver lesions continue to be a frequent cause of histologic sampling, especially when imaging results are unclear or tissue is needed for molecular profiling. This preponderance is consistent with their findings.

The high percentage in our series most likely reflects the clinical necessity to distinguish secondary lesions from primary hepatocellular carcinoma or benign nodules, as well as the rising incidence of gastrointestinal and extra-hepatic malignancies in our area. Furthermore, despite advancements in non-invasive imaging, liver biopsies remain essential for guiding therapeutic strategies, particularly in the age of tailored and targeted treatments.

In contrast, another study documented a change in the indications for liver biopsies over a five-year period, from hepatitis C virus (HCV) infection to metabolic dysfunction–associated fatty liver disease (MAFLD), which reflected shifts in the prevalence of the disease and management approaches [10]

It has also been shown that percutaneous liver biopsy is useful for diagnosing benign liver tumors like focal nodular hyperplasia and hepatocellular adenomas. Imaging and biopsy work in tandem to prevent needless surgical procedures [11].

Tolerance, performance and safety of the procedure:

PLB is still necessary for histological evaluation even with the rise of non-invasive diagnostic techniques, especially in complex cases where imaging alone is not enough [12]. Studies have shown that percutaneous liver biopsy has a low incidence of serious complications and a high diagnostic accuracy, with nearly all cases resulting in successful histological diagnoses [2]. According to a study comparing endoscopic ultrasound-guided fine-needle aspiration (EUS-FNA) and ultrasound-guided percutaneous biopsy, both procedures performed diagnostically equally, but EUS-FNA was linked to fewer side effects[13].

Additionally, it has been demonstrated that using contrast-enhanced ultrasound improves the sensitivity, and success rate of PLB, especially for liver tumors that are large or difficult to see [14].

Therefore, PLB keeps offering vital diagnostic information in situations where non-invasive methods are unable to produce conclusive results, guaranteeing precise

Our cohort's overall procedure tolerance was satisfactory. In 89.70% of cases (n = 209), no adverse events were reported, and in 9.87% of patients (n = 23), moderate post-procedural pain was successfully treated with basic analgesics. There was only one significant complication, an intra-abdominal hemorrhage that needed careful observation but didn't require radiologic or surgical intervention. Crucially, there was no procedure-related death. These results are in line with the literature, which shows that minor events like pain are still the most common but controllable, and that major complications are usually reported in less than 1% of cases.[15], [16]. When several needle passes are necessary or in patients who are not cooperative, complications are more likely to occur.[17], [18]. Prior research has also shown that ultrasound-guided liver biopsies, especially those using contrast-enhanced ultrasound (CEUS), have a lower rate of complications than blind methods [19]

The majority of biopsies (n = 191, 81,9%) in our series were successfully completed with automated or semi-automated cutting needles pass; 39 cases (16.7%), however, required two passes, and only three procedures (1%) required three passes.

the results of liver biopsies often supported or updated early clinical suspicions, which helped inform treatment choices. In line with earlier reports, this was especially noticeable in cases of viral hepatitis, secondary liver metastases, and non-specific hepatic masses [20]. Histopathological analysis yielded a definitive diagnosis in 74.25% of our cases, enabling clinicians to confidently develop treatment plans. On the other hand, 25.75% of samples were considered non-contributive, frequently as a result of incomplete or broken material. Remarkably, a subset of these cases underwent repeat biopsy, which improved overall diagnostic accuracy with a diagnostic yield of 68%.

Moreover, liver biopsy is still crucial for classifying hepatic pathology, particularly in cases of cancer and chronic liver disease, where histological information influences treatment planning and prognosis. The literature [2] highlights these roles, and our experience was no exception, as biopsy results had a direct bearing on clinical judgment and patient follow-up.

Conclusion:-

Ultrasound-guided percutaneous liver biopsy remains an essential tool in the evaluation of liver diseases, even in the era of advanced non-invasive techniques such as transient elastography and high-resolution imaging. In our study, liver biopsy demonstrated an overall diagnostic yield of 74.25%, with particularly high performance for tumor-related indications, notably secondary liver cancer and indeterminate hepatic masses. Autoimmune and inflammatory liver diseases showed an intermediate yield, whereas isolated biological abnormalities and steatopathy were less contributive.

Our results demonstrate the critical influence of biopsy specimen quality on diagnostic accuracy, including fragment length and number of needle passes. With a very low rate of complications and no significant adverse events noted, the procedure had an excellent safety profile. In order to maximize diagnostic effectiveness and preserve the clinical significance of liver biopsy, careful indication selection is still necessary.

Our study demonstrates also that PLB is still essential in complex or unclear clinical scenarios, especially when significant therapeutic decisions rely on histological confirmation, even in the face of ongoing advancements in non-invasive testing. It continues to play an important role in the management of liver diseases by guiding diagnosis, developing treatment plans, and ensuring appropriate longitudinal patient follow-up.

Bibliography:-

- [1]« Ultrasound-guided percutaneous liver biopsy: A review of what operators need to know », *Medicine*, vol. 103, juill. 2024, doi: 10.1097/md.00000000000038673.
- [2]« Ultrasound-Guided Percutaneous Liver Biopsy: Diagnostic Value in Diffuse Liver Disease and Viral Hepatitis », *Journal of molecular virology and immunology*, juill. 2023, doi: 10.46683/jmvi.2023.75.
- [3]« The Application of Multimodal Ultrasound Technology in Improving the Success Rate of Liver Tumor Puncture under Poor Visibility on Conventional Ultrasound Imaging », *SciSpace - Paper*. Consulté le: 28 juillet 2025. [En ligne]. Disponible sur: <https://scispace.com/papers/the-application-of-multimodal-ultrasound-technology-in-21sls95s9t>
- [4]« Clinical application of ultrasonography-guided percutaneous liver biopsy and its safety over 18 years. », *Clinical and molecular hepatology*, vol. 26, n° 3, p. 318-327, mai 2020, doi: 10.3350/CMH.2019.0019N.
- [5]« Role of Liver Biopsy in Assessment of Radiologically Identified Liver Masses », *Digestive Diseases and Sciences*, p. 1-7, févr. 2021, doi: 10.1007/S10620-021-06822-9.
- [6]« Ultrasound-guided percutaneous biopsy for focal liver lesions: Adverse events and diagnostic yield in a single-centre analysis », *PLOS ONE*, vol. 19, mai 2024, doi: 10.1371/journal.pone.0304026.
- [7]« Direct comparison of biopsy techniques for hepatic malignancies », *Clinical and molecular hepatology*, vol. 27, n° 2, p. 305-312, avr. 2021, doi: 10.3350/CMH.2020.0301.
- [8]« Dataset with Demographic characteristics of the study samples used in the study. », *SciSpace - Paper*. Consulté le: 30 juillet 2025. [En ligne]. Disponible sur: <https://scispace.com/papers/dataset-with-demographic-characteristics-of-the-study-1andws3u2e>

- [9]« Ethnic, gender, and age-related differences in patients with the metabolic syndrome », Current Hypertension Reports, vol. 11, n° 2, p. 127-132, mars 2009, doi: 10.1007/S11906-009-0023-8.
- [10]« Changes in indications for outpatient percutaneous liver biopsy over 5 years: from hepatitis C to fatty liver disease », Gastroenterologia Y Hepatologia (english Edition), vol. 45, n° 8, p. 579-584, oct. 2022, doi: 10.1016/j.gastre.2021.12.005.
- [11]« [Ultrasound-guided puncture-biopsy of the liver could replace blind puncture-biopsy in diffuse hepatopathies. Retrospectivestudy of 1293 patients] », Gastroenterologie Clinique Et Biologique, vol. 19, p. 703-706, août 1995.
- [12]« Utilité et tolérance de la réalisation d'une biopsie hépatique pour l'exploration des anomalies hépatiques après une allogreffe de cellules souches hématopoïétiques », SciSpace - Paper. Consulté le: 30 juillet 2025. [En ligne]. Disponible sur: <https://scispace.com/papers/utilite-et-tolerance-de-la-realisation-d-une-biopsie-lgbjadsk76>
- [13]« Comparative Study of an Ultrasound-guided Percutaneous Biopsy and Endoscopic Ultrasound-guided Fine-needle Aspiration for Liver Tumors », Internal Medicine, vol. 60, n° 11, p. 1657-1664, juin 2021, doi: 10.2169/INTERNALMEDICINE.6183-20.
- [14]« (PDF) Prospective comparison between real time contrast enhanced and conventional ultrasound guidance in percutaneous biopsies of liver tumors. (2015) | Zeno Spârchez | 57 Citations ». Consulté le: 30 juillet 2025. [En ligne]. Disponible sur: <https://scispace.com/papers/prospective-comparison-between-real-time-contrast-enhanced-q02xjqzm0q>
- [15]« Percutaneous Liver Biopsies Guided with Ultrasonography: A Case Series », Iranian Journal of Radiology, vol. 10, n° 3, p. 182-184, août 2013, doi: 10.5812/IRANJRI.13184.
- [16]« Percutaneous Liver Biopsies: Safety and Efficacy », Türkiye Klinikleri Tıp Bilimleri Dergisi, vol. 30, n° 4, p. 1287-1291, janv. 2010, doi: 10.5336/MEDSCI.2009-13508.
- [17]« Compare The Efficacy and Complications of 16 Gauge Vs 18 Gauge Core Biopsy Needle in Ultrasound Guided Percutaneous Liver Biopsies », Journal of the Dow University of Health Sciences, vol. 11, n° 2, p. 36-40, oct. 2017, doi: 10.36570/JDUHS.2017.2.506.
- [18]« Impact of risk factors on the efficacy and complications of ultrasound-guided percutaneous liver biopsy of space-occupying lesions. », Problemes olímpics, vol. 64 6, n° 6, p. 497-505, juin 2022, doi: 10.1016/j.rxeng.2020.09.012.
- [19]« Major changes in the number and indications of liver biopsy for chronic liver diseases over one decade in France. », European Journal of Gastroenterology & Hepatology, vol. 28, n° 9, sept. 2016, doi: 10.1097/MEG.0000000000000683.
- [20]« Contrast-enhanced ultrasound-guided biopsy improved diagnostic accuracy in patients with hepatitis: A prospective multicenter study of 2056 patients », SciSpace - Paper. Consulté le: 30 juillet 2025. [En ligne]. Disponible sur: <https://scispace.com/papers/contrast-enhanced-ultrasound-guided-biopsy-improved-30k7zq54ra>