



RESEARCH ARTICLE

SEALING THE FUTURE: APEXIFICATION WITH BIODENTINE – A CASE REPORT

Krishna Prasada L¹, Gunjan Chawla², Julia Jacob² and Narendra Babu²

1.Head of the department, Department of Conservative dentistry and Endodontics, Kvg Dental College and Hospital, Sullia, Karnataka, India.

2.Post graduate, Department of Conservative dentistry and Endodontics, Kvg Dental College and Hospital, Sullia, Karnataka, India.

Manuscript Info

Manuscript History

Received: 07 June 2025

Final Accepted: 9 July 2025

Published: August 2025

Abstract

The root growth is a gradual phenomenon and a root apex closure takes place for up to three years after the tooth eruption. If some damage to the tooth occurs during this period, it will impede the root apex closure process. The root canal with thin and delicate walls is therefore wide and the apex is always open. This impairs the instrumentation of the root canal and prevents an appropriate apical stop. It is essential that an artificial apical barrier is created, or the apical foramen is closed with calcified tissue to permit the condensation of the filling material and to facilitate apical sealing in such cases. The apexification of premature permanent teeth with open apices may be a feasible alternative. Apexification is an endodontic procedure designed to induce apical closure in nonvital immature permanent teeth with open apices by stimulating hard tissue formation and presents a unique challenge to dental professionals.²In the past,calcium hydroxide was commonly used in apexification, but it has disadvantages, including questionable tissue apposition, high solubility, low push-out bond strength, the potential for voids, and an inability to create a reliable apical barrier.³To address these limitations,mineral trioxide aggregate(MTA)emerged as a biocompatible alternative, forming a monoblockbarrierthat promotes cementum deposition, though its extended setting time remains a drawback.

"© 2025 by the Author(s). Published by IJAR under CC BY 4.0. Unrestricted use allowed with credit to the author."

Introduction:-

Biodentine, a calcium silicate based material, has emerged as a promising dentinal substitute for single visit apexification, offering improved handling and safety compared to materials like Mineral Trioxide Aggregate (MTA).⁴It enables efficient single-visit apexification with superior physical properties, including compressive strength comparable to natural dentin and a faster setting time (~62 minutes). Its biocompatibility stimulates periodontal ligament stem cell proliferation, migration, adhesion, and mineralization at optimal concentrations, while its antibacterial activity and ability to form micromechanical tags with dentin ensure a reliable apical seal.^{5,6}Biodentine's physical and mechanical properties are similar to dentin, and it is exceptionally biocompatible, allowing for bonding with composite resin and forming a stable apical barrier.³

Corresponding Author:-Krishna Prasada L

Address:-Kvg Dental College And Hospital, Sullia, Karnataka, India.

This case report illustrates two cases of maxillary incisors with open apices and periapical lesions, successfully managed through apexification using Biodentine followed by gutta percha obturation and prosthetic rehabilitation.

Case Report:-

CASE 1:

A 36-year-old male presented with mild-to-moderate continuous pain in the upper left front tooth region for two weeks. Clinical examination revealed dental caries approaching lingually and tenderness to percussion with respect to tooth 22, along with discolouration of tooth and sinus opening in the buccal mucosa (FIGURE – A,B).

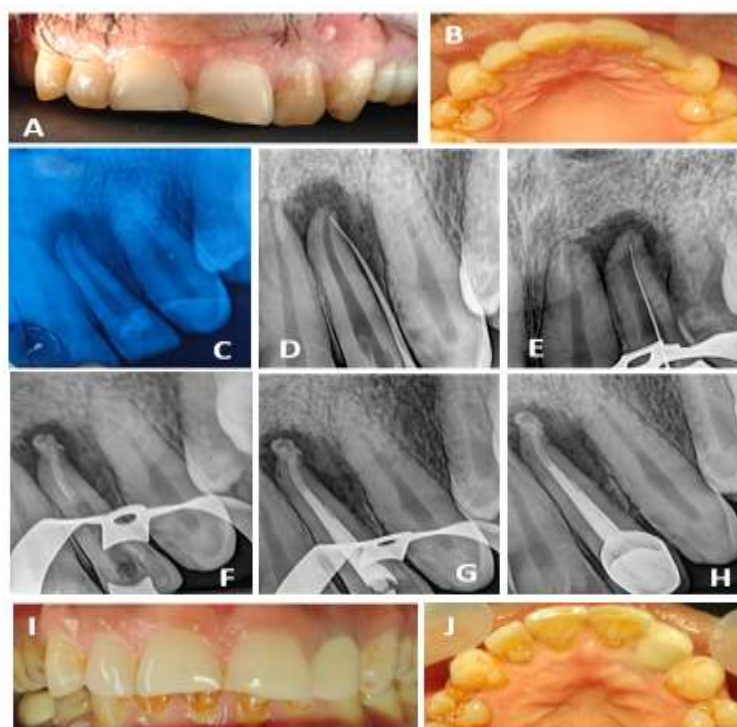
A radiographic examination of tooth 22 showed radiolucency involving enamel, dentin and pulp with an immature open apex and ill-defined periapical radiolucency (FIGURE – C). Confirmation of the affected tooth was done by sinus tracing using gutta percha cone (FIGURE – D). The patient was diagnosed with a symptomatic periapical abscess with sinus opening involving tooth 22.

Given his dental history and the open root apex, a biodentine apexification procedure was chosen for tooth 22, followed by conventional root canal treatment. An Endo-Z bur (Dentsply Maillefer, Ballaigues, Switzerland) was used to create an access opening under rubber dam isolation and local anesthesia with 2% lidocaine containing 1:100,000 epinephrine. A No. 15 K file was employed to achieve apical patency, with the working length measured using an apex locator (Root ZX Mini, J. Morita, Saitama, Japan) and confirmed radiographically (FIGURE – E). Cleaning and shaping were accomplished with hand K-files (Mani, New Delhi, India) and ProTaper Universal rotary files (Dentsply Maillefer). The canals were irrigated with 3% sodium hypochlorite (Hyposol; PrevestDenPro, Jammu, India), 17% EDTA (Neoedta; Orikam, Gurgaon, India), and saline, followed by drying with sterile paper points.

After two weeks of calcium hydroxide medication (RC Cal; Prime Dental, Thane, India), the root canal was disinfected using 3% sodium hypochlorite. Following the manufacturer's guidelines, Bio dentine was mixed and delivered apically using a carrier, ensuring 3-4 mm of bio dentine placement (FIGURE – F).

Radiographic verification confirmed proper placement. The remaining canal space was filled with rolled cone gutta-percha technique and bio ceramic sealer (Angelus Bio C Sealer Bioceramic Root Canal Sealer) (FIGURE – G). Finally, the post endodontic restoration was done using composite, followed by crown preparation and cementation after 1 week. (FIGURE – I, J)

The patient was followed up for 3 months, with a radiograph showing reduction in lesion size.(FIGURE – H)



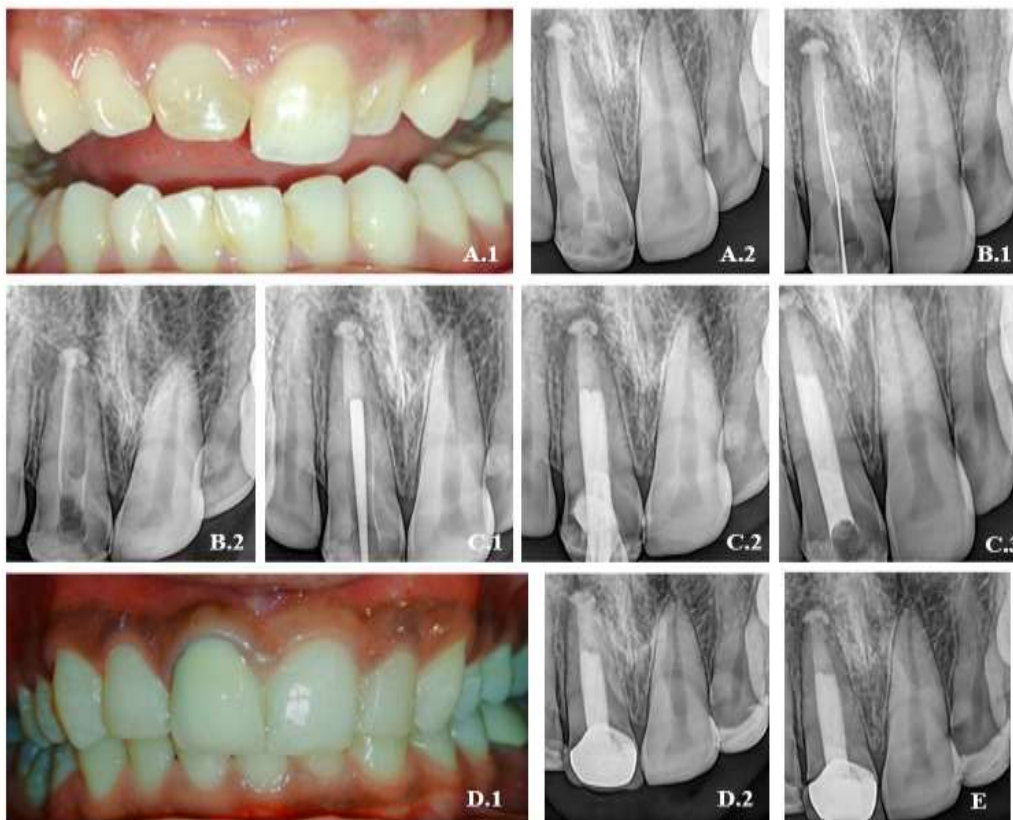
A,B – PRE-OPERATIVE PHOTOGRAPHS – LABIAL VIEW AND OCCLUSAL VIEW, C – PRE-OPERATIVE RADIOGRAPH, D – SINUS TRACING DONE USING GP CONE, E- WORKING LENGTH DETERMINED, F – BIODENTINE APICAL PLUG PLACED, G – OBTURATION COMPLETED, H – 3-MONTHS FOLLOW UP RADIOGRPAH, I,J – POST-OPERATIVE PHOTOGRAPHS – LABIAL AND

Case 2:-

A 20-year-old male patient reported to the Department of Conservative Dentistry and Endodontics with a chief complaint of fractured tooth in the upper front tooth. (FIGURE A.1) Patient gave a history of trauma 6 months ago and visited dentist 2 months ago. On clinical examination, composite restoration is seen wrt 11. Vitality test was then performed, and tooth showed negative response to electric pulp testing. Radiographic examination revealed an immature tooth with wide open apex and radiolucent material seen in the pulp canal, suggestive of intracanal medicament in relation to 11. (FIGURE A.2) The patient was diagnosed with previously initiate root canal treatment wrt 11. The treatment plan was decided to continue with the root canal and seal the apex using biodentine (Septodont company, France).

Access opening was done using Endo-Z bur (Dentsply Maillefer, Ballaigues, Switzerland) under rubber dam isolation. Working length was determined and gentle instrumentation was done with #80 H-file (Mani files) in circumferential manner to remove the intracanal medicament present inside the canal. (FIGURE B.1 and B.2) Root canal debridement was done using alternative irrigation with 1% NaOCl and saline. Then the canal was completely dried with multiple absorbent paper points and calcium hydroxide (RCcal, PRIME dental products pvt. Ltd.) was placed in root canal and access was sealed with Cavit and patient was recalled after 1 week. At subsequent appointment, calcium hydroxide dressing was removed, and saline irrigation was done. After drying the canal,

Biodentine was manipulated and condensed with hand plugger till the thickness of 5mm and after that root canal was obturated with gutta percha using reverse cone technique (FIGURE C.1 and C.2) and post-obturation radiograph was taken to confirm the completion of the endodontic therapy (FIGURE C.3) and access was sealed with composite. After 1 week, PFM crown preparation and cementation was done along with composite build up wrt 12 and 22. (FIGURE D.1 and D.2) A 2 month follow up radiograph revealed decrease in apical radiolucency. (FIGURE E) Tooth was completely asymptomatic and has been called for future follow up.



A.1– PRE-OPERATIVE PHOTOGRAPH, A.2 – PRE-OPERATIVE RADIOGRAPH, B.1, B.2 –REMOVAL OF ICM, C.1- BIODENTINE APICAL PLUG PLACED, C.2, C.3 –OBTURATION DONE, D.1, D.2 –CROWN CEMENTATION DONE, E – 3-MONTHS FOLLOW UP RADIOGRAPH.

Discussion:-

The management of immature permanent teeth with necrotic pulps and wide-open apices is particularly challenging in endodontics, not only due to the difficulty in achieving a proper apical seal but also because the thin dentinal walls are more susceptible to fracture.⁷ Traditional apexification with calcium hydroxide, although effective in inducing apical barrier formation, requires multiple appointments over several months, often leading to poor patient compliance and increased risk of reinfection or treatment failure due to missed follow-ups.⁷ Additionally, prolonged exposure to calcium hydroxide can further weaken the already delicate root structure, increasing the likelihood of cervical root fractures.⁸

To overcome these limitations, contemporary protocols favour the use of biocompatible materials such as mineral trioxide aggregate (MTA) and Biodentine for creating an artificial apical barrier in a single visit.⁹ While MTA has been widely used, it presents drawbacks including a long setting time, difficult handling, and potential for tooth discoloration.¹⁰ Biodentine, a tricalcium silicate-based cement introduced as a dentine substitute, offers several advantages over MTA, such as a significantly shorter setting time (as little as 12 minutes), improved handling characteristics, and mechanical properties closely resembling natural dentine.¹¹

Clinical studies have demonstrated that Biodentine can be used effectively as an apical plug in single-visit apexification procedures, with outcomes comparable to or even surpassing those of MTA in terms of periapical healing and barrier formation.¹² For optimal sealing and prevention of microleakage, a 4–5 mm thick Biodentine apical plug is recommended, as thinner plugs (1–2 mm) may be less effective for both Biodentine and MTA. Biodentine's bioactivity is further evidenced by its ability to induce apatite formation, which enhances the marginal seal and supports the healing of periapical tissues.¹³

Furthermore, Biodentine continues to strengthen over time as its porosity decreases, reaching compressive strengths similar to natural dentine within a month. Case reports and follow-up studies have shown favourable clinical and radiographic outcomes, including the resolution of periapical lesions and the formation of a calcific barrier apical to the Biodentine plug. Thus, Biodentine is increasingly regarded as a reliable and efficient material for apexification, especially in cases where patient compliance or time constraints are concerns.¹³

Conclusion:-

The single-visit apexification with biocompatible materials such as Biodentine represents a significant advancement in the management of teeth with open apices. By addressing the shortcomings of traditional calcium hydroxide therapy and overcoming the drawbacks associated with MTA, Biodentine provides a reliable, efficient, and time-saving alternative. Its excellent biocompatibility, capacity for biomimetic mineralization, and favourable handling properties make it particularly well-suited for creating a predictable apical barrier. This approach not only streamlines the treatment process but also enhances clinical outcomes, offering a promising solution for both practitioners and patients facing the challenges of immature permanent teeth.

References:-

1. Aeran H, Sharma M, Tuli A. Biodentine: Material of choice for apexification. *International Journal of Oral Health Dentistry*. 2021;7(1):54-56.
2. Gawthaman M, Vinodh S, Mathian VM, Vijayaraghavan R, Karunakaran R. Apexification with calcium hydroxide and mineral trioxide aggregate: Report of two cases. *J Pharm Bioallied Sci*. 2013 Jul;5(Suppl 2):S131-4. doi: 10.4103/0975-7406.114305. PMID: 23956590; PMCID: PMC3740659.
3. Rane MS, de Ataide I, Fernandes M. Apexification and dentinal wall reinforcement using Biodentine and glass fiber post. *J Conserv Dent*. 2022 Jan-Feb;25(1):98-100. doi: 10.4103/jcd.jcd_533_21. Epub 2022 May 2. PMID: 35722064; PMCID: PMC9200175.
4. Ravindran V, Jeevanandan G. Comparative Evaluation of the Physical and Antimicrobial Properties of Mineral Trioxide Aggregate, Biodentine, and a Modified Fast-Setting Mineral Trioxide Aggregate Without Tricalcium Aluminate: An In Vitro Study. *Cureus*. 2023 Aug 2;15(8):e42856. doi: 10.7759/cureus.42856. PMID: 37664390; PMCID: PMC10473445.
5. Thakur V. Modified single-step apexification and strengthening of thin dentinal walls with Biodentine. *J Conserv Dent Endod*. 2024 Feb;27(2):214-218. doi: 10.4103/JCDE.JCDE_239_23. Epub 2024 Feb 8. PMID: 38463468; PMCID: PMC10923217.
6. Abuarqoub D, Aslam N, Jafar H, Abu Harfil Z, Awidi A. Biocompatibility of Biodentine™® with Periodontal Ligament Stem Cells: In Vitro Study. *Dent J (Basel)*. 2020 Feb 8;8(1):17. doi: 10.3390/dj8010017. PMID: 32046292; PMCID: PMC7148534.
9. Vidal K, Martin G, Lozano O, Salas M, Trigueros J, Aguilar G. Apical Closure in Apexification: A Review and Case Report of Apexification Treatment of an Immature Permanent Tooth with Biodentine. *J Endod*. 2016 May;42(5):730-4. doi: 10.1016/j.joen.2016.02.007. Epub 2016 Mar 16. PMID: 26994597.
10. Anjum FS, Brusevold IJ, Wigen TI. Prognosis of non-vital incisors after apexification using bioceramics: a retrospective study. *Eur Arch Paediatr Dent*. 2024 Oct;25(5):637-644. doi: 10.1007/s40368-024-00915-5. Epub 2024 Jun 5. PMID: 38839734; PMCID: PMC11442509.
11. Dhall, Sonam; Mittal, Rakesh; Tandan, Monika. Single-Visit Apexification with Biodentine and Platelet-Rich Fibrin. *Journal of Dental Research and Review* 7(4):p 201-205, Oct-Dec 2020. | DOI: 10.4103/jdrr.jdrr_69_20
12. Tolibah YA, Kouchaji C, Lazkani T, Ahmad IA, Baghdadi ZD. Comparison of MTA versus Biodentine in Apexification Procedure for Nonvital Immature First Permanent Molars: A Randomized Clinical Trial. *Children (Basel)*. 2022 Mar 14;9(3):410. doi: 10.3390/children9030410. PMID: 35327782; PMCID: PMC8946907.
13. Nayak G, Hasan MF. Biodentine-a novel dentinal substitute for single visit apexification. *Restor Dent Endod*. 2014 May;39(2):120-5. doi: 10.5395/rde.2014.39.2.120. Epub 2014 Mar 21. PMID: 24790925; PMCID: PMC3978102.
14. Pavula, S.; Sherwood, I. Anand; Amaechi, Bennett Tochukwu1; Murugadoss, Vaanjay; Prakasam, Ernest Prince; Abirami, A. Azhagu. Cone-beam computed tomographic evaluation of biodentine apexification for traumatized necrotic immature permanent incisors: One-year clinical study. *Endodontology* 36(1):p 67-74, Jan-Mar 2024. | DOI: 10.4103/endo.endo_233_22
15. Bani M, Sungurtekin-Ekçi E, Odabaş ME. Efficacy of Biodentine as an Apical Plug in Nonvital Permanent Teeth with Open Apices: An In Vitro Study. *Biomed Res Int*. 2015;2015:359275. doi: 10.1155/2015/359275. Epub 2015 Sep 7. PMID: 26436090; PMCID: PMC4575981.