

| | | |
|---|---|---|
|  <p>ISSN NO. 2320-5407</p> | <p>Journal Homepage: www.journalijar.com</p> <p>INTERNATIONAL JOURNAL OF ADVANCED RESEARCH (IJAR)</p> <p>Article DOI:10.21474/IJAR01/21602 DOI URL: http://dx.doi.org/10.21474/IJAR01/21602</p> |  |
|---|---|---|

RESEARCH ARTICLE

MALIGNANT TRANSFORMATION IN MATURE CYSTIC TERATOMA- A CASE REPORT

Priyanka Singh, Priyanka Sameer and Ila Tiwari

Manuscript Info

Manuscript History

Received: 13 June 2025

Final Accepted: 15 July 2025

Published: August 2025

Abstract

Squamous cell carcinoma in mature cystic teratoma is the most common malignant transformation observed, presenting in postmenopausal women older than 50 years and in large tumours. Early-stage disease confined to the ovary can be easily treated by surgery, not requiring adjuvant treatment, with a good prognosis.

"© 2025 by the Author(s). Published by IJAR under CC BY 4.0. Unrestricted use allowed with credit to the author."

Introduction:-

More than 95% of teratoma are mature cystic teratoma or dermoid cyst. The 20-25% of all ovarian neoplasms are dermoid cysts. It is the most common ovarian tumour of young women however it may occur in perimenopausal women and the malignant transformation of any of the dermatomal tissue is also reported among the peri or postmenopausal age group.[1] We are describing the clinicopathological features of a postmenopausal lady who presented with a mature cystic teratoma with malignant transformation of squamous tissue and was treated surgically.

Case Report:-

A multiparous lady in her fifties presented with symptoms of dull aching pain over whole abdomen for 6 months and distension of abdomen with a palpable lump in right lower abdomen for one month and loss of appetite of one month. She had attained premature menopause in her forties. The patient was frail and had BMI of 18 while her Eastern Cooperative Oncology Group (ECOG) performance score was 2.

There were no associated clinical features of anemia, jaundice or cardiac or respiratory disease. On abdominal examination there was a globular firm, tender mass of approximate size 8×6 cm extending from right iliac fossa to just adjacent to midline, the surface was smooth with bosselation, well-defined borders with restricted mobility and fullness in the right flank. There was no organomegaly. Per speculum examination was unremarkable and on pelvic examination the same mass was palpable through the right vaginal fornix bimanually.

Contrast enhanced CT scan of abdomen and pelvis showed that there was a large well defined, heterogeneous, predominantly fat lesion with dystrophic calcification seen involving pelvic cavity measuring anterior to uterus approx. 11×11 cm (Figure 1). Suggestive of teratoma. CA-125 was 66.85 u/ml.CEA 17.28ng/ml. LDH 112 U/L. CA19.9 220U/ML.S.AFP 1.42 iu/ml. Thus, with the given results of investigations and clinical information, teratoma was suspected and the patient was deemed operable.

Corresponding Author:-Ila Tiwari

Exploratory laparotomy revealed a heterogenous, vascular mass of 8 by 10 cm arising from right ovary with the infracolicomentum adhered to it with normal left ovary and bilateral fallopian tubes (Figure1). It was associated with 250 ml of ascitic fluid. The rest of the peritoneal cavity was normal on inspection and palpation. The para-aortic and pelvic lymph nodes were not enlarged on exploration and were sampled. The ovarian mass along with the fallopian tube was excised and subjected to frozen section biopsy, that showed malignant transformation of squamous tissue component.

A pan hysterectomy was then performed. Histopathological examination revealed: On gross examination 13.5x12.5x8.5 cm right ovarian mass, outer surface bosselated and irregular on cut surface pultaceous material emanated, predominantly grey white solid areas with few cystic areas 5.8 x 4.6 x 3.5 cm. Hair were also seen embedded within solid areas of necrosis. Omentum of size 27 x5cm was seen attached to the right ovarian mass.

The fallopian tubes, uterus and cervix and left ovary were unremarkable. Microscopic examination: sections from right ovarian mass showed necrosis along with tumour cells dispersed in cords and nests with keratin pearl formation. High grade nucleo-cytoplasmic ratio, hyperchromatic nuclei, inconspicuous nucleoli and moderate amount of cytoplasm.

Sections from solid areas also showed fibroadipose tissue and cystic cavity lined by single layer of cuboidal epithelium. No immature component or other germ cell tumour suggestive of mature cystic teratoma with malignant transformation, squamous cell carcinoma. (Figure 2) The disease was staged as TNM 1A.

The patient completed 11 months of follow-up uneventfully. This was done with CA125 and by imaging using sonography, PET CECT and clinical examination.

Discussion:-

Malignant transformation is commonly observed in the postmenopausal age around an average age of 55 years, the most common malignant transformation occurs to squamous cell carcinoma.[2] It has been reported that about 1% to 2% of mature cystic teratoma of ovary (MCTO) transform into malignant forms. This transformation begins from the dermoid plug. Since the malignant transformation is rare and resembles the appearance of the benign form, it is challenging to make a preoperative diagnosis.

Gadducci et. Al. Described that it may be difficult to distinguish between squamous cell carcinoma (SCC) in germ cell tumours based on tissue morphology. Immunostaining of epithelial markers, such as CK10 and CK18 are useful in the pathological diagnosis of SCC.[1] This was not necessary in our patient since the squamous tissue was readily discernible on histopathology.

Hackethal et al in their meta-analysis describe that most women with mature cystic teratoma and squamous cell carcinoma are above 50 years of age, postmenopausal and present with a raised CA125 level and tumours above 10 centimetres.[3] This corroborates with the clinical findings in our patient.

Management methods of this disease are varied, with no guidelines, given the rare nature of disease. Most patients diagnosed with SCC-MCTO underwent surgical treatments and adjuvant chemotherapy subsequently, depending on stage. It is reported that radiotherapy has no established role. In postmenopausal women, total debulking surgery including hysterectomy, bilateral adnexectomy and comprehensive staging are the mainstay of treatment. Adjuvant chemotherapy is considered in advanced stages, usually with alkylating agents.[3]

Although molecular profiling and IHC was not necessary in this patient since it was confined to ovary, in a cohort of 13 patients ovarian squamous cell carcinoma arising in mature cystic teratoma, the molecular inversion probe (MIP) array analysis and targeted sequencing of 275 cancer susceptibility genes, showed TP53 gene mutation as the commonest mutation followed by PIK3CA(36%), PTEN(27%) and KMT2D(27%), while mutations in CDKN2A and copy number loss of 9p21.3 were observed in 51%.[4] In another series of 6 cases PDL1 expression of median 41% and mutations in homologous recombination repair pathway genes (BLM, ATM, BRCA1, BRIP1 and ATM) were found in 5/6 patients. [5]

The IHC for p63, cytokeratin (CK) 5/6, PAX8 and CK34bE12 markers is used to diagnose squamous carcinoma of ovarian origin.[6] A retrospective survival analysis of 222 cases ascertained tumour stage and optimal debulking as critical to survival and better responsiveness to chemotherapy, unlike squamous carcinoma of the cervix.[7] Other forms of epithelial tissue tumour transformations seen in mature cystic teratoma are carcinoids and mucinous

cystadenoma.[8]Conclusion: Mature cystic teratomas are rare in the elderly women although they may occur in some patients and this case highlights the importance of the awareness of the possibility of a malignant transformation in a mature teratoma when presenting in menopausal women.

Learning Points

- Squamous transformation in a mature cystic teratoma occurs in postmenopausal women presenting with large mass and raised CA125.
- Surgery is ad
- Equa
- te treatment for SCC-MCTO in early stage.

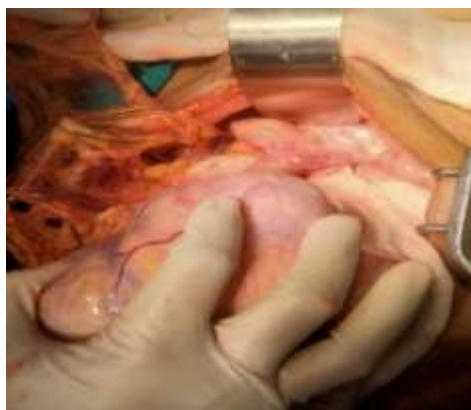


Fig 1: Right sided ovarian mass along with omental adhesion.

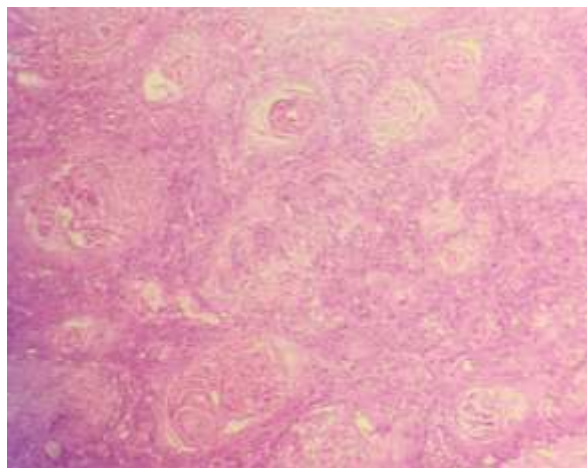


Figure 2: h & e 400 x magnification: nests and islands of atypical squamous cells with keratin pearl formation.

References:-

1. Gadducci a, guerrieri me, cosio s. Squamous cell carcinoma arising from mature cystic teratoma of the ovary: a challenging question for gynecologic oncologists. Crit rev oncolhematol. 2019 jan;133:92-98. Doi: 10.1016/j.critrevonc.2018.10.005. Epub 2018 nov 2. Pmid: 30661663.
2. Rim sy, kimsn, choi hs. Malignant transformation of ovarian mature cystic teratoma. International j gynecol cancer 2006;16: 140-4
3. Hackethal a, brueggmann d, bohlmannmk, frankefe, tinneberghr, münstedt k. Squamous-cell carcinoma in mature cystic teratoma of the ovary: systematic review and analysis of published data. Lancet oncol. 2008 dec;9(12):1173-80. Doi: 10.1016/s1470-2045(08)70306-1. Erratum in: lancet oncol. 2009 may;10(5):446. Pmid: 19038764.
4. Chao a, lai ch, chao as, lin cy, wang yc, huanghj, wurc. Molecular characterization of ovarian squamous cell carcinoma originating from mature teratoma. J mol med (berl). 2025 jan;103(1):101-111. Doi: 10.1007/s00109-024-02505-w. Epub 2024 dec 4. Pmid: 39630279.
5. Liang y, ruan h, yu m, lü b. Ovarian squamous cell carcinoma associated with teratoma: a report of six cases with genomic analysis. Pathology. 2023 dec;55(7):966-973. Doi: 10.1016/j.pathol.2023.08.001. Epub 2023 sep 6. Pmid: 37739924.
6. Margioulas-siarkou c, almpierica, almpieris a, margioulas-siarkou g, titilas g, dinas k, petousis s. Squamous cell carcinoma of the ovary: a rare case. Cureus. 2024 nov 26;16(11):e74547. Doi: 10.7759/cureus.74547. Pmid: 39735155; pmcid: pmc11671788.
7. Chen rj, chenky, chang tc, sheubc, chow sn, huang sc. Prognosis and treatment of squamous cell carcinoma from a mature cystic teratoma of the ovary. J formos med assoc. 2008 nov;107(11):857-68. Doi: 10.1016/s0929-6646(08)60202-8. Pmid: 18971155.
8. Jafari-nozad am, jahani n, moniri y. Mucinous cystadenoma and carcinoid tumor arising from an ovarian mature cystic teratoma in a 60 year-old patient: a case report. J med case rep. 2024 jun 25;18(1):290. Doi: 10.1186/s13256-024-04603-2. Pmid: 38915051; pmcid: pmc11197182.