



RESEARCH ARTICLE

PARADOXICAL REACTION ON HIV- NEGATIVE SPINAL TUBERCULOUS ARACHNOIDITIS PATIENT: A CASE REPORT

Benaddi Mina¹, Benksim Abdelhafid², Fatihi Touria³ and Sabour Alaoui Sanaa¹

1. Polyvalent Research and Development Team, Polydisciplinary Faculty, University of Sultan Moulay Sliman Beni Mellal, Morocco.

2. Regional Health Directorate, Higher Institute of Nursing Professions and Health Techniques (ISPITS-M), Nursing Care Department, Marrakech 40000, Morocco.

3. Department of Infectious Diseases, Regional Hospital of Beni Mellal, Morocco.

Manuscript Info

Manuscript History

Received: 07 July 2025

Final Accepted: 09 August 2025

Published: September 2025

Key words:-

paradoxical reaction-tuberculous meningitis- spinal arachnoiditis.

Abstract

Introduction:- Tuberculosis is a major public health issue in our country. Central nervous system tuberculosis has severe life threatening sequelae. The diagnosis of this form of tuberculosis is still challenging. Thus, availability of data about symptoms, paths of treatment, and eventual outcomes could be beneficial for practitioners. Hence, we are reporting a case of paradoxical response on patient with tuberculous meningitis (TBM) complicated with spinal arachnoiditis.

Case Presentation:- We report a case of a 26 yearsold HIV- negative man, admitted on juaunary the 28 th with headache, fever syndrome, ptosis, behavioral, neurological and sphincter disorders. Medullary Magnetic Resonance Imaging (MRI) showed extensive cervical-dorsal-lumbar epiduritis with nodular epiduritis posterior to L1, besides a radiculitis extended cauda equina syndrome and cervical-medullary cystic dilatation at D2 and L1 suggestive as arachnoiditis. Treatment was lunched with regimen including four main drugs: isoniazid, rifampin, pyrazinamide, and ethambutol. After two months, the patient showed a paradoxical reaction. Adjuvant treatment was given to consolidate first line treatment. The patient state got improved and was discharged with a scheduled follow-up visit.

Conclusion:- During the treatment of TBM, a paradoxical reaction can occur at any time. Quick diagnosis, appropriate treatment, and constant reevaluation of care protocols may reduce the likelihood of complications and sequelae.

"© 2025 by the Author(s). Published by IJAR under CC BY 4.0. Unrestricted use allowed with credit to the author."

Introduction:-

Tuberculosis is a major public health issue in Morocco. Indeed, in 2022 World Health Organization (WHO) estimated nearly 35,000 new tuberculosis infections, from which extra-pulmonary tuberculosis (EPT) constitutes 49%, and 3,300 tuberculosis-related deaths in the country (1). The EPT diagnosis is challenging, as it is not easily confirmed bacteriologically.(2). Central nervous system tuberculosis (CNS-TB) is a severe type of EPT, and it

Corresponding Author:- Benaddi Mina

Address:- Polyvalent Research and Development Team Polydisciplinary Faculty, University of Sultan Moulay Sliman Beni Mellal, Morocco.

accounts for 1%-2% of TB cases worldwide(3). This form of Tuberculosis, even though uncommon, has serious life-threatening consequences. Spinal arachnoiditis (radiculomyelitis), as a form of CNS TB, is rarely reported even in countries where CNS TB is common. Uncommonly, a patient, who got better with anti-tuberculosis treatment, may present a paradoxical reaction. A paradoxical reaction (PR) is a worsening of tuberculosis lesions or the appearance of a new lesion in patients who first improved with treatment.(4)

We report a case of PR in a young immunocompetent male with tuberculous meningitis (TBM) complicated with spinal arachnoiditis, hospitalized in the infectious diseases department in the regional hospital of Beni Mellal city, Morocco.

CASE REPORT :-

We report a case of a 26 years old young Moroccan man admitted on January the 28th 2025 with headache and fever syndrome for about two weeks, in the infectious diseases department in the regional hospital of Beni Mellal city, Morocco. The young man also suffered from a ptosis, behavioral, neurological and sphincter disorders. Clinical examination reveals a stiff neck, lumbar puncture revealed a lymphocyte dominated hyperloco cytosis, and biological workup revealed a high white cells count ($26.10^3/\mu\text{l}$) along with a high C-Reactive Protein (CRP) at 230 mg/l (Table 1).

The patient was, at first, diagnosed with Lymphocytic meningitis and treated with peripheral venous access, paracetamol, ceftriaxone, vomistop, and corticosteroid therapy. Otherwise, the young man presented a pyeloureteral junction syndrome (vesical globe even after probing) confirmed with abdominal ultrasound. A cytobacteriological examination of urine showed an abnormal Leucocyturia. The urologist examination, led to 10 days bladder probe, ciprofloxacin (sepcen) antibiotic therapy, and a scheduled cold surgery. On the eighth day of treatment, comportemental, neurological and sphincter disorders still persisted.

Radiculomyelitis tuberculosis was suspected and antibacillary treatment was started. Indeed, ERIP K4, which is a regimen including four main drugs: isoniazid (I), rifampin (R), pyrazinamide (P), and ethambutol (E), along with ciprofloxacin, solumedrol, and novex has been started on February the third 2025, along with additional paraclinical examinations. Rapid test of HIV has been performed and been negative. Cerebral computed tomography (CT) scan showed dilated ventricles with hydrocephalus, while abdominal and pelvic CT scan showed no particularities. Cerebral Magnetic Resonance Imaging (MRI) showed minimal tetra ventricular hydrocephalus without transependymal resorption syndrome, with exaggerated meningeal enhancement and tensional syndrome.

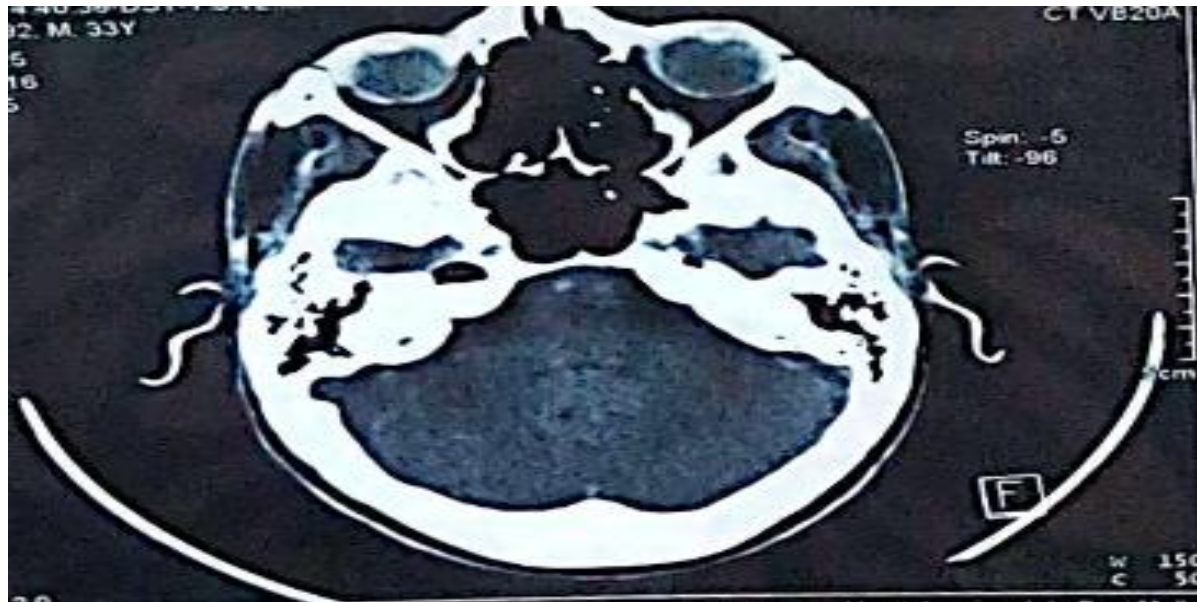
Medullary MRI showed extensive cervical-dorsal-lumbar epiduritis with nodular epiduritis posterior to L1, besides a radiculitis extended cauda equina syndrome and cervical-medullary cystic dilatation at D2 and L1 suggestive as arachnoiditis. The MRI objective a syringomyelitis without vestibular collection or infiltration. Tuberculous meningo radiculitis complicated by intracranial hypertension syndrome was confirmed. (Figure 1) At day twelve of bacillary treatment the patient situation got stabilized on the biological and clinical order. Hence, the patient was discharged with scheduled follow up visit in February the 17th 2025.

April the fourth, the young man was readmitted in the infectious diseases department for presenting paradoxical reaction (PR) to antibacillary treatment. Indeed, the patient was presenting sphincter disorders, left ptosis and lower limb paralysis. Cerebral CT scan showed a moderate dilatation of the ventricular system with midline in place and moderate hydrocephalus. The ophthalmologist examination reported a normal fundus. Day eight of treatment the, Follow-up CT scan shows moderate hydrocephalus with regression of intracranial hypertension syndrome. Biological work up revealed a notable increase in white cells count ($17,20.10^3$), CRP (170 mg/l), and gamma GT (130 U/l) after their significant decrease at the end of the first admission which support the PR state.

Corticosteroid therapy along with the established antibacillary treatment was relaunched (solumedrol 120 mg 2 times a day). Besides, Proton Pump Inhibitors (PPI), paracetamol, and adjuvant treatment was set up to control symptoms and consolidate first-line treatment. The twelfth day of treatment, as the patient showed a good clinical and biological outcome, the Solumedrol dose was reduced from 120 mg to 80 mg two times a day. On April the 17th, 2025, the patient resumed micturition with persistent diplopia. The 22 April, the clinical examination revealed no signs of neurological worsening, Abdominal and testicular ultrasound showed an epididymitis orchis. Hence, the patient has benefited from double J probe and antibiotic therapy (triaxon and ciproxine). The 25th April, the patient was discharged as he has improved clinically (could stand and walk with stick, resumption of sphincter and neurological disorders despite the persistence of diplopia), and a follow-up visit was scheduled in two weeks' time.

Table 1: Evolution of patient biological indicators from the first admission and the second one

Date	28\01\2025	17\2\2025	18\04\2025
CRP	230mg/l	61,3mg/l	170.10mg/l
Leucocytes	26. 10 ³ \ μl	7,16. 10 ³ \ μl	17.20.10 ³ \ μl
Uricemia	1.07g/l	0,35g/l	0.12 g/l
Creatinine	69mg/l	7,25mg/l	5.69 g/l

**FIGURE1:** CT scan showed a minimal tetra ventricular hydrocephalus without transependymal resorption syndrome, with exaggerated meningeal enhancement and tensional syndrome.**Discussion :-**

CNS TB is an uncommon but highly devastating form of tuberculosis. Several risk factors for CNS tuberculosis have been identified. Mostly, children and HIV-coinfected patients (5). The immune reaction and inflammatory process can affect the spine leading to spinal arachnoiditis. On MRI, the affection is characterized by CSF localization, subarachnoid space obliteration in the spine, and thickened and lumpy nerve roots in the lumbar region (6). Our patient had shown symptoms of radiculomyelitis.

MRI revealed active tuberculous meningo-radicularitis. The comportemental disorders, fever, and sphincter disorders decreased after anti-TB medication and corticosteroid therapy. However, he was readmitted for clinical and biological worsening. The abnormal evolution is suggestive of "paradoxical reaction" (PR) which refers to observation of clinical or radiological worsening of previous TB lesions or development of new lesions after at least one month of TB treatment in a patient who initially responded to anti-TB therapy (7). The mechanism of PR is still poorly understood.

However, PR manifestations may result from a patient's exaggerated immune response to dead and dying bacteria (8). Adjunctive corticosteroid therapy was used in the management of PR in our case. Indeed, there is a paper supporting the use of that steroid therapy as it improves survival in patients with tuberculous meningitis without evidence on preventing disabilities (9) (4). Our patient developed PR though adjunctive steroid therapy from the outset of anti-TB medication treatment. Thus, in our case we witness the likelihood of severe complications and sequelae of CNS TB besides PR in immunocompetent persons which is obviously uncommon. Hence, the diagnosis should be made and initiate anti-TB medication and corticosteroid therapy accordingly, as quick as possible. Further advancement in early detection and diagnosis of CNS TB is valuable for physicians in clinical practice. To conclude, both methods for detection of CNS TB diagnosis procedures and treatment protocols should be evaluated constantly in order to reduce the burden of neurological sequelae.

References :-

1. Plan stratégique National TB 2024-2030.pdf. (s. d.). Consulté 18 mai 2025, à l'adresse <https://www.sante.gov.ma/Documents/2023/11/Plan%20strate%C3%ACgique%20National%20TB%202024-2030.pdf>
2. Version Finale Lignes Directrices TEP PNLAT Version finale Août 2023.pdf. (s. d.). Consulté 17 mai 2025, à l'adresse <https://www.sante.gov.ma/Documents/2024/04/VersioFinale202023.pdf>
3. TB du système nerveux central (SNC). (s. d.). Normes canadiennes pour la lutte antituberculeuse. Consulté 17 mai 2025, à l'adresse [https://manuals.cts.sct.ca/documentation/chapitre 7 la tuberculose extrapulmonaire/3 tableaux-cliniques-selon-lorgane-atteint/3-5-tb-du-systeme-nerveux-central-snc/?lang=fr](https://manuals.cts.sct.ca/documentation/chapitre%207%20la%20tuberculose%20extrapulmonaire/3%20tableaux-cliniques-selon-lorgane-atteint/3-5-tb-du-systeme-nerveux-central-snc/?lang=fr)
4. Garg, R. K., Malhotra, H. S., & Kumar, N. (2014). Paradoxical reaction in HIV negative tuberculous meningitis. *Journal of the Neurological Sciences*, 340(1), 26-36. <https://doi.org/10.1016/j.jns.2014.03.025>
5. Rock, R. B., Olin, M., Baker, C. A., Molitor, T. W., & Peterson, P. K. (2008). Central nervous system tuberculosis : Pathogenesis and clinical aspects. *Clinical Microbiology Reviews*, 21(2), 243-261, table of contents. <https://doi.org/10.1128/CMR.00042-07>
6. Bernaerts, A., Vanhoenacker, F. M., Parizel, P. M., Van Goethem, J. W. M., Van Altena, R., Laridon, A., De Roeck, J., Coeman, V., & De Schepper, A. M. (2003). Tuberculosis of the central nervous system : Overview of neuroradiological findings. *European Radiology*, 13(8), 1876-1890. <https://doi.org/10.1007/s00330-002-1608-7>
7. Carvalho, A. C. C., De Iaco, G., Saleri, N., Pini, A., Capone, S., Manfrin, M., & Matteelli, A. (2006). Paradoxical reaction during tuberculosis treatment in HIV-seronegative patients. *Clinical Infectious Diseases: An Official Publication of the Infectious Diseases Society of America*, 42(6), 893-895. <https://doi.org/10.1086/500459>
8. Liu, Y., Wang, Z., Yao, G., Lu, Y., Hu, Z., Yao, H., Zhang, Q., Zhu, H., Song, Z., Wang, W., & Liu, D. (2019). Paradoxical reaction in HIV-negative tuberculous meningitis patients with spinal involvement. *International Journal of Infectious Diseases*, 79, 104-108. <https://doi.org/10.1016/j.ijid.2018.11.366>
9. Thwaites, G. E., Nguyen, D. B., Nguyen, H. D., Hoang, T. Q., Do, T. T. O., Nguyen, T. C. T., Nguyen, Q. H., Nguyen, T. T., Nguyen, N. H., Nguyen, T. N. L., Nguyen, N. L., Nguyen, H. D., Vu, N. T., Cao, H. H., Tran, T. H. C., Pham, P. M., Nguyen, T. D., Stepniewska, K., White, N. J., ... Farrar, J. J. (2004). Dexamethasone for the treatment of tuberculous meningitis in adolescents and adults. *The New England Journal of Medicine*, 351(17), 1741-1751. <https://doi.org/10.1056/NEJMoa040573>