

| | | |
|---|--|--|
|  <p>ISSN NO. 2320-5407</p> | <p>Journal Homepage: - www.journalijar.com</p> <p>INTERNATIONAL JOURNAL OF ADVANCED RESEARCH (IJAR)</p> <p>Article DOI: 10.21474/IJAR01/21742 DOI URL: http://dx.doi.org/10.21474/IJAR01/21742</p> |  <p>INTERNATIONAL JOURNAL OF ADVANCED RESEARCH (IJAR) ISSN 2320-5407 Journal Homepage: http://www.journalijar.com Article DOI: 10.21474/IJAR01/21742</p> |
|---|--|--|

RESEARCH ARTICLE

FATAL MISDIAGNOSIS OF ISOLATED CERVICAFACIAL MYELOID SARCOMA IN A YOUNG ADULT: CASE REPORT

Hanine Mohamed Amine¹, Atmani Walid² and Haddou Ammar¹

1. ENT Departement , Hassan II Military Teaching Hospital , Laayoune , Morocco.

2. Anesthesiology and intensive care Unit, Hassan II Military Teaching Hospital , Laayoune ,Morocco.

Manuscript Info

Manuscript History

Received: 09 July 2025

Final Accepted: 11 August 2025

Published: September 2025

Key words:-

Cervicofacial , myeloid sarcoma , leukemia , fatal prognosis

Abstract

Introduction: Myeloid sarcoma is a rare extramedullary manifestation of acute myeloid leukemia. Its isolated cervicofacial presentation is exceptional and often misdiagnosed.

Case Presentation: We report a case of a 19-year-old male with no significant medical history presenting with a rapidly growing cervicofacial mass initially treated as a dental abscess. Despite multiple dental interventions, there was no improvement. Histopathological examination of a biopsy specimen revealed myeloid sarcoma. Unfortunately, due to financial constraints and delayed hematological management, the patient died before initiation of chemotherapy.

Discussion: This case underscores the diagnostic challenge posed by atypical head and neck presentations of hematological malignancies. Immediate biopsy and immunophenotyping are essential. Socioeconomic barriers can have fatal consequences in such aggressive neoplasms.

Conclusion: Awareness of rare manifestations of hematological diseases is essential for early diagnosis and timely intervention.

"© 2025 by the Author(s). Published by IJAR under CC BY 4.0. Unrestricted use allowed with credit to the author."

Introduction:-

Myeloid sarcoma (MS), also known as granulocytic sarcoma or chloroma, is a rare extramedullary tumor composed of immature myeloid cells [1]. It is most commonly associated with acute myeloid leukemia (AML), either concomitantly, during relapse, or as a harbinger of disease [2]. Isolated MS without marrow involvement is rare and may present a diagnostic dilemma, particularly in unusual locations such as the head and neck region [3].

We report a rare and fatal case of isolated cervicofacial myeloid sarcoma in a young adult, initially misdiagnosed as a dental abscess, illustrating the critical importance of early recognition and intervention.

CASE REPORT:

A 19-year-old male with no prior medical history presented to the Otolaryngology Department of the Military Hospital of Laayoune, Morocco, with a painful, progressively enlarging cervicofacial mass evolving over one month. The patient initially sought dental care and was treated empirically for a presumed dental abscess without improvement.

Corresponding Author:- Hanine Mohamed Amine

Address:- ENT Departement ,Hassan II MilitaryTeachingHospital , Laayoune , Morocco.

On examination, there was a firm, tender, and diffusely swollen mass predominantly involving the left cheek, extending to the periorbital region, causing complete occlusion of the left eye. Intraoral examination revealed a large, necrotic, whitish mass involving the upper vestibule and hard palate.

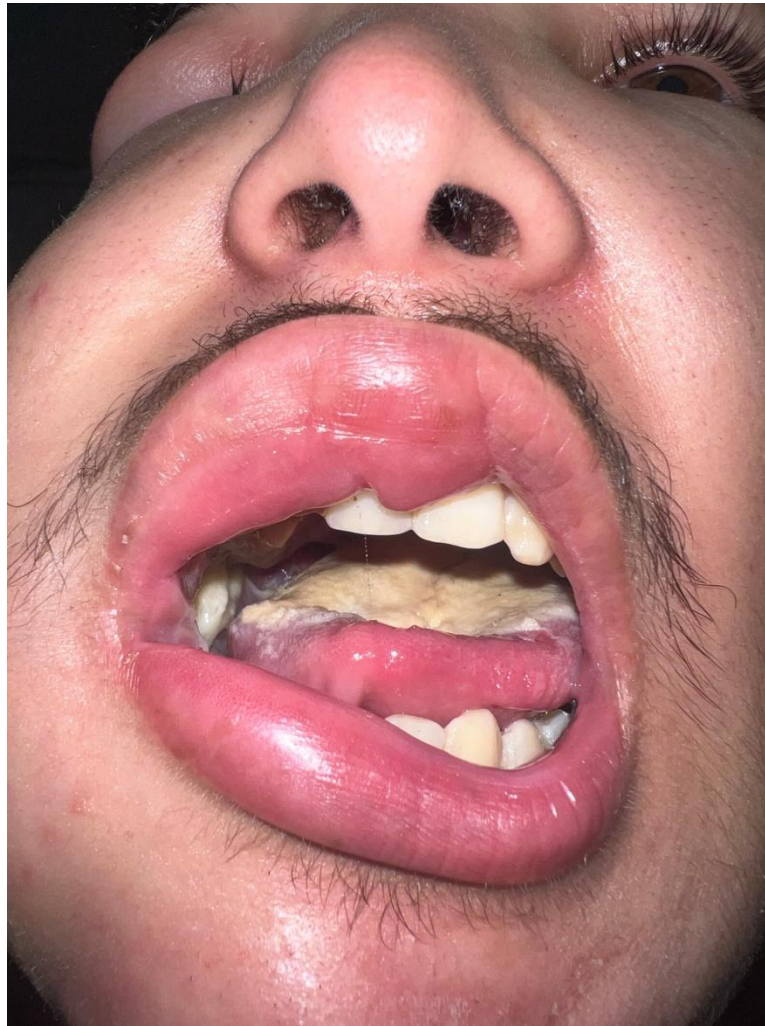


Figure 1: Extensive intraoral infiltration involving the upper vestibule and hard palate, covered by a necrotic pseudomembrane.

The patient's general condition was deteriorated with marked asthenia and weight loss. Laboratory tests showed mild anemia but no blasts on peripheral blood smear. A biopsy was performed under local anesthesia. Histopathological examination revealed a dense infiltrate of medium-sized blastic cells with irregular nuclei. Immunohistochemistry was positive for myeloperoxidase (MPO), CD33, and CD117, confirming the diagnosis of myeloid sarcoma.

The patient was referred urgently to the Hematology Department for systemic chemotherapy. Unfortunately, due to lack of medical insurance and financial resources, the initiation of therapy was delayed, and the patient succumbed to his disease within two weeks after diagnosis.

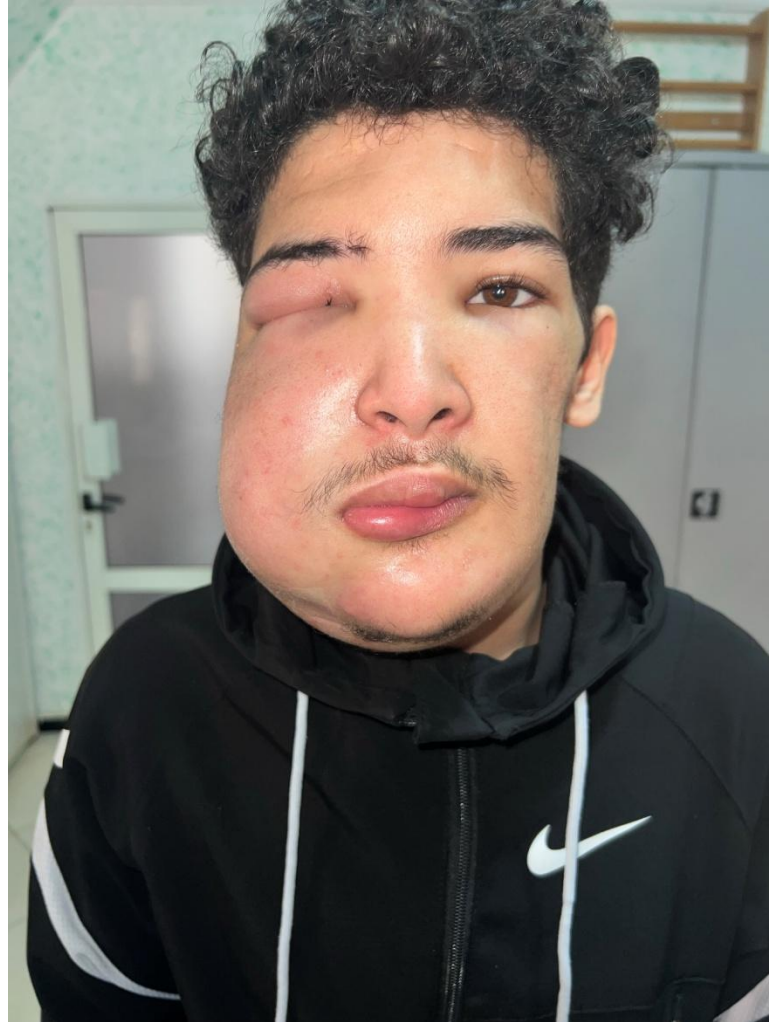

Figure 2: Frontal view demonstrating severe cervicofacial swelling causing facial asymmetry and complete closure of the left eye due to tumor infiltration.

DISCUSSION:-

Myeloid sarcoma is an uncommon entity, representing about 2–8% of cases of acute myeloid leukemia [4]. It may occur at any site, but involvement of the head and neck region is rare, accounting for approximately 12–24% of cases [5]. In isolated MS, where bone marrow is initially unaffected, diagnosis becomes particularly challenging and is often delayed.

The differential diagnosis in cervicofacial swellings typically includes odontogenic infections, benign tumors, lymphomas, sarcomas, and metastatic lesions [6]. As in our patient, misdiagnosis as a dental abscess is common, especially when oral symptoms predominate.

Histological evaluation is essential but often inconclusive without immunohistochemistry. Markers such as MPO, CD68, CD33, and CD117 are critical for distinguishing MS from lymphoid malignancies and other small round blue cell tumors [7].

The prognosis of isolated MS is poor if systemic AML-type chemotherapy is not promptly initiated. Delayed treatment often leads to rapid progression to overt AML, with median survival less than 8 months in untreated patients [8]. Early systemic chemotherapy improves survival dramatically and may delay or prevent leukemic transformation [9].

Socioeconomic factors, as tragically highlighted in our case, play a major role in outcomes. Limited access to healthcare, delayed diagnosis, and inability to initiate timely chemotherapy contribute significantly to mortality, especially in resource-limited settings [10].

This case emphasizes the importance of maintaining a high index of suspicion for malignancy in atypical cervicofacial lesions, particularly when initial therapy fails. Biopsy and immunohistochemical analysis must be performed without delay.

CONCLUSION:-

Isolated cervicofacial myeloid sarcoma is an extremely rare and aggressive disease, prone to misdiagnosis. Early identification and initiation of AML-type chemotherapy are essential to improve prognosis. In developing countries, enhancing access to specialized care remains a critical need to prevent avoidable deaths.

Conflit of interest :

NONE

Funding declaration :

NO Funding

Ethics :

Ethical conditions are approved

CLINICAL TRIAL NUMBER :

Not applicable

Consent to publish declaration :

Not applicable

THE WORK WAS REPORTED IN ACCORDANCE WITH THE SCARE GUIDELINES

During the preparation of this work the author used HANINE MOHAMED AMINE / ENT in order to VERIFY THE QUALITY OF WORK. After using this tool, the author reviewed and edited the content as needed and takes full responsibility for the content of the publication

REFERENCES:-

1. Pileri SA, Ascani S, Cox MC, et al. Myeloid sarcoma: Clinico-pathologic, phenotypic and cytogenetic analysis of 92 adult patients. *Leukemia* 2007;21(2):340–350.
2. Avni B, Koren-Michowitz M. Myeloid sarcoma: current approach and therapeutic options. *Ther Adv Hematol* 2011;2(5):309–316.
3. Tsimberidou AM, Kantarjian HM, Estey E, et al. Outcome in patients with nonleukemic granulocytic sarcoma treated with chemotherapy with or without radiotherapy. *Leukemia* 2003;17(6):1100–1103.
4. Neiman RS, Barcos M, Berard C, et al. Granulocytic sarcoma: a clinicopathologic study of 61 biopsied cases. *Cancer* 1981;48(6):1426–1437.
5. Paydas S, Zorludemir S, Ergin M. Granulocytic sarcoma: 32 cases and review of the literature. *Leuk Lymphoma* 2006;47(12):2527–2541.
6. Audouin J, Comperat E, Le Tourneau A, Camilleri-Broet S, Molina T. Myeloid sarcoma: Clinical and morphologic features of 16 cases treated at a single institution. *Ann Pathol* 2003;23(6):376–380.
7. Bakst RL, Tallman MS, Douer D, Yahalom J. How I treat extramedullary acute myeloid leukemia. *Blood* 2011;118(14):3785–3793.
8. Yamauchi K, Yasuda M. Comparison in treatments of nonleukemic granulocytic sarcoma: report of two cases and a review of 72 cases in the literature. *Cancer* 2002;94(6):1739–1746.
9. Antic D, Elezovic I, Milic N, et al. Is there a "gold" standard treatment for patients with isolated myeloid sarcoma? *Biomed Pharmacother* 2013;67(1):72–77.
10. Velez JCQ, Petroianu A, deFaria Andrade FJ, et al. Disparities in cancer outcomes in low- and middle-income countries: A call for equity. *Lancet Oncol* 2021;22(4):451–452.