



RESEARCH ARTICLE

FACIAL PALSY IN ASOM : AN UNCOMMON PRESENTATION

Dhanashree Brahmanandan, Vinod Gite and Ninad Gaikwad

Manuscript Info

Manuscript History

Received: 09 July 2025

Final Accepted: 11 August 2025

Published: September 2025

Key words:-

Acute Suppurative Otitis Media (ASOM); Facial Nerve Palsy; Pediatric; Myringotomy; Grommet Insertion; Adenoid Hypertrophy; Tympanostomy Tubes; Otitis Media with Effusion (OME).

Abstract

Introduction: Acute Suppurative Otitis Media (ASOM) is a common childhood infection. However, complication with facial nerve palsy is a rare but significant occurrence, representing a medical urgency. This case report details the presentation, management, and outcome of a 5-year-old male with ASOM-associated facial palsy.

Case Report: A previously healthy 5-year-old male presented with acute-onset left-sided facial weakness. History revealed a preceding upper respiratory tract infection with cough, cold, and fever. Otoscopic examination confirmed left ASOM and right serous otitis media (OME). Initial conservative management with antibiotics and analgesics yielded no improvement in facial nerve function. The child subsequently underwent bilateral myringotomy with insertion of a grommet on the left side. Intraoperative diagnostic nasal endoscopy revealed Grade 4 adenoid hypertrophy. Significant improvement in facial palsy was noted by the fifth postoperative day. Three months later, the patient successfully underwent elective adenoidectomy (Tonsillectomy and Adenoidectomy - TAR) to address the underlying pathology and prevent recurrence.

Discussion: Facial palsy in ASOM is believed to result from direct inflammation and neuropraxia of the dehiscence tympanic segment of the facial nerve or via congenital bony defects. Timely surgical intervention with myringotomy and ventilation tube insertion is the cornerstone of management, providing immediate decompression and drainage. The presence of significant adenoid hypertrophy is a known risk factor for recurrent otitis media, and its removal is often indicated to ensure long-term resolution.

Conclusion: Although rare, facial palsy is a serious complication of ASOM. A high index of suspicion and prompt otologic evaluation are crucial. Early surgical myringotomy with grommet insertion leads to excellent recovery of facial function. Evaluation and management of predisposing factors, such as adenoid hypertrophy, are essential for definitive treatment.

"© 2025 by the Author(s). Published by IJAR under CC BY 4.0. Unrestricted use allowed with credit to the author."

Introduction:-

Acute Suppurative Otitis Media (ASOM) is one of the most frequently diagnosed infections in pediatric populations, characterized by the rapid onset of signs and symptoms of inflammation in the middle ear. While most cases resolve uneventfully with appropriate medical management, intratemporal and intracranial complications, though rare in the post-antibiotic era, still occur.

Facial nerve palsy is an uncommon but alarming complication of ASOM, with an estimated incidence of 0.005% to 0.001% [1]. The pathophysiology typically involves direct inflammation of the facial nerve within its bony canal in the middle ear. The nerve is most vulnerable in its tympanic segment, where the bony covering may be dehiscant in a significant portion of the population, particularly children [2]. The inflammatory mediators and bacterial toxins from the middle ear infection can cause neuropraxia, leading to the acute onset of unilateral facial weakness.

This case report presents the clinical course of a 5-year-old child who developed facial palsy secondary to ASOM. It highlights the importance of a systematic diagnostic approach, the limitations of conservative management, the critical role of timely surgical intervention, and the necessity of addressing underlying predisposing factors like adenoid hypertrophy to prevent recurrence.

Case Report

A 5-year-old male child, previously healthy and fully immunized, was brought to the ENT OPD with a chief complaint of acute-onset drooping of the left side of the face and inability to fully close the left eye, which had developed over the previous 24 hours (Figure 1)

The history revealed a prodrome of cough, cold, and mild fever for four days. The parents also reported the child complaining of left ear pain, which had since subsided. There was no history of head trauma, rash, recent vaccination, or previous similar episodes.

On examination, the child was afebrile and alert. A gross left-sided lower motor neuron type facial palsy (House-Brackmann Grade IV) was evident, with inability to frown, incomplete eye closure, loss of nasolabial fold, and asymmetry of the mouth on crying. Otoloscopic examination revealed a bulging, erythematous, and opaque right tympanic membrane consistent with ASOM. The right tympanic membrane was dull and amber-colored with an air-fluid level, suggestive of otitis media with effusion (OME). A pure tone audiometry was attempted but was unreliable due to the child's age and cooperation.

A provisional diagnosis of left ASOM with secondary facial palsy and right OME was made. The child was started on a course of oral broad-spectrum antibiotics (Amoxicillin-clavulanate), oral nasal decongestants, and analgesic/anti-inflammatory medication. Lubricating eye drops and advice for eye patching at night were given to protect the cornea.

After 72 hours of conservative treatment, there was no improvement in the facial palsy. The otoscopic findings persisted. Consequently, a decision was made for surgical intervention. The child was taken to the operating theatre for an examination under microscopy and myringotomy.

Intraoperatively, a left myringotomy was performed, which released purulent material (Figure 2). A ventilation tube (grommet) was inserted (Figure 3). A right myringotomy was also performed, which drained serous fluid; however, a grommet was not inserted on this side at this time (Figure 4). Diagnostic nasal endoscopy (DNE) performed during the same anesthesia session revealed significant Grade 4 adenoid hypertrophy (obstructing >95% of the choanal opening) (Figure 5)

The postoperative course was uneventful. The child was continued on antibiotic ear drops and oral antibiotics. Remarkably, on the fifth postoperative day, a significant improvement in facial symmetry and movement was observed (improving to House-Brackmann Grade II) (Figure 6). The child was discharged with advice for regular follow-up.

Three months later, after complete resolution of the acute infection and facial palsy, the child underwent an elective Tonsillectomy and Adenoidectomy (TAR) to eliminate the source of chronic upper airway obstruction and Eustachian tube dysfunction, thereby preventing future episodes of otitis media.



Figure 1 Left Facial Palsy

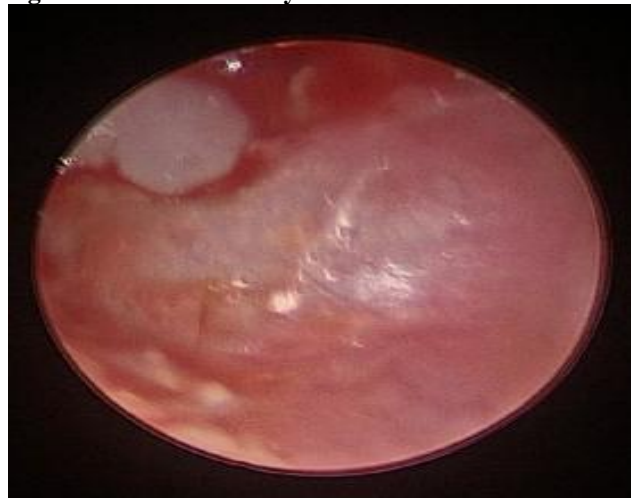


Figure 2 Pus discharge from Left side on myringotomy

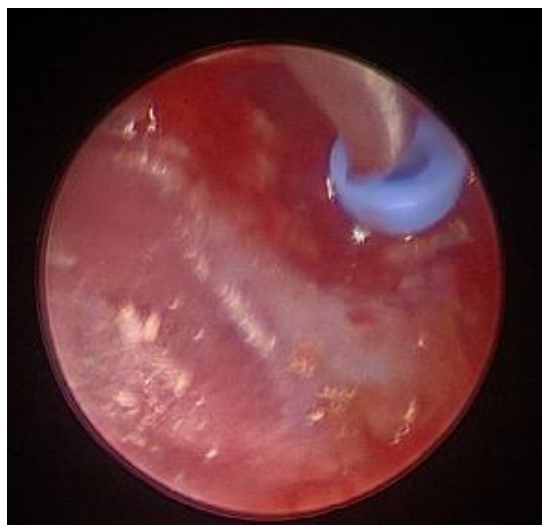


Figure 3 Grommet inserted in Left Tympanic Membrane

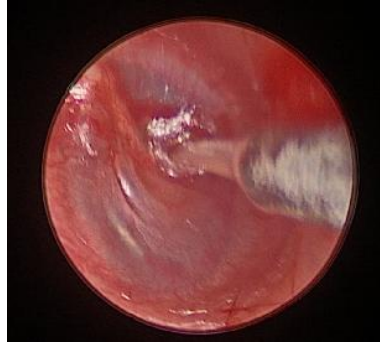


Figure 4 Serous fluid suctioned from Right middle ear after myringotomy

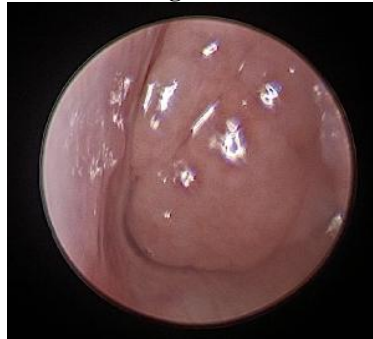


Figure 5 Grade 4 adenoid hypertrophy on DNE



Figure 6 Post operative improvement in Facial weakness

Discussion:-

This case exemplifies a rare but serious complication of a common pediatric condition. The development of facial palsy in a child with ASOM signifies a failure of medical management to control the infectious and inflammatory process, necessitating prompt escalation to surgical intervention.

The pathogenesis of facial palsy in ASOM is primarily attributed to the anatomic proximity of the facial nerve to the middle ear. The tympanic segment of the nerve courses just above the oval window and stapes. Congenital dehiscences in the bony Fallopian canal are present in up to 25-55% of the population, most commonly in this segment [3]. In our case, the inflammatory edema and bacterial toxins from the suppurative infection in the right middle ear likely traversed a dehiscence bony canal, causing neuropraxia of the facial nerve without permanent axonal degeneration.

The initial conservative management with antibiotics and anti-inflammatories is a standard first step. However, the lack of improvement within 72 hours indicated that drainage of the purulent collection was imperative to decompress the nerve. Myringotomy with grommet insertion achieves two critical goals: 1) it allows for culture and drainage of the infected material, immediately relieving pressure within the middle ear, and 2) it facilitates the topical delivery of medications and ensures continued aeration, preventing re-accumulation [4]. The dramatic

improvement on postoperative day 5 supports the theory of a pressure-induced or inflammatory neuropraxia that reverses upon removal of the inciting factor.

The finding of Grade 4 adenoid hypertrophy is a key element in this case. Adenoid hypertrophy is a well-established cause of Eustachian tube dysfunction, leading to impaired middle ear ventilation and the development of both ASOM and OME [5]. By addressing this underlying pathology with adenoidectomy (as part of TAR) after the acute infection had resolved, the surgical team aimed to break the cycle of recurrent otitis media and prevent future complications.

This case underscores a critical management algorithm: in ASOM complicated by facial palsy, prompt surgical myringotomy with ventilation tube insertion is the treatment of choice if there is no immediate improvement with medical therapy. Furthermore, a complete otolaryngologic evaluation, including nasal endoscopy to assess the adenoid, is essential for comprehensive management and prevention of recurrence.

References:-

- [1] Kitsko, D. J., and Dohar, J. E. (2007). Management of pediatric facial nerve paralysis. *Current Opinion in Otolaryngology and Head and Neck Surgery*, 15(6), 450–455.
- [2] Moreano, E. H., Paparella, M. M., Zelterman, D., and Goycoolea, M. V. (1994). Prevalence of facial canal dehiscence and of persistent stapedial artery in the human middle ear: a report of 1000 temporal bones. *The Laryngoscope*, 104(3 Pt 1), 309–320.
- [3] Takahashi, H., and Sando, I. (1992). Facial canal dehiscence: histologic study and computer reconstruction. *The Annals of Otology, Rhinology, and Laryngology*, 101(11), 925–930.
- [4] Pang, K. P., and de Ribaupierre, S. (2002). Facial nerve palsy secondary to acute otitis media. *The Journal of Laryngology and Otology*, 116(11), 944–946.
- [5] Torretta, S., Marchisio, P., and Pignataro, L. (2017). The role of adenoidectomy in the treatment of paediatric otitis media with effusion. *Acta Otorhinolaryngologica Italica*, 37(2), 113–117.