



Journal Homepage: [-www.journalijar.com](http://www.journalijar.com)

INTERNATIONAL JOURNAL OF ADVANCED RESEARCH (IJAR)

Article DOI:10.21474/IJAR01/21761

DOI URL: <http://dx.doi.org/10.21474/IJAR01/21761>



RESEARCH ARTICLE

VERY HIGH PROSTATE SPECIFIC ANTIGEN IN AN ASYMPTOMATIC PATIENT LEADING TO DIAGNOSING METASTATIC PROSTATE CANCER IN A PRIMARY HEALTH CARE CENTER IN JEDDAH, SAUDI ARABIA

Omar Banamah, Mohammed Mohammed, Mohammed Kutbi, Bakur A. Turkstani, Bader Alallah and
Ammar K. Mandili

Manuscript Info

Manuscript History

Received: 11 July 2025

Final Accepted: 13 August 2025

Published: September 2025

Abstract

Prostate-specific antigen (PSA) is a glycoprotein secreted by both normal and malignant prostate epithelial cells, and its measurement in serum has become a cornerstone in the screening, diagnosis, and monitoring of prostate cancer (PCa) (1). Elevated PSA levels are commonly associated with prostate malignancy, but they may also result from benign conditions such as benign prostatic hyperplasia (BPH), prostatitis, urinary tract infection, or even recent ejaculation or prostate manipulation (2,3). A serum PSA level above 4.0 ng/mL traditionally raises concern for the presence of prostate cancer, although levels between 4.0 and 10.0 ng/mL fall into a "gray zone" where specificity and sensitivity are limited (4). PSA levels greater than 10 ng/mL are generally associated with a significantly increased likelihood of prostate cancer (5). However, PSA levels in the extremely high range (above 100 ng/mL) are unusual and typically suggest advanced or metastatic disease (6). In some cases, extreme PSA elevation has been reported in the absence of confirmed malignancy, raising questions about potential diagnostic pitfalls and the necessity for thorough clinical evaluation (7).

"© 2025 by the Author(s). Published by IJAR under CC BY 4.0. Unrestricted use allowed with credit to the author."

Introduction:-

Prostate-specific antigen (PSA) is a glycoprotein secreted by both normal and malignant prostate epithelial cells, and its measurement in serum has become a cornerstone in the screening, diagnosis, and monitoring of prostate cancer (PCa) (1). Elevated PSA levels are commonly associated with prostate malignancy, but they may also result from benign conditions such as benign prostatic hyperplasia (BPH), prostatitis, urinary tract infection, or even recent ejaculation or prostate manipulation (2,3). A serum PSA level above 4.0 ng/mL traditionally raises concern for the presence of prostate cancer, although levels between 4.0 and 10.0 ng/mL fall into a "gray zone" where specificity and sensitivity are limited (4). PSA levels greater than 10 ng/mL are generally associated with a significantly increased likelihood of prostate cancer (5). However, PSA levels in the extremely high range (above 100 ng/mL) are unusual and typically suggest advanced or metastatic disease (6). In some cases, extreme PSA elevation has been reported in the absence of confirmed malignancy, raising questions about potential diagnostic pitfalls and the necessity for thorough clinical evaluation (7).

Several case reports in the literature describe unusually high PSA levels without confirmed prostate cancer. For example, Patel et al. reported a case where a patient presented with a PSA level exceeding 1,000 ng/mL, but histopathology revealed no malignancy and instead showed florid granulomatous prostatitis (8). Another report by Kim et al. highlighted a case of a 68-year-old male with a PSA of 546 ng/mL, later found to have high-grade prostatitis but no evidence of carcinoma on biopsy (9). These cases underline the importance of a comprehensive diagnostic workup that includes clinical history, digital rectal examination (DRE), imaging, and prostate biopsy before concluding the presence of malignancy.

Moreover, PSA kinetics, such as PSA velocity (the rate of change over time) and PSA doubling time, may aid in distinguishing between benign and malignant causes of PSA elevation (10). However, their clinical utility remains controversial, especially in cases of extremely high PSA levels without other supporting evidence of cancer (11).

Given these complexities, our case report details a patient with an unusually elevated PSA level, exploring the differential diagnosis, diagnostic challenges, and management decisions. We aim to contribute to the growing body of literature that highlights the importance of careful interpretation of PSA values and to advocate for evidence-based approaches to prevent overtreatment or misdiagnosis.

Case Presentation:

This is a case of a 68-year-old male who is known to have Type 2 Diabetes Mellitus, Hypertension, and Bronchial Asthma, who is a non-smoker. He presented to the Primary Health Care (PHC) clinic in March 2021, requesting a general routine laboratory workup. At that visit, he did not complain of any symptoms, and the general systemic review questions were all negative, including those related to lower urinary tract symptoms.

His daughter then returned in April 2021 for a follow-up, requesting the lab results. All results were reassuring, except for an extremely elevated level of Prostate-Specific Antigen (PSA), which was 211.66 ng/mL (reference range: ~ 4 ng/mL). At that time, PSA level was ordered as a screening method for Prostate Cancer, even though the patient did not show any symptoms of it or have any family history of any type of malignancy.

After seeing this PSA level result, an immediate referral to the Urology Surgery department was made. He was then seen by Urology Surgery, and they ordered an abdomen and pelvis CT for him and referred him to the Medical Oncology department. Abdomen and pelvis CT showed the prostate to be enlarged and measured 4.9 x 4.4 x 3.2 cm with an estimated volume of 35.8 ml and demonstrated heterogeneous enhancement. The left external iliac lymph node group measures 1.5 cm in diameter. Dysmorphic features of the liver were seen. Also, diffuse bone metastasis was seen. Dysmorphic features of the liver were then correlated with a positive Hepatitis B virus serology in cirrhosis.

His later visit to the Medical Oncology clinic resulted in the decision to take an extra-rectal prostate biopsy. Biopsy results showed Prostatic Acinar Carcinoma. The patient was then started on chemotherapy and went through multiple cycles, including:

- * Abiraterone with Prednisolone and Androgen Deprivation Therapy in March 2021
- * Six cycles of Docetaxel on the 24th of May 2023
- * Enzalutamide on the 11th of July 2023
- * Five cycles of Cabazitaxel on the 7th of April 2024

All these cycles resulted in minimal improvement of the patient's general condition and were then labeled as Castration-resistant Prostate Cancer with bone and lymph nodes metastasis.

During the treatment for his disease, monitoring for Prostate Cancer was done by measuring PSA levels, as shown in Figures 1 and 2, which are the trends for PSA and Free PSA (FPSA) readings, respectively.

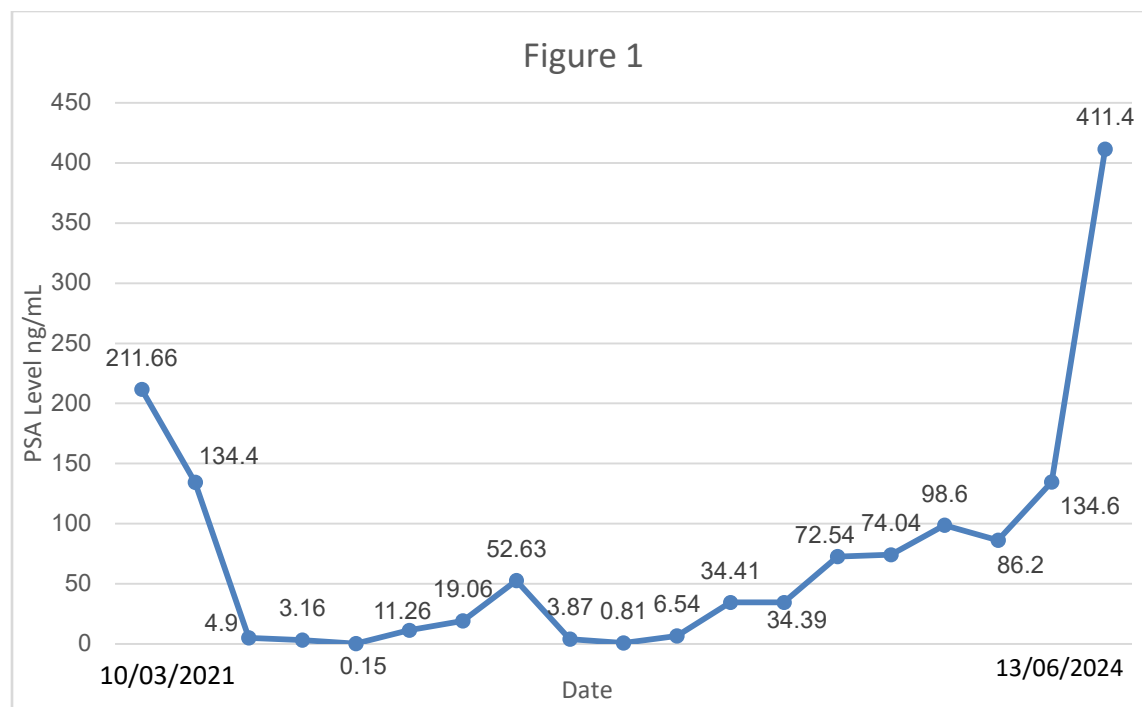


Figure 1: Trend of PSA levels throughout the years shown in ng/mL. First and last levels where the most significant showing extreme elevations from reference range: ~ 4 ng/mL. PSA: Prostate Specific Antigen

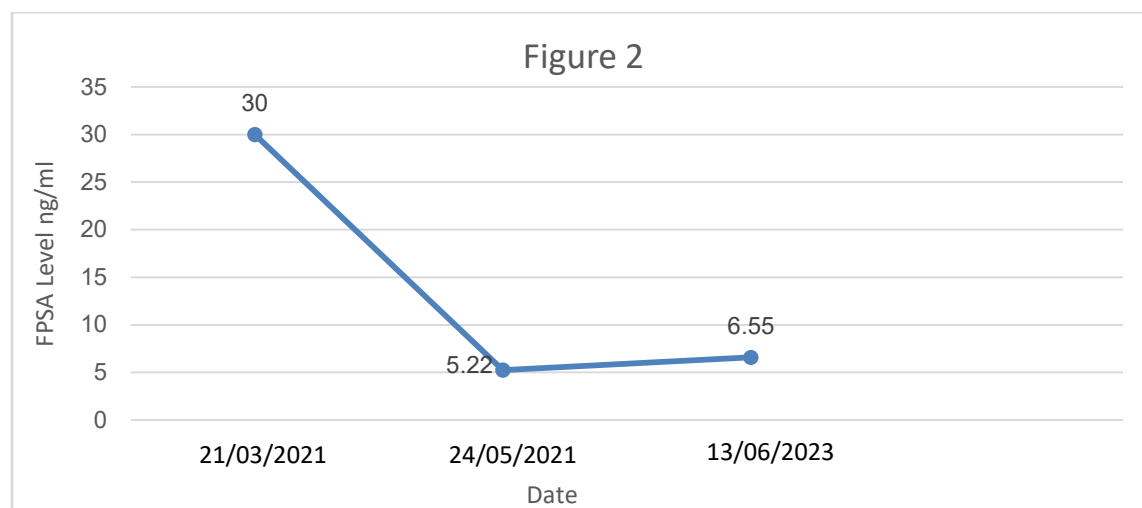


Figure 2: Trend of FPSA levels throughout the years shown in ng/mL. FPSA: Free Prostate Specific Antigen

The patient was then transferred to Palliative Care due to poor response and general decline of his health condition due to progression of the primary disease.

He was then admitted for the first time to the Palliative Care ward and stayed there for about one month with no improvement in his health condition. On the 9th of July 2024, the patient was found non-responsive with no pulse, no audible heartbeat, blood pressure undetectable, and pupils fixed and dilated; his death was announced then.

Discussion:-

Prostate-specific antigen (PSA) testing plays a central role in the detection, monitoring, and management of prostate cancer. PSA is a serine protease produced by both normal and malignant prostate epithelial cells. While it is not specific to prostate cancer, its elevation often prompts further diagnostic evaluation. The sensitivity of PSA testing for prostate cancer ranges from 70% to 80%, while specificity is lower, approximately 60%, due to elevations seen in benign prostatic hyperplasia, prostatitis, and other non-malignant conditions (12,2).

Despite its limitations, PSA remains the cornerstone of the initial prostate cancer workup. Elevated PSA levels in asymptomatic individuals often lead to the detection of early-stage prostate cancer. However, this benefit must be weighed against the potential for overdiagnosis and overtreatment of indolent tumors. Data from large trials such as the European Randomized Study of Screening for Prostate Cancer (ERSPC) showed a relative reduction in prostate cancer mortality of about 20% among men undergoing regular PSA screening (13). Guidelines regarding PSA screening vary. The U.S. Preventive Services Task Force (USPSTF) recommends that men aged 55 to 69 years engage in shared decision-making with their clinicians about PSA-based screening (14).

The American Urological Association (AUA) advises similar individualized decision-making for men in the same age range, while discouraging routine screening in men over 70 or those with less than 10-15 years of life expectancy (15). Meanwhile, the National Comprehensive Cancer Network (NCCN) provides risk-stratified screening protocols based on family history, race, and age (16).

In this case, PSA testing—though not part of routine screening—contributed to the incidental diagnosis of metastatic prostate cancer. This highlights the dual nature of PSA: while not a perfect test, it remains a valuable biomarker in clinical practice when interpreted within context. Elevated PSA, especially in conjunction with clinical symptoms or abnormal digital rectal examination (DRE), warrants further investigation with imaging and histopathological confirmation.

Castration-resistant prostate cancer (CRPC) with metastasis remains a significant challenge in the management of advanced prostate cancer. The incidental diagnosis of metastatic CRPC, as seen in our patient, underscores the complexity and heterogeneity of this disease. Despite ongoing efforts to implement evidence-based screening protocols, incidental findings continue to occur, often revealing advanced disease at the time of initial presentation.

CRPC is defined by disease progression despite androgen deprivation therapy (ADT), with castrate levels of testosterone (<50 ng/dL) (16). Once prostate cancer progresses to the castration-resistant stage, it typically demonstrates a more aggressive course and a higher likelihood of metastasis, commonly to bone and lymph nodes (17). Our patient exhibited metastatic lesions in both sites, reflecting the typical pattern of dissemination.

The management of metastatic CRPC has evolved significantly over the past decade. Therapeutic options now include androgen receptor signaling inhibitors (such as abiraterone and enzalutamide), taxane-based chemotherapy (docetaxel and cabazitaxel), radiopharmaceuticals (radium-223 for bone metastases), and novel agents targeting DNA repair pathways (e.g., PARP inhibitors in BRCA-mutated cases) (18, 19). Treatment selection must consider disease burden, symptomatology, performance status, prior therapies, and molecular characteristics of the tumor (20).

Bone metastases are present in approximately 90% of men with advanced CRPC and are associated with significant morbidity, including skeletal-related events (SREs) (21). In this context, bone-modifying agents such as zoledronic acid and denosumab are recommended to reduce the risk of SREs (22). Our patient was initiated on bisphosphonate therapy as part of supportive care.

Although PSA screening for prostate cancer remains controversial due to concerns about overdiagnosis and overtreatment, some data suggest potential mortality benefits in appropriately selected populations (23). However, leading guidelines such as those from the US Preventive Services Task Force (USPSTF) recommend individualized decision-making regarding PSA testing, especially in men aged 55–69 years (24). This case highlights that incidental PSA testing, while not routinely recommended, can uncover advanced disease in asymptomatic individuals.

Genomic profiling is gaining increasing importance in the management of metastatic CRPC, particularly for identifying actionable mutations. Recent data support the use of next-generation sequencing to guide personalized therapy, including PARP inhibitors for patients with homologous recombination repair gene mutations (24). While our patient's molecular analysis is pending, future treatment will be guided by these findings.

In conclusion, this case emphasizes the importance of maintaining a high index of suspicion in patients with nonspecific symptoms and highlights the multifaceted approach required for managing metastatic CRPC. Ongoing research into biomarkers, novel therapies, and optimal sequencing of treatments continues to shape the evolving landscape of prostate cancer care.

Conclusion:-

This case highlights the diagnostic complexity of markedly elevated PSA levels in an asymptomatic patient and the necessity of a thorough clinical evaluation. The incidental discovery of metastatic castration resistant prostate cancer (CRPC) in this patient highlights both the potential utility and limitations of PSA testing. Incorporating PSA assessment into primary healthcare settings, guided by risk factors and clinical suspicion, can facilitate the earlier detection of significant pathology. This report reinforces the need for Individualized screening strategies, careful interpretation of PSA values, and clinical vigilance in both specialized and primary care contexts.

References:-

1. Wang MC, Valenzuela LA, Murphy GP, Chu TM. Purification of a human prostate-specific antigen. **Invest Urol**. 1979;17(2):159–163.
2. Oesterling JE. Prostate-specific antigen: a critical assessment of the most useful tumor marker for adenocarcinoma of the prostate. **J Urol**. 1991;145(5):907–923.
3. Nadler RB, Humphrey PA, Smith DS, Catalona WJ, Ratliff TL. Effect of inflammation and benign prostatic hyperplasia on elevated serum prostate specific antigen levels. **J Urol**. 1995;154(2 Pt 1):407–413.
4. Catalona WJ, Smith DS, Ratliff TL, et al. Measurement of prostate-specific antigen in serum as a screening test for prostate cancer. **N Engl J Med**. 1991;324(17):1156–1161.
5. Thompson IM, Pauler DK, Goodman PJ, et al. Prevalence of prostate cancer among men with a prostate-specific antigen level ≤ 4.0 ng per milliliter. **N Engl J Med**. 2004;350(22):2239–2246.
6. Ross AE, Loeb S, Landis P, et al. Prostate-specific antigen kinetics during follow-up are an unreliable trigger for intervention in a prostate cancer surveillance program. **J Clin Oncol**. 2010;28(17):2810–2816.
7. Morgan WR, Zincke H, Blute ML. Elevated serum prostate-specific antigen levels: causes and management. **Mayo Clin Proc**. 1993;68(3):297–301.
8. Patel AR, Jones JS, Babineau D, et al. Granulomatous prostatitis mimicking carcinoma: MRI and histological correlation. **Can J Urol**. 2008;15(3):4076–4079.
9. Kim SH, Kim SH, Joung JY, et al. Extremely elevated serum PSA without prostate cancer: a case report and literature review. **World J Surg Oncol**. 2013;11:251.
10. D'Amico AV, Chen MH, Roehl KA, Catalona WJ. Preoperative PSA velocity and the risk of death from prostate cancer after radical prostatectomy. **N Engl J Med**. 2004;351(2):125–135.
11. Vickers AJ, Savage CJ, O'Brien MF, Lilja H. Systematic review of pretreatment prostate-specific antigen velocity and doubling time as predictors for prostate cancer. **J Clin Oncol**. 2009;27(3):398–403.
12. Thompson IM, et al. Operating characteristics of prostate-specific antigen in men with an initial PSA level of 3.0 ng/mL or lower. *JAMA*. 2005.
13. Schröder FH, et al. Screening and prostate-cancer mortality in a randomized European study. *N Engl J Med*. 2009.
14. US Preventive Services Task Force. Screening for Prostate Cancer: US Preventive Services Task Force Recommendation Statement. *JAMA*. 2018.
15. Carter HB, et al. Early detection of prostate cancer: AUA guideline. *J Urol*. 2013.

16. Mohler JL, et al. Prostate cancer, version 2.2019, NCCN Clinical Practice Guidelines in Oncology. J Natl ComprCancNetw. 2019.
17. Kirby M, et al. Characterising the castration-resistant prostate cancer population: a systematic review. Int J ClinPract. 2011.
18. Fizazi K, et al. Abiraterone acetate for metastatic prostate cancer without previous chemotherapy. N Engl J Med. 2013.
19. de Bono J, et al. Olaparib for metastatic castration-resistant prostate cancer. N Engl J Med. 2020.
20. Cornford P, et al. EAU-EANM-ESTRO-ESUR-SIOG Guidelines on Prostate Cancer. Eur Urol. 2023.
21. Roodman GD. Mechanisms of bone metastasis. N Engl J Med. 2004.
22. Saad F, et al. Zoledronic acid and skeletal complications in patients with metastatic prostate cancer. J Natl Cancer Inst. 2002.
23. Schröder FH, et al. Screening and prostate-cancer mortality in a randomized European study. N Engl J Med. 2009.
24. Mateo J, et al. DNA-repair defects and olaparib in metastatic prostate cancer. N Engl J Med. 2015.