



## CASE REPORT

# CRITICAL ROLE OF CHEST TUBE DRAINAGE AS THE INITIAL TREATMENT FOR KLEBSIELLA PNEUMONIAE-RELATED PYOPNEUMOTHORAX: A CHALLENGING CASE REPORT FROM MOHAMMAD NOER GENERAL HOSPITAL, PAMEKASAN

Abdi Malik Rahardjo<sup>1</sup>, Muhammad Fauzi Lufthansyahrizal<sup>2</sup>, Mokhammad Mukhlis<sup>3</sup> and Swiandini Kumala<sup>4</sup>

1. Internship Doctor, Mohammad Noer General Hospital, Pamekasan, East Java, Indonesia.
2. Internship Doctor, Aisyiyah Islamic General Hospital, Nganjuk, East Java, Indonesia.
3. Department of Pulmonology and Respiratory Medicine, Mohammad Noer General Hospital, Pamekasan, East Java, Indonesia
4. Department of Microbiology Clinic, Mohammad Noer General Hospital, Pamekasan, East Java, Indonesia.

## Manuscript Info

### Manuscript History

Received: 19 July 2025

Final Accepted: 21 August 2025

Published: September 2025

### Keywords:-

chest tube, initial treatment, pyopneumothorax, klebsiella pneumoniae.

## Abstract

**Introduction:**Pyopneumothorax caused by Klebsiella pneumoniae infection is a clinically rare event, and few cases have been reported. Chest tube drainage insertion is crucial due to potentially large and prolonged air leaks, and increased risk of morbidity and mortality.

**Case presentation:** An Indonesian male, 40 years old with underlying diabetes mellitus who presented with 1 month of progressively worsening shortness of breath (SOB), chest discomfort, cough, nausea and fever. The patient appears weak, dyspnea, blood pressure (BP) of 120/80 mmHg, heart rate (HR) of 161 bpm, respiratory rate (RR) of 32 x/min, oxygen saturation (SpO<sub>2</sub>) of 84% room air. On inspection and fremitus, the development of left lung expansion was delayed. Percussion sound of left lung was dull on the first day hospitalization but reverse to hypersonor on the fifth day of hospitalization and rhonchi of the right lung on auscultation. Laboratory examination showed leukocyte was elevated to 18.040/Cmm. A chest X-ray on the first day hospitalization revealed pneumonia of dextra lung and pleural effusion of left hemithorax. On the day fifth of hospitalization, chest X-ray revealed pneumothorax sinistra. A culture of the sputum and pleural effusion grew Klebsiella pneumoniae. The patient underwent needle thoracocentesis with chest tube drainage and antibiotic therapy for 7 days. The patient had improved but a few days later developed a pneumothorax sinistra. Based on persistence of fever and not restoring lung expansion, the patient referred to another hospital that had better facilities.

"© 2025 by the Author(s). Published by IJAR under CC BY 4.0. Unrestricted use allowed with credit to the author."

**Corresponding Author:-**Abdi Malik Rahardjo

**Address:-**Internship Doctor, Mohammad Noer General Hospital, Pamekasan, East Java, Indonesia.

**Discussion:** *Klebsiella pneumoniae* may progress to empyema thoracis following an infection with antibiotic-resistant organism or associated with comorbid conditions (malignancy and diabetes mellitus). Pyopneumothorax can be managed by prompt initiation of antibiotic therapy, pus drainage, and restoring lung expansion. Patients who do not respond to tube drainage and antibiotic medications indicate a need for surgical intervention.

**Conclusion:** To the best of our knowledge, this is the first case of chest tube drainage as the initial treatment for pyopneumothorax due to *Klebsiella pneumoniae* infection that showed only temporary improvement but less poor prognosis.

### **Introduction:-**

Pyopneumothorax is serious complications of thoracic infection that are associated with significant morbidity and mortality. Based on previous studies, it was found that *Klebsiella pneumoniae* infection had a significantly higher mortality rate than that for the patients without *Klebsiella pneumoniae* infection, which estimated incidence of isolation of Gram-negative bacteria from the pleural fluid to be about 84% were immunocompromised hosts, especially those with diabetes mellitus and malignancy as well as history of upper digestive system surgery, alcohol drinking habit, and a smoking habit. The mortality of which was reported to be 32.4% (12 of 37 patients) within hospitalization (Chen et al., 2000; Lin, et al., 2010). Major chest infections due to *Klebsiella* spp. include pneumonia, lung abscess, and empyema (Ishiguro et al., 2020). In the United States, approximately 65,000 cases of empyema occur annually, with a mortality rate of 15% and a health cost burden of approximately 500 million dollars per year (Semenkovich et al., 2018). In Nigeria, although specific prevalence rates for empyema are not given, pleural effusions are generally found in about 400 per 100,000 population (Nwagboso et al., 2022). In the US, about 1 million patients are hospitalized with pneumonia annually and 20%-40% of them are associated with pleural cavity infection (Santoshi et al., 2022).

Empyema is a type of complicated parapneumonic effusion characterized by the presence of frank pus in the pleural cavity or a positive Gram stain or culture. Pneumothorax, characterized by the presence of air in the pleural cavity, can be classified as spontaneous and traumatic. Spontaneous pneumothorax can in turn be primary or PSP (occurring without any apparent underlying lung disease) and secondary or SSP (associated with pre-existing lung pathology). Pyopneumothorax caused by *Klebsiella pneumoniae* infection is a clinically rare event, and case reporting was limited. Previous studies highlight, the most common causes of secondary spontaneous pneumothorax (SSP) are chronic obstructive pulmonary disease (COPD), cystic fibrosis, lung malignancy, and infections. These conditions compromise alveolar integrity, leading to air leakage into the pleural space (Sorino et al., 2024). These two conditions that occur at the same time are considered to be a challenge in determining the next therapeutic steps.

According to the American Thoracic Society, the process of empyema thoracis (ET) consists of three stages: (1) the exudative phase (acute or stage I), when exudate fluid begins to accumulate in the pleural cavity without loculation; (2) the fibrinopurulent phase (stage II), characterized by pleural fluid that becomes cloudy or purulent and loculation begins to form; and (3) the organizational phase (chronic or stage III), when pus thickens or a fibrin layer forms, accompanied by the growth of granulation tissue in the pleural cavity (Liu et al., 2025; Tantraworasin et al., 2018). Common symptoms include fever, chest pain, shortness of breath, and cough (Knebel et al., 2018; Magendiran et al., 2024). To confirm the diagnosis, supporting examinations such as chest X-ray, CT scan, and thoracic ultrasonography are performed. Analysis of pleural fluid from thoracentesis is also important, including tests for pH, glucose, LDH, and bacterial culture (Knebel et al., 2018; Kondov et al., 2017).

Treatment ranges from intravenous antibiotic, intercostal chest tube drainage (ICD), video-assisted thoracoscopic surgery (VATS) to thoracotomy decortication (TCD). Early initiation of intravenous antibiotics and ICD procedure promote smooth recovery and lung expansion in up to 86% of cases. ICD with intravenous antibiotics may fail to clear the pus in loculated empyema, bilateral empyema, thickened pleura, and chronic empyema with lung trapping. Failed cases should be investigated promptly for planning of surgical intervention. Thus, close monitoring of the responses to ICD procedure is essential in the management of empyema thoracis (Mandal et al., 2019). The effectiveness of chest tube drainage in empyema depends on several factors such as the size and location of the effusion, the viscosity of the pleural fluid and the presence of loculation. The use of a large-bore chest tube (LBCT) with 20-28 French is commonly used due to better drainage ability in thick purulent effusions, but the use of a small-bore catheter with 10-14 French is more popular due to its less invasive nature and comparable efficacy in certain scenarios (Hassan et al., 2021). In SSP, chest tube insertion is crucial due to potentially large and prolonged air

leaks, and the increased risk of morbidity and mortality. Success rates are lower compared to PSP due to the underlying lung pathology. Persistent air leaks are more common, and additional interventions such as surgery or chemical pleurodesis may be required (Mubarik et al., 2019; Sorino et al., 2024). Therapeutic drainage via chest tube is commonly required not only to relieve symptoms but also to obtain a sample for diagnostic analysis, which can guide further treatment. In some conditions when pleural effusion is recurrent, pleurodesis or decortication might be an option to reduce the risk of relapses (Sorino et al., 2024).

Chest tube drainage as initial treatment for pyopneumothorax due to klebsiella pneumoniae infection was limited and few cases have been reported, especially in tertiary hospitals with all their limitations. Here, we report a case of successful initial treatment of a patient with pyopneumothorax due to Klebsiella pneumoniae infection. This case contributes valuable information to the current knowledge on the treatment of this infectious disease.

Case Presentation:

A 40-year-old Indonesian Male experienced with 1 month of progressively worsening shortness of breath (SOB). Shortness of breath was ongoing, worsening, and unaffected by daily activities and/or mobilization. Shortness of breath accompanied by severe and piercing chest discomfort, particularly in hemithorax sinistra. The patient had been complaining of coughing with yellowish sputum for one month. He also experienced a fever of 38.3 degreeCelcius in the first to the seventh days. The fever tended to be felt throughout the day. Nausea was also prominent for the first three days of symptoms (Figure 1).

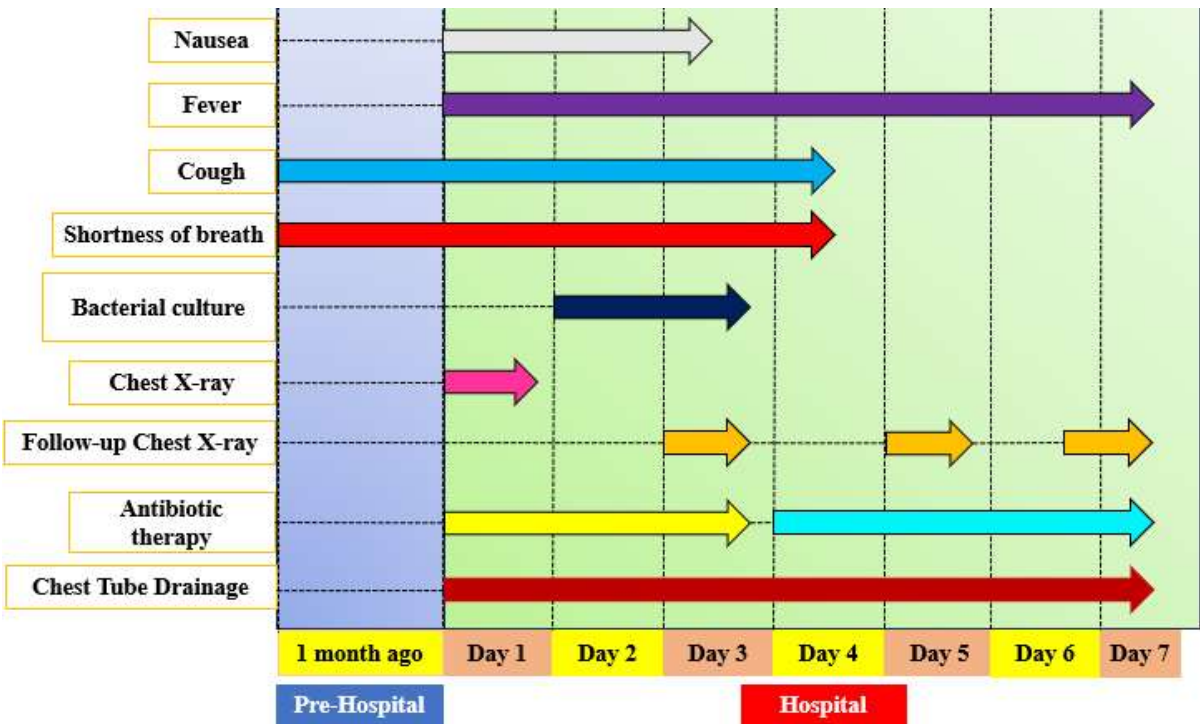
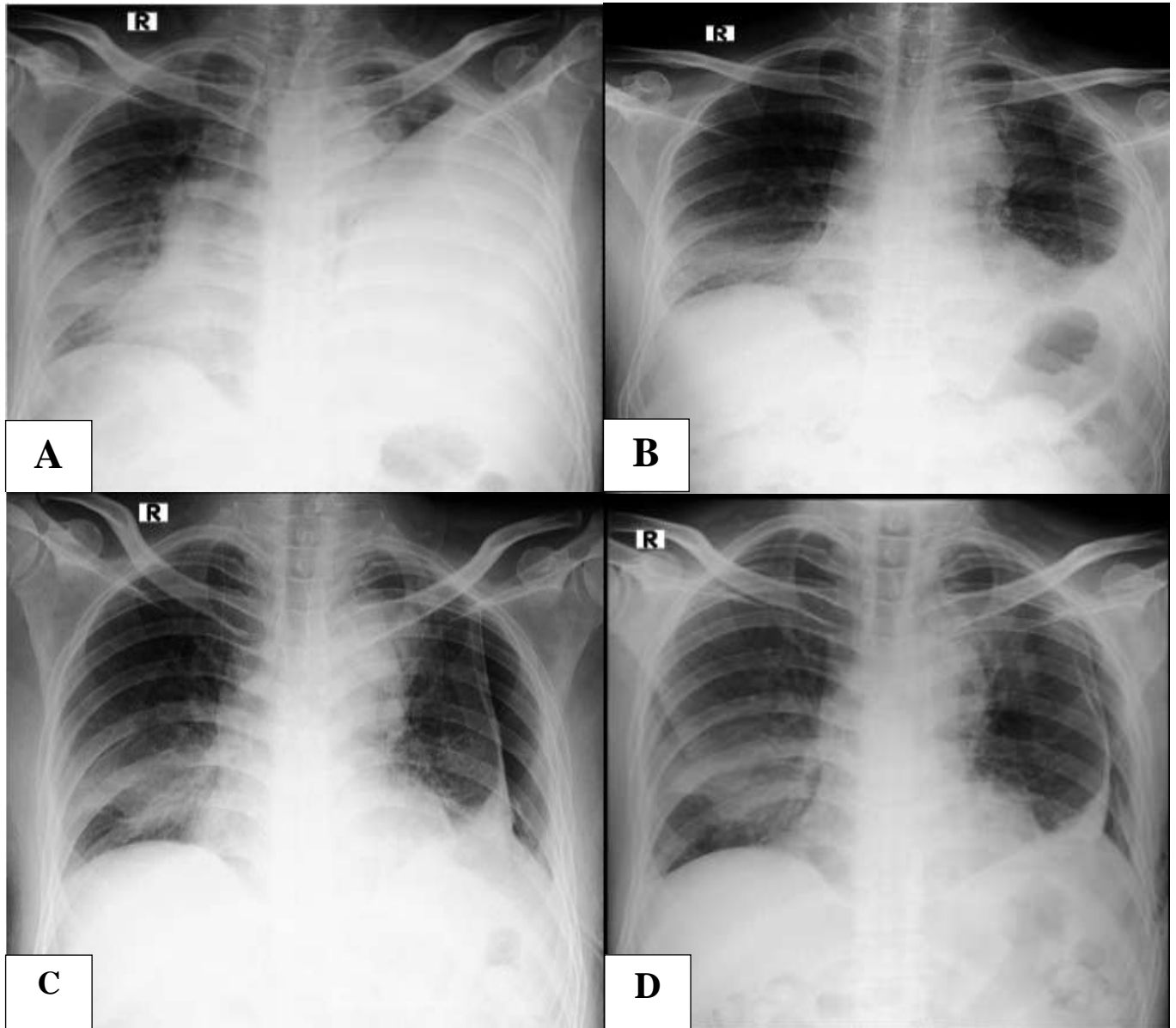


Figure 1. Onset, Duration of Symptoms, Follow-up Examination and Management of the Patient During the Follow-up Period of 7 Days.

9 months ago, the patient was diagnosed with empyema dextra by a pulmonologist doctor and got chest tube drainage and Metronidazole 3x500mg via infusion during admission at hospital. At that time, he refused to be referred to another hospital that had better facilities. The patient had a history of smoking 1 pack/day for 20 years ago and diabetes mellitus. The patient's general condition appeared to be weak and dyspnea, blood pressure was 120/80 mmHg, with a pulse rate of 161 bpm, respiratory rate (RR) was 32 x/min, oxygen saturation (SpO2) was 84% room air. The head and neck examination revealed dyspnea with nostril breathing. The thoracic inspection revealed lung expansion asymmetric, in which the left lung lags behind the right lung. When fremitus tactil is carried out, results that are similar to thoracic inspection are also obtained, namely lung expansion asymmetries. The

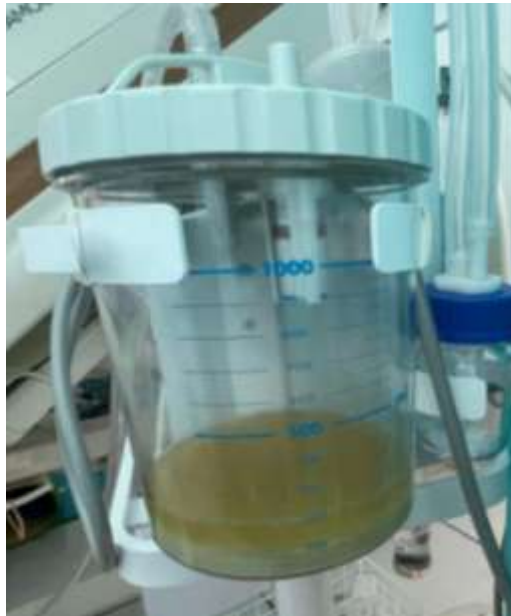result of percussion was dull and auscultation of slow vesicular sound and rhonchi were obtained on the right and left hemithorax. Other aspects of the physical examination were normal.

Laboratory examination on first day of symptoms showed: Hemoglobin 13.5g/dL, Hematocrit 40%, Thrombocyte 234.000/Cmm, the Leukocyte was elevated to 18.040/Cmm (normal level 4.000-11.000/Cmm) with Eosinofil 1.4%, Basofil 0.2%, Neutrophil Segment 74,4%, Lymphocyte 13,0%, Monocyte 11%, random blood sugar (RBS) 250mg/dl, and post-prandial blood sugar (PPBS) 334mg/dl. Chest X-ray on first day of symptoms and follow-up chest X-ray on day two and fifth of hospitalization, showed consolidation in the basal dextra of lung suspect of pneumoniae and suspect of pleural effusion of left hemithorax (Figure. 2A), follow-up chest X-ray on day three and fifth of hospitalization revealed a collapsed left lung with a pleural visceral line (Figure. 2B-C).



**Figure. 2.**(A) Chest X-ray revealed a pneumonia infection on basal of dextra lung and pleural effusion of left hemithorax; (B-C) Chest X-ray revealed a decreased left pleural effusion and collapsed left lung with a pleural visceral line; (D) Chest X-ray on day 7 of hospitalization revealed decreased pleural effusion but not in lung re-expansion.

Bacterial culture from pleural fluid was taken on day two of hospitalization, showed of positive *Klebsiella pneumoniae*, when bacterial culture from sputum is carried out on day three of hospitalization, results that are similar to pleural fluid sample is also obtained, showed of positive *Klebsiella pneumoniae*. The strain was resistant to Ampicillin, Ciprofloxacin, and Nitrofurantoin. The patient was diagnosed with left pyopneumothorax associated with *Klebsiella pneumoniae* infection. In the emergency room, the patient underwent needle thoracocentesis by inserting a large-bore chest tube (LBCT) 24 French placed in the left pleural cavity produced fluid output of about 900mL on the first insertion, 200mL on the last day of hospitalization (**Figure 3**). The following treatment are oxygen therapy with a simple mask 8L/min, NaCl 0.9% of 1000mL/day, Metronidazole 3x500 via infusion, Sansulin log G 10iu SC, Paracetamol 3x500mg inj., Omeprazole 1x40mg inj., Dexamethasone 3x8mg inj., Sucralfat syrup 3x1, N-Acetylcysteine 200mg/8 h was given for 7 days.



**Figure 3. On day 7 of hospitalization pleural cavity produced fluid output of about 200mL**

Nausea were resolved on day three of hospitalization; however, shortness of breath and cough still remains but resolved on the day sixth of hospitalization and fever was ongoing. Previous therapy was continued. On day four of hospitalization, based on bacterial culture from empyema and sputum, antibiotic therapy changed to a 7-day course of Meropenem. On day seven of hospitalization, the patient's fever still remained on this day, Leukocyte was still elevated to 16.800/Cmm and chest X-ray on this day showed decreased pleural effusion not in lung re-expansion (Figure. 2D). Based on persistence of fever and not restoring lung expansion, the patient referred to another hospital that had better facilities. The patient was lost on follow-up after out of hospitalization.

### **Discussion:-**

In developing countries, more than one-fourth of hospital-admitted patients with pneumonia eventually develop parapneumonic effusion or empyema because of delayed initiation of adequate treatment. *Klebsiella pneumoniae* may progress to empyema thoracis following an infection with antibiotic-resistant organism or associated with comorbid conditions (malignancy, malnutrition, diabetes mellitus) (Chen et al., 2000; Lin, et al., 2010; Mandal et al., 2019). Patients with *K. pneumoniae* infection had significantly higher mortality rate than for the patients without *K. pneumoniae* infection (Chen et al., 2000; Lin, et al., 2010). However, our case found that early initiation of management of empyema thoracis with chest tube drainage for pyopneumothorax caused by *Klebsiella pneumoniae* showed only temporary improvement but less poor prognosis that had not been previously reported.

According to the 2017 guidelines from the American Association for Thoracic Surgery, in the early stages (stage I), surgery or installation of thoracic drainage is usually not required, can safely managed by antibiotics and ICD with or without fibrinolysis therapy/antiseptic lavage-irrigation of the chest tube. However, in stages II and III, closed drainage and decortication procedures are highly recommended (Liu et al., 2025). Patients who do not respond to tube drainage and antibiotic medications indicate a need for removal of the restrictive peel by open or thoracoscopic

surgery. Decortication should be planned for patients not responding to appropriate antibiotics and drainage, along with persistence of fever (Mubarik et al., 2019; Roberts et al., 2023). Chang et al., conducted a meta-analysis study suggest pigtail catheter drainage may be considered as the initial treatment option for patients with primary or secondary spontaneous pneumothorax. In line with Hussein et al., and Tsai et al., conducted a retrospective study of drainage complications was more frequent in failed cases of intercostal tube (20F-32F catheter) than failed cases of the pigtail (10F-14F) group with a significant difference and suggested that pigtail tube drainage should be considered as the initial treatment of choice. Mubarik et al., conducted a study with ICD procedure in the treatment of ET caused by Mycoplasma pneumoniae showed decortication should be reserved for ICD failure cases. In our case, the patient referred to another hospital that had better facilities for further follow-up in addressing the recovery of lung expansion and the patient's persisting complaints and should be investigated promptly for planning of surgical intervention if needed.

Klebsiella pneumoniae was the most frequently isolated sole pathogen, and its isolation had a strong correlation with diabetes mellitus. Previous study from the retrospective study revealed that patients with Klebsiella pneumoniae empyema when compared with patients with non-Klebsiella empyema had a higher prevalence of diabetes mellitus (44.1% vs 15.3%, respectively;  $p < 0.001$ ). Another retrospective study showed K. pneumoniae and non-K. pneumoniae pleural effusion revealed that the format had a higher prevalence of diabetes mellitus (51.4% vs 20%, respectively,  $p < 0.001$ ) (Chen et al., 2000; Lin, et al., 2010). But, the reason for the association of K. pneumoniae infection with diabetes mellitus still remains unknown.

Secondary spontaneous pneumothorax (SSP) results from chronic obstructive pulmonary disease (COPD), cystic fibrosis, pulmonary malignancy and/or infection. These conditions compromise the alveolar integrity, causing air to fill the pleural cavity (Sorino et al., 2024). Incidence of pneumothorax caused by lung infections in adults are the development of pleurisy and the lack of localized pulmonary overdistention and rupture of overdistended alveoli as result of severe coughing (Love & King, 1954). Pneumothorax in the course of pulmonary infection has been reported in infancy, less frequently in older children, and rarely in adults. Has been known for a long time that pneumothorax may be the result of either necrotizing pulmonary lesions or the development of postinfectious pneumatoceles or subpleural blebs. These mechanism was described as "carbuncles of the lung" rupturing into the pleural cavity. Subpleural blebs are formed by the rupture of alveoli and dissection of air between pulmonary parenchyma and visceral pleura. Pneumatoceles are "non-epithelialized positive pressure cavities produced by hyperinflation of a parenchymal defect from infection (Schweich & Fierstein, 1959). Sorino et al., also described lung infections compromise alveolar integrity, leading to air leakage into the pleural space.

Appropriate drainage of the pleural effusion, antibiotic like Aztreonam is reasonable as an initial therapy in patients with diabetes mellitus (Chen et al., 2000). Another retrospective study showed isolates of K. pneumoniae were uniformly resistant to ampicillin and susceptible to all cephalosporins (Lin et al., 2010). The strain was resistant to amoxicillin and sensitive to amoxicillin-clavulanate, piperacillin-tazobactam, cefotiam, ciprofloxacin, and gentamicin (Kitaya et al., 2025). Our study highlights the use of antibiotics starting on the day of fourth hospitalization but the patient's symptoms still remained on the last day of hospitalization. This assumes that further research is needed regarding the ideal period of antibiotic use in empyema thoracis patients.

### **Conclusion:-**

Our case showed initial treatment of pyopneumothorax caused by Klebsiella pneumonia with chest tube drainage using large-bore chest tube (LBCT) 24, but our case underscores the need for further follow-up in addressing the recovery of lung expansion and the patient's persisting complaints and should be investigated promptly for planning of surgical intervention if needed. Our case indicated that pyopneumothorax treated with chest tube drainage and appropriate antibiotic is a good choice as initial treatment.

### **References:-**

1. Chang, S. H., Kang, Y. N., Chiu, H. Y., & Chiu, Y. H. (2018). A systematic review and meta-analysis comparing pigtail catheter and chest tube as the initial treatment for pneumothorax. *Chest*, 153(5), 1201-1212. DOI :<https://doi.org/10.1016/j.chest.2018.01.048>
2. Chen, K. Y., Hsueh, P. R., Liaw, Y. S., Yang, P. C., & Luh, K. T. (2000). A 10-year experience with bacteriology of acute thoracic empyema. *Chest*, 117(6), 1685-1689. DOI :<https://doi.org/10.1378/chest.117.6.1685>



3. Hassan, M., Patel, S., Sadaka, A. S., Bedawi, E. O., Corcoran, J. P., & Porcel, J. M. (2021). Recent insights into the management of pleural infection. *International Journal of General Medicine*, 14, 3415–3429. <https://doi.org/10.2147/IJGM.S292705>
4. Hussein, R. M., Elshahat, H. M., Shaker, A., & Hashem, A. Z. A. (2017). Study of pigtail catheter and chest tube in management of secondary spontaneous pneumothorax. *Egyptian Journal of Chest Diseases and Tuberculosis*, 66(1), 107-114. DOI :<http://dx.doi.org/10.1016/j.ejcdt.2016.08.011>
5. Ishiguro, T., Uozumi, R., Yoshioka, H., Nishida, T., & Takayanagi, N. (2020). Comparison between Patients with Chest Infection due to *Klebsiella* spp. and *Streptococcus pneumoniae*. *Internal Medicine*, 59(5), 611-618. DOI :<https://doi.org/10.2169/internalmedicine.3531-19>
6. Kitaya, S., Saito, D., & Kanamori, H. (2025). Thoracic Empyema Caused by Hypermucoviscous *Klebsiella pneumoniae* Following Lung Resection in an Immunocompromised Patient. *The American Journal of Medicine*, 138(5), e87-e88. DOI :<https://doi.org/10.1016/j.amjmed.2024.12.007>
7. Knebel, R., Fraga, J. C., Amantea, S. L., & Isolani, P. B. S. (2018). Videothoracoscopic surgery before and after chest tube drainage for children with complicated parapneumonic effusion. *Jornal de Pediatria*, 94(2), 140–145. <https://doi.org/10.1016/j.jped.2017.05.008>
8. Kondov, G., Spirovski, Z., Kondova-Topuzovska, I., Kokareva, A., Colanceski, R., Sreca, M., Kondov, B., Dzikovski, I., Toleska-Dimitrovska, N., & Petrusevska-Marinkovic, S. (2017). Surgical Treatment of Pleural Empyema – Our Results. *PRILOZI*, 38(2), 99–105. <https://doi.org/10.1515/prilozi-2017-0027>
9. Lin, Y. T., Chen, T. L., Siu, L. K., Hsu, S. F., & Fung, C. P. (2010). Clinical and microbiological characteristics of community-acquired thoracic empyema or complicated parapneumonic effusion caused by *Klebsiella pneumoniae* in Taiwan. *European journal of clinical microbiology & infectious diseases*, 29, 1003-1010. DOI : 10.1007/s10096-010-0961-8
10. Liu, C. C., Chen, Y. L., Cheng, C. Y., Huang, C. L., Hung, W. H., & Wang, B. Y. (2025). Risk factors and prognostic predictors of recurrent bacterial empyema in patients after surgical treatment. *BMC Infectious Diseases*, 25(1). <https://doi.org/10.1186/s12879-025-11077-0>
11. Love, L., & King, J. C. (1954). Spontaneous pneumothorax complicating pneumonia. *Annals of Internal Medicine*, 40(1), 153-160.
12. Magendiran, B., Viswanathan, S., Selvaraj, J., & Pillai, V. (2024). Empyema Tube or No Tube? *Cureus*. <https://doi.org/10.7759/cureus.12829>
13. Mandal, K. C., Mandal, G., Halder, P., Mitra, D., Debnath, B., & Bhattacharya, M. (2019). Empyema thoracis in children: A 5-year experience in a tertiary care institute. *Journal of Indian Association of Pediatric Surgeons*, 24(3), 197-202. DOI : 10.4103/jiaps.JIAPS\_112\_18
14. Nwagboso, C. I., Echieh, C. P., Eze, J. N., Ogbudu, S. O., Njoku, C. H., Etiuma, A. U., & Bassey, O. O. (2022). Predictors of outcome of chest tube drainage of nonpurulent exudative pleural effusions. *ERJ Open Research*, 8(2). <https://doi.org/10.1183/23120541.00604-2021>
15. Roberts, M. E., Rahman, N. M., Maskell, N. A., Bibby, A. C., Blyth, K. G., Corcoran, J. P., Edey, A., Evison, M., De Fonseka, D., Hallifax, R., Harden, S., Lawrie, I., Lim, E., McCracken, D., Mercer, R., Mishra, E. K., Nicholson, A. G., Noorzad, F., Opstad, K. S., ... Walker, S. (2023). British Thoracic Society Guideline for pleural disease. *Thorax*. <https://doi.org/10.1136/thorax-2023-220304>
16. Santoshi, R. K., Chandar, P., Gupta, S. S., Kupfer, Y., & Wiesel, O. (2022). From Chest Wall Resection to Medical Management: The Continued Saga of Parapneumonic Effusion Management and Future Directions. *Cureus*, 14(1). <https://doi.org/10.7759/CUREUS.21017>
17. Semenkovich, T. R., Olsen, M. A., Puri, V., Meyers, B. F., & Kozower, B. D. (2018). Current State of Empyema Management. *Annals of Thoracic Surgery*, 105(6), 1589–1596. <https://doi.org/10.1016/j.athoracsur.2018.02.027>
18. Sorino, C., Feller-Kopman, D., Mei, F., Mondoni, M., Agati, S., Marchetti, G., & Rahman, N. M. (2024). Chest Tubes and Pleural Drainage: History and Current Status in Pleural Disease Management. In *Journal of Clinical Medicine* (Vol. 13, Issue 21). Multidisciplinary Digital Publishing Institute (MDPI). <https://doi.org/10.3390/jcm13216331>
19. Schweich, A., & Fierstein, J. (1959). Staphylococcal septicemia with recurrent spontaneous pneumothorax. *Annals of Internal Medicine*, 50(3), 819-828.
20. Tantraworasin, A., Thepbunchonchai, A., Siwachat, S., Ruengorn, C., Khunyotying, D., Kaufman, A. J., Taioli, E., & Saeteng, S. (2018). Factors associated with recurrent bacterial empyema thoracis. *Asian Journal of Surgery*, 41(4), 313–320. <https://doi.org/10.1016/j.asjsur.2017.02.009>
21. Tsai, W. K., Chen, W., Lee, J. C., Cheng, W. E., Chen, C. H., Hsu, W. H., & Shih, C. M. (2006). Pigtail catheters vs large-bore chest tubes for management of secondary spontaneous pneumothoraces in adults. *The American journal of emergency medicine*, 24(7), 795-800. DOI :doi:10.1016/j.ajem.2006.04.006