

 <p>ISSN (O): 2320-5407 ISSN (P): 3107-4928</p>	<p>Journal Homepage: <a href="http://www.journalijar.com">www.journalijar.com</a></p> <h2 style="text-align: center;">INTERNATIONAL JOURNAL OF ADVANCED RESEARCH (IJAR)</h2> <p style="text-align: center;">Article DOI: 10.21474/IJAR01/22560 DOI URL: <a href="http://dx.doi.org/10.21474/IJAR01/22560">http://dx.doi.org/10.21474/IJAR01/22560</a></p>	
--	---	---

### CASE REPORT

## OVERNIGHT OCCLUSIVE TOPICAL APPLICATION OF HIGH-CONCENTRATION 35 KDA HYALURONIC ACID FRAGMENTS FOR FACIAL ERYTHEMA AND SUBCUTANEOUS FAT: A CASE SERIES

Ding Mingxing<sup>1</sup>, Jia Xiaoxiao<sup>2</sup>, Fanghui Gao<sup>2</sup>, Xinrong Li<sup>2</sup>, Jessica Hui<sup>2</sup>, Vera Gorbunova<sup>3</sup> and Hui Mizhou<sup>2</sup>

1. Department of Cosmetology, Changchun Jiahe Plastic Surgery Hospital, Changchun, China.
2. Department of Biomaterials, Qingdao Hainuo Laboratory, Qingdao, China.
3. Departments of Biology and Medicine, University of Rochester, Rochester, New York, USA.

#### Manuscript Info

##### Manuscript History

Received: 04 November 2025  
Final Accepted: 06 December 2025  
Published: January 2026

##### Key words:-

Hyaluronic acid fragments; 35 kDa hyaluronic acid; facial erythema; subcutaneous fat; occlusive topical application; case series.

#### Abstract

**Background:** The naked mole rat (NMR) exhibits an exceptionally high concentration of hyaluronan (HA) in the skin and subcutaneous tissues, minimal subcutaneous fat accumulation, and a low incidence of inflammatory skin conditions. These features suggest a potential role for high-concentration HA in regulating cutaneous inflammation and adipose-related facial appearance.

**Methods:** This exploratory case series included five adults seeking non-invasive improvement of facial erythema and localized subcutaneous fat. A 10% formulation of 35 kDaHA fragments was applied to the entire face under occlusive conditions overnight once every two days for a total of five applications. Facial subcutaneous fat appearance, inflammatory erythema, skin radiance, and nasal alar pore condition were assessed at baseline, after the first application, and after the fifth application using a standardized 0–10 numerical rating scale (NRS).

**Results:** All participants demonstrated consistent reductions in facial subcutaneous fat appearance and inflammatory erythema, with visible improvement observed after the first overnight application and further enhancement following repeated treatment. Skin radiance improved and nasal alar pore enlargement was attenuated in all cases. No local or systemic adverse events were reported.

**Conclusions:** Overnight occlusive topical application of high concentration 35 kDaHA fragments was well tolerated and associated with rapid improvements in facial erythema, subcutaneous fat appearance, skin radiance, and pore condition. These preliminary findings support further investigation of low-molecular-weight HA fragments as a non-invasive approach for facial aesthetic improvement in controlled clinical studies.

"© 2026 by the Author(s). Published by IJAR under CC BY 4.0. Unrestricted use allowed with credit to the author."

**Corresponding Author:** Hui Mizhou and Vera Gorbunova.

**Address:-** Hainuo Building, No. 1 Guangdong Road, Jiangshan Industrial Park, Laixi 266603, Qingdao, Shandong, China; University of Rochester, 500 Joseph C. Wilson Blvd, Rochester, NY 14627, USA

**Acknowledgments:**The authors thank the participants for their involvement in this study and the clinical staff of Changchun Jiahe Plastic Surgery Hospital for their assistance. No external funding was received.

**Consent for Publication:**Written informed consent was obtained from the patient, and the patient consented to the publication of all clinical data, and other information included in the manuscript.

### **Introduction:-**

The NMR has attracted substantial scientific interest due to its extraordinary longevity and remarkably low incidence of inflammation and neoplastic disease. A defining biological characteristic of this species is the exceptionally high concentration of HA in its skin and subcutaneous tissues, accounting for approximately 6% of tissue composition, which is markedly higher than that observed in humans and other mammals. Notably, naked mole rats exhibit minimal subcutaneous fat accumulation and rarely develop inflammatory skin disorders [1,2]. These features suggest that high levels of HA may play an important role in maintaining adipose homeostasis and suppressing cutaneous inflammation.

Increasing evidence indicates that the biological activity of HA is highly dependent on its molecular weight. In contrast to high-molecular-weight HA, HA fragments within specific molecular weight ranges have been shown to modulate adipocyte differentiation, inflammatory signaling, and neuro-sensory pathways through receptor-mediated mechanisms [3,4]. Our research group previously demonstrated that continuous oral administration of high-dose, intestinally permeable 70 kDa HA fragments led to reductions in facial subcutaneous fat appearance, attenuation of inflammatory erythema, and improvement in overall facial condition within 20–40 days (Chinese Patent Application No. 202411344317).

More recently, we observed that topical application of a 10% high-concentration 35 kDa HA fragment formulation produced rapid relief of cutaneous pruritus and superficial pain [5]. Pharmacokinetic analyses suggested that this molecule does not readily penetrate into the dermis or subcutaneous tissue within short time frames, implying that its biological effects may not depend on conventional transdermal absorption. Building upon these observations, the present study aimed to explore the effects of repeated overnight occlusive topical application of a 10% high-concentration 35 kDa HA fragment formulation on facial subcutaneous fat appearance, inflammatory erythema, skin radiance, and nasal alar pore condition.

### **Cases and Methods:-**

#### **PARTICIPANTS:**

This case series included five Asian participants (three females and two males) who presented to the Department of Aesthetic Medicine at Changchun Jiahe Plastic Surgery Hospital, China. All participants sought non-invasive improvement of facial appearance due to localized subcutaneous fat accumulation and/or facial erythema.

Participants ranged in age from 27 to 68 years. Participant 1 was a 27-year-old female with a normal body mass index (BMI), a history of chronic sleep deprivation, and mildly sensitive skin. Her primary concerns included mild subcutaneous fat accumulation in the cheek and nasal alar regions accompanied by recurrent facial flushing, with no history of systemic dermatologic disease. Participant 2 was a 28-year-old male with a slightly elevated BMI, presenting with fat accumulation along the cheeks and mandibular border, as well as pronounced nasal alar pore enlargement. No active inflammatory skin conditions were reported. Participant 3 was a 42-year-old premenopausal female with increased subcutaneous fat in the cheeks and mandibular regions, accompanied by dull erythema in the central facial area and occasional acneiform lesions. Participant 4 was a 56-year-old postmenopausal female exhibiting facial skin laxity, reduced skin radiance, prominent subcutaneous fat accumulation in the temporal and cheek regions, and enlarged nasal alar pores. Participant 5 was a 68-year-old male with evident age-related skin changes, uneven facial fat distribution, and chronic erythema with enlarged pores in the nasal alar region.

All participants demonstrated full decision-making capacity and were able to understand and independently use a standardized 0–10 NRS[6,7] to complete self-assessments and report outcome measures. None of the participants had received fat-reduction treatments, medical aesthetic injections, or professional facial care within two weeks prior to enrollment.

#### INTERVENTION:

All participants underwent an identical intervention protocol. Each evening before sleep, a 10% high-concentration 35 kDaHA fragment formulation (product code: Q/0285HND045) was evenly applied to the entire face. The treated area was then covered with plastic wrap or a protective occlusive film to prevent premature drying, and the formulation was left in place overnight. Facial cleansing was performed the following morning.

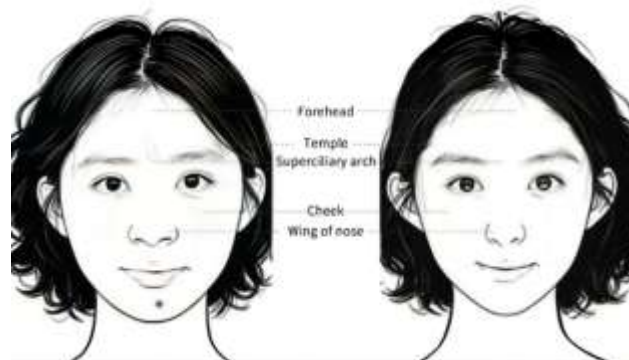
The intervention was administered once every two days, with a total of five applications completed over a 10-day period.

#### OUTCOME ASSESSMENT

A standardized 0–10 numerical rating scale (6,7) was used to quantitatively evaluate facial changes at baseline, after one application, and after completion of five applications. The assessed parameters included facial subcutaneous fat thickness, dark inflammatory erythema, skin radiance, and nasal alar pore enlargement.

Based on the schematic illustration shown in Figure 1, visual inspection combined with tactile palpation was used to assess the distribution and relative thickness of subcutaneous fat in the forehead, brow ridge, temples, cheeks, and nasal alar regions. Visual inspection was also employed to evaluate the extent of dark inflammatory erythema in these regions and to assess changes in nasal alar pore appearance.

Scoring criteria were defined as follows. For facial subcutaneous fat thickness, a score of 0 indicated normal thickness, while 10 represented the theoretical maximum thickness. For dark inflammatory erythema in the cheek and nasal alar regions, 0 indicated absence of erythema and 10 represented the theoretical maximum severity. For facial skin radiance, 0 indicated normal radiance and 10 represented the poorest theoretical radiance. For nasal alar pore enlargement, 0 indicated normal pores without enlargement and 10 represented the most severe theoretical enlargement.



**Figure 1. Schematic illustration of visual assessment of facial parameters before and after treatment. Figure 1A represents the estimated facial condition at baseline, and Figure 1B represents the estimated condition after five applications.**

#### RESULTS:-

After five overnight occlusive topical applications, all participants exhibited a sustained decreasing trend in subcutaneous fat thickness across multiple facial anatomical regions. The most pronounced improvements were observed in the forehead, brow ridge, cheeks, and nasal alar regions, as summarized in Table 1. The severity of dark inflammatory erythema in the cheek and nasal alar regions decreased concurrently, and in most participants, visually perceptible improvement was already evident after the first application.

Facial skin radiance scores demonstrated a progressive decline in the forehead, brow ridge, and central facial regions, indicating improvement in skin dullness and overall luminosity. The degree of nasal alar pore enlargement

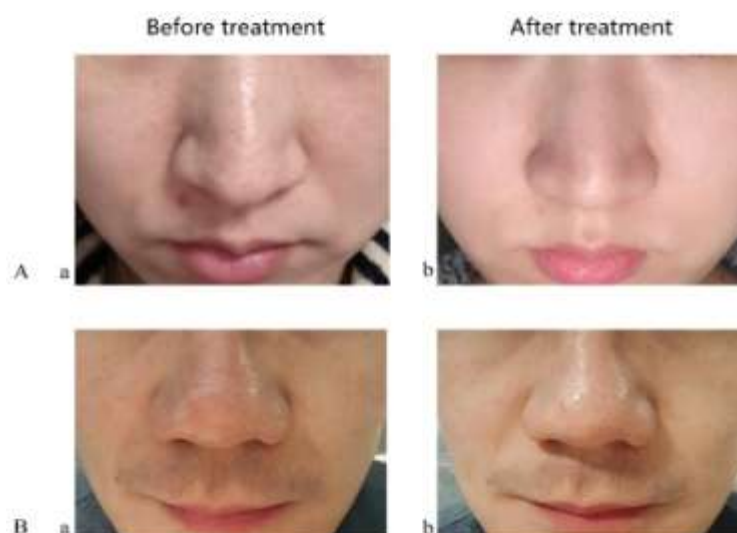also decreased with increasing numbers of applications. Throughout the study period, no participant reported local irritation, burning sensation, desquamation, or delayed adverse reactions, and no systemic adverse events were observed, suggesting good tolerability of the occlusive topical regimen.

**Table 1. Quantitative scores (0–10) of facial parameters before and after treatment**

Evaluation Parameter	Assessment Site	Baseline	After 1 treatment	After 5 treatments
Facial subcutaneous fat thickness	Forehead	3.6 ± 1.4	2.6 ± 1.4*	0.8 ± 0.7**
	Brow ridge	4.0 ± 1.8	3.0 ± 1.8*	1.0 ± 0.9**
	Temple	2.2 ± 1.0	2.2 ± 1.0 ns	0.2 ± 0.4**
	Cheek	4.2 ± 1.8	3.2 ± 1.8*	1.0 ± 0.9**
Dark inflammatory erythema	Nasal alar	3.0 ± 0.9	2.4 ± 0.5*	0.8 ± 0.4**
	Cheek	3.2 ± 1.2	2.2 ± 1.2*	0.2 ± 0.4**
	Nasal alar	2.6 ± 0.8	1.8 ± 0.7*	0.4 ± 0.5**
	Forehead and brow ridge	3.0 ± 0.9	2.0 ± 0.9*	0.2 ± 0.4**
Facial skin radiance	Temple and cheek	3.6 ± 0.5	2.6 ± 0.5*	0.4 ± 0.5**
	Nasal alar and facial region	4.0 ± 0.9	3.0 ± 0.9*	0.8 ± 0.7***
	Pore enlargement	3.0 ± 0.6	2.4 ± 0.5*	0.6 ± 0.5**

\*Data are presented as mean ± SD. Statistical significance is based on comparisons with baseline: ns,  $P > 0.05$ ; \* $P < 0.05$ ; \*\* $P < 0.01$ ; \*\*\* $P < 0.001$ .

Figure 2 presents representative clinical images from two participants before treatment and after five applications. Visible improvements were observed in nasal alar pore enlargement, facial dark erythema, skin radiance, and nasal alar subcutaneous fat appearance.



**Figure 2. Representative facial images before and after treatment.**

**Discussion:-**

This exploratory case series suggests that five overnight occlusive topical applications of a 10% high-concentration 35 kDaHA fragment formulation were associated with stable and consistent aesthetic improvements across multiple facial parameters. Improvements were observed in all assessed domains, including the appearance of subcutaneous fat thickness, inflammatory erythema, skin radiance, and nasal alar pore appearance, as summarized in Table 1 and illustrated in Figure 2. Collectively, these findings align with the inflammation-resistant phenotype associated with high tissue hyaluronan content in naked mole rats and are consistent with observations reported in our previous clinical and experimental studies [1–5]. Together, they provide preliminary clinical-level support for the potential role of high-concentration, molecular-weight-specific HA fragments in facial aesthetic modulation and inflammatory regulation.

Notably, partial improvements were already apparent following the first overnight occlusive application, indicating that the observed effects may not depend exclusively on long-term structural tissue remodeling. Instead, relatively rapid regulatory processes—potentially involving neuro-inflammatory signaling, microcirculatory modulation, or changes in tissue hydration dynamics—may contribute to the early clinical responses. Previous studies have suggested that 35 kDa HA fragments can interact with transient receptor potential ion channels in peripheral sensory nerve endings and influence downstream inflammatory signaling pathways, thereby reducing local inflammatory sensitivity and indirectly affecting cutaneous blood flow, tissue tension, and adipose homeostasis [5]. Although the present study did not directly investigate these mechanisms, the rapid onset of visible changes observed under occlusive conditions is compatible with such regulatory pathways.

From a clinical perspective, facial erythema, localized subcutaneous fat accumulation, and pore enlargement are often managed as independent aesthetic concerns. However, emerging evidence indicates that these features are frequently interconnected and associated with chronic low-grade cutaneous inflammation, microvascular dilation, and dysregulated adipose metabolism. In this context, the observed simultaneous improvement across multiple facial parameters suggests a shared underlying regulatory effect rather than isolated cosmetic changes.

Compared with topical corticosteroids, which are commonly used to suppress facial inflammation but are limited by risks such as skin atrophy, barrier impairment, and rebound erythema, the 35 kDa HA fragment formulation applied in this study demonstrated a relatively rapid improvement profile without observable local or systemic adverse effects [8–10]. This favorable tolerability profile may offer potential advantages for repeated or longer-term use, particularly in individuals with inflammation-prone facial skin.

Several limitations of this study should be acknowledged. The sample size was small, and outcome assessments were based primarily on subjective NRSs, without objective imaging, biochemical markers, or histological validation. In addition, the use of occlusive application may have amplified local microenvironmental effects, and the efficacy and durability of this formulation under routine, non-occlusive topical conditions remain to be determined. Future studies incorporating larger cohorts, controlled study designs, and objective assessment tools—such as high-frequency skin ultrasound or optical imaging—are warranted to confirm these findings and further clarify the underlying biological mechanisms.

**Conclusion:-**

Overnight occlusive topical application of a 10% high-concentration 35 kDaHA fragment formulation was associated with visible reductions in the appearance of facial subcutaneous fat and inflammatory erythema, improvement in nasal alar pore appearance, and enhancement of overall skin radiance. The intervention demonstrated a rapid onset of effect and good tolerability in this small case series. Although preliminary in nature, these findings suggest that high-concentration, low-molecular-weight HA fragments may represent a safe, non-invasive, and potentially effective approach for facial aesthetic improvement and skin condition modulation, meriting further investigation in larger, well-controlled clinical studies.

**Reference:-**

- [1] Zhang Z H, Tian X, Lu J Y, et al. Increased hyaluronan by naked mole-rat Has2 improves healthspan in mice. *Nature*, 2023, 621:196-205.
- [2] Takasugi M, Firsanov D, Tomblin G, et al. Naked mole-rat very-high molecular-mass hyaluronan exhibits superior cytoprotective properties. *Nature Communications*, 2020, 11:2376.

- [3] Park B G, et al. Enzymatic fragments of hyaluronan inhibit adipocyte differentiation in 3T3-L1 pre-adipocytes. *BiochemBiophys Res Commun*, 2015, 467(4):623-628.
- [4] Park B G, et al. Anti-obesity potential of enzymatic fragments of hyaluronan on high-fat diet-induced obesity in C57BL/6 mice. *BiochemBiophys Res Commun*, 2016, 473(1):290-295.
- [5] Fenghe Xu, Xiaoxiao Jia, Jessica H Hui, et al. Analgesic Effect of High-Concentration 35 kDa Hyaluronic Acid Fragment Gel in Herpes Zoster–Related Pain: A Case Series. *Journal of Dermatological Case Reports*, In press.
- [6] Cleland J A, Childs J D, Whitman J M. Psychometric properties of the Neck Disability Index and Numeric Pain Rating Scale in patients with mechanical neck pain. *Arch Phys Med Rehabil*, 2008, 89(1):69-74.
- [7] Vernon H, Mior S. The Neck Disability Index: a study of reliability and validity. *J Manipulative PhysiolTher*, 1991, 14(7):409-415.
- [8] Xie H, Xiao X, Li J. Topical steroids in Chinese cosmetics. *JAMA Dermatol*, 2017, 153(9):855-856.
- [9] Nyati A, Singhal A K, Yadav D, et al. Topical steroid abuse on face: a prospective study from a tertiary care centre of north India. *International Journal of Research in Dermatology*, 2017, 3(3):433-438.
- [10] Coondoo A, Phiske M, Verma S, et al. Side-effects of topical steroids: a long overdue revisit. *Indian Dermatol Online J*, 2014, 5(4):416-425.