

 <p>ISSN (O): 2320-5407 ISSN (P): 3107-4928</p>	<p>Journal Homepage: - <a href="http://www.journalijar.com">www.journalijar.com</a></p> <h2 style="text-align: center;">INTERNATIONAL JOURNAL OF ADVANCED RESEARCH (IJAR)</h2> <p style="text-align: center;">Article DOI: 10.21474/IJAR01/22618 DOI URL: <a href="http://dx.doi.org/10.21474/IJAR01/22618">http://dx.doi.org/10.21474/IJAR01/22618</a></p>	
--	---	---

### RESEARCH ARTICLE

## HEPATOPROTECTIVE EFFECT OF KALMEGHA (ANDROGRAPHIS PANICULATA): INSIGHTS FROM AN ANIMAL EXPERIMENTAL STUDY

Barkha Thakur, Pankaj Mishra and Shiromani Mishra

#### Manuscript Info

##### Manuscript History

Received: 10 November 2025

Final Accepted: 12 December 2025

Published: January 2026

##### Key words:-

Kalmegha, Andrographis paniculata, hepatoprotective, liver injury, animal study, herbal medicine.

#### Abstract

**Background:** Liver diseases are a global health burden. Kalmegha (Andrographis paniculata), a traditional medicinal plant, has been used for liver ailments, but scientific validation in experimental models is essential.

**Objective:** To evaluate the hepatoprotective potential of Kalmegha in experimentally induced hepatic injury in animal models.

**Methods:** [Briefly mention model used, e.g., carbon tetrachloride/paracetamol-induced hepatotoxicity, animal group division, dose of extract, duration, biochemical & histopathological assessment.

**Results:** Kalmegha significantly improved biochemical parameters (ALT, AST, Bilirubin) and restored antioxidant levels compared to toxicant control. Histopathological examination supported biochemical findings.

**Conclusion:** Findings suggest Kalmegha possesses promising hepatoprotective activity and may serve as a potential natural hepatoprotective agent.

"© 2026 by the Author(s). Published by IJAR under CC BY 4.0. Unrestricted use allowed with credit to the author."

#### Introduction:-

Liver diseases are a major cause of morbidity and mortality worldwide, accounting for nearly two million deaths annually<sup>1</sup>. Current pharmacological therapies are limited and often associated with side effects, which has increased interest in natural hepatoprotective agents<sup>2</sup>. dkyes%k HkwfuEcks ;okdkjQyLrFkk A lqfrDr% y?kq:{kks".k% dQflkRrfouk'kuAA nhui% Losnuks Ks;% d'fe?u% fRRklkj d% A ;d'njksxs fdzeh dq"Bs Tojs PkklkSiz'kL;rsAA fiz0 fu0 136 ¼4'kriq"ikfn oxZ½ Acharya Priyavrat Sharma states in Priye Nighantu that Kalmegha possesses Deepana and Pittasarak properties and is used in Yakrit Roga, highlighting its hepatoprotective potential<sup>3</sup>. Kalmegha is cited for liver disorders in Dravyaguna Hastamalak<sup>4</sup>, Vanoshadhi Nidarsika<sup>5</sup>, and Vaidya V.M. Gage's Ayurvedic Pharmacology<sup>6</sup>. Kalmegha (Andrographis paniculata, family: Acanthaceae), known as "King of Bitters," is widely used in Ayurveda, Siddha, and traditional Chinese medicine for treating fever, jaundice, and liver disorders<sup>7</sup>. Its bioactive compound, andrographolide, has been reported to possess antioxidant, anti-inflammatory, and hepatoprotective properties<sup>8</sup>. However, experimental validation of its hepatoprotective efficacy in animal models remains crucial. The present study was designed to evaluate the hepatoprotective activity of Kalmegha against paracetamol induced hepatotoxicity in Wistar rats.

**Corresponding Author:-** Barkha Thakur

**Aim and Objectives:-****Aim-**

To study the effect of Kalmegha on hepatic disorders.

**Objective:-**

- ☑To study about Yakrit Roga (liver disorder) and hepatotoxicity and determine the role of hepatoprotective property of Kalmegha in Yakrit Roga.
- ☑To serve humanity by providing safe, economical and effective hepatoprotective drug and by treating liver diseases without producing toxicity.
- ☑To prove that Ayurveda cures diseases in natural way without disturbing equilibrium of the body, and is superior therapy than other modern therapies.

**Materials and Methods:-****Ethical clearance:-**

Clearance from the ethical committee was obtained from government autonomous Dhanwantari Ayurvedic college Ujjain MP (approved date 10-02-2020, letter no/2020/4385) and institutional animal ethical committee of college of veterinary science and Animal Husbandary, Jabalpur MP (Approved date 15-12-2020, no ex 09/iaec/vety/2020) before commencement of the study.

**Hypothesis:-**

Null Hypothesis (H<sub>0</sub>):<sup>[1][2]</sup>There is no significant difference in hepatoprotective activity among the four groups, and the decoction or dilution of Kalmegha does not produce any improvement in liver parameters when compared with the negative control. Alternative Hypothesis (H<sub>1</sub>):<sup>[1][2]</sup>There is a significant difference in hepatoprotective activity among the groups, and the decoction or dilution of Kalmegha produces measurable improvement in liver parameters compared with the negative control, with possible differences between their decoction and dilution forms.

**Plant Material:-**

Kalmegha leaves were collected, shade-dried, and authenticated by a botanist. To investigate anti-hepatotoxic substances, it is customary to subject animal experimentation to a range of standard protocols of hepatoprotective activity by merging certain in vivo and in vitro models. In these models certain toxic substances or toxicant have been used to produce hepatic injury resembling the different diseases and then anti hepatotoxic activity is evaluated. The hepatoprotective activity is assessed by noting the effect of test drug on toxicants induced changes in different parameters like weight, volume and cytoarchitecture of liver, viability of hepatocytes after perfusion with test drug, chemical constituents and enzyme activity in liver and serum, especially those that are related to secretory metabolic and excretory functions of liver.

**Study design:-****Chemicals :-**

**The chemicals used in hematology, biochemistry and histopathology are listed:**

**Below:**

- Acetone (Make: Molychem, 21040)
- Alanine amino transferase kit (Cat loguErba Transaia Bio-Medicals)
- Aspartate amino transferase kit (CatT, Erba ransaia Bio-Medicals )
- Eosin-Y (Merck, 230251)
- Geimsa stain (Fisher Scientific, 38723)
- Hematology reagents (Ark diagnostics)
- Harris hematoxylin (Hi-Media, SO34)
- Paraffin wax (Make: Hi-Media, GRM1042)

**Equipment:-**

- Blood cell analyzer (Make: Abacus junior vet 5)
- Centrifuge machine (Make: REMI, R-8C)
- Microscope with image capturing facility (Make: Leica)
- Rotary microtome (Make: Yorco, Spencer type)

- Semi-automatic biochemical analyzer (Make: Erba Mannheim)
- Wax incubator (Make: Yorco scientific)

#### Experimental animals:-

The experiment was conducted on Wistar rats of either sex weighing 150-200 g. These rats were housed in the Central Laboratory Animal House, College of Veterinary Science & A.H., Jabalpur, as per the guidelines of CPCSEA. Rats were provided with ad-libitum commercial pelleted feed (Nutrivet life sciences) and water. Environmental conditions such as  $22\pm 3^{\circ}\text{C}$  temperature and 12 hours light and dark cycle were given to the rats. The protocol of the study was approved by the IAEC (IAEC protocol no. 09./IAEC/Vety/20) After 07 days of acclimatization, the rats were randomly divided into four groups, consisting of 08 animals each..

The treatment protocol is summarized in following Table .

Group	Treatment	Number of animals
I	Positive Control,	08
II	Negative Control	08
III	2 ml decoction of Kalmegha	08
IV	2 ml dilution of Kalmegha	08

#### Experimental design:-

- Hepatic damage in rats from group I, III, IV, were produced by administration of single dose of Paracetamol @1500mg/kg orally.
- Rats of group I served as Positive control of hepatic damage.
- Rats of group III, and IV, also administered with treatment protocol as mentioned in above table.
- Rats of group II were provided with standard feed and water, served as Negative control.

#### Clinical observation:-

- All the rats belonging to various groups were closely observed on a daily basis for the development of any clinical signs during the entire experimental period.

#### Body weight estimation:-

- The body weight of individual rats was recorded from the first to fourth week of the study to assess the weekly body weight gain using the weighing balance (Aczet, CY223C) during the experimental period.

#### Collection of blood samples:-

- Approximately 1.0 ml of blood was collected aseptically from retro orbital sinus of rats on 30<sup>th</sup> day of study. Then, the blood was transferred into two sterilized Eppendorf tubes, one coated with heparin as anticoagulant was used for hematological examination, while the other without anticoagulant was used for serum separation (stored at  $-20^{\circ}\text{C}$ ).

#### Serum Biochemistry:-

- Serum samples were analyzed for biochemical parameters namely, ALT, AST and total bilirubin using semi-automatic biochemical analyzer (Erba mannheim) by using commercially available kits (Erba- Transaia Bio-Medicals LTD).

**Collection of tissue samples:-**

- Rats belonging to different groups were humanely sacrificed at end of study period. All the rats were subjected for detailed post mortem examination. Liver from different groups were collected. A portion of liver is collected for histopathological study.

**Gross Pathological Examination:-**

- Rats belonging to various experimental groups were subjected to detail pathological examination. Gross pathological lesions were closely observed and recorded in various organs especially liver of rats.

**Histopathology:-**

- Representative tissue samples of liver from rats of different groups were collected and fixed in 10% formalin for a minimum period of 24 hours and processed for histopathological examination. Tissue pieces of approximately 0.5×0.5 cm in size were dehydrated in three changes of acetone and cleared in three changes of benzene, followed by impregnation was done in four chambers of wax. The paraffin tissue blocks were made by embedding tissue in wax using L-molds or cassettes as per the method described by Gridley (1960) with slight modification.

**Section cutting:-**

- Approximately 4-5 mm thin sections were cut by rotary microtome and ribbon section was placed in water bath. Floating sections were taken on clean glass slides smeared with egg albumin as adhesive for histopathology.

**Staining of tissues:-****Hematoxylin and Eosin (H&E):-**

Hematoxylin & Eosin staining was performed as per the method described by Gridley (1960) with slight modification. The sectioned slides were stained with hematoxylin and eosin, mounted with DPX (Distyrene plasticizer xylene) and covered with coverslips for further histopathological examination. Duration of study-The study was conducted for the period of one month.

**Statistical analysis:-**

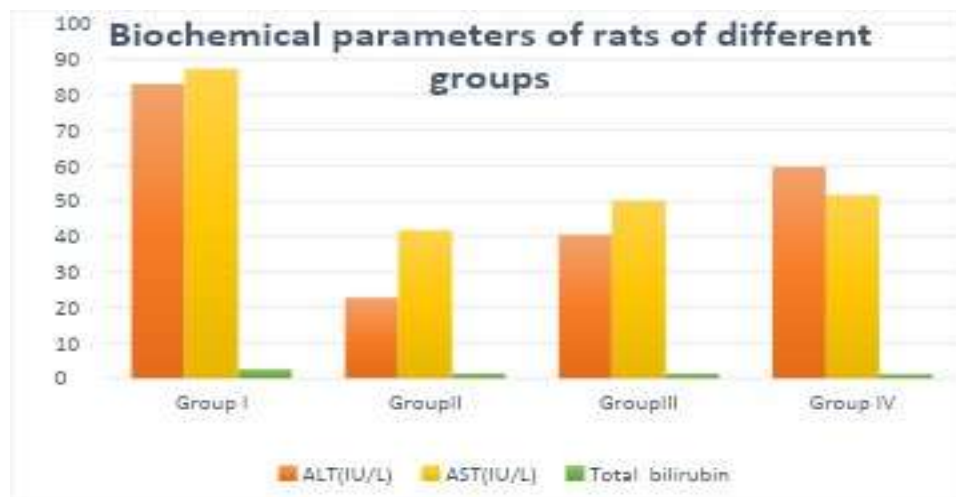
Data gathered from the study was analyzed by standard statistical procedures (Snedecor and Cochran, 1994). The data was tabulated and descriptive statistics, such as mean and standard error and inferential statistics, including one-way Analysis of Variance (ANOVA) were obtained. The mean values were compared by Fisher pair wise comparison 5 per cent level of significance Snedecor and Cochran, (1994)

**Results:-**

In the present study, serum samples of rats were subjected to biochemical examination including, ALT, AST and Total bilirubin (TB). Results are presented in following table:

**Biochemical parameters of rats of different groups:-**

Groups/ Parameters	ALT (IU/L)	AST (U/L)	Total Bilirubin(mg/dL)
Group I	82.97 <sup>a</sup> ±0.63	87.33. <sup>a</sup> ±1.07	02.60 <sup>a</sup> ±0.22
Group II	22.76 <sup>f</sup> ±0.32	41.66 <sup>d</sup> ±0.33	01.36 <sup>b</sup> ±0.05
Group III	40.46 <sup>d</sup> ±2.00	50.17 <sup>b</sup> ±1.61	01.35 <sup>b</sup> ±0.03
Group IV	59.64 <sup>b</sup> ±0.31	51.64. <sup>b</sup> ±0.28	01.21 <sup>b</sup> ±0.03



Mean value with different superscript differs significantly ( $P < 0.05$ ) in row. Biochemical examination showed, significant increase in value of liver enzymes like ALT, AST and total bilirubin rats of positive control as compared to negative control and other groups. There was significant difference in the values between the groups. There was significant improvement recorded on ALT and AST and total bilirubin in all treated rats who were received decoction of Kalmegha (group III) and dilution of Kalmegha (group IV).

## Discussion:-

### Serum biochemistry:-

Biochemical examination showed, significant increase in value of liver enzymes like ALT, AST and total bilirubin in rats of positive control as compared to negative control and other groups. There was significant difference in the values between the groups. There was significant improvement recorded on level of ALT and AST and total bilirubin in all treated rats who received decoction of Kalmegha and dilution of Kalmegha. Though this improvement was more pronounced in group group III with statistical difference at level of both the liver enzymes. The above result aligns with Gupta et al. (2022)<sup>9</sup> and Thomas et al. (2023)<sup>10</sup> with improved level of ALT, AST and total bilirubin with use of Kalmegha due to its antioxidant, anti-inflammatory and hepatoprotective actions. However, Verma et al. (2013)<sup>11</sup> compared the hepatoprotective action of Kalmegha and Chirayata, in which extract of *A. Paniculata* showed significant better hepatoprotective as compare to *S. chirayita*. Shrivastava and Gilhotra. (2017) also evaluated the hepatoprotective activity in Kalmegha in CCl<sub>4</sub> treated rats induced liver damage and found significant reduction in ALT value<sup>12</sup>.

### Gross and Histo Pathology:-

At the end of study, post mortem examination of rats pointed that dark coloured congestion and whitish-yellowish discolored foci in few rats of positive control group. Histopathological examination of liver of rats of positive control, who received single dose of Paracetamol showed moderate necrosis and vacuolation of hepatocytes pointing towards hepatic damage, as also evident by the increased liver enzymes (ALT and AST) in group I rats. Rats who received the decoction of Kalmegha after hepatic damage (paracetamol administration) showed normal histology and hepatocytes pointing towards improvement in liver histoarchitecture on administration of the drugs. Where as this improvement on liver histology was milder in rats who received dilution of Kalmegha after hepatic damage. The findings of our research work aligns with work done Verma et al. (2013), paracetamol group shows severe centrilobular necrosis characterized by nuclear pyknosis, karyolysis, and eosinophilic infiltration, confirming extensive hepatocellular damage and found hepatoprotective effects demonstrated by both the plants (Kalmegha and Chirayata). Similarly, in present study we observed improvement on hepatic damage on administration of Kalmegha with better preserved histology in decoction of Kalmegha than dilution of Kalmegha. As Kalmegha prevents the lipid peroxidation of hepatocytes additionally anti-inflammatory effects protects the hepatocytes from necrosis and vacuolation.

### Overall Effect Of Therapy:-

The study demonstrated that paracetamol administration at 1500 mg/kg produced significant biochemical disturbances, histopathological alterations, and pronounced hepatic injury in rats. Kalmegha exhibited clear

hepatoprotective effects against this induced liver damage. Notably, the decoction form provided greater therapeutic benefit compared to dilution, indicating superior efficacy in restoring liver function and mitigating tissue injury. The results demonstrate that Kalmegha possesses potent hepatoprotective activity against paracetamol induced hepatotoxicity. Restoration of liver function markers and antioxidant enzymes suggests its protective mechanism involves free radical scavenging and stabilization of hepatocyte membranes. Andrographolide, the major active compound of Kalmegha, has been previously shown to modulate cytochrome P450 enzymes, suppress lipid peroxidation, and enhance antioxidant defence. Our findings align with earlier studies reporting hepatoprotective effects of *Andrographis paniculata* extracts in animal models. Its Ushna virya supports Agnivardhana, facilitating detoxification and regeneration of Yakrit dhatu.

#### Guna–Karma Relationship:-

- Tikta rasa → Detoxifies liver, enhances bile flow, and clears Ama.
- Laghu-Rukshaguna → Reduces Medodushti and Kleda accumulation in hepatic tissue.
- Ushna virya → Stimulates metabolism (Agni).
- Katu vipaka → Ensures clearance of metabolic wastes (Mala nissarana).

Hence, the hepatoprotective effect observed experimentally is a physiological manifestation of these gunas acting in synergy.

The experimental findings scientifically validate traditional Ayurvedic reputation of Kalmegha as a potent hepatoprotective agent, demonstrating its ability to effectively prevent and reverse paracetamol-induced liver injury in Wistar rats. Notably, the decoction form outperformed the diluted powder suspension, likely due to enhanced solubility and bioavailability of key phytoconstituents like andrographolide.

#### Conclusion:-

- Paracetamol successfully induced hepatotoxicity, evidenced by elevated ALT, AST, bilirubin, and histopathological damage.
- Kalmegha treatment significantly normalized biochemical markers and restored liver architecture.
- Decoction exhibited superior efficacy compared to diluted powder form.

#### Clinical Implications:-

These results affirm Ayurveda's Samadosha Samagnischa Samadhatu Mala Kriya principle, wherein Kalmegha restores doshic equilibrium and physiological homeostasis. As a safe, economical, and effective natural remedy, Kalmegha decoction holds substantial promise for integration into modern hepatology protocols for both prevention and management of drug-induced liver injury.

#### References:-

1. GBD 2019 Diseases and Injuries Collaborators. Global burden of 632 diseases and injuries in 204 countries and territories, 1990-2019. *Lancet*. 2020;396(10258):1204-22.
2. Trivedi KP, Rawal BK. Introduction to hepatology. Ahmedabad: NB Patel; 1999.
3. Priyavrat Sharma A. Priye Nighantu. Varanasi: Chaukhambha Orientalia; 2001. p. 136 (Priyanguvarga).
4. Sharma PC, Yelne MB, Dennis TJ. Dravyaguna Vijnana. Varanasi: Chaukhambha Bharati Academy; 2005.
5. Ambike VN, Bhide MB. Vanoushadhi Nidarsika. Pune: Saptarishi Prakashan; 1970.
6. Garge VM. Ayurvedic Pharmacology. Mumbai: Vaidyasagar Prakashan; 1995.
7. Hossain MS, Urbi Z, Sule A, Hafizur Rahman KM. *Andrographis paniculata* (Burm.f.) Wall. ex Nees: a review of its ethnopharmacology, phytochemistry, and pharmacological activities. *J Pharm Pharmacol*. 2014;66(12):1371-95.
8. Jayakumar T, Hsieh CY, Lee JJ, Sheu JR. Experimental and Clinical Pharmacology of *Andrographis paniculata* and Its Major Bioactive Constituent Andrographolide. *Front Pharmacol*. 2013;4:125.
9. Gupta P, Yadav D, Bisen PS. Evaluation of hepatoprotective activity of *Andrographis paniculata* against paracetamol-induced hepatotoxicity. *J Pharmacogn Phytochem*. 2022;11(11S):467-72.
10. Thomas T, Sabu MC, Kuttan R. Hepatoprotective and anti-inflammatory activities of *Andrographis paniculata*. *Pharm J*. 2023;1(1):295-300.
11. Verma VK, Saraf SK, Tripathi P. Comparison of hepatoprotective activity of *Swertia chirayita* and *Andrographis paniculata* against CCl induced hepatotoxicity in rats. *Pharmacologyonline*. 2013;3:104-13.
12. Shrivastava S, Gilhotra R. Hepatoprotective activity of *Andrographis paniculata* in CCl induced liver damage in Wistar rats. *Int J Pharm Sci Res*. 2017;8(10):4321-7.