



RESEARCH ARTICLE

VERTICAL ROOT FRACTURE

Twinkle Gupta, Ajay Kumar Nagpal, Sunil Kumar, Juhi Dubey and Himanshu Sharma

Manuscript Info

Manuscript History

Received: 8 February 2026

Final Accepted: 10 March 2026

Published: April 2026

Key words:-

Vertical root fracture, Multifactorial etiology, Endodontically treated teeth, Progressive bone loss, Extraction

Abstract

Vertical root fracture (VRF) is a longitudinal fracture of the root that most frequently affects endodontically treated teeth, although it may also occur in vital dentition. As part of the cracked tooth spectrum, VRF presents significant diagnostic and therapeutic challenges due to its variable clinical manifestations and its resemblance to persistent endodontic or periodontal disease. The etiology is multifactorial, involving natural predisposing factors such as root morphology, occlusal loading, dentin aging, and pre-existing microcracks, as well as iatrogenic factors including excessive dentin removal, obturation stresses, post placement, and inadequate restorative design. VRFs typically develop through a slow process of cyclic fatigue and structural weakening of radicular dentin, leading to longitudinal crack propagation and subsequent periodontal breakdown. Early and accurate diagnosis is essential to prevent unnecessary retreatment, progressive bone loss, and complications that may compromise future implant placement. Diagnosis should be based on a comprehensive assessment integrating patient-reported symptoms, clinical findings—such as isolated deep periodontal probing defects and coronally positioned sinus tracts—and radiographic evaluation. Conventional periapical radiographs have limited sensitivity for early fractures, while cone-beam computed tomography (CBCT) provides three-dimensional assessment but remains constrained by resolution limitations and imaging artifacts. Management depends on fracture extent and restorability, ranging from conservative monitoring and root resection procedures to extraction and implant rehabilitation. Preventive strategies emphasizing preservation of dentin, controlled obturation forces, appropriate post selection, and adequate ferrule design are critical in reducing the risk of VRF and improving long-term treatment outcomes.

"© 2026 by the Author(s). Published by IJAR under CC BY 4.0. Unrestricted use allowed with credit to the author."

Introduction:-

Cracked teeth is a general term for a series types of tooth fracture with quite variable and complicated clinical signs and symptoms. Several different terminologies, definitions, and classifications for cracked teeth have been proposed. The most widely used classification is the American Association of Endodontists (AAE) classification, which divides cracked teeth into five types: craze lines, fractured cusp, cracked tooth, split tooth, and vertical root fracture (VRF). It should be noted that these five types are not entirely mutually exclusive. Linear cracks tend to grow and

change over time, and so, one fracture type can progress into another type over time.¹ A vertical root fracture is defined in the AAE Glossary of Endodontic Terms as a longitudinal fracture “in the root whereby the fractured segments are incompletely separated; it may occur buccal-lingually or mesial-distally; it may cause an isolated periodontal defect(s) or sinus tract; it may be radiographically evident”. (2, 3) Most VRFs occur in endodontically treated teeth. VRFs usually do not occur during the actual obturation of the root canal, but rather long after the procedure has been completed. The etiology of VRFs is multifactorial, arising in the presence of one or more predisposing factors, the repeated functional or parafunctional occlusal loads which may eventually lead, over months or even years, to the development of a VRF.² Now “why is the early diagnosis of vertical root fracture important?”

Accurate and timely diagnosis is crucial in VRF cases, allowing the extraction of the tooth or root before extensive damage to the alveolar bone occurs. Early diagnosis is particularly important when implants are a potential part of the future restorative process; when an extraction is performed at an early stage, the uncomplicated placement of an implant is more likely. When the tooth is extracted after extensive damage has already occurred, bone regeneration procedures may be required, adding additional cost and time to the restoration process. The diagnostic modalities that are often used for detection of VRFs include clinical examination, radiography, and invasive options such as exploratory surgery.^(2, 4) Vertical root fractures may develop slowly and without any obvious signs and/or symptoms, making (differential) diagnosis challenging. Early detection and appropriate management of (incomplete) VRFs is essential to enhance the chances of retaining the affected tooth and/or minimizing the undesirable consequences of this complication. Timely extraction of teeth with advanced VRFs (i.e., complete VRF or split tooth) will prevent pain/discomfort and limit peri-radicular bone loss which may have an impact on subsequent implant treatment planning.⁽⁵⁾

Prevalence:-

VRFs are commonly associated with endodontically treated teeth with or without a post. Nevertheless, VRFs can also occur in teeth with no previous root canal treatment. The most susceptible sites and tooth groups are the maxillary and mandibular premolars, mesial roots of the mandibular molars, mesio-buccal roots of the maxillary molars, and mandibular incisors. However, VRFs may occasionally occur in other teeth and roots as well.²

Etiology:-

VRFs may arise from a series of factors, some of which are natural whereas others are iatrogenic, arising from dental procedures. These factors can be broadly divided into two categories: Natural predisposing factors and Iatrogenic predisposing factors.²

Natural predisposing factors:-

Shape of root cross section:-

One of the common anatomic features shared by teeth that typically develop VRFs is an oval cross section of the root, with a bucco-lingual diameter being larger than the mesiodistal diameter. These teeth include the maxillary and mandibular premolars, the mesial roots of the mandibular molars, and the mandibular incisors. Such anatomy is easily observed in the axial plane of a CBCT scan. The fracture in these teeth typically starts in the bucco-lingual plane, specifically at the highest convexity of the oval root. This conclusion, derived from large case series, is also supported by finite element analysis. Such analysis clearly demonstrated strain concentration on the inner side of the remaining dentin wall at the highest convexity point (i.e., the buccal and lingual sides of the oval roots)²

Tooth location and occlusal forces:-

Posterior teeth are significantly more likely to develop a VRF than anterior teeth. This is most likely because posterior teeth, particularly the last standing molar, are subject to higher functional and non-functional occlusal loading.

Parafunctional activity and/or non-working side interferences may also lead to excessive lateral forces on posterior teeth, increasing their susceptibility to VRF⁵:-

Pre-existing (micro-)cracks and fractures:-

Small cracks are often present naturally in the dentin of intact teeth, appearing both parallel and/or perpendicular to the root canal spacelike resulting from repeated forces of mastication or occlusal parafunction. During intra-canal procedures when dentin is removed, especially in the mesio-distal areas, these cracks may be exposed and progress over time in a buccal and/or lingual direction, potentially creating fractures.^(6, 2)

Dentin age:-

Dentin “age” is also considered a predisposing factor for tooth fracture in endodontically treated teeth. Crack extension in older dentin has been shown to propagate at a faster rate than in younger dentin. Also, aged dentin has an increased amount of translucent dentin, making it more susceptible to fracture.⁶

Iatrogenic predisposing factors:-

Change in biomechanical properties of dentine of root treated teeth:-

Root filled teeth have an increased susceptibility to VRF due to changes in the biomechanical properties of dentine. Endodontic treatment can result in depletion of the organic components of root dentine and alteration in the chemical composition. As the pulp complex is mainly composed of water, root filled teeth will inevitably undergo a reduction in free water content (dehydration) within the dentine matrix and dentinal tubules, with a consequent effect on the viscoelastic properties. Dehydration of the dentine can result in lower fracture toughness, decrease in resistance to fatigue failure, as well as reduced microhardness and poorer dissipation of occlusal forces. The effects of dehydration may be considered a possible causative factor in the development of a VRF.⁵

Excessive removal of sound dentine during RCT:-

Peri-cervical dentine (PCD) as the region of a tooth extending approximately 4mm coronal and apical to the crestal bone level. They propose that the loss of sound dentine, most specifically the PCD, incurred during ‘traditional’ access cavity and root canal preparation may predispose the residual tooth structure to fracture and impact survival.⁵

Prolong exposure to intracanal medicaments and disinfectants:-

There are also some recent in vitro studies suggesting that excessive use of various root canal irrigation solutions and medicaments, such as sodium hypochlorite, chelating agents and calcium hydroxide, may change the quality of dentin, possibly causing an increase in dentinal wall erosion that makes the dentin more prone to cracks and fractures.⁶

Methods of obturation:-

Certain obturation techniques, such as lateral compaction, involve the application of internal pressure with a spreader, which may cause strains and subsequent propagation of microcracks into fractures across the full dentin thickness. Other obturation methods may create less pressure, such as thermoplasticized gutta-percha, and may reduce the risk of VRFs.²

Inappropriate execution of post-endodontic restoration (including post preparation):-

Restorative considerations after root canal therapy, such as post space preparation, post type and shape, hydrostatic pressure from traumatic cementation of a post, and the expansion of a post due to corrosion, are all possible additional iatrogenic factors contributing to the initiation of a VRF in endodontically treated teeth. The use of posts carries an inherent risk of root fracture, particularly if excessive dentin is removed during preparation. Posts should only be used when essential for core retention and should be avoided whenever sufficient coronal tooth structure is available for the secure retention of the crown.^(6,2)

Crown design:-

When considering endodontically treated teeth, crowns with a ferrule margin (i.e., supported by a sound tooth structure all around and beyond the gingival margins of the core) provide better strain distribution than similar restorations that are supported by the post and core alone. This design may help to avoid yet another potential predisposing factor for VRFs. Even though endodontic treatment may be necessary because of pulpal pathosis, the impact of each of the iatrogenic predisposing factors should be minimized as much as possible, as they are likely to have a cumulative deleterious effect in perpetuating VRFs.²

Pathogenesis:-

Unlike traumatic dental injuries, which are acute in nature and usually present immediately after a recognized impact, VRFs usually develop as a result of a dynamic cyclical fatigue process, and therefore, may take months, years or even decades to become evident. VRFs may be initiated at any root level. They may also be initiated at the apical part of the root and propagate coronally. Some VRFs originate at the coronal-cervical part of the root and extend apically, and in other cases a VRF may be initiated as a midroot fracture. Although the pathogenesis of VRFs has not been clearly established, it has been proposed that the pathogenesis of vertical root fracture involves a

combination of mechanical stresses and structural weakening of the root dentin. VRFs typically originate within the root canal wall where excessive internal stresses, generated during biomechanical preparation, obturation (especially with high compaction forces), or post placement, exceed the tensile strength of the remaining dentin and initiate a crack that propagates longitudinally along the long axis of the root. These fractures may extend coronally or apically depending on the force direction and dentin thickness, and are more prevalent in roots with reduced dentinal thickness due to extensive instrumentation or restorative procedures. Once the fracture line communicates with the periodontal tissues, oral fluids, bacteria, and their by-products can penetrate the fracture site, leading to localized inflammation, periodontal breakdown, and characteristic clinical signs such as deep probing depths and sinus tract formation.^(6, 2, 5)

Diagnostic Method:-

Diagnosis of a vertical root fracture (VRF) should be based on a comprehensive assessment that integrates the patient's subjective complaints with objective clinical and radiographic findings, rather than relying on a single pathognomonic sign. Early and accurate identification of a VRF is essential to prevent unnecessary nonsurgical retreatment, persistent soft tissue inflammation, progressive bone loss, or unwarranted apical surgery, all of which may further complicate future restorative or implant therapy. However, establishing a definitive diagnosis can be challenging, particularly in endodontically treated teeth, as the clinical presentation often overlaps with other conditions. Common signs and symptoms—such as spontaneous dull pain, discomfort on mastication, tooth mobility, sinus tract formation, isolated deep periodontal probing defects, periodontal-type abscesses, and localized bony radiolucencies—closely resemble those associated with failed endodontic therapy, reinfected root canals, or primary periodontal disease, thereby necessitating careful differential diagnosis.^(7,6)

Biting Pain and Bite Test:-

In order to reproduce the discomfort of the patient while chewing and thus reconfirm their chief complaint, a bite test was suggested. Tools such as rubber wheels or a Tooth Slooth Fracture Detector can be applied. Endodontically treated teeth with a good quality root canal filling that exhibited specific biting pain is regarded as highly suspicious.⁷

Pulp Vitality Test:-

VRFNETT may show vital or necrotic pulpal responses. The nerve tissue may necrotize when the fracture lines progressively extend into the pulp. A VRF is highly suspected in nonvital teeth with an intact structure or minimal restorations, when no other evident etiology can be identified.⁷

Magnification:-

A microscope may assist in identifying the fracture line during nonsurgical or surgical endodontic/periodontal treatments. Magnification and direct light sources are helpful.⁷

Clinical features:-

Occasionally, the patient can be aware of a sharp cracking sound at the time of condensation of gutta percha or the cementation of a post. Bleeding during condensation of a root filling material and an apparent lack of resistance within the canal during condensation, leading to an almost unlimited ability to condense gutta percha into the canal are also signs that a vertical root fracture is present. A common presenting feature is the dislodgement of a post or post crown. A root fracture should be suspected if an apparently well-fitting post or post core becomes dislodged. Because of problems with diagnosis, it is not uncommon for teeth with vertical root fractures to have been treated repeatedly by surgery before the presence of a fracture is suspected. When surgery fails for no obvious reasons, a vertical fracture should be considered a possibility before the periapical area is re-entered surgically.⁸ Most of the non-endodontically treated VRF teeth showed moderate to severe attritions in relatively intact crowns with minimal restorations. The attrited occlusal surface may indicate excessive, repetitive and heavy masticatory stress, which may further lead to root fractures in these patients. According to the 2008 AAE Communiqué, there is a specific combination of signs and symptoms that, when present in the endodontically treated tooth, are considered “pathognomonic” for the presence of a VRF. However, this “pathognomonic combination” is not necessarily present in all VRF cases.⁶

These parameters are:-

Presence of a sinus tract:-

Coronally located sinus tract. Sinus tracts that originate from a chronic apical abscess are typically detected at the site of least bone resistance, against the apical part of the root or in the area of the junction of the attached gingiva and the oral mucosa. Sinus tracts that are associated with a VRF pocket are often found in or close to attached gingiva rather than in the apical region as the source is not from a periapical lesion (Fig 1).² Double or multiple sinus tracts are common (Fig 2). Where multiple sinus tracts are present one or more of these tracts may be located some distance from the involved tooth.⁸ Thus, the insertion of a gutta-percha point into the sinus tract to trace the offending tooth assists in diagnosis. If the gutta-percha cone appears parallel to the periodontal ligament (PDL), a VRF is highly suspected. This unique tracing pattern provides an important diagnostic difference between a VRF and other endodontic or periodontal pathologies.⁷

As in the case of a VRF pocket, if the sinus tract is located at the furcation of a molar, this observation does not necessarily indicate a VRF, as periapical abscesses from re-infected root canal treatment can also drain in this coronal location.²

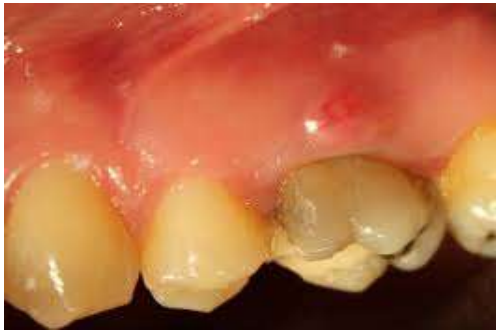

FIG 1 - A draining sinus tract at the gingival margin of a first maxillary molar with a buccal VRF in the mesial

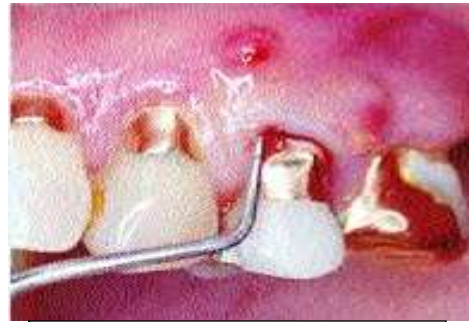

FIG 2 - Double or multiple sinus tracts are a feature of vertically fractured teeth.

Existence of a narrow and deep isolated periodontal defect:-

A common feature of vertically root fractured teeth is the development of deep, narrow, isolated periodontal pockets. Pocketing is usually situated adjacent to the fracture site (FIG 3).⁸ This presentation may be inconsistent with the surrounding periodontal status. This specific type of periodontal defect occurs secondary to the bony dehiscence caused by the VRF. Vertical root fracture pockets. The pockets that are typical of the early stages of VRFs differ substantially from the deep pockets associated with advanced periodontal disease. The deep pockets associated with periodontal disease develop as a result of the bacterial biofilm that initially accumulates at the cervical areas of the tooth and the destructive host response to these bacteria. Therefore, deep periodontal pockets are typically wider coronally and easier to probe. This pocket anatomy allows an easy insertion of a rigid periodontal probe. These types of periodontal pockets typically present with the deeper part of the pocket at the mesial or distal aspects of the tooth. In addition, periodontal disease often affects groups of teeth rather than an isolated location of a single tooth.

The pockets associated with VRFs develop due to bacterial penetration into the fracture, triggering a destructive host response that occurs in the periodontal ligament along the entire length of the fracture. These bacteria may leak from an infected root canal; however, when the VRF extends to the cervically exposed root, the microbes in the fracture may also originate from the oral cavity. In the early stages, the periodontal ligament is affected and destroyed along the longitudinal opening of the fracture, initially with a limited resorption to the adjacent bone. This permits the penetration of a periodontal probe. The pocket associated with a VRF is typically isolated and present only in a limited area adjacent to the affected tooth. This pocket is often located at the buccal or lingual convexity of the tooth (FIG 4)

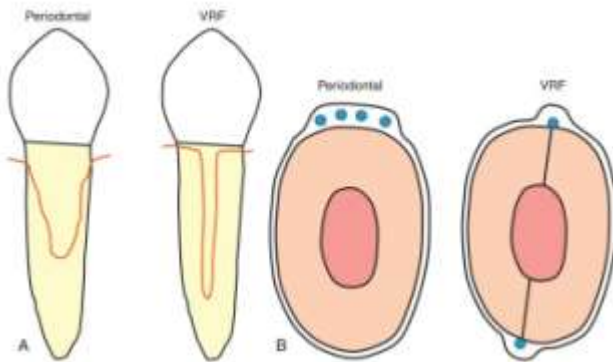


FIG3 - Vertical root fracture (VRF) pocket. A, Periodontal pockets (left) are wide coronally, whereas VRF pockets (right) are narrow and deep. B, Periodontal pockets (left) are loose and allow probing at various sites, whereas VRF pockets (right) are narrow and tight. If not checked carefully at every millimeter of the sulcus, an early VRF pocket can easily be missed. Note that periodontal pockets appear more commonly in the proximal sides of the root, whereas VRF pockets are more common on the buccal or lingual sides.

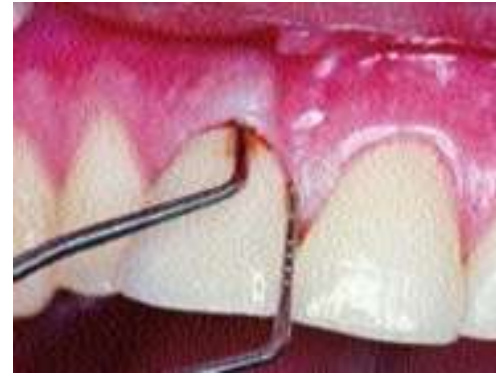

FIG 4 - Maxillary central incisor tooth exhibiting a deep narrow pocket on the labial surface of the tooth with normal attachment in the interproximal area. The presence of a bucco-lingual vertical root fracture was confirmed by surgery.

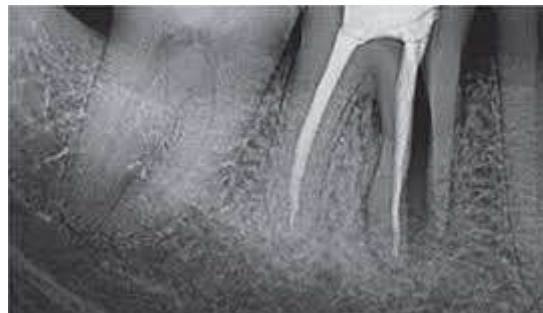Therefore, when a deep narrow periodontal probing defect is present with a coronally located sinus tract, and when a bony dehiscence is observed during exploratory surgery, the tooth with a VRF can be better diagnosed in a timely manner.⁶

Radiographic features:-

Radiographic examination is an essential adjunct in diagnosing VRF, but findings can be variable and in some cases, especially early or incomplete fractures, conventional radiographs may show no observable changes, underscoring the limitations of 2-D imaging. Common radiographic features include:

Separation of root fragments:-

When separation of root fragments occurs, the root fracture is clearly visible. Once separation of fragments has occurred, proliferation of granulation tissue often results in the rapid movement of the fragment away from the remaining root, in many cases until the fragment comes into contact with an adjacent tooth.⁸



Fracture lines along the root or root fillings:-

A fine, hair-like radiolucent fracture line within the root canal or in the root filling may be seen in some cases. Such lines, however, are difficult to detect and are commonly not seen in routine periapical radiographs because either the root canal filling has “masked” the fracture line or the angulation of the x-ray beam is not optimal for discerning the fracture. When a VRF is suspected, one may initiate root canal retreatment, removing the root obturation, and

exposing radiographs at two or three different horizontal angulations. The detection of a hairline radiolucency may provide a more definitive diagnosis of a VRF²



Periradicular and Lateral Radiolucencies (“Halo” / “J-shaped” lesions):-

The J-shaped or halo radiographic appearance of bone loss, a combination of periapical and periradicular radiolucencies, was associated with a high probability of a VRF.²

V-shaped diffuse bone loss on roots of posterior teeth:-

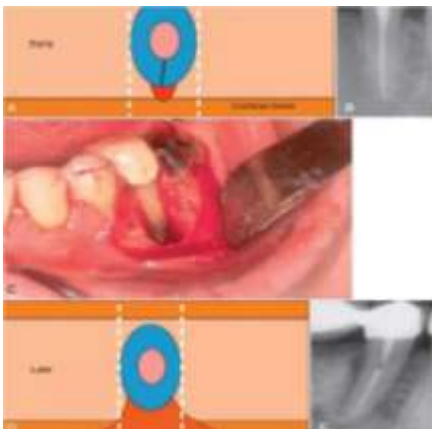
Where the buccal roots of maxillary molars or the roots of lower molars are vertically fractured, the characteristic radiographic image of bone loss is a diffuse V-shaped radiolucency, widest at the crestal bone, narrowing towards the apex. The shape and diffuse radiographic evidence of the bone loss is due to the fact that much of the bone lost is lingual to the buccal plate of bone, which to some extent masks its presence. Diffuse bone loss of this type, when confined to a single root or a single tooth in the mouth, is almost pathognomonic of a vertical root fracture.⁸

Step-like bone defects:-

Step-like bone destruction may develop if the vertical fracture line extends obliquely through the root or does not appear in the apical portion. Shifting 15 degrees in the mesial or distal direction may assist in the observation of the defect. However, step-like bony destruction is not a definite indication of a VRF. Besides a VRF, canal perforations and endodontic lesions are also possible. Thus, the exact diagnosis of a VRF needs to be confirmed with other diagnostic methods.⁷

Osseous radiolucency adjacent to the root:-

The type of periradicular radiolucency associated with a VRF is not and should not be interpreted as a thickening of the PDL. Instead, it represents a substantial destruction of the cortical plate of the alveolar bone. In the case of a VRF in the bucco-lingual plane, often the bone resorption is limited at early stages, and any associated radiolucency may be obscured by the superimposition of the root. As the bone loss increases, the radiolucency becomes greater than the dimensions of the root, allowing it to be detected more clearly.²



Early versus late radiographic presentation of a vertical root fracture-associated bone defect. At an early stage, a bone defect (red) is not likely to be detected in a periapical radiograph, as the root will overlap with the defect (A and B). At later stages, when major damage has occurred to the cortical plate (C), the bone defect may be large enough to extend beyond the silhouette of the root (C and D) and appear as a radiolucent defect along the root (E)

Angular or Vertical Bone Loss Patterns:-

An angular resorption of the crestal bone along the root on one or both sides, without the involvement of the periapical area, mimicking a “periodontal radiolucency”.²

Resorption along the fracture line:-

One of the presenting signs of a vertical root fracture is resorption along the fracture line. This resorption may occur apically where it causes a Vshaped notch in the apical region, or longitudinally along the whole length of the fracture, giving the appearance of an irregular long resorptive defect running along the gutta percha root filling. Disintegration of root canal sealer, silver points and gutta percha in association with extensive resorption of the root has been reported as being a feature of vertically root fractured teeth.⁸

Widened Periodontal Ligament (PDL) Space:-

Localized PDL widening adjacent to the fracture site is a common but nonspecific sign.

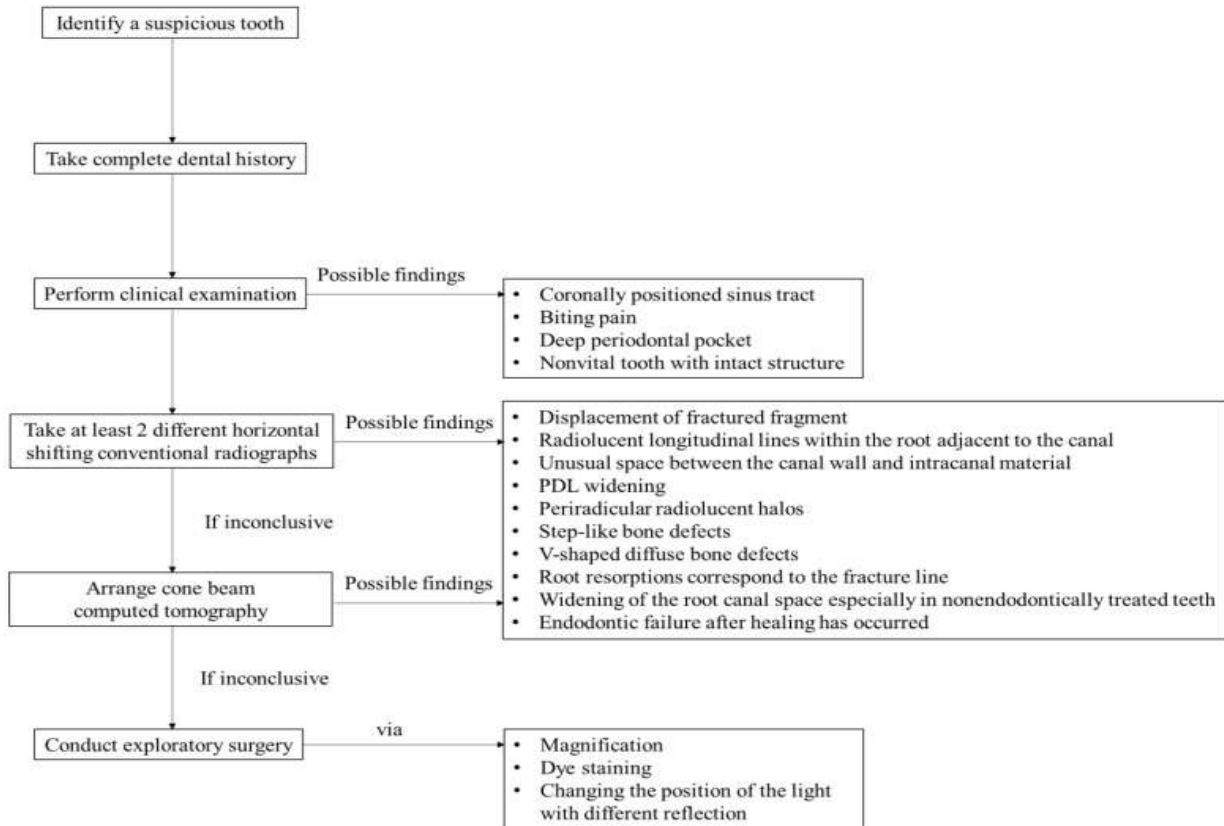
Role of CBCT:-

Cone-beam computed tomography in vertical root fracture diagnosis. Modern cone-beam computed tomography (CBCT) has a much smaller radiation dose compared to traditional medical spiral CT imaging, thus rendering CBCT a reasonable diagnostic tool for use in selected endodontic cases. One of the unique features of CBCT is its ability to study the suspected tooth and associated bone in an axial plane (i.e., the horizontal sectioning of the root). Axial views may provide detailed information regarding the crosssectional appearance of the tooth and its surrounding bone. Considering the resolution of the current CBCT devices, the width of an unseparated fracture may be too small to be detectable. Traditional planar, periapical radiographs are also of limited value for the early detection of VRFs. More specifically, bone damage or separation of the fragments is only radiographically evident at a relatively late stage. Several studies suggested that the detection of early stage VRFs by a CBCT scan set to an axial view may be possible. Yet such detection may greatly depend on the resolution of the machine (i.e., the voxel size). At a voxel size of 0.3 mm, the detection of early, unseparated VRFs is not reliable; however, when smaller voxel sizes were used in these in vitro studies, the reliability greatly increased. Although the detection level of a fracture is thought to be the width of twice the voxel size of the CBCT imaging, there is presently no literature available to support this theory.

Therefore, given that the smallest voxel size currently available for a CBCT device is about 0.075 mm, CBCT imaging would not be able to visualize a root fracture unless the fracture width was greater than 0.15 mm. It should also be noted that the intracanal presence of gutta-percha or a metal post often causes artifacts that make it extremely difficult to discern a VRF. Although the width of early VRFs may still be below the detection level of many CBCT devices, the early destruction of the bone along the suspected fracture may be visible in the cancellous bone (i.e., with an axial view) at relatively early stages, whereas this early bone destruction would not be detectable in traditional two-dimensional periapical radiographs; such bone resorption may help to establish a VRF diagnosis. With likely increased resolution in the near future, CBCT may become a more important diagnostic tool for the detection of VRFs. For the present, neither the most updated Joint Position Statement of the American Association of Endodontists and American Academy of Oral and Maxillofacial Radiology (2010), nor the European Society of Endontology position statement on the use of CBCT in endodontics (2014) recommend the use of CBCT for a definitive diagnosis of VRF. Improvements of CBCT imaging—such as achieving a better signal-to-noise ratio, obtaining a smaller voxel size, and by applying advanced algorithms to segment fracture lines—may promise the potential to enhance the ability to detect early-stage VRFs in the future.²

Visual inspection during exploratory surgery:-

When clinical and radiographic evaluations are equivocal in detecting a suspected VRF, exploratory surgery may be indicated. In the presence of a bony lesion, especially a bony dehiscence, the raising of a full-thickness flap and removal of the granulation tissue may help to facilitate the visualization of a VRF. The bone resorption pattern associated with a VRF is most often seen as a bony dehiscence, with the greater bone destruction being present on the buccal cortical plate located over the offending root. In a small percentage of the cases, a fenestration can be seen. Furthermore, it has been shown that the longer a VRF-related infection persists, the greater the resulting periradicular bone destruction.²



Diagnostic flowchart for the detection of VRF.7

Precautions:-

Prevention is the key to managing VRFs. There are many predisposing factors and iatrogenic causes of these fractures, all of which should be minimized as much as clinically possible.²

The following can reduce potential risks of VRFs:

- 1) Recognize the roots and teeth most susceptible to fracture.
- 2) During endodontic and restorative procedures preserve as much tooth structure as reasonably possible. It is recognized that there may be a challenging balance between the need to achieve a clean root canal system and removing only the amount of dentin necessary for the specific intra-canal procedure.
- 3) Compaction forces during canal obturation should be minimized. Future developments of root canal obturating methods and materials should focus on preventing excessive stresses on root dentin.
- 4) Posts should only be used when necessary for additional core support.
 - Metal posts should have parallel walls with passive fit and round edges.
 - Fiber reinforced resin based composite posts should be used when indicated.
- 5) Full coverage coronal restoration should have a ferrule margin with a vertical length of 1.5 to 2 mm on sound dentin.⁶
- 6) For patients with the habit of bruxism or clenching, night guards were able to provide some protection to minimize the risk of VRF.⁷

Management:-

The aim of treatment for teeth with VRF which appear to be restorable is to retain them in a healthy and functional state; this is usually applicable to incomplete VRF only. The desirable objectives of treatment are to eliminate ingress of microbes along the fracture line and prevent destruction of the periodontium.⁵ There are diverse treatment approaches for VRFs.⁹

Treatment modality	Description	Advantages	Disadvantages
No treatment, just observation with monitoring	Following the actual clinical condition without taking any step in the treatment	Least invasive option, allows assessment of the fracture's stability	Tooth may become symptomatic or fail. Typically leads to tooth loss due to infection or complications
Root resection and root amputation	Removing apex of a tooth's root, or the whole root of multi-rooted teeth	Tooth preservation, maintains the bone density, restores the function and is an alternative to extraction	Complex procedure, risk of residual infection which leads to limited success. Requires surgical skills
Hemisection	The surgical removal of one-half of a tooth, typically in multi-rooted teeth	Can save one portion of the tooth, cost-effective, conservation of healthy roots	May result in a gap if one portion is extracted, also it is a complex procedure
Laser fusion of vertical root fracture	Sealing the fracture line while generating thermal energy	Better alternative than extraction and no treatment	Is not a widely recognized or established dental procedure
Re-cementing, bonding or sealing the fractured fragment	Closing the fracture line with different approaches, with the aim of saving the tooth and sealing the fracture line so the bacteria does not enter	Minimally invasive, compared with resection and hemisection, even though it is often combined with these procedures. Cost-effective and preserves the tooth	Complex procedure, Requires good surgical skills and healthy periradicular tissues, some bacteria can remain within the fracture lines
Intentional replantation	Tooth is intentionally removed from its socket, treated or repaired, and then replanted back into its original position in the patient's mouth	Preservation of natural tooth, less invasive than dental implants and requires fewer dental appointments	Risk of complications, success rates vary, potential for reinfection, risk of root resorption, not suitable for all cases
Prosthetic rehabilitation (partial denture or bridge)	Focused on restoring or replacing missing teeth and associated oral structures to enhance oral function, aesthetics, and overall well-being	Provides a functional and aesthetic replacement of the lost tooth as a result of vertical root fracture	Alteration of adjacent healthy teeth, not suitable for single-tooth replacements, potential for discomfort or instability
Tooth extraction and implant placement	The most common treatment in vertical root fracture cases	Removes the source of infection and brings back the tooth function	Loss of the natural tooth and extra cost for the implant

Conclusion:-

Vertical root fracture (VRF) remains one of the most challenging complications in endodontics due to its multifactorial etiology, insidious progression, and diagnostic ambiguity. The condition frequently mimics persistent endodontic or periodontal disease, often leading to delayed or inappropriate treatment. Accurate diagnosis requires a systematic and integrative approach that combines detailed patient history, meticulous clinical examination, and careful radiographic interpretation. While conventional periapical radiography continues to serve as a primary diagnostic tool, its limitations in early detection are well recognized. Cone-beam computed tomography (CBCT) offers enhanced three-dimensional assessment; however, its diagnostic accuracy remains dependent on voxel size, image resolution, and the presence of restorative materials. Therefore, clinical judgment remains paramount, and exploratory surgery may be necessary in equivocal cases. Management strategies are dictated by the extent and location of the fracture, periodontal involvement, and overall restorability. Although conservative approaches may

be considered in selected incomplete fractures, extraction remains the most predictable treatment for complete VRFs. Emphasis should therefore be placed on prevention. Future advancements in imaging technology and biomaterials may improve early detection and therapeutic outcomes. Until then, prevention, early recognition, and evidence-based decision-making remain the cornerstones in minimizing the clinical impact of vertical root fractures.

References:-

1. Diagnosis Of Cracked Teeth Using Cone-Beam Computed Tomography: Literature Review And Clinical Experience.
2. Cohn
3. Cracked Teeth And Vertical Root Fractures: A New Look At A Growing Problem Aae
4. Is Cone-Beam Computed Tomography More Accurate Than Periapical Radiography For Detection Of Vertical Root Fractures? A Systematic Review And Meta-Analysis
5. Present Status And Future Directions: Vertical Root Fractures In Root Filled Teeth
6. Ingle
7. Vertical Root Fracture In Non-Endodontically And Endodontically Treated Teeth: Current Understanding And Future Challenge
8. Diagnosis And Management Of Teeth With Vertical Root Fractures