



Journal Homepage: - www.journalijar.com

INTERNATIONAL JOURNAL OF ADVANCED RESEARCH (IJAR)

Article DOI: 10.21474/IJAR01/23470

DOI URL: <http://dx.doi.org/10.21474/IJAR01/23470>



RESEARCH ARTICLE

A BIBLIOMETRIC EVALUATION OF RADIONUCLIDE IMAGING APPLICATIONS IN TEMPOROMANDIBULAR JOINT DISORDERS

Menduh Sercan Kaya

1. Dental Specialist, Department of Dentomaxillofacial Radiology, Faculty of Dentistry, Dicle University, Sur, 21280 Diyarbakır, Turkey.

Manuscript Info

Manuscript History

Received: 10 March 2026

Final Accepted: 12 April 2026

Published: May 2026

Key words:-

Bibliometric Analysis, Scintigraphy, Positron Emission Tomography, Radionuclide Imaging, Single Photon Emission Computed Tomography, Temporomandibular Joint.

Abstract

Radionuclide imaging methods are techniques used for the functional evaluation of tissues, and the aim of the present study was to evaluate the structure of the literature on radionuclide imaging methods in temporomandibular joint imaging through bibliometric analysis. The study data were obtained from the Web of Science Core Collection database, and R, RStudio, Biblioshiny, and Bibliometrix were used for the bibliometric analyses. The results demonstrated an increase in annual scientific production, and the term “condylar hyperplasia” was identified as occupying a central position within the literature. It was determined that the literature in this field mainly focuses on condylar hyperplasia and temporomandibular joint metabolic activity.

© 2026 by the Author(s). Published by IJAR under CC BY 4.0. Unrestricted use allowed with credit to the author."

Introduction:-

Nuclear medicine imaging methods constitute a field that utilizes radioactive substances to evaluate tissue functions and diagnose diseases by examining the distribution of these substances. Although these imaging methods are widely used in fields such as oncology and cardiology, they are also employed in dentistry. However, these imaging modalities have several disadvantages. Compared to anatomical imaging methods, they exhibit lower spatial resolution. These high-cost imaging techniques require trained personnel and specialized equipment. In addition, radiation exposure associated with these methods raises concerns for patients, patients' relatives, and healthcare professionals(1-3). However, these methods have the capability to detect biochemical changes in cells before morphological alterations occur, thereby enabling early diagnosis and providing information regarding cellular physiology(4).

Among these imaging modalities, scintigraphy uses gamma cameras and radionuclides to identify regions with high cellular metabolic activity. These regions, where radionuclides accumulate, are visualized as hot spots. Single Photon Emission Computed Tomography overcomes the major limitation of scintigraphy, namely two-dimensional image formation, by performing a 360° gamma camera scan and generating three-dimensional images. Positron Emission Tomography is one of the most advanced imaging methods in nuclear medicine and, unlike other imaging techniques, utilizes positron-emitting radioisotopes instead of gamma-emitting radioisotopes. This allows the detection of smaller changes with greater sensitivity. One of the most common applications of these imaging modalities in dentistry is the imaging of the temporomandibular joint(3, 5-12).

Corresponding Author:- Menduh Sercan Kaya

Address:-Dental Specialist, Department of Dentomaxillofacial Radiology, Faculty of Dentistry, Dicle University, Sur, 21280 Diyarbakır, Turkey.

Although numerous studies have been conducted on temporomandibular joint imaging in dentistry using nuclear imaging methods, there is limited information in the literature regarding the conceptual structure and thematic evolution of this field(13, 14). For this reason, it becomes difficult to identify the development and progression of the field. Bibliometric analysis is a useful method for overcoming these limitations. Through bibliometric analysis, the performance and conceptual structure of a research field can be evaluated using quantitative findings(15-17). The aim of this study was to investigate the use of radionuclide imaging methods in the temporomandibular joint through Annual Scientific Production, Most Cited Documents Analysis, Keyword Co-occurrence Analysis, Thematic Map Analysis, and Thematic Evolution Analysis, and to evaluate the current status and evolution of the literature in this field.

Materials and Methods:-

The present study was designed as a bibliometric analysis investigating the use of radionuclide imaging methods for temporomandibular joint imaging in the field of dentistry. Due to the nature of the bibliometric analysis method, no human or animal subjects were involved; therefore, ethical committee approval was not required. The data used in this study were obtained from the Web of Science Core Collection (WoSCC) database. The dataset was created by entering the following search terms into the WoSCC database: ((scintigraphy OR SPECT OR PET OR radionuclide) AND (TMJ OR TMD OR temporomandibular OR condyle OR "temporomandibular joint") AND (mandible OR mandib* OR maxilla* OR jaw OR dentistry OR maxillofacial)). In order to ensure the homogeneity of the dataset, conference proceedings, editorial letters, and studies unrelated to the subject were excluded. The dataset was generated based on articles published between 1995 and 2025. R (version 4.6.0), RStudio, and the Bibliometrix package (version 5.3.0) through Biblioshiny were used for the bibliometric analysis. Within the scope of performance analysis, Annual Scientific Production and Most Cited Documents Analysis were evaluated. In order to investigate the conceptual structure of the field, Keyword Co-occurrence Analysis, Thematic Map Analysis, and Thematic Evolution Analysis were performed.

The conceptual structure of the field was examined using network-based clustering approaches. In the Keyword Co-occurrence Analysis, only author keywords were included. During the analysis, the colors within the generated network structure represented different thematic groups, the node size indicated keyword frequency, and the edge thickness represented the strength of co-occurrence. Within the scope of the Thematic Map Analysis, basic themes, motor themes, niche themes, and emerging/declining themes were evaluated. In addition, the development of existing themes over time was investigated through Thematic Evolution Analysis.

Results:-

A total of 167 articles indexed in the WoSCC database were included in the study. Until 2004, the annual scientific production remained relatively lower compared to subsequent years, whereas a general increasing trend accompanied by fluctuations was observed in the following years. The lowest annual scientific production was recorded in 2004, while the highest annual scientific production was reached in 2023 (Figure 1).

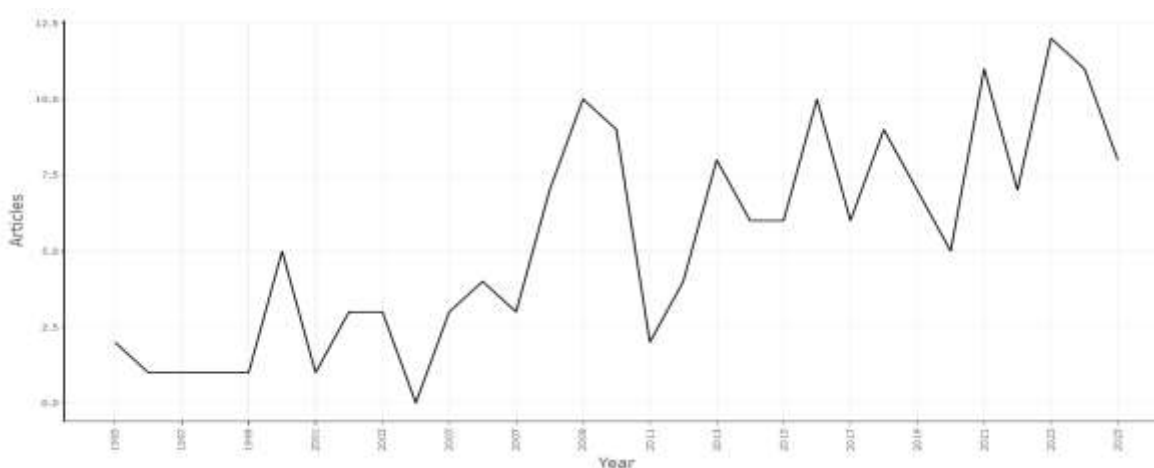


Figure 1. Annual Scientific Production Related to Radionuclide Imaging Methods in Temporomandibular Joint Research Between 1995 and 2025.

Evaluation of the Most Globally Cited Documents Analysis revealed that the study by Nitzan et al.(10)had the highest number of citations with 143 citations, followed by the study by Suh et al.(18)with 97 citations and the study by Hodder et al.(19)with 94 citations (Figure 2).

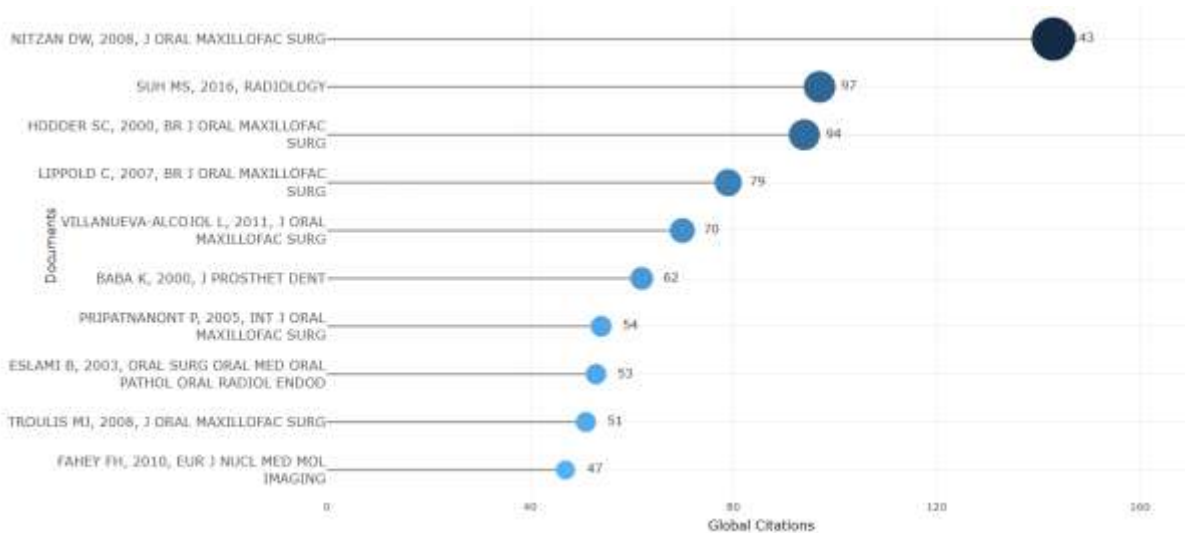


Figure 2. Most Globally Cited Documents Related to Radionuclide Imaging Methods in Temporomandibular Joint Research.

Evaluation of the Authors’ Keywords Co-occurrence Analysis demonstrated that the term “condylar hyperplasia” was located at the center of the generated network and exhibited a high degree of connection density. This term showed strong associations with the terms “temporomandibular joint,” “scintigraphy,” “facial asymmetry,” and “condylectomy” (Figure 3).

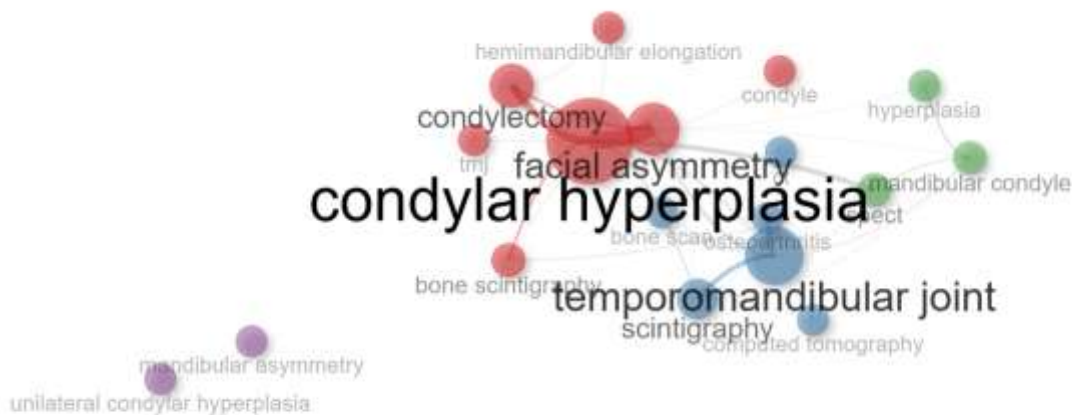


Figure 3. Authors’ Keywords Co-occurrence Network Related to Radionuclide Imaging Methods in Temporomandibular Joint Research.

Evaluation of the Thematic Map Analysis in the present study demonstrated that the terms “temporomandibular joint,” “bone scintigraphy,” and “joint” were located in the motor themes area, whereas the terms “management,” “hyperplasia,” “condylectomy,” “diagnosis,” “bone-scintigraphy,” and “condylar hyperplasia” were positioned

within the basic themes area. In addition, the terms “mandibular condyle,” “CT,” “PET,” “scintigraphy,” “tomography,” and “skeletal” were identified in the niche themes area, while the terms “osteochondroma,” “orthognathic surgery,” and “TMJ” were located in the emerging/declining themes region (Figure 4).

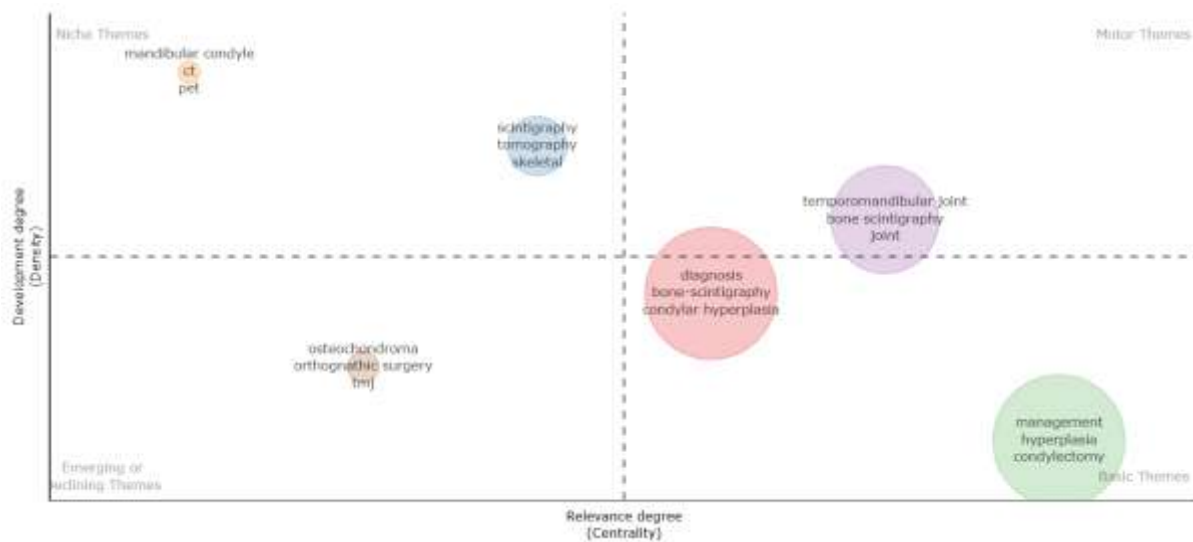


Figure 4. Thematic Map Related to Radionuclide Imaging Methods in Temporomandibular Joint Research.

Evaluation of the Thematic Evolution Analysis demonstrated that, during the early period, the themes “diagnosis,” “scintigraphy,” “bone scintigraphy,” “mandibular condyle,” “growth,” “rheumatoid arthritis,” and “cancer” were prominent. In the later period, the terms “diagnosis” and “scintigraphy” maintained their presence, while the themes “temporomandibular joint,” “condylar hyperplasia,” “bone scintigraphy,” and “mandibular asymmetry” became more prominent (Figure 5).

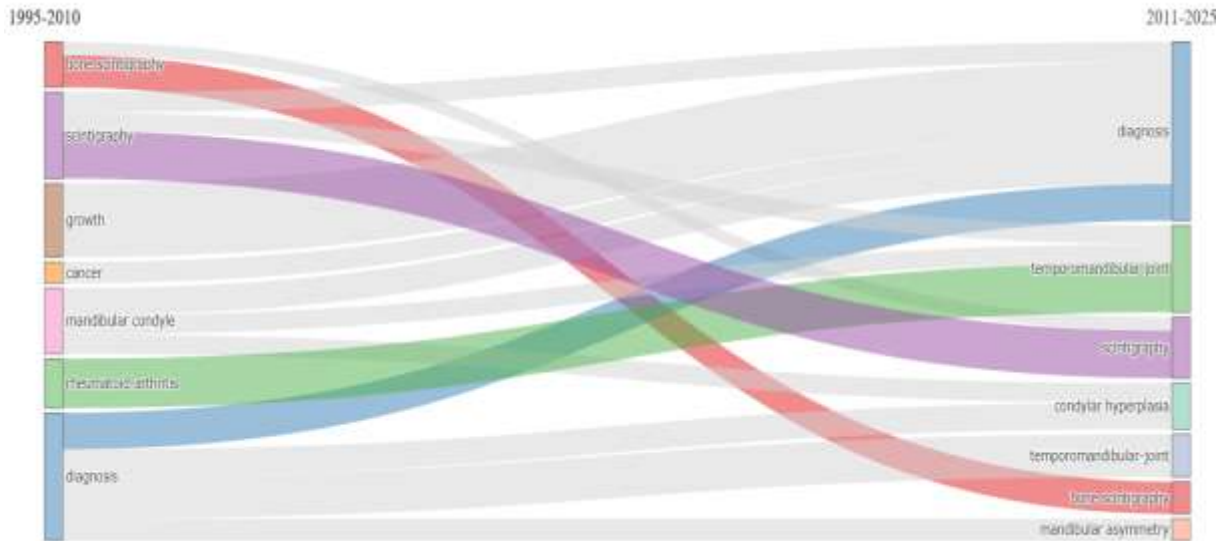


Figure 5. Thematic Evolution Related to Radionuclide Imaging Methods in Temporomandibular Joint Research.

Discussion:-

Nuclear medicine imaging methods are techniques that enable the diagnosis of pathological conditions by utilizing the radioactive decay properties of radioisotopes. Nuclear medicine represents a specialized field across all areas of healthcare and has great diagnostic importance through modalities such as scintigraphy, Positron Emission Tomography, and Single Photon Emission Computed Tomography. This importance also extends to dentistry. In these methods, the distribution of administered radioactive isotopes is evaluated using specialized scanners. Although there are studies regarding this field in dentistry, a lack of awareness still exists (13, 14, 20, 21). In addition, since this is a developing field, there is limited information regarding its scientific production, conceptual structure, and thematic evolution. Therefore, it is necessary to evaluate the conceptual structure and current status of the field.

Evaluation of the Annual Scientific Production related to nuclear imaging methods in dentistry demonstrated a general increasing trend over the years despite the presence of fluctuations. This trend may be associated with the growing interest in functional imaging methods for the evaluation of temporomandibular joint disorders. The ability of nuclear medicine imaging modalities to assess metabolic activity in conditions such as condylar hyperplasia, osteoarthritis, and inflammatory temporomandibular joint diseases may have contributed to the expansion of their applications in dentistry. In addition, the fluctuations observed in annual scientific production may be related to the fact that the field has developed around certain specific clinical topics(14, 22, 23). Evaluation of the Most Globally Cited Documents Analysis revealed that the most highly cited studies were focused on temporomandibular joint imaging(10, 18, 19). This finding suggests that the evaluation of the temporomandibular joint using nuclear medicine imaging methods holds an important place in the field of dentistry.

Evaluation of the Authors' Keywords Co-occurrence Analysis regarding the present topic demonstrated that the term "condylar hyperplasia" played a central role within the network structure with a high degree of connection density. In particular, the strong associations of the terms "scintigraphy," "facial asymmetry," and "condylectomy" with "condylar hyperplasia" suggest that the field has been shaped around temporomandibular joint pathologies, facial asymmetry, and surgical planning. In addition, the presence of the term "computed tomography" within the network structure indicates the current position of hybrid imaging methods in the field(22, 24).

Evaluation of the Thematic Map Analysis demonstrated that the terms "temporomandibular joint," "bone scintigraphy," and "joint" were located within the motor themes cluster. This finding indicates that scintigraphy-based imaging methods are among the current and extensively investigated themes in the evaluation of joint disorders within the literature(22). The themes "diagnosis," "bone-scintigraphy," "condylar hyperplasia," "management," and "condylectomy" were located within the basic themes cluster. This finding indicates that these are research themes with a high degree of centrality and demonstrates that radionuclide imaging methods are important not only for diagnostic purposes but also in relation to surgical treatments(25, 26). The placement of the terms "CT," "PET," "scintigraphy," "tomography," "mandibular condyle," and "skeletal" within the niche themes cluster indicates that hybrid and advanced radionuclide imaging methods are concentrated around specific research areas in temporomandibular joint imaging(27). The positioning of the terms "osteochondroma" and "orthognathic surgery" within the emerging/declining themes cluster indicates that these areas have been investigated to a limited extent in the literature but represent specific research topics that are important in terms of particular clinical applications(28, 29).

Evaluation of the Thematic Evolution Analysis demonstrated that, during the early period, the terms "bone scintigraphy," "scintigraphy," "growth," "mandibular condyle," "rheumatoid arthritis," and "diagnosis" were prominent. This finding suggests that the research focus was directed toward the evaluation of temporomandibular joint growth activity and inflammatory joint diseases using scintigraphy. In later periods, the emphasis on the terms "condylar hyperplasia," "bone scintigraphy," and "mandibular asymmetry" indicates that the research field became concentrated on the assessment of temporomandibular joint metabolic activity and the evaluation of facial asymmetry. The presence of the terms "diagnosis" and "scintigraphy" in both periods demonstrates that the evaluation of the temporomandibular joint through scintigraphy has remained a long-standing focus of research.

The limitations of this study include the creation of the dataset through searches performed only in the WoSCC database using English-language terms. However, the fact that English is the most widely used language in the literature and that the WoSCC database has high indexing standards increases the reliability of the study.

Conclusion:-

In conclusion, the obtained data demonstrated an increase in annual scientific production. Overall, the literature was found to be mainly concentrated on temporomandibular joint hyperplasia and scintigraphy. Future studies are recommended to include search terms in different languages and to incorporate different databases.

References:-

1. Merrick MV. Essentials of nuclear medicine: Springer Science & Business Media; 2012.
2. Lundberg TM, Gray PJ, Bartlett ML. Measuring and minimizing the radiation dose to nuclear medicine technologists. *Journal of nuclear medicine technology*. 2002;30(1):25-30.
3. Erdoğan Ç, Akay G. Nuclear Imaging Applications in Dentistry. *ADO Klinik Bilimler Dergisi*. 2024;13(3):562-9.
4. Mallya S, Lam E. *White and Pharoah's Oral Radiology: Principles and Interpretation*: Mosby; 2018.
5. Jo JH, Bae S, Gil J, Oh D, Park S, Cheon GJ, et al. Limited implication of initial bone scintigraphy on long-term condylar bone change in temporomandibular disorders—Comparison with cone beam computed tomography at 1 year. *Journal of Oral Rehabilitation*. 2021;48(8):880-90.
6. Coutinho A, Fenyó-Pereira M, Dib LL, Lima ENP. The role of SPECT/CT with ^{99m}Tc-MDP image fusion to diagnose temporomandibular dysfunction. *Oral Surgery, Oral Medicine, Oral Pathology, Oral Radiology, and Endodontology*. 2006;101(2):224-30.
7. Wassef HR, Colletti PM. Nuclear medicine imaging in the dentomaxillofacial region. *Dental Clinics*. 2018;62(3):491-509.
8. Jeong H-J, Cho B-H, Jung Y-H. Comparison of planar scintigraphy and bone SPECT with clinical findings and other imaging modalities in temporomandibular disorder patients. *Korean Journal of Oral and Maxillofacial Radiology*. 2004:91-7.
9. Ahn B-C, Kim H-J, Lee S-W, Yoo J, Choi J-K, Lee J. New quantitative method for bone tracer uptake of temporomandibular joint using Tc-99m MDP skull SPECT. *Annals of nuclear medicine*. 2009;23(7):651-6.
10. Nitzan DW, Katsnelson A, Bermanis I, Brin I, Casap N. The clinical characteristics of condylar hyperplasia: experience with 61 patients. *Journal of Oral and Maxillofacial Surgery*. 2008;66(2):312-8.
11. Saridin C, Rajmakers P, Al Shamma S, Tuinzing D, Becking A. Comparison of different analytical methods used for analyzing SPECT scans of patients with unilateral condylar hyperactivity. *International journal of oral and maxillofacial surgery*. 2009;38(9):942-6.
12. Lee J, Lee S, Kim SJ, Choi J, Baek K. Clinical utility of fluoride-18 positron emission tomography/CT in temporomandibular disorder with osteoarthritis: comparisons with ^{99m}Tc-MDP bone scan. *Dentomaxillofacial Radiology*. 2013;42(2):292-300.
13. Buch SA, Babu SG, Castelino RL, Rao S, Madiyal A, Bhat S. Nuclear imaging in the field of dentistry: A review. 2017.
14. Rajbaran Singh S, Gutta AA. A Review of the role of Nuclear Medicine Imaging in Diagnostic Dentistry. *South African Dental Journal*. 2021;76(10):624-31.
15. Ellegaard O. The application of bibliometric analysis: disciplinary and user aspects. *Scientometrics*. 2018;116(1):181-202.
16. Donthu N, Kumar S, Mukherjee D, Pandey N, Lim WM. How to conduct a bibliometric analysis: An overview and guidelines. *Journal of business research*. 2021;133:285-96.
17. Passas I. Bibliometric analysis: the main steps. *Encyclopedia*. 2024;4(2).
18. Suh MS, Lee WW, Kim Y-K, Yun P-Y, Kim SE. Maximum standardized uptake value of ^{99m}Tc hydroxymethylene diphosphonate SPECT/CT for the evaluation of temporomandibular joint disorder. *Radiology*. 2016;280(3):890-6.
19. Hodder S, Rees J, Oliver T, Facey P, Sugar A. SPECT bone scintigraphy in the diagnosis and management of mandibular condylar hyperplasia. *British Journal of Oral and Maxillofacial Surgery*. 2000;38(2):87-93.
20. Shreenivasamurthy P, Shastry SL. Nuclear medicine in orofacial diagnosis: A review. *Journal of Medicine, Radiology, Pathology and Surgery*. 2016;2(4):12-6.
21. Stefanache A, Mihai C, Lungu II, Calin G, Mihalache C, Grigoriu D, et al. EVOLUTION AND APPLICATIONS OF RADIOPHARMACEUTICALS IN NUCLEAR DENTISTRY: A COMPREHENSIVE OVERVIEW. *Romanian Journal of Oral Rehabilitation*. 2024;16(1).
22. Yang Z, Reed T, Longino BH. Bone scintigraphy SPECT/CT evaluation of mandibular condylar hyperplasia. *Journal of nuclear medicine technology*. 2016;44(1):49-51.

23. Kim J-Y, Lee C, Park YL, Lee J-H, Ryu YH, Huh J-K. Diagnostic criteria for temporomandibular joint osteoarthritis using standardized uptake value in single-photon emission computed tomography-computed tomography. *Scientific Reports*. 2024;14(1):31569.
24. López DF, Ríos Borrás V, Muñoz JM, Cardenas-Perilla R, Almeida LE. SPECT/CT Correlation in the diagnosis of unilateral condylar hyperplasia. *Diagnostics*. 2021;11(3):477.
25. Wen B, Shen Y, Wang C-Y. Clinical Value of 99Tcm-MDP SPECT Bone Scintigraphy in the Diagnosis of Unilateral Condylar Hyperplasia. *The Scientific World Journal*. 2014;2014(1):256256.
26. Rodriguez I, Mut F. Quantitative bone SPECT analysis of mandibular condyles in an asymptomatic population: An approach to normal reference values. *International Journal of Oral and Maxillofacial Surgery*. 2021;50(6):733-9.
27. Israel O, Pellet O, Biassoni L, De Palma D, Estrada-Lobato E, Gnanasegaran G, et al. Two decades of SPECT/CT—the coming of age of a technology: an updated review of literature evidence. *European journal of nuclear medicine and molecular imaging*. 2019;46(10):1990-2012.
28. Follacchio GA, Ricci M, Ramieri V, Vellone V, Frantellizzi V, Liberatore M, et al. Unilateral condylar hyperplasia recurrence after orthognathic surgery: a case report. *RADIOLOGY AND DIAGNOSTIC IMAGING*. 2017;1(2):1-4.
29. Yamamoto FP, Silva BSdF, Modes RW, Fonseca FP, Pontes FSC, de Sousa SCO. Computed tomography and scintigraphy exams for diagnosis and treatment planning of the condylar osteochondroma: A case report. *Revista Odonto Ciência*. 2010;25:422-6.